

Generic Contrast Agents

Our portfolio is growing to serve you better. Now you have a *choice*.



FRESENIUS
KABI

[VIEW CATALOG](#)

AJNR

Radiography of Trigeminal Neuralgia and Hemifacial Spasm

David Sobel, David Norman, Craig H. Yorke and Thomas H. Newton

AJNR Am J Neuroradiol 1980, 1 (3) 251-253

<http://www.ajnr.org/content/1/3/251>

This information is current as
of May 15, 2025.

Radiography of Trigeminal Neuralgia and Hemifacial Spasm

David Sobel¹
David Norman¹
Craig H. Yorke²
Thomas H. Newton¹

Radiographic findings in 68 patients with trigeminal neuralgia and 24 patients with hemifacial spasm are reviewed. The relative value of various radiographic diagnostic procedures is discussed. Trigeminal neuralgia and hemifacial spasm are usually caused by vascular compression of the trigeminal root entry zone and facial nerve exit zone respectively. Computed tomography (CT) of the posterior fossa is the only radiographic screening procedure required. Angiography should be reserved for patients in whom CT findings suggest an aneurysm or tumor.

The most common remediable cause of trigeminal neuralgia and hemifacial spasm is vascular compression of the fifth and seventh cranial nerves, respectively [1-3]. Microsurgical vascular decompression almost always provides clinical relief [4, 5]. Wilson et al. [4] recently reported excellent results with microsurgical decompression in 50 patients with trigeminal neuralgia and 22 patients with hemifacial spasm treated between 1969 and 1979. Our report reviews the radiographic findings in the patients in the latter series, adding 20 patients studied since that report. The radiographic findings and the relative value of various radiographic diagnostic procedures are discussed.

Materials and Methods

Of 68 patients with trigeminal neuralgia evaluated, 40 (59%) were female and 28 (41%) were male. Age range was 39-76 years (mean, 57). Symptoms were right-sided in 33 patients, left-sided in 30, and bilateral in five.

There were 24 hemifacial spasm patients; 23 (96%) were female and one (4%) was male. Age range was 26-82 years (mean, 53). Symptoms were right-sided in 13 patients and left-sided in 11 (bilateral in none).

Results

Trigeminal Neuralgia

A total of 61 patients (90%) was evaluated by pre- and postcontrast computed tomography (CT). Vascular abnormalities were found in six patients and tumors in two (table 1). In six of the eight patients CT disclosed a lesion that at surgery was thought to be the cause of the trigeminal neuralgia (figs. 1 and 2). Seven patients were studied with vertebral angiography. One of these had breast

Received December 19, 1979; accepted January 14, 1980.

¹Department of Radiology, M 396, University of California School of Medicine, San Francisco, CA 94143. Address reprint requests to D. Norman.

²Department of Neurological Surgery, University of California School of Medicine, San Francisco, CA 94143.

This article appears in May/June 1980 *AJNR* and July 1980 *AJR*.

AJNR 1:251-253, May/June 1980
0195-6108/80/0103-0251 \$00.00
© American Roentgen Ray Society

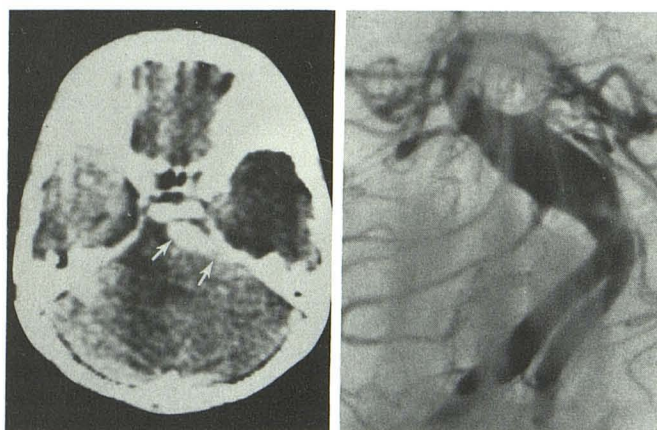
carcinoma; one had a carotid bruit; in one the presence of an arteriovenous malformation was suspected; in two CT scanning was unavailable; in the other two CT findings indicated aneurysmal dilatation of the basilar or vertebral

arteries. Angiographic abnormalities were found in only two patients. Skull films of 16 patients showed no abnormalities. Operative findings are summarized in table 2.

TABLE 1: Trigeminal Neuralgia: CT Abnormalities

Abnormality (8 patients)	Responsible Lesion
Dolichoectasia, vertebrobasilar artery	Same and superior cerebellar artery
Dolichoectasia, vertebrobasilar artery	Same
Dolichoectasia, basilar artery	Vein
Basilar artery aneurysm*	Same
Basilar artery aneurysm	Posterior inferior cerebral artery
Vertebral artery aneurysm*	Same
Cerebellopontine angle epidermoidoma	Same
Fifth nerve schwannoma	Same

* Angiographically confirmed



A

B

Fig. 1.—A, Postcontrast axial CT. Tubular-shaped area of enhancement in left cerebellopontine angle (arrows) typical for fusiform basilar artery aneurysm. Left-to-right shift of fourth ventricle. B, Angiographic confirmation.

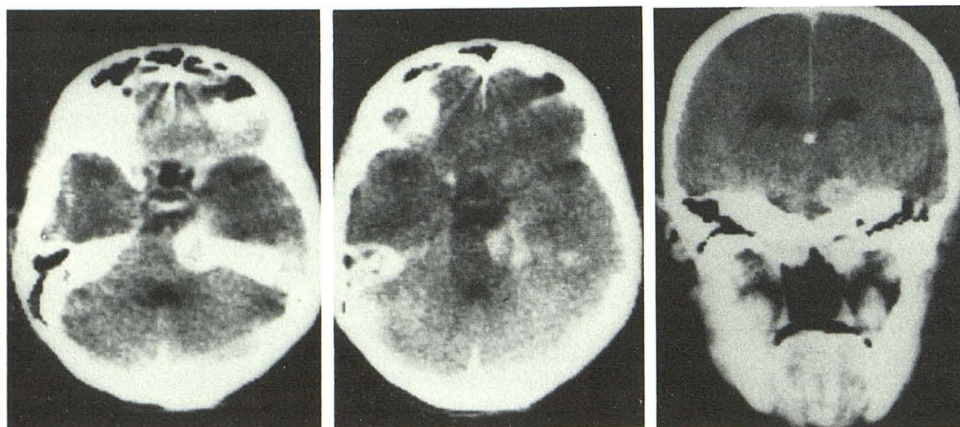
Hemifacial Spasm

Of the 24 patients, 18 (75%) were evaluated by pre- and postcontrast CT. A basilar artery aneurysm was identified in one patient. At surgery, a branch of the posterior inferior cerebral artery and not the basilar artery itself was found to be the responsible lesion. A cerebellopontine angle epidermoid was demonstrated in the second patient (fig. 3). At surgery, the epidermoid and a branch of the posterior inferior cerebral artery, were thought to be the cause of the hemifacial spasm. The other 16 CT examinations were normal. In most of the 12 patients studied by vertebral angiography, it was performed because CT was unavailable. Angiograms were abnormal in six patients (table 3). In only two of these six did the angiographic findings correspond to the surgically identified responsible lesion. Skull films in six patients were normal. Operative findings are summarized in table 4.

Discussion

Trigeminal neuralgia and hemifacial spasm are cranial nerve dysfunction syndromes with many shared features [6–8]. Both nerves are located in the cerebellopontine angle. Symptoms are limited to the distribution of the involved cranial nerve. Trigeminal neuralgia is characterized by sudden severe paroxysms of pain, usually confined to the second and/or third division of the trigeminal nerve. Hemifacial spasm is characterized by paroxysmal unilateral twitching of the orbicularis oculi muscle, which gradually progresses to prolonged intense spasm of all the facial muscles on one side. Symptoms tend to occur in middle age and are characterized by paroxysms of activity resembling the effect of electrical stimulation.

In their first microsurgical approach to a patient with trigeminal neuralgia in 1966, Ruby and Janetta [6] noted



A

B

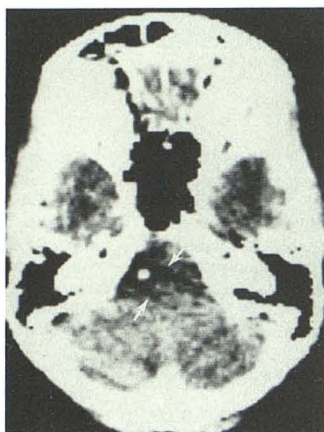
C

Fig. 2.—Trigeminal neuralgia. Postcontrast axial (A and B) and coronal (C) scans. Fifth nerve neurinoma extends from Meckel cave to involve ambient and cerebellopontine angle cisterns. Patient had trigeminal neuralgia.

TABLE 2: Trigeminal Root Entry Zone: Surgical Findings

Compressing Structure	No. Patients (n = 68)
Superior cerebellar artery	43
Anterior inferior cerebellar artery	9
Posterior inferior cerebellar artery	1
Vein	12
Aneurysm	3
Tumor	2
None	7

Fig. 3—Hemifacial spasm. Postcontrast axial scan. Low density lesion (arrows) in left cerebellopontine angle with serpiginous, poorly defined borders and central calcification. Patient had hemifacial spasm. Calcified epidermoid removed at surgery.



arterial cross-compression in the trigeminal root entry zone. Similar observations referable to the seventh nerve were made in patients with hemifacial spasm [1, 3, 6]. In most of our patients with either trigeminal neuralgia or hemifacial spasm, the vessel found at operation to be responsible for vascular cross-compression was not identified by either CT or vertebral angiography. A loop of the superior cerebellar artery compressing the fifth nerve at its brainstem entry zone was usually responsible for trigeminal neuralgia, whereas a loop of the anteroinferior cerebellar artery compressing the seventh nerve exit zone was most often associated with hemifacial spasm. In the three patients with trigeminal neuralgia caused by aneurysms, the lesions were identified on CT. In the one patient with an aneurysm identified as the cause of hemifacial spasm, CT was unavailable. In the two patients (3%) with tumors identified as the cause of trigeminal neuralgia and the one patient (4%) with a tumor identified as the cause of hemifacial spasm, the diagnosis was made by CT. Angiographic confirmation was not deemed necessary.

On the basis of the above, it seems that a pre- and postcontrast scan of the posterior fossa is the only screening procedure required for evaluation of patients with either hemifacial spasm or trigeminal neuralgia. Angiography should be reserved for those patients in whom CT findings suggest an aneurysm or tumor. Skull films play no useful

TABLE 3: Hemifacial Spasm: Angiographic Abnormalities

Abnormality (6 of 12 patients)	Responsible Lesion
Tortuous vertebral artery	Same
Tortuous vertebral artery	Posterior inferior cerebellar artery
Tortuous vertebral artery	Anterior inferior cerebellar artery
Tortuous vertebral artery	Anterior inferior cerebellar artery
Tortuous vertebral artery	Anterior inferior cerebellar artery
Tortuous vertebrobasilar junction	Same and posterior inferior cerebellar artery
Ectatic anterior and posterior inferior cerebellar arteries	Anterior inferior cerebellar artery

TABLE 4: Facial Nerve Root Exit Zone: Surgical Findings

Compressing Structure	No. Patients (n = 24)
Anterior inferior cerebellar artery	13
Vertebral artery; posterior inferior cerebellar artery complex	10
Vein	2
Tumor	1
Aneurysm	1
None	0

role in the evaluation of patients with hemifacial spasm or trigeminal neuralgia. A tumor is the cause of symptomatic nerve compression in only 3–4% of patients.

REFERENCES

1. Gardner WJ. Concerning the mechanism of trigeminal neuralgia and hemifacial spasm. *J Neurosurg* 1962;19:947–958
2. Gardner WJ, Miklos MV. Response of trigeminal neuralgia to decompression of sensory root. Discussion of cause of trigeminal neuralgia. *JAMA* 1959;170:1773–1776
3. Janetta PJ. Trigeminal neuralgia and hemifacial spasm. Etiology and definitive treatment. *Trans Am Neurol Assoc* 1975;100:89–91
4. Wilson CB, Yorke C, Prioleau G. Microvascular decompression for trigeminal neuralgia and hemifacial spasm: experience with 72 cases. *West J Med* 1980 (In press)
5. Maroon JC. Hemifacial spasm. A vascular cause. *Arch Neurol* 1978;35:481–483
6. Ruby JR, Janetta PJ. Hemifacial spasm: ultrastructural changes in the facial nerve induced by neurovascular compression. *Surg Neurol* 1975;4:369–370
7. Kramer RA, Eckman PB. Hemifacial spasm associated with redundancy of the vertebral artery. *AJR* 1972;115:133–136
8. Kerber CW, Margolis MT, Newton TH. Tortuous vertebrobasilar system: a cause for cranial nerve signs. *Neuroradiology* 1972;4:74–77