



## Discover Generics

Cost-Effective CT & MRI Contrast Agents



FRESENIUS  
KABI

WATCH VIDEO

# AJNR

## **Third cranial nerve palsy caused by gummatous neurosyphilis: MR findings.**

T Vogl, S Dresel, H Lochmüller, C Bergman, C Reimers and J Lissner

*AJNR Am J Neuroradiol* 1993, 14 (6) 1329-1331

<http://www.ajnr.org/content/14/6/1329>

This information is current as  
of June 1, 2025.

# Third Cranial Nerve Palsy Caused by Gummatous Neurosyphilis: MR Findings

T. Vogl,<sup>1</sup> S. Dresel,<sup>1</sup> H. Lochmüller,<sup>2</sup> C. Bergman,<sup>1</sup> C. Reimers,<sup>2</sup> and J. Lissner<sup>1</sup>

**Summary:** The clinical and MR findings in an unusual case of gummatous neurosyphilis are reported. A 44-year-old woman suffering from diplopia and right-sided headaches was admitted. Physical examination and routine laboratory parameters were normal except for a third-nerve palsy. MR images revealed a contrast-enhancing lesion of the upper brain stem and third cranial nerve. Differential diagnosis included neuroma of the third cranial nerve, as well as neurosarcoidosis and other inflammatory processes. Serologic tests and lumbar puncture revealed the presence of active syphilis. After intravenous treatment with penicillin G, follow-up MR examinations showed diminishing size of the lesion with its complete resolution within 3 months.

**Index terms:** Syphilis; Nerves, oculomotor (III); Neuroma; Sarcoidosis; Brain, magnetic resonance

Syphilis may involve the central nervous system at almost any stage of the disease, from weeks to decades after the primary infection (1). Neurosyphilis develops in about 5% of untreated syphilitic patients (2). The diagnosis of neurosyphilis has always been elusive, largely because of its frequently nonspecific clinical presentation and the occurrence of seronegative forms of the disease (3). With the development of effective antibiotic therapy, neurosyphilis has become less frequent, further hampering its diagnosis. However, new cases continue to appear, both sporadically and as a complication of acquired immunodeficiency syndrome (AIDS).

We report the clinical and magnetic resonance (MR) findings and the course after therapy of a female patient with gummatous neurosyphilis.

## Case Report

A 44-year-old woman was admitted for the evaluation of insidious onset of diplopia and right-sided frontal headaches over a period of 7 weeks. Her medical history included no history of neurologic or venereal disease. Physical examination, as well as the routine laboratory parameters electrocardiogram, ultrasound of the abdomen, and x-ray of the chest were normal. Neurologic examination

revealed an incomplete ptosis of the right eye. The right pupil was dilated, with loss of direct and consensual light reflexes. All right-sided extraocular muscles except the superior oblique and lateral rectus muscles were severely paretic. A nearly complete palsy of the right oculomotor nerve was diagnosed.

The first MR examination (Fig 1), on a 1.5-T unit, showed a hyperintense area in the region of the midbrain in T2-weighted images (3000/90) (repetition time/echo time). After administration of gadopentetate dimeglumine there was marked enhancement in T1-weighted sequences (500/17). Because of the MR appearance, the differential diagnosis of this lesion included neuroma of the third cranial nerve as well as neurosarcoidosis and other inflammatory processes.

A lumbar puncture yielded clear, colorless cerebrospinal fluid, containing eight white cells per cubic millimeter. The cerebrospinal fluid findings may be summarized as showing inflammation with pleocytosis. Serologic tests confirmed the presence of active syphilis. This finding and the pleocytosis indicated active neurosyphilis. The patient was treated with 30 million U/day of penicillin G intravenously for 14 days. Serologic findings were negative for human immunodeficiency virus 1 and 2, Coxsackie B-virus, herpes simplex virus, Lyme-borreliosis, toxoplasmosis, echinococcosis, and cysticercosis.

The MR examination 2 months after commencement of therapy revealed a lesion clearly reduced in size with homogeneous gadopentate dimeglumine enhancement in T1-weighted sequences and hyperintensity in T2-weighted images. The rapid response of this lesion to therapy made the diagnosis of a gummatous lesion most likely.

In the most recent MR examination (Fig 2), 3 months after therapy, there was a normal appearance of the affected area. At this point, the patient's clinical symptoms and neurologic finding had resolved as well.

## Conclusion

Most patients with neurosyphilis are asymptomatic (2). The major symptomatic types of neurosyphilis are the meningovascular forms and the parenchymatous forms, tabes dorsalis and gen-

Received June 23, 1992; revision requested September 14, received November 4, and accepted November 8.

<sup>1</sup> Department of Radiology, University of Munich, Siemssenstrasse 1, 8000 Munich 2, Germany. Address reprint requests to Th. Vogl, MD.

<sup>2</sup> Department of Internal Medicine, Friedrich Baur Institute, University of Munich, 8000 Munich 2, Germany.

AJNR 14:1329-1331, Nov/Dec 1993 0195-6108/93/1406-1329 © American Society of Neuroradiology



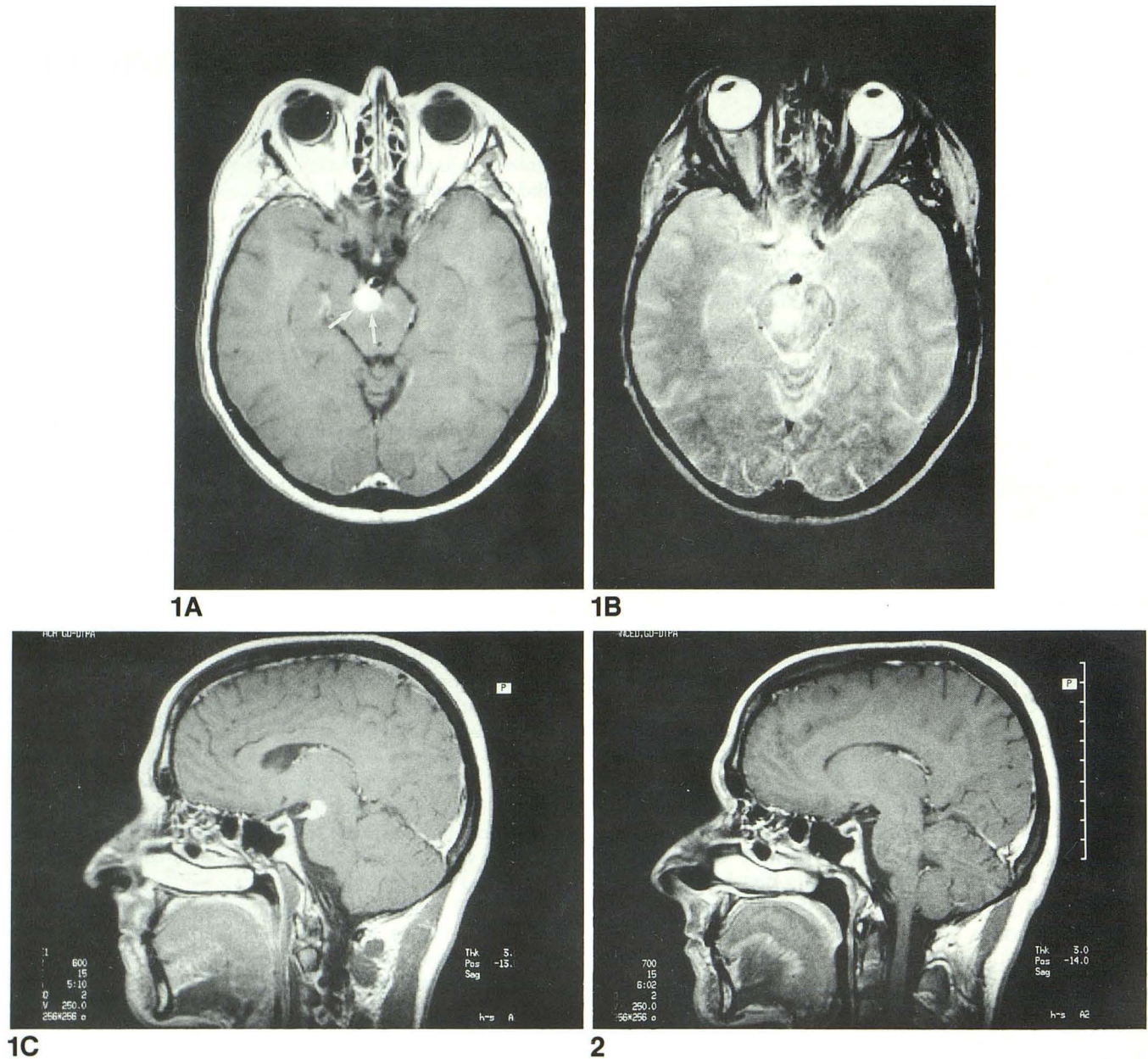


Fig. 1. Patient before therapy.

A, Axial-enhanced scan (500/25). A sharply demarcated, hyperintense area in the region of the ventral midbrain is seen (arrows). There are no signs of infiltrative growth.

B, Unenhanced scan (3000/90). The T2-weighted image also shows an area of high signal intensity. The region is not as well demarcated as in the gadolinium-enhanced T1-weighted image, probably due to surrounding edema. This finding makes the diagnosis of neuroma of the third cranial nerve very unlikely and a meningovascular process more likely. Lateral deviation of the right globe is seen, indicating right third nerve palsy.

C, Enhanced sagittal scan (500/25). The sagittal orientation shows the location of the lesion to the right of interpeduncular cistern, along the cisternal course of third nerve.

Fig. 2. Patient three months after therapy.

Sagittal enhanced scan (500/25). Three months after therapy the former lesion has disappeared completely.

eral paresis. Although mixed features are common, the parenchymatous type comprises the more well known forms of the disease, including general paresis with widespread parenchymal damage and tabes dorsalis with demyelination of the posterior columns, dorsal roots, and dorsal root ganglia. The meningovascular type, accounting for a minority of all cases of neurosyphilis (4), may be associated with focal or widespread central nervous system changes. Clinically, meningovascular syphilis may manifest as an acute stroke syndrome or, more commonly, as a subacute illness, with a prodrome of weeks to months. Symptoms include headache, vertigo, seizures, transient hemiplegia, insomnia, and psychological disturbances (5, 6). These symptoms may appear from months to more than a decade after the primary infection, with an average latency of 7 years (4). Pathologic findings include widespread thickening of the meninges and perivascular spaces, with lymphocytic infiltration. The angiographic findings of neurosyphilis include segmental constriction and occlusion of the supraclinoid carotid and proximal horizontal portions of the anterior and middle cerebral arteries.

In this case, clinical, cerebrospinal fluid, and MR findings strongly suggested the presence of

gummatous neurosyphilis, seen in MR as an enhancing soft-tissue lesion in the region of the exit of the third cranial nerve from the midbrain. There were no other findings to suggest the presence of the more common forms of neurosyphilis as mentioned above. MR imaging documented the reduction of size of the lesion under therapy, including its resolution at a 3-month follow-up, thus corroborating the diagnosis.

Gummatous neurosyphilis should be included in the differential diagnosis of focal brain lesions, because the patient will benefit from antibiotic treatment.

## References

1. Holland BA, Perrett LV, Mills CM. Meningovascular syphilis: CT and MR findings. *Radiology* 1986;158:439-442
2. Clark EG, Danbolt N. The Oslo study of the natural course of untreated syphilis. *Med Clin North Am* 1964;48:613
3. Hooshman H, Escobar M, Kopf S. Neurosyphilis: a study of 241 patients. *JAMA* 1972;219:726-729
4. Merritt H, Adams R, Solomon H. Neurosyphilis. New York: Oxford University Press, 1946
5. Holmes MD, Brant-Zawadzki MN, Simon RP. Clinical features of meningovascular syphilis. *Neurology* 1984;34:553-556
6. Godt P, Stoeppler L, Wrscher U, Schroeder H. The value of computed tomography in cerebral syphilis. *Neuroradiology* 1979;18:197-200