



Discover Generics

Cost-Effective CT & MRI Contrast Agents



FRESENIUS
KABI

WATCH VIDEO

AJNR

Localized cerebral proton MR spectroscopy in HIV infection and AIDS.

W K Chong, M Paley, I D Wilkinson, M A Hall-Craggs, B Sweeney, M J Harrison, R F Miller and B E Kendall

AJNR Am J Neuroradiol 1994, 15 (1) 21-25

<http://www.ajnr.org/content/15/1/21>

This information is current as
of June 5, 2025.

Localized Cerebral Proton MR Spectroscopy in HIV Infection and AIDS

W. K. Chong,¹ M. Paley,¹ I. D. Wilkinson,¹ M. A. Hall-Craggs,¹ B. Sweeney,² M. J. G. Harrison,² R. F. Miller,³ and B. E. Kendall¹

PURPOSE: To document differences in the cerebral proton MR spectra of patients with early and late stages of human immunodeficiency virus (HIV) infection. **METHOD:** We studied the relative N-acetyl-aspartate (NAA) levels by localized proton spectroscopy of the parietooccipital region of the brain in 43 HIV-seropositive patients, including 26 with an acquired immunodeficiency syndrome (AIDS)-defining diagnosis, and in eight control subjects. **RESULTS:** Reduced relative NAA levels were shown in those HIV-1-seropositive patients: 1) with AIDS against HIV1-seropositive patients without AIDS ($P < .04$); 2) with HIV1-associated cognitive/motor complex against neurologically healthy patients ($P < .007$); 3) with encephalopathic changes on MR against those with normal imaging ($P < .001$); and 4) on follow-up against their results on initial study ($P < .03$). **CONCLUSIONS:** By clinical (Centers for Disease Control classification) and radiologic (MR evidence of white-matter disease) criteria indicating late-stage HIV infection, reduced relative levels of NAA have been demonstrated. Spectroscopic abnormalities can be quantitatively tracked with time. This paper demonstrates the clinical use of detecting NAA as a putative in vivo measure of the neuronal loss that has been demonstrated in postmortem studies of patients with AIDS. This neuronal loss, which is believed to underlie the HIV-1-associated cognitive/motor complex, is thought to be attributable directly or indirectly to the presence of HIV in the brain. Proton spectroscopy may serve as a quantitative noninvasive indicator of this aspect of cerebral involvement in HIV disease.

Index terms: Magnetic resonance, spectroscopy; Brain, magnetic resonance; Acquired immunodeficiency syndrome (AIDS)

AJNR Am J Neuroradiol 15:21-25, Jan 1994

Clinical and radiologic manifestations of central nervous system involvement in human immunodeficiency virus (HIV) infection generally occur after the onset of immune suppression (1, 2) (Manji H, et al. Seventh International Conference on AIDS, Florence, Italy, 1991). In addition to opportunistic infections and tumors, encephalopathy (3) and myelopathy (4) also occur which have been attributed to the HIV. Clinically the encephalopathy may present with signs and

symptoms that comprise the HIV-1-associated cognitive/motor complex, previously known as the acquired immunodeficiency syndrome (AIDS) dementia complex (5). A number of histopathologic papers have described the presence of neuronal loss on examination of postmortem brains of HIV-infected patients (6-8); more recently, neuronal loss has been shown in the occipital and parietal lobes and in brains demonstrating minimal changes at necropsy (Everall IP, et al. Fourth International Conference: The Neuroscience of HIV Infection, Amsterdam, 1992). The mechanisms involved in the cause of this neuronal loss need to be elucidated, because these are likely to underlie the development of the dementia complex.

Proton magnetic resonance spectroscopy (¹H-MRS) offers a noninvasive in vivo method of measuring the cerebral content of N-acetyl-aspartate (NAA), a chemical that is largely confined

Received August 12, 1992; accepted pending revision December 4; revision received January 12, 1993.

This project was supported by the Medical Research Council (MRC) of Great Britain. W. K. Chong, M. Paley, and M. A. Hall-Craggs are funded by the MRC.

¹ MR Unit, ² Department of Neurological Sciences, and ³ Department of Medicine, The Middlesex Hospital, Mortimer Street, London, W1N 8AA, England. Address reprint requests to W. K. Chong, MD.

AJNR 15:21-25, Jan 1994 0195-6108/94/1501-0021

© American Society of Neuroradiology

to neurons (9, 10). There has been some early work exploring this technique in the clinical context of AIDS (11, 12). This study further investigates the clinical use of ^1H -MRS as a putative measure of neuronal loss in HIV infection and AIDS. In particular, we aimed to compare those seropositive patients who had clinical or radiologic evidence of late-stage disease with those in the early stages of infection.

Materials and Methods

Forty-three HIV-seropositive patients were studied prospectively, including 26 who had developed an AIDS-defining diagnosis or an AIDS-related complex (ARC) diagnosis (Centers for Disease Control clinical classification CDC group IV). Two patients were believed to have acquired the virus through heterosexual contact with high-risk partners. The rest were homosexual men. Eight healthy volunteers who did not belong to any high-risk group for HIV infection participated as controls. The age distributions of the subjects are summarized in Table 1, and this will be addressed in the Results and Discussion.

All the patients were clinically assessed before MR scanning and spectroscopy. Twenty-three had a full neurologic assessment, including mental test scores, by a clinical neurologist and were specifically assessed for features satisfying the criteria for the HIV-1-associated cognitive/motor complex as defined by the American Academy of Neurology AIDS Task Force (5). The results of follow-up spectroscopy were available on 15 patients, performed between 3 and 8 months after their initial study.

Imaging and spectroscopy was performed on a Siemens 1.5-T Magnetom SP scanner (Siemens Medical Systems, Erlangen, Germany) using a standard transmit-receive head coil.

Diagnostic MR imaging was performed in all cases. This was in the form of a dual-echo spin-echo sequence (3500/20–90/1 [repetition time/echo time/excitations]) using contiguous 5-mm transverse sections to cover the entire cranium. The scans were interpreted by a neuroradiologist and scored for the presence or absence of the white-matter abnormalities that suggest the HIV encephalopathy described earlier.

TABLE 1: Mean age and age ranges of the patient groups

Clinical/Radiologic Grouping	Mean Age	Age Range
Seropositive non-ARC/AIDS (CDC groups II and III) (n = 17)	38.3	31–56
Seropositive with ARC/AIDS (CDC group IV) (n = 26)	38.6	25–62
Neurologically healthy (n = 14)	35.7	25–45
HIV cognitive/motor complex (n = 6)	36.5	26–62
No encephalopathy on images (n = 34)	37.6	25–62
Encephalopathy on images (n = 9)	40.4	30–59
Control (n = 8)	29.3	21–38

The method for spectroscopy in this prospective study was chosen specifically to allow the study of very ill patients and to minimize data after processing with the aim of applying the protocol to a busy clinical unit. ^1H -MRS from a located $2 \times 2 \times 2$ -cm volume of interest placed in the parietooccipital region of the brain was obtained in all cases. Where mass lesions were present, the volume of interest was placed in a parietooccipital region distant from the lesion. In all cases, a suitably large region of brain was available for spectroscopy. This region was chosen mainly for ease of shimming during spectroscopy, with the added benefit of allowing sufficient leeway for minor adjustments in voxel positioning in patients with cerebral atrophy or focal lesions.

A 90-180-180 spin-echo sequence was used to obtain the spectra (1600/135/256). Water suppression was achieved using a single gaussian chemically selective pulse. Phase distortions caused by residual eddy currents were corrected in accordance with the method of Ordidge and Creshull (13). A mild gaussian time-domain filter (4-Hz line broadening) was then applied in all cases before Fourier transformation.

At this echo time, three major peaks are fully resolved (see Fig 1). The areas under the curves for the NAA peak, the creatine/phosphocreatine (Cr) peak, and the total choline (Cho) peak were measured for each case using the standard software supplied by Siemens, and then the NAA:(NAA + Cr + Cho) ratio was calculated. The use of ratios is necessary in ^1H -MRS because there is no direct measure of the metabolite concentrations. Until a practical, reliable, and rapid method for absolute quantification of metabolites in a clinical setting is established, the use of metabolite ratios to describe abnormalities on in vivo ^1H -MRS remains the accepted norm.

The clinical assessment was performed blind to the results of the imaging and spectroscopy. The neuroradiologist interpreting the scans and the physicist interpreting the spectra were blinded, where possible, to the clinical status of the patient. This was obviously not possible when there were intracranial lesions present.

The results from the patients were grouped by their clinical CDC status, evidence of HIV-1-associated cognitive/motor complex, or the presence or absence of encephalopathic changes on their images. Those in CDC group IV or with abnormal imaging were considered at a late stage of disease. The mean NAA:(NAA + Cr + Cho) ratios for each group were calculated, and the significance of the differences between the means was tested using the Student unpaired *t* test. The results in those for whom follow-up was performed were compared with the results from their initial studies and the differences between the means tested with the paired *t* test.

Results

The results are summarized in Table 2. Typical examples of the spectra in relation to abnormal imaging are shown in Figures 2 and 3.

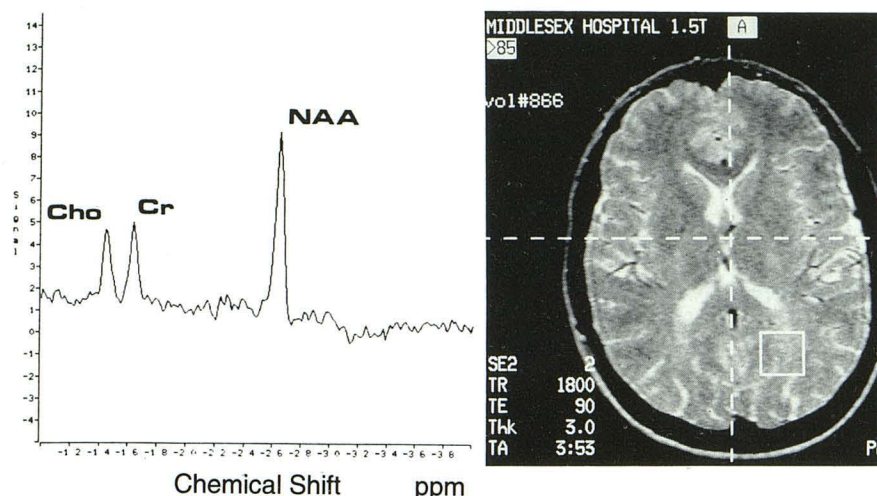


Fig. 1. ^1H -MRS spectrum (1600/135) and localizer image from a 35-year-old healthy volunteer demonstrating the position and size of the $2 \times 2 \times 2$ -cm volume of interest and the three major resonances studied.

TABLE 2: Summary of results by patient groups: NAA: (NAA + Cho + Cr) ratios

Clinical/Radiologic Grouping	Mean Ratio	SD	P Value
Seropositive non-ARC/AIDS (CDC groups II and III) (n = 17)	0.51	0.053	<.04
Seropositive with ARC/AIDS (CDC group IV) (n = 26)	0.47	0.069	
Neurologically healthy (n = 14)	0.52	0.043	<.007
HIV cognitive/motor complex (n = 6)	0.46	0.042	
No encephalopathy on images (n = 34)	0.51	0.050	<.001
Encephalopathy on images (n = 9)	0.42	0.068	
Follow-up ^1H -MRS (n = 15):			
Initial study	0.50	0.039	<.03
Follow-up study	0.48	0.045	
Control (n = 8)	0.56	0.039	See text

A significant reduction in the NAA:(NAA + Cho + Cr) ratios (NAA ratio) has been demonstrated in seropositive patients who have developed ARC or AIDS (CDC group IV) against those who have not had an AIDS-defining diagnosis (CDC groups II and III) ($P = .04$). The mean NAA ratio in the ARC/AIDS group was 8% less than in the non-ARC/AIDS group.

Of the 23 seropositive patients formally assessed by a neurologist, three were excluded from this analysis because their abnormal clinical signs were related to the presence of intracranial mass lesions detected on MR. Fourteen were found to be neurologically normal. The remaining six satisfied the criteria for the HIV-1-associated cognitive/motor complex (5). The mean NAA ratio in those six cases was 11% less than in the neurologically healthy group ($P = .007$).

Those patients who had encephalopathic changes on their MR scans, as determined by the presence of the diffuse white-matter abnormalities described earlier, had lower ratios than their

seropositive counterparts with normal-appearing white matter ($P < .0001$). The mean NAA ratio in the group with encephalopathy was 18% less than in the group with normal imaging.

The results from eight non-HIV high-risk-group healthy controls are included for comparison. The mean NAA:(NAA + Cho + Cr) ratios in these controls were significantly higher by 16% than the seropositive CDC group-II and -III patients ($P = .03$) and also significantly higher by 9% than in all seropositive patients with normal imaging ($P = .006$).

We also had the opportunity to perform follow-up spectroscopy on 15 patients who returned between 3 and 8 months (with a mean interval of 5.4 months) after their initial studies. Despite the relatively short follow-up period, there is a trend toward declining NAA ratios with a significant difference between the mean values at initial study and follow-up.

The mean ages in each of the clinical and radiologic groups are shown in Table 1. There was no significant difference between the ages of the CDC II and III and CDC IV groups, between the patients with and without encephalopathy on imaging, and between patients satisfying the criteria for the HIV-1-associated cognitive/motor complex and those who were neurologically healthy.

Discussion

Proton spectroscopy offers a method of tracking noninvasively and quantitatively relative changes in a chemical that is largely confined to neurons, changes that may serve as a measure of neuronal integrity if not neuronal loss. Post-mortem studies have demonstrated a diffuse neu-

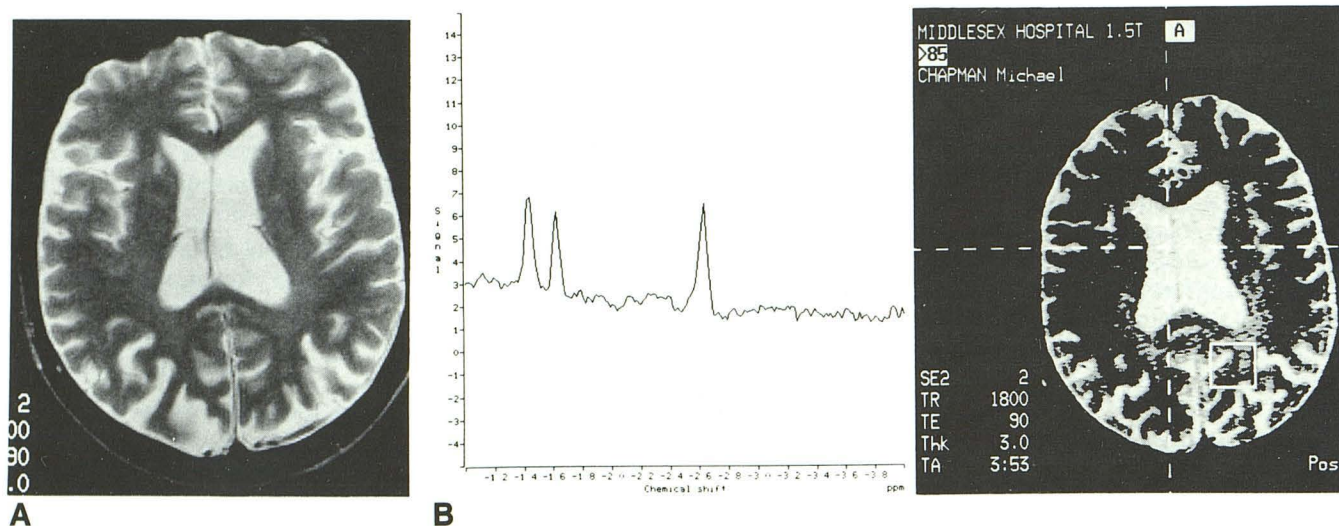


Fig. 2. A, T2-weighted image (3500/90) of a 29-year-old patient with mild encephalopathic changes of diffuse white-matter disease and minimal cerebral atrophy.

B, The spectrum (1600/135) and located image of the patient with mild encephalopathy on imaging. Note the marked reduction in the relative size of the NAA peak with respect to the other two peaks in the context of minimal changes on MR.

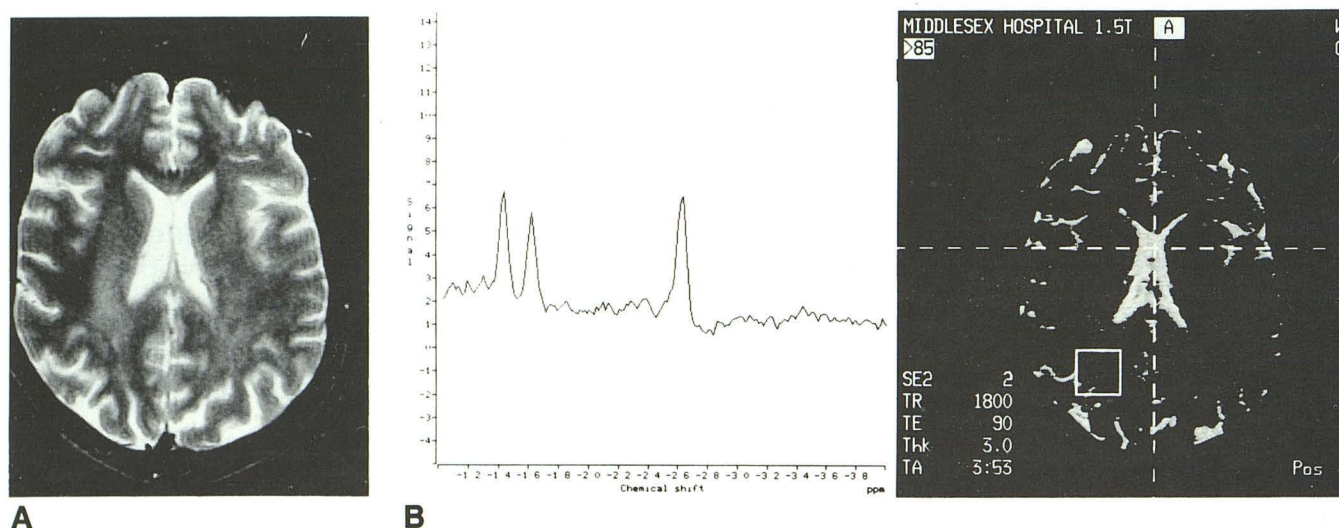


Fig. 3. A, T2-weighted image (3500/90) of a 40-year-old patient with moderately severe cerebral atrophy and few white-matter changes.

B, The spectrum (1600/135) and located image of the patient with moderately severe cerebral atrophy. The NAA peak is relatively reduced in size in a region of the brain that displays normal signal patterns on MR.

ronal loss in HIV-infected patients, which is believed to be directly or indirectly related to the presence of the HIV. A quantitative *in vivo* measure of neuronal integrity may serve as an indicator of the degree of central nervous system involvement in HIV infection and AIDS. It also may serve as an objective and alternative measure of the efficacy of disease-modifying drugs with respect to the central nervous system. More carefully constructed and detailed studies also may help to reveal the possible mechanisms that underly

the neuronal loss by addressing the multitude of confounding variables.

The spin-echo technique used in this study is one of the better-established sequences and produces a good signal-to-noise ratio. A standard echo time of 135 was chosen to optimize the resolution of the three major resonances that have long T2 relaxation times and to help distinguish any lactate in the spectrum, which produces inverted peaks at this echo time.

Improvements in the Siemens software user

interface and automated shimming facility allowed us to obtain the spectra consistently between 15 and 25 minutes, thereby making it a realistic clinical tool. In concentrating on one region of the brain, we have accounted for any regional variations in the cerebral metabolites.

Early work by Tallan (9) in 1957, which has been further elucidated by Nadler and Cooper (10) in 1972, is the basis for the generally accepted premise that NAA is largely confined to neurons. Its role in the central nervous system is still not clearly established, although it is believed to be involved with lipid or protein synthesis, and it may be a storage buffer for aspartate (14).

Reduced NAA levels (inferred from reductions in NAA:Cr and NAA:Cho ratios) in two patients with AIDS who had normal imaging have been reported by Menon et al (11). Our findings with larger numbers indicate that there is in fact a spectrum of NAA values in HIV-infected patients, and it is not possible, without rigorous age and risk-group matching of controls, to determine what levels can be considered abnormally reduced. Our findings also seem to indicate a relative reduction in NAA levels (inferred from differences in the NAA ratios) of about 9% in the HIV-infected group with normal imaging when compared to the non-HIV high-risk-group controls ($P = .006$). We have noted, however, that our control group is younger on average, despite an overlap of the age ranges. We may expect a decline in detectable NAA levels to parallel neuronal loss with age (15) (Itoh S, et al, Society of Magnetic Resonance in Medicine 11th Annual Meeting, 1992) and so these results should be interpreted with caution.

The most important findings in this paper are the differences in the NAA ratios between the patients with AIDS and their seropositive counterparts who had not developed AIDS and between those seropositive patients with encephalopathic changes on MR and those without. These groups were well matched for age. In those with clinical or radiologic evidence of late-stage HIV infection, this study has demonstrated reduced relative levels of NAA. A mean decline in NAA ratios also has been shown to occur at early follow-up. As a putative measure of neuronal loss, this study has demonstrated noninvasive and in vivo evidence of the neuronal loss that has been seen at necropsy in patients dying from AIDS-related diseases.

The method allows a different perspective on the detection of early central nervous system changes resulting from HIV infection and offers a method for monitoring disease progression. The latter may have major implications on studying the effects of disease-modifying drugs.

Acknowledgments

We acknowledge the assistance of Rolf Sauter, PhD, and Siemens Medical Systems for their continued support of MRS.

References

- McArthur JC, Cohen BA, Selnes OA, et al. Low prevalence of neurological and neuropsychological abnormalities in otherwise healthy HIV-1-infected individuals: results from the Multicenter AIDS Cohort Study. *Ann Neurol* 1989;26:601-611
- Post MJD, Berger JR, Quencer RM. Asymptomatic and neurologically symptomatic HIV-seropositive individuals: prospective evaluation with cranial MR imaging. *Radiology* 1991;178:131-139
- Price RW, Brew BJ. The AIDS dementia complex. *J Infect Dis* 1988;158:1079-1083
- Petito CK, Navia BA, Cho ES, et al. Vacuolar myelopathy pathologically resembling subacute combined degeneration in patients with AIDS. *N Engl J Med* 1985;312:874-879
- American Academy of Neurology AIDS Task Force. Nomenclature and research case definitions for neurologic manifestations of human immunodeficiency virus-type 1 (HIV-1) infection. *Neurology* 1991;41:778-785
- Ketzler S, Weis S, Haug H, Budka H. Loss of neurons in the frontal cortex in AIDS brains. *Acta Neuropathol* 1990;80:92-94
- Wiley CA, Masliah E, Morey M, et al. Neocortical damage during HIV infection. *Ann Neurol* 1991;29:651-657
- Everall IP, Luthbert PJ, Lantos PL. Neuronal loss in the frontal cortex in HIV infection. *Lancet* 1991;337:1119-1121
- Tallan HH. Studies on the distribution of N-acetyl-L-aspartic acid in the brain. *J Biol Chem* 1957;224:41-45
- Nadler JV, Cooper JR. N-acetyl-L-aspartic acid content of human neural tumours and bovine peripheral nervous tissues. *J Neurochem* 1972;19:313-319
- Menon DK, Baudouin CJ, Tomlinson D, Hoyle C. Proton MR spectroscopy and imaging of the brain in AIDS: evidence of neuronal loss in regions that appear normal with imaging. *J Comput Assist Tomogr* 1990;14:882-885
- Menon DK, Ainsworth JG, Cox IJ, et al. Proton MR spectroscopy of the brain in AIDS dementia complex. *J Comput Assist Tomogr* 1992;16:538-542
- Ordridge RJ, Creshull ID. The correction of transient B₀ field shifts following the application of pulsed gradients by phase correction in the time domain. *J Magn Reson* 1986;69:151-155
- Birkin D, Oldendorf WH. N-acetyl-L-aspartic acid: review of a compound prominent in the ¹H NMR spectroscopic studies of the brain. *Neurosci Behav Rev* 1989;13:23-30
- Henderson G, Tomlinson BE, Gibson PH. Cell counts in human cerebral cortex in normal adults throughout life using an image analysing computer. *J Neurol Sci* 1980;46:113-136