



Discover Generics

Cost-Effective CT & MRI Contrast Agents



WATCH VIDEO

AJNR

Ocular ischemic syndrome during carotid balloon occlusion testing.

E J Russell, K Goldberg, J Oskin, C Darling and O Melen

AJNR Am J Neuroradiol 1994, 15 (2) 258-262

<http://www.ajnr.org/content/15/2/258>

This information is current as
of June 1, 2025.

Ocular Ischemic Syndrome during Carotid Balloon Occlusion Testing

Eric J. Russell, Kenneth Goldberg, James Oskin, Crystal Darling, and Onur Melen

Summary: The use of a double-lumen balloon catheter for temporary occlusion testing of the internal carotid artery permits simultaneous perfusion of the distal internal carotid artery (and ophthalmic artery) with heparinized saline. If saline is infused too rapidly, the result may be total or partial replacement of oxygenated blood within the ophthalmic artery. This replacement may produce the signs and symptoms of ocular ischemic syndrome. These include ipsilateral orbital pain and progressive unocular visual loss. Simple technical adjustments in the performance of the occlusion test can prevent the development of this syndrome. Failure to recognize the cause of the observed visual loss may produce the false impression of a positive occlusion test or may falsely suggest that a thromboembolic complication has occurred. Awareness of the occurrence of this syndrome should prevent confusion concerning the predictive result of provocative carotid occlusion testing.

Index terms: Interventional neuroradiology, provocative testing; Interventional neuroradiology, complications of; Arteries, carotid (internal); Arteries, ophthalmic; Iatrogenic disease or disorder

Temporary balloon occlusion of the carotid artery is commonly performed to test tolerance before more permanent surgical or endovascular arterial obliteration. The test is often a prelude to permanent balloon occlusion of the internal carotid artery in patients with giant unclippable aneurysms. It is performed with the patient awake to permit repeated neurologic testing. Patients are fully heparinized to reduce the risk of thromboembolic complications.

During the last 2 years, we have discovered patterned intraprocedural clinical findings that are related to the specific technical methods we use for temporary carotid occlusion. Although it took us some time to appreciate the significance of the signs and symptoms that we now attribute to technique, provocative maneuvers performed late in the evolution of our theory confirmed our impression of their cause.

The use of a double-lumen balloon catheter for temporary occlusion of the carotid artery permits simultaneous perfusion of the artery (with heparinized saline) beyond the obstructing balloon. This helps to minimize the risk of distal thromboembolism, but saline replaces blood within the carotid artery beyond the balloon. Too rapid an infusion of saline, administered by a pressure pack, may result in total or partial replacement of oxygenated blood within the ophthalmic artery (Fig 1). This replacement produces the signs and symptoms of ocular ischemic syndrome, including ipsilateral orbital pain and associated progressive visual loss.

Ocular ischemic syndrome (1–7) may occur in noniatrogenic situations, most commonly in patients with unilateral or bilateral atherosclerotic internal carotid artery occlusion. In these cases, it is presumed that inadequate collateral supply exists to the orbit from the contralateral internal carotid and ipsilateral and contralateral external carotid systems. Inadequate perfusion of the optic nerve, orbit, and retina lead to regional ischemic pain and visual loss. Although the mechanism of ischemia is different in our cases (replacement of blood with saline), the clinical signs are identical.

Simple technical adjustments in the performance of the occlusion test can prevent the clinical syndrome. Failure to recognize this cause of intraprocedural unilateral visual loss may produce the false impression of a positive balloon occlusion test or falsely suggest that a thromboembolic complication has occurred.

Materials and Methods

Over the past 2 years, 30 consecutive patients underwent temporary balloon occlusion testing of the carotid artery. The clinical indications for occlusion testing, intra-

Received July 14, 1992; accepted pending revision October 26; revision received January 4, 1993.

Presented at the 30th Annual Meeting of the American Society of Neuroradiology, St Louis, Mo, May 31–June 5, 1992.

From the Department of Diagnostic Radiology, Section of Neuroradiology (E.J.R., K.G., J.O.), and the Department of Neurology (O.M.), Northwestern Memorial Hospital, Children's Memorial Hospital (C.D.), and Northwestern University Medical School (E.J.R., K.G., J.O.), Chicago, Ill.

Address reprint requests to Eric J. Russell, MD, Department of Radiology, Northwestern Memorial Hospital, 710 N Fairbanks Ct, Olson Pavilion/Suite 3420, Chicago, IL 60611.

AJNR 15:258–262, Feb 1994 0195-6108/94/1502-0258 © American Society of Neuroradiology

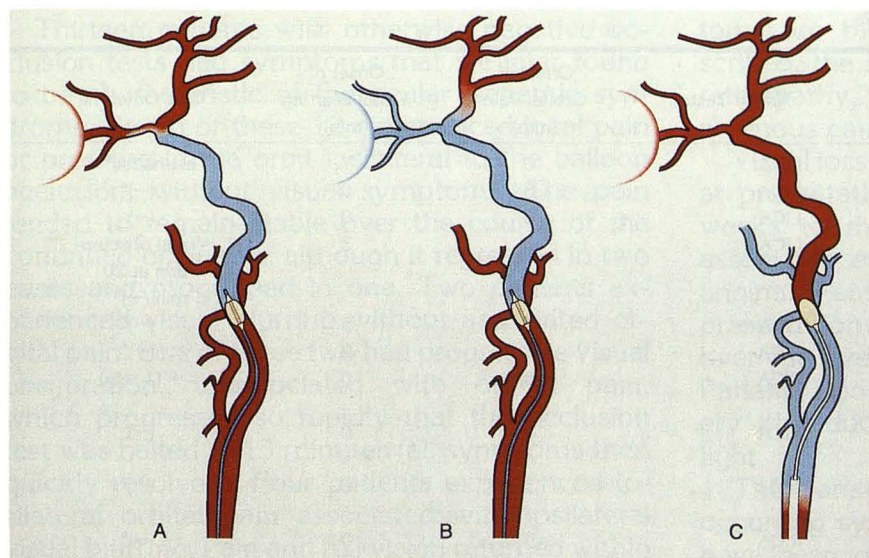


Fig. 1. A, Slow saline flush through double lumen balloon catheter permits retrograde flow of blood to perfuse the ophthalmic artery.

B, Rapid saline flush replaces blood in the ophthalmic artery, causing ocular ischemic syndrome.

C, Single lumen obstructing balloon permits retrograde flow of blood.

procedural clinical findings, and outcomes are summarized in Tables 1 and 2.

Standard Procedure

Complete history was obtained and physical examination performed before balloon occlusion testing. Informed consent was obtained. The femoral artery was punctured, and a 6.5-F femoral introducer sheath was placed to facilitate catheter exchange. Angiography was performed to assess collateral flow, using a standard 4-F or 5-F H1-type angiographic catheter. Cross-compression testing of the circle of Willis was typically performed during the angiographic workup.

Five thousand to 7000 U of heparin was typically administered intravenously to produce prolongation of the activated clotting time to roughly two and one-half times normal. With the catheter in the artery to be tested, an exchange guide wire was placed. A 5-F double-lumen occlusive balloon catheter (Meditech, Watertown, Mass, OB5-2-100) was then exchanged for the angiographic catheter. The tip of the balloon catheter was most commonly placed in the midcervical internal carotid artery (at the C2 level).

With the patient awake and under continuous electroencephalographic monitoring, the balloon was slowly inflated with a volume predetermined to be adequate to obstruct the internal carotid lumen. To confirm complete obstruction, a small test dose of contrast was injected through the distal catheter lumen. Complete contrast stasis within the carotid artery was typically seen. In most cases, a bolus of heparinized saline was administered through the distal lumen to clear contrast beyond the obstructing balloon. Once complete obstruction was confirmed, the distal catheter lumen was continuously flushed with heparinized saline solution by direct connection to a saline pressure pack (maintained above arterial pressure). Infusion rates varied between 1 and 10 cc/min. During the ensuing 20 to

30 minutes, continuous clinical testing and electroencephalographic monitoring were performed with a neurologist in attendance. Any change in baseline clinical status was recorded.

At the termination of the test, the balloon was rapidly deflated, restoring flow within the distal internal carotid artery. Neurologic testing was repeated. The catheter was then fully withdrawn. A repeat activated clotting time measurement was taken to assess the need for reversal of heparinization. Once activated clotting time returned to baseline, the femoral sheath was removed and the groin compressed. There were no neurologic complications in any case.

Provocative Test

Toward the end of the time during which our appreciation of the clinical syndrome was evolving, an additional maneuver was performed in four cases: adjustment of the rate of infusion of heparinized saline through the distal lumen of the obstructing balloon catheter during the period of occlusion. This was accomplished by adjusting the rate of flow of saline from the pressure pack by partial clamping and unclamping of the connecting tube leading to the catheter hub. The *in vivo* rate of saline infusion was estimated by *in vitro* measurement of flow rate through the same catheter system. A slow infusion correlated with a flow rate of 1 cc/min, and a rapid infusion correlated with a flow rate of 10 cc/min. Changes in patient clinical status were carefully recorded during this provocative test.

Results

Of the 30 patients included in this review (Table 2), four experienced an immediate decrease in level of consciousness and contralateral hemiparesis within 30 seconds after balloon inflation.

TABLE 1: Patient data (n = 30)

Age/Sex	Indication	Artery Tested	Onset of Orbital Pain (min)	Onset of Visual Blurring (min)	Test Outcome
14/M	Angiofibroma	LICA	0	7	Test halted ^a
42/M	Skull base mets	LICA	8	0	(-) ^a
66/F	Neck metastases	LICA	0	0	(-)
36/M	Giant cell tumor	LICA	5	3	Visual obscuration at 20 min (-) ^a
43/F	Vagal schwannoma	LICA	5	5	(-) ^a
43/M	Parotid cancer	RICA	3	2	(-) ^a
45/M	Adenoma, parapharyngeal space	RICA	0	0	+ (1 min)
33/F	Chondrosarcoma temporomandibular joint	RICA	0	0	(-)
39/F	Recurrent acoustic schwannoma	RICA	3	0	(-) ^a
62/M	Carcinoma parapharyngeal space	RICA	5	0	(-) ^a
62/F	Neck metastases	LICA	5	0	(-) ^a
35/M	Schwannoma parapharyngeal space	RCCA	0	0	(-)
46/F	Neck metastases	LICA	0	0	(-)
30/F	Adenoma parapharyngeal space	LICA	0	0	Test halted TX hemianopia
69/M	Parotid adenoma	LICA	0	0	(-)
66/F	Adenocarcinoma parapharyngeal space	RICA	0	0	(-)
39/M	Nasopharyngeal carcinoma	RICA	0	3	(-) ^a
46/F	Adenoma parapharyngeal space	LICA	0	0	(-)
73/F	Larynx carcinoma	RICA	0	0	(-)
77/F	Carotid aneurysm	LICA	0	0	+ (1 min)
69/F	Carotid aneurysm	RICA	3	0	(-) ^a
50/M	Carotid aneurysm	RICA	0	0	+ (1 min)
54/M	RICA aneurysm	RICA	5	5	Test halted at 13 min (visual obscuration) ^a
59/F	Cavernous LICA aneurysm	LICA	0	0	(-)
37/F	RICA pseudoaneurysm	RICA	Transient	0	(-)
47/F	Cavernous aneurysm	LICA	0	0	(-)
67/F	Cavernous aneurysm	RICA	0	0	+ (1 min)
71/F	Pseudoaneurysm	LICA	0	0	(-)
68/M	Carcinoma parapharyngeal space	RICA	10	0	(-) ^a
72/M	Carotid blowout	LICA and LCCA	0	0	(-)

Note.—LICA indicates left internal carotid artery; RICA, right internal carotid artery; (-), neurologic tolerance of the test.

^a Twelve patients with ocular ischemic syndrome during occlusion test. Symptoms referable to ocular ischemic syndrome fully resolved within 5 minutes after balloon deflation in all 12 cases.

TABLE 2: Results (n = 30)

Positive test (intolerance)	4
No orbital symptoms	12
Orbital pain only	7
Orbital pain and visual loss	4
Visual blurring only	2
Unrelated visual disturbance	1

Note.—All symptoms and signs of ocular ischemic syndrome resolved rapidly after balloon deflation.

These patients with positive tests were excluded from consideration since a prolonged saline infusion was not performed. One patient experienced a transient hemianopia, temporally related to contrast injection within the dominant vertebral artery during functional angiography (patient 14). Of the 25 remaining patients, 12 had negative occlusion tests and experienced no signs or symptoms referable to the orbit.

Thirteen patients with otherwise negative occlusion tests had symptoms that we later found to be characteristic of the ocular ischemic syndrome. Seven of these 12 experienced local pain or pressure in the orbit ipsilateral to the balloon occlusion, without visual symptoms. The pain tended to remain stable over the course of the continued occlusion, although it regressed in two cases and progressed in one. Two patients experienced visual blurring without associated orbital pain. One of these two had progressive visual obscuration, unassociated with orbital pain, which progressed so rapidly that the occlusion test was halted at 13 minutes (all symptoms then quickly resolved). Four patients experienced ipsilateral orbital pain associated with ipsilateral visual blurring. Pain and full vision returned within 5 minutes after balloon deflation in all symptomatic patients. No patient had any permanent visual loss. In two cases subsequent permanent balloon occlusion of the carotid artery for treatment of carotid aneurysm failed to produce visual blurring or any orbital pain syndrome.

In four patients examined toward the end of the study period, intentional variations in the velocity of flow of saline through the central lumen of the obstructing balloon catheter (slow or fast flow) were produced by constricting or releasing the plastic valve on the pressure pack line. The first two of these patients had initially developed visual obscuration, which completely regressed after diminishing the saline infusion to a trickle (slow flow). Transient restoration of high saline flow once again resulted in visual obscuration in both of these cases. These symptoms again resolved with intentional reduction of the rate of infusion beyond the obstructing balloon. Similar reversible symptoms were found in one of two additional patients subjected to this trial near the end of the study period.

The Ocular Ischemic Syndrome

Kearns and Hollenhorst (4), in 1963, described the presence of orbital pain and visual loss ipsilateral to internal carotid or common carotid artery occlusion. Symptoms are related to poor flow and decreased perfusion pressure in the distribution of the ophthalmic artery beyond the obstruction. These symptoms were seen in 5% of patients with internal carotid artery occlusion. When occurring naturally (outside of the angiographic laboratory), persons under age 50 are rarely affected (mean age 65 years). Males are more affected than females (2 to 1 ratio). Sym-

toms are bilateral in 20%. When initially described, the syndrome was called "venous stasis retinopathy," a confusing term falsely intimating a venous cause (4, 5).

Visual loss is seen in more than 90% of patients at presentation. The loss may be gradual over weeks to months, or it may be abrupt. The associated orbital pain has been called "ocular angina." Pain is prominent in 40% of patients at presentation and is often described as a dull ache over the eye, which may radiate to the temple. Patients also may experience a prolonged recovery of reduced vision after exposure to bright light.

There are many objective signs of the naturally occurring syndrome (2). These likely would not have been observed in our patients because of the short duration of decreased orbital flow. These signs include rubeosis iridis, neovascular glaucoma, retinal artery narrowing, neovascularization of the optic disk and retina, cherry red spot, and spontaneous pulsations of the retinal arteries which occur at diastole when intraocular pressure exceeds pressure within the central retinal artery. Ischemic optic neuropathy also may occur, because of hypoperfusion in the posterior ciliary circulation. Laboratory studies such as fluorescein angiography may be abnormal in chronic cases. In a Mayo Clinic study, it has been determined that at least a 90% stenosis of the internal carotid artery is required to produce a marked decrease in retinal artery perfusion pressure(s). Most of the reported cases of ocular ischemic syndrome are in patients with complete carotid occlusion.

The therapy of the ocular ischemic syndrome is reversal of carotid stenosis in cases without complete occlusion. Return of vision has been documented after carotid endarterectomy.

Discussion

In retrospect, the symptoms we observed should have prompted us to investigate their cause more quickly. We initially attributed ipsilateral orbital pain and visual blurring to transient changes in orbital flow induced by carotid occlusion. Because in a number of patients these symptoms stabilized or fluctuated (and in a few cases regressed) during the occlusion test, and there were no electroencephalographic changes, we generally did not consider that these abnormalities reflected intolerance to balloon occlusion. Therefore, with two exceptions (patients 1 and

23), the test was correctly presumed to be negative when no other focal symptoms developed.

The cause of the symptoms is easily explained. The pattern of findings closely resembles a well-reported ophthalmologic entity, the ocular ischemic syndrome. Ocular ischemic syndrome may occur in patients with unilateral or bilateral carotid artery occlusion and is presumed to be caused by decreased flow (perfusion pressure) in the distribution of the ophthalmic artery. Visual loss is attributed to progressive ischemia of the retina and choroid. Orbital and frontal pain is related to ischemia of other orbital contents, especially the extraocular muscles.

In three of the four provocative test cases described above, we manipulated the velocity of flow of the flush solution within the internal carotid artery beyond the balloon occlusion and proved that ocular ischemic syndrome symptoms were flow dependent in these cases. Figure 1 illustrates flow patterns of saline and blood, which suggest the cause of ocular ischemic syndrome during double-lumen catheter balloon occlusion testing. When the pressure of inflowing saline is sufficient to fully replace the column of blood beyond the obstructing balloon, saline totally fills the ophthalmic artery. The continued inflow of saline under pressure prevents blood, which ordinarily would fill the ophthalmic system by retrograde flow in the distal internal carotid, from doing so. A reduction in the rate of infusion as accomplished by our provocative test allows admixing of saline and blood in the ophthalmic artery, thereby oxygenating the orbit and reversing ischemic symptoms. The production of symptoms may have been hastened by the injection of a bolus of saline used to dissipate the initial test dose of contrast material injected beyond the obstruction, shortly after balloon inflation.

The absence of symptoms of ocular ischemic syndrome in 11 patients may be the result of excellent collateral flow to the orbit from the external carotid artery or fortuitously slow saline perfusion. The former condition also may explain the absence of a positive response to the provocative test in one of four patients.

Although we believe that double-lumen catheter balloon occlusion testing is safe and effective, the ocular ischemic syndrome has not been reported with occlusion testing using a single-lumen obstructing balloon device. In the context of our study, this makes perfect sense, because retrograde flow of blood will continuously perfuse the ophthalmic artery when proximal flow is totally

blocked (Fig 1C). If a double-lumen balloon catheter is to be used for occlusion testing, the flow of saline through the distal lumen should be reduced to a trickle if symptoms of orbital pain and visual blurring develop. Alternatively, intermittent flushing will allow adequate perfusion of the ophthalmic arterial system.

Conclusions

The signs and symptoms of ocular ischemic syndrome may develop rapidly during balloon occlusion testing of the internal carotid artery when a double lumen balloon catheter system is used. Complete replacement of oxygenated blood with saline in the ipsilateral ophthalmic artery is the presumed mechanism (see Fig 1).

The development of orbital pain and visual blurring ipsilateral to the side of occlusion testing may not imply intolerance to occlusion, and should not be construed as evidence of a positive balloon occlusion test.

Ipsilateral orbital pain and visual loss developing during a balloon occlusion test performed in this fashion may be reversed completely by diminishing the flow rate of flush solution through the distal balloon lumen.

The ocular ischemic syndrome may or may not develop during balloon occlusion testing using a single lumen balloon device. If similar symptoms develop during such a test, there may be significant implications concerning tolerance of carotid occlusion or a procedural complication.

Our findings are supported by the previously reported theory concerning the development of ocular ischemic syndrome: decreased perfusion of the territory of the ophthalmic artery.

References

1. Bogousslavsky J, Pedrazzi PL, Borruat FX, Regli F. Isolated complete orbital infarction: a common carotid artery occlusion syndrome. *Eur Neurol* 1991;31:72-76
2. Brown GC. Anterior ischemic optic neuropathy occurring in association with carotid artery obstruction. *J Clin Neurol Ophthalmol* 1986;6:39-42
3. Kearns TP. Ophthalmology and the carotid artery. *Am J Ophthalmol* 1979;88:714-722
4. Kearns TP, Hollenhorst RW. Venous-stasis retinopathy of occlusive disease of the carotid artery. *Mayo Clin Proc* 1963;38:304-312
5. Kearns TP, Younge BR, Peipgras DG. Resolution of venous stasis retinopathy after carotid bypass surgery. *Mayo Clin Proc* 1980;55:342-346
6. Kobayashi S, Hollenhorst RW, Sundt TM Jr. Retinal arterial pressure before and after surgery for carotid artery stenosis. *Stroke* 1971;2:569-575
7. Young LHY, Appen RE. Ischemic oculopathy. A manifestation of carotid artery disease. *Arch Neurol* 1981;38:358-361