



Discover Generics

Cost-Effective CT & MRI Contrast Agents



WATCH VIDEO

AJNR

A clinical and neuropathologic study of silk suture as an embolic agent for brain arteriovenous malformations.

J P Deveikis, H J Manz, A J Luessenhop, A J Caputy, A I Kobrine, D Schellinger and N Patronas

This information is current as of June 4, 2025.

AJNR Am J Neuroradiol 1994, 15 (2) 263-271
<http://www.ajnr.org/content/15/2/263>

A Clinical and Neuropathologic Study of Silk Suture as an Embolic Agent for Brain Arteriovenous Malformations

John P. Deveikis, Herbert J. Manz, Alfred J. Luessenhop, Anthony J. Caputy, Arthur I. Kobrine, Dieter Schellinger, and Nicholas Patronas

PURPOSE: To evaluate the safety and efficacy of silk suture as an agent for preoperative embolization of cerebral arteriovenous malformations. **METHODS:** Clinical and histopathologic results were analyzed in six patients who underwent embolization of cerebral arteriovenous malformations using silk suture in combination with other agents. **RESULTS:** Three of the patients treated with silk hemorrhaged after embolization, and two of these patients died. Neuropathologic analysis of four patients showed acute perivascular inflammation, sometimes quite severe. **CONCLUSIONS:** The inflammatory response to silk may explain its effectiveness in producing vascular occlusion. However, a fulminate vasculitis theoretically can predispose to delayed hemorrhage. Other problems with silk include the pressure required to inject the agent and the inability to determine the final site of deposition of the silk. Although other embolic agents may share some of these potential difficulties, we feel that the disadvantages outweigh the advantages of silk as an embolic agent.

Index terms: Arteriovenous malformations, cerebral; Arteriovenous malformations, embolization; Interventional materials, embolic agents

AJNR Am J Neuroradiol 15:263-271, Feb 1994

Endovascular therapy of cerebral arteriovenous malformations originally developed as a means of facilitating surgical removal of these lesions (1). Preoperative embolization of brain arteriovenous malformations has shown signs of being a useful adjunct to surgery (1-6) by decreasing blood flow through the arteriovenous malformation, shrinking arterial feeders and venous drainage pathways, and thereby reducing blood loss at surgery. Silastic spheres (1), balloons (4), cyanoacrylates (2, 5, 6), microcoils (7, 8), polyvinyl alcohol particles (9-11), and thrombotic mixtures (2, 12, 13) have been used for preoperative embolization of brain arteriovenous mal-

formations. Large spheres and balloons share the limitation of producing proximal occlusions and rarely reaching the nidus of the lesion. Cyanoacrylates can selectively occlude the arteriovenous malformation nidus, but it has been claimed that the firm, polymerized material can increase the difficulty of resecting the lesion, and, similarly, vessels occluded with microcoils also can be difficult to section (8). Polyvinyl alcohol and thrombotic mixtures can be selectively injected into arteriovenous malformations using microcatheters and produce a relatively soft thrombus in the occluded vessels. However, high-flow feeders may be difficult to occlude using small particles alone. Silk suture material has a number of characteristics that make it a promising agent for endovascular embolization of cerebral arteriovenous malformations (14). The material is readily available, can easily be delivered superselectively via microcatheters, is intensely thrombogenic, allowing for occlusion of even high-flow arteriovenous malformation feeders, and is soft and easily sectioned at surgery. In order to evaluate the safety and effectiveness of silk suture as an embolic agent, the clinical and histopathologic results obtained in a group of six patients who

Received June 26, 1990; accepted pending revision October 3; revision received February 16, 1993.

Presented as a poster at the 28th Annual Meeting of the American Society of Neuroradiology, March 19-23, 1990, Los Angeles, Calif.

From the Departments of Radiology (Neuroradiology) (J.P.D., D.S., N.P.), Pathology (Neuropathology) (H.J.M.), and Surgery (Neurosurgery) (A.J.L., A.J.C., A.I.K.), Georgetown University Hospital, Washington, DC.

Address reprint requests to John P. Deveikis, MD, University of Michigan Hospitals, Radiology Department/B1D530, 1500 East Medical Center Drive, Ann Arbor, MI 48109-0030.

AJNR 15:263-271, Feb 1994 0195-6108/94/1502-0263

© American Society of Neuroradiology

TABLE 1: Histopathology and clinical outcome, silk embolization

Case	Agents Used	Days after Initial Embolization	Thrombus	Intra-vascular PMNs	Extra-vascular Inflammation	Vessel Wall Necrosis	Outcome
1	Silk AV/ETH/PVA Spheres	1	Acute	+	0	++	Surgical excision, did well
2	Silk/AV/ETH/PVA	7	NA	NA	NA	NA	ICH, died, autopsy refused
3	Silk Spheres	7	NA	NA	NA	NA	ICH, disabled, surgery refused
4	Silk/PVA	2	Acute	+	++	0	Surgical excision, mild postoperative residual deficit
5	Silk/AV/ETH PVA	2	0	+	+	0	ICH, died 10 days later
		(Surgical path) 14	Acute	++	++	0	
6	Silk/PVA	(autopsy) 5	Acute and chronic	++	+++	0	Surgical excision did well

Note: AV indicates microfibrillary collagen; ETH, ethyl alcohol; PVA, polyvinyl alcohol microparticles; Spheres, silicone rubber spheres; NA, not available; +, mild; ++, moderate; +++, severe; and ICH, intracerebral hemorrhage.

underwent arteriovenous malformation embolizations using silk along with other agents were analyzed.

Materials and Methods

Six patients 23 to 60 years of age underwent transvascular embolization using silk suture. Five were men and one was a woman. Three of the arteriovenous malformations were left parietal, one left temporoparietal, one right occipital, and one right cerebellar in location.

The technique used to deliver the silk emboli was transfemoral catheterization with 6F or 7F introducing catheters, with placement of 2.3F Tracker-18 catheters (Target Therapeutics, San Jose, Calif) coaxially into the desired feeding artery. Superselective digital subtraction angiography and superselective sodium amytal testing were performed before embolization. Five- to 15-mm lengths of 5-0 silk (Ethicon, Somerville, NJ) were injected with boluses of contrast (Omnipaque, Winthrop Laboratories, New York, NY), until some slowing of flow was appreciated. Additional injections of a thrombotic mixture (2, 3) of microfibrillary collagen (Avitene, Medical Chemical Products, Woburn, Mass), polyvinyl alcohol (Pacific Medical, La Mesa, Calif), and 30% ethyl alcohol in nonionic contrast were used in three cases, and polyvinyl alcohol alone in two cases to achieve stasis of flow in the feeders. Flow-directed barium-impregnated silicone rubber spheres were used along with silk in two cases.

All of these patients' medical records were reviewed. Histopathology of the embolized arteriovenous malformations was available from surgical specimens in four patients and autopsy results in one of these patients. All slides were retrospectively studied to look for signs of thrombus, intra-vascular polymorphonuclear infiltration, perivascular inflammation, or vessel wall necrosis.

Results

As long as segments of 4-0 or 5-0 silk were less than 15 mm in length, they could be injected easily without occluding the microcatheter lumen, although a higher pressure was required to expel the suture from the catheter, compared with the pressure required to inject suspensions of polyvinyl alcohol particles or thrombotic mixtures. The silk was usually quite effective in producing noticeable decreases in arteriovenous malformation flow when used in conjunction with other embolic agents. Even though the suture material was injected using boluses of contrast, once the contrast washed through arteriovenous malformation the suture itself was virtually invisible and the actual site of deposition was impossible to determine.

Clinical findings in the six patients embolized with silk are summarized in Table 1. Of the six patients, three suffered an intracerebral hemorrhage between 2 and 7 days after the initial silk embolization, and two of these patients died. One patient (case 2) bled during the second stage of a two-session procedure, 1 week after the first silk embolization. Another patient (case 3) suffered a hemorrhage at home, 1 week after embolization. One patient (case 5) bled 1 hour after the second of two embolizations. The first stage was accomplished 2 days earlier. Of the three arteriovenous malformations that did bleed, only one had ever bled before (case 5), and that was only a minor hemorrhage with no residual deficit. One patient (case 6) experienced headache, fever, and diaphoresis after embolization. Although she

eventually did well, bleeding was surprisingly brisk at the time of surgery. The fever never returned after excision of the embolized arteriovenous malformation.

Table 1 also shows the available histologic findings in these patients. Surgery and/or autopsy was refused in two patients (cases 2 and 3) who bled after embolization, so no histology is available in these cases. Silk fibers scattered throughout the arteriovenous malformation could be easily demonstrated histologically. The other embolic agents used were less consistently seen. Intravascular accumulations of inflammatory cells and perivascular inflammation were seen frequently, and these changes were quite pronounced in some cases. Prominent vessel wall necrosis was seen in one case (case 1).

Selected Case Reports

Case 1

A 44-year-old man with a 15-year history of seizures was diagnosed as having an arteriovenous malformation located in the left sylvian fissure (Fig 1A). The patient had a 2-week episode of transient aphasia one year before admission,

but no documented hemorrhage; he was neurologically intact on admission. For preoperative embolization of middle cerebral feeders (Fig 1B), a total of 4 cm of 4-0 silk and 10 ml of the thrombotic mixture of collagen, polyvinyl alcohol, and ethyl alcohol were injected, with no appreciable change in flow. Therefore, flow-directed silicone spheres were used, resulting in a moderate decrease in the flow through the arteriovenous malformation (Fig 1C). Surgery the following day was uneventful. The histopathology of the surgical specimen is described in Table 1. Postoperative angiography 9 days later revealed no residual arteriovenous malformation (Fig 1D). The patient remained well and was discharged with no neurologic deficits.

Case 3

A 60-year-old man had seizures since age 27. Aside from slowly progressive memory difficulties, he was neurologically intact and had no history of intracranial hemorrhage. His seizures became difficult to control, and work-up showed a large arteriovenous malformation in the left sylvian fissure (Fig 2A). In an attempt to arrest

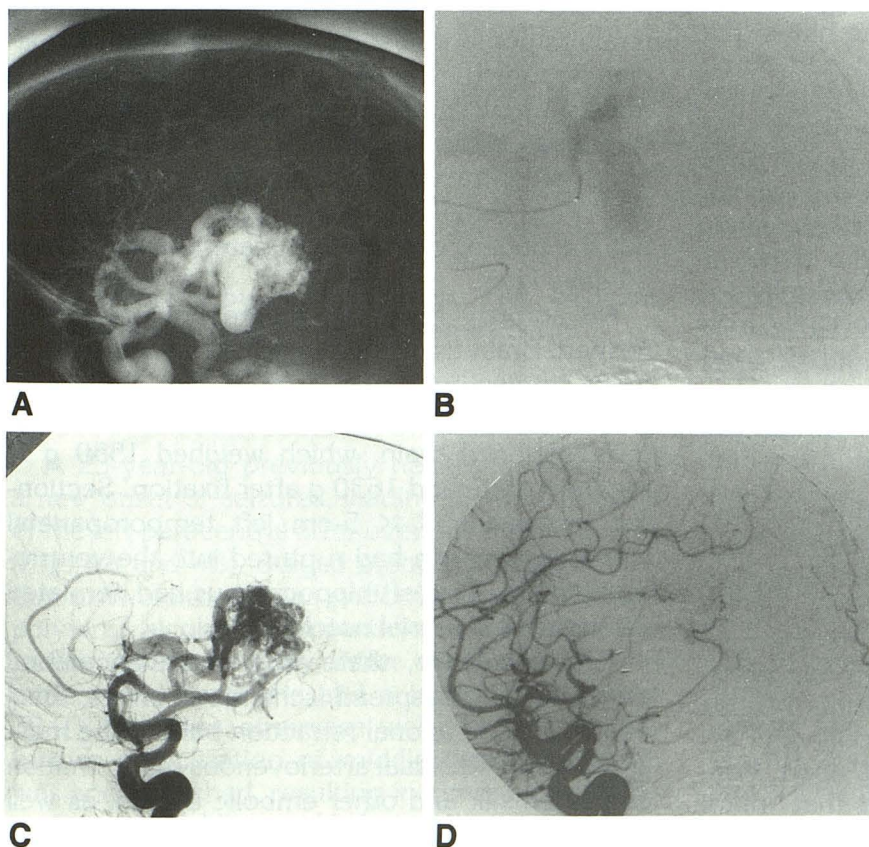


Fig. 1. Case 1.

A, Lateral angiogram shows dominant-hemisphere arteriovenous malformation.

B, Superselective lateral angiogram through a microcatheter in a middle cerebral artery feeder.

C, Postembolization lateral angiogram shows slowing of the flow through the arteriovenous malformation.

D, Postoperative lateral angiogram shows no further arteriovenous shunting.

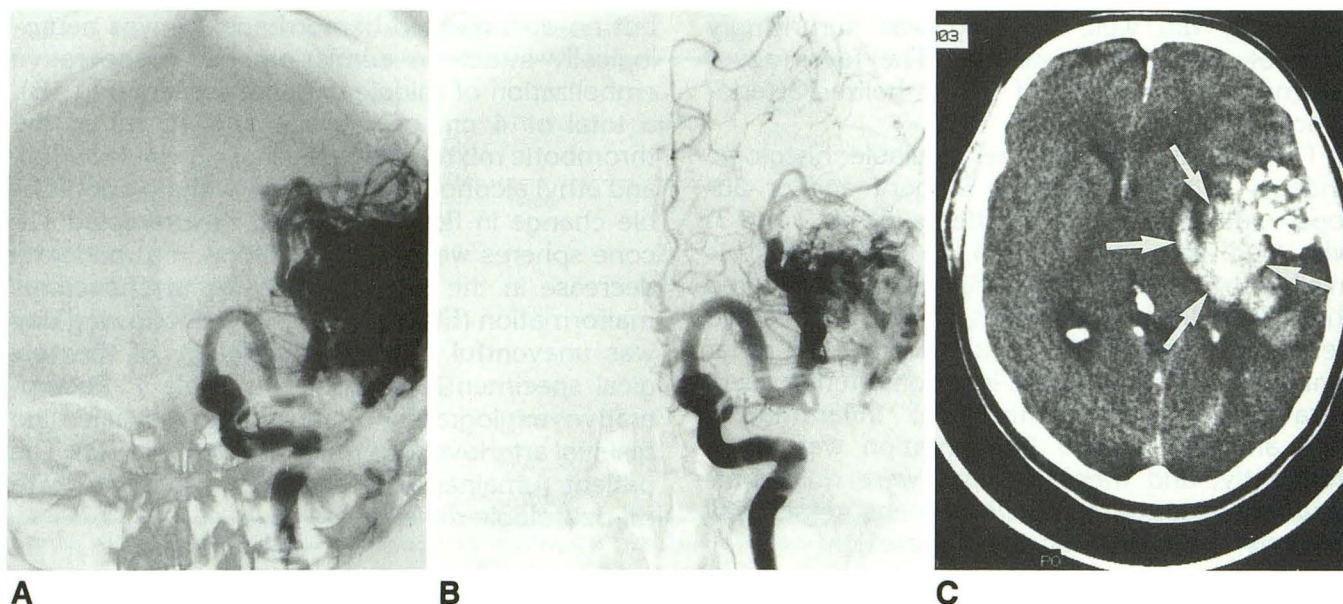


Fig. 2. Case 3.

A, Preembolization anteroposterior angiogram demonstrates a large left temporal arteriovenous malformation.

B, Postembolization anteroposterior angiogram now shows decreased flow through the arteriovenous malformation.

C, Noncontrast CT performed 7 days after embolization shows a large intracerebral hemorrhage (arrows).

the progression of the seizures, and possibly render it more surgically accessible, embolization of the arteriovenous malformation with silk and silicone spheres was performed, resulting in a noticeable decrease in flow through the nidus (Fig 2B). After embolization, the patient had some worsening of short-term memory, but this improved. He had headaches during the week after the procedure but remained afebrile. Seven days after embolization, his headache became worse, and that night, his wife found him unresponsive. Computed tomography (CT) showed a large intracerebral hemorrhage (Fig 2C). The family refused surgery. He was treated supportively with some recovery, but continued to be aphasic and hemiplegic.

Case 5

A 49-year-old man was transferred to our hospital after suffering an intracerebral hemorrhage from a left parietal arteriovenous malformation (Figs 3A–3C). He had no deficits after recovering from the small hemorrhage. Staged preoperative embolization was performed, with embolization of several middle cerebral feeders using 5-0 silk followed by the collagen–ethanol–polyvinyl alcohol mixture at two sittings, 2 days apart. Postembolization angiography showed that much of the middle cerebral supply to the arteriovenous malformation had been obliterated, with much

more obvious collateral supply from additional anterior and posterior cerebral artery sources (Fig 3D) and with redistribution of venous drainage (Fig 3E). The patient was well after the first embolization and also had no complaints immediately after the second procedure, but approximately 1 hour after the procedure, he complained of nausea, and rapidly lapsed into coma, with a large left intracerebral hemorrhage on CT (Fig 3F). The hematoma was surgically evacuated, but the patient continued to deteriorate and died 10 days later.

An autopsy restricted to the brain was performed. Brain tissue herniated through a left posterior craniectomy 10 × 7 cm in size. Subarachnoid hemorrhage was evident over the edematous, softened brain, which weighed 1550 g in the fresh state and 1630 g after fixation. Sectioning revealed a 7 × 5-cm left temporoparietal hematoma, which had ruptured into the ventricular system. The left hippocampus had herniated through the tentorial notch.

Microscopically, there was massive cerebral edema with widespread ischemic changes, focal infarction, and axonal retraction balls in the mesencephalon. Residual arteriovenous malformation contained silk and other embolic agents, as well as leukocyte accumulations. Extravascular inflammatory cells were seen, with demolition of

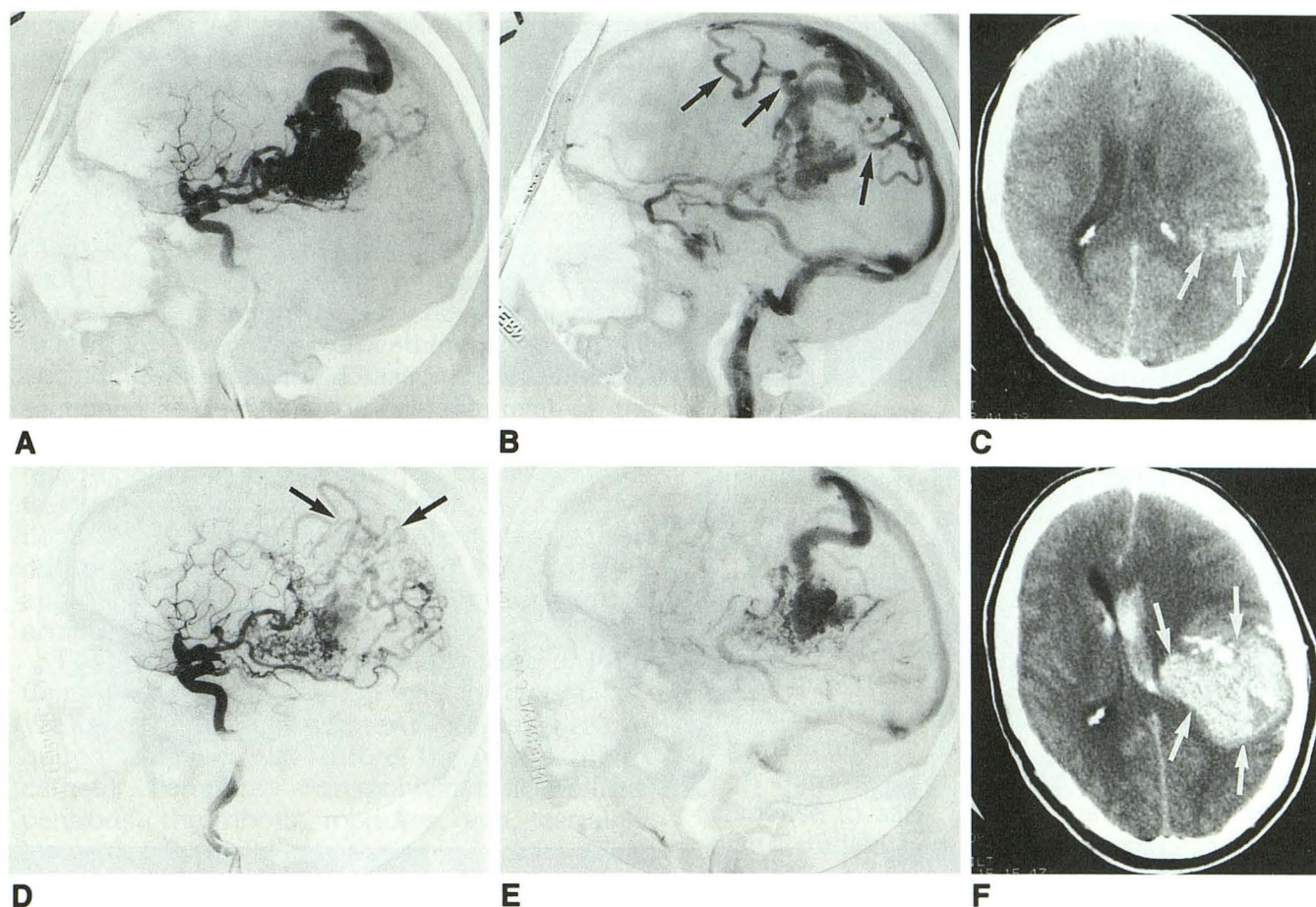


Fig. 3. Case 5.

A and B, Preembolization left carotid angiogram. Early arterial phase (A) shows left temporoparietal arteriovenous malformation. Later phase (B) shows cortical venous drainage (arrows).

C, Noncontrast CT shows the hyperdense arteriovenous malformation (arrows).

D and E, Lateral control angiogram. Early arterial phase (D) shows continued filling of nidus from small residual feeders and anterior cerebral artery collaterals (arrows). Late arterial phase (E) shows reduced cortical venous drainage compared with B.

F, When the patient deteriorated 1 hour after embolization, CT shows large intracerebral bleed (arrows).

necrotic brain by macrophages. The adjacent cerebral tissue also contained hemosiderin.

Case 6

A 23-year-old previously healthy woman had a new onset of seizures, leading to the diagnosis of the left paracentral arteriovenous malformation (Figs 4A and 4B). Staged preoperative embolization at two sittings was performed using silk and polyvinyl alcohol microparticles to obliterate the middle cerebral supply. After the first stage, the patient had headache and a low-grade fever of 38.9°C but was otherwise well. Two days later further embolization of middle cerebral feeders was accomplished, resulting in almost total obliteration of middle cerebral supply. The anterior cerebral collateral supply was now well shown on

the postembolization arteriogram (Figs 4C and 4D). After embolization, she had further headache, low-grade fever, and diaphoresis, with no source of infection identified. Surgery was performed on the third day after the last embolization and was notable for considerable blood loss (3600 ml) during the procedure, despite the extensive embolization. The postoperative arteriogram shows complete excision of the arteriovenous malformation, with moderate amounts of vasospasm (Figs 4E and 4F). Microscopic analysis of the excised surgical specimen revealed rather striking intravascular and extravascular inflammatory cell infiltration along with the silk (Figs 4G, 4H, and 4I). After the operation, the patient had transient word-finding difficulties and right-arm paresis, although both had improved considerably by the time of her discharge from the

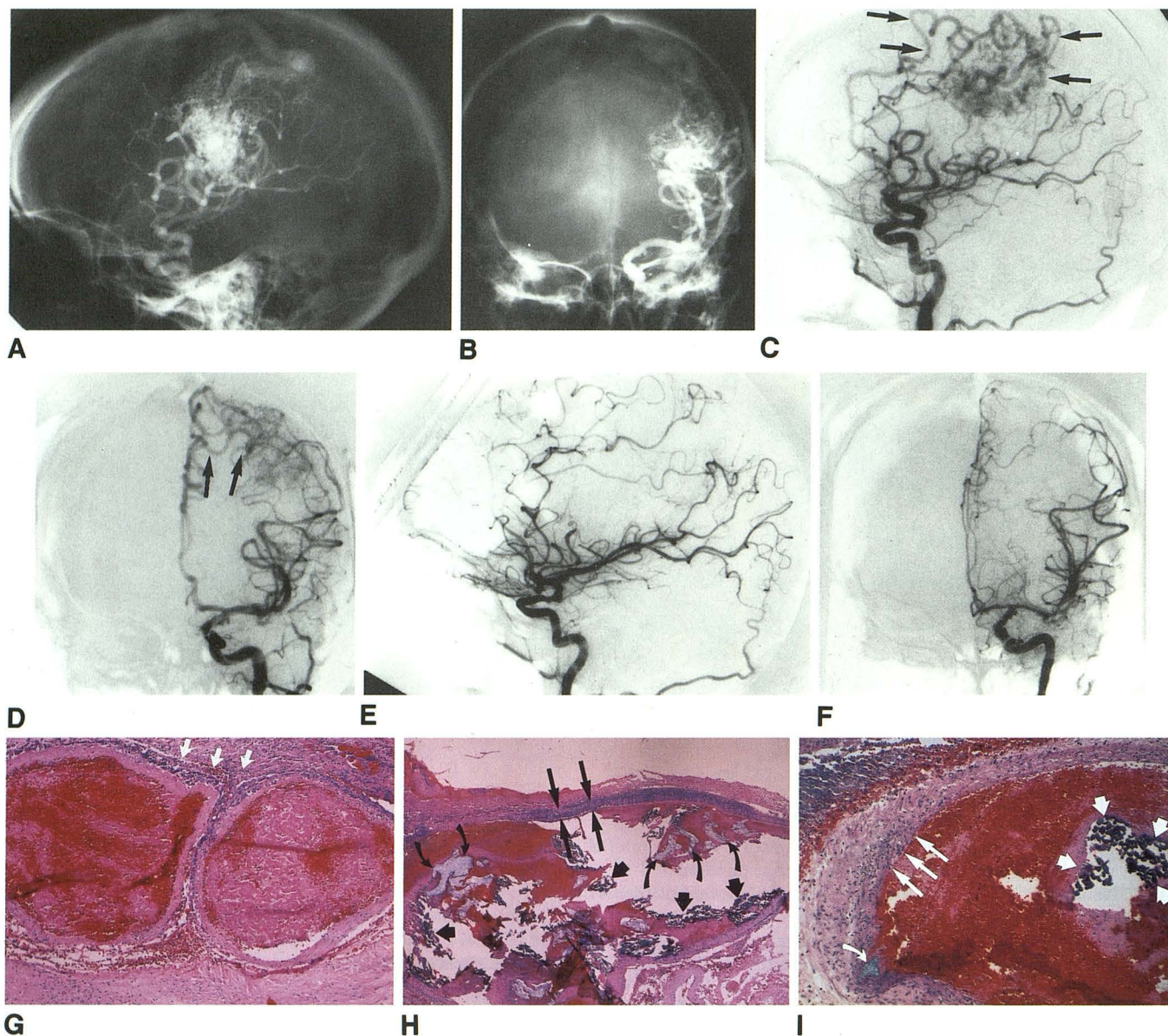


Fig. 4. Case 6.

A and B, Left carotid angiogram. Lateral (A) and anteroposterior (B) views show a paracentral arteriovenous malformation.

C and D, Control angiogram. Lateral (C) and anteroposterior (D) views after embolization show a significant decrease in middle cerebral artery supply to the arteriovenous malformation. Anterior cerebral artery contribution is now quite obvious (arrows).

E and F, Postoperative angiogram. Lateral (E) and anteroposterior (F) views demonstrate total excision of the lesion.

G-I, Arteriovenous malformation histopathology.

G, Hematoxylin and eosin section. Two contiguous vessels with thrombosed lumina, focally inflamed walls, and a necrotic, acute perivascular inflammatory process (arrows). The vessel on the left has a more recent thrombus, the one on the right, an older thrombus.

H, Hematoxylin and eosin section. Obliquely sectioned vessel containing abundant silk fibers (arrowheads), particles of polyvinyl alcohol (curved arrows), and early thrombus. The wall is entirely permeated by acute inflammatory cells (large arrows).

I, High-power hematoxylin and eosin section. Obliquely sectioned vessel containing a bundle of silk (arrowheads), a small amount of polyvinyl alcohol (curved arrow), and recent thrombus. Numerous fragmented leukocytes permeate the vessel wall (large arrows). Necrotic acute inflammatory debris is in the upper left corner in the extravascular space.

hospital. She remained afebrile throughout her postoperative course.

Discussion

The ideal embolic agent for preoperative treatment of cerebral arteriovenous malformations should be safe to use, readily available, easy to deposit selectively in the arteriovenous malformation via available microcatheters, effective in occluding the lesion, and easily manipulated and sectioned to facilitate surgical removal of the arteriovenous malformation. Silk suture has been reported to be an effective embolic agent for treatment of cerebral arteriovenous malformations (8, 14). Results of the current study raise a number of questions concerning how closely it approaches the ideal embolic agent for cerebral arteriovenous malformations.

The first issue concerns the pressure of injections used to introduce the silk intravascularly. We have found that greater pressures were required to inject silk suture through a microcatheter, compared with polyvinyl alcohol suspensions, thrombotic mixtures, and, certainly, low-viscosity cyanoacrylate preparations. Even microcoils, which largely fill the lumen of the microcatheter, can be deposited under low pressure by using the available pusher wires intended for that use. Although none of the hemorrhages in this series occurred at or immediately after the time of a silk thread injection, it is a theoretical possibility that a fairly high-pressure injection into an arteriovenous malformation feeder could predispose to vessel rupture, particularly if the catheter tip is wedged in a small vessel.

The second problem is related to the difficulty in determining the site of deposition of the suture material. Because the silk is not radioopaque, it is effectively invisible after it is deposited. In cases 5 and 6, there was evidence that the site of occlusion was primarily in the feeding arteries, rather than the arteriovenous malformation nidus, which continued to fill from alternative collateral sources after embolization. It is possible that the increased flow through these alternative pathways might overload vessels with limited autoregulation abilities and increase the probability of rupture and hemorrhage (15, 16). Moreover, signs of altered venous flow pattern, such as in case 5, may indicate that some of the embolic material was lodging on the venous side, or at least inducing thrombosis in the veins, and thus obstructing

venous outflow pathways. Venous outlet obstruction has been suggested (6, 17) to be a significant risk factor for hemorrhage of cerebral arteriovenous malformations. Although none of the preembolization superselective angiograms demonstrated a direct arteriovenous fistula, all of the embolized vessels were high-flow feeders. The histologic analysis demonstrated fibers smaller than the original 5- to 15-mm lengths injected. It is therefore possible that some fragmentation of fibers occurred during or after injection, and these small fibers could easily traverse the arteriovenous malformation nidus and deposit on the venous side. Thus, the inability to see where the silk suture lodges might cause one to continue to deposit embolic material either in the feeding artery or draining vein, and the actual site of occlusion might not be known until complete occlusion had occurred, when it was too late to prevent inadvertent occlusion of these structures. The highly radioopaque microcoils and standard preparations of cyanoacrylates would not share this difficulty.

A third issue of concern is the inflammatory response to silk. The histopathology in the patients studied here showed prominent intravascular acute inflammatory cell accumulations, as well as extravascular inflammation and even vessel wall necrosis in one case (case 1). Silk has been previously shown to produce intense inflammation when used for endovascular embolization (18). Case 6 not only showed a local inflammatory reaction histologically, but also had systemic signs of inflammation, with fever and diaphoresis. These symptoms disappeared after the silk-laden arteriovenous malformation was surgically excised.

Cyanoacrylate glue, including both the isobutyl and n-butyl forms, have been shown to produce intense acute and chronic inflammatory changes (16, 19, 20). This inflammation has been postulated as a potential contributing factor in the development of delayed postembolization hemorrhage (16, 20). However, glue has the advantage over silk that it produces occlusion by filling the vessel lumen and adhering to the wall (20). Microfibrillary collagen has been shown to produce an intense inflammatory response but also largely fills the lumen to produce mechanical occlusion (21). Silk, on the other hand, could be seen to be surrounded by the thrombus, and it was the combination of silk and thrombus that occluded the vessel. The thrombus can be ex-

posed to the fibrinolytic effects of plasmin (22), with resultant clot lysis. This could expose the inflamed, possibly weakened vessel wall to flowing blood if sufficient recanalization occurs during the acute inflammatory stage.

Reports on the histologic response to polyvinyl alcohol have been variable. Minimal inflammatory changes were seen by both White et al (23) and Quisling et al (24). On the other hand, Germano et al (9) more recently have reported a rather striking inflammatory response in patients embolized with polyvinyl alcohol particles, suggesting that this agent is not as biologically inert as has been previously assumed. Five of our six patients embolized with silk also had polyvinyl alcohol injected, and therefore, some of the inflammatory changes might be related, at least in part, to agents other than silk. The one patient who did not have polyvinyl alcohol used with the silk had a disabling intracerebral hemorrhage 1 week after the embolization. This might suggest that either the silk itself produced sufficient inflammatory changes to disrupt the vessel walls, or that other factors were causative.

The question of what, exactly, caused the hemorrhages in these patients remains unanswered. The causes could be unrelated to the embolization, such as the intrinsic tendency of arteriovenous malformations to bleed (1, 3, 25). Rupture of feeding arteries during catheter manipulation can cause bleeding (6, 26), but this is most often seen when calibrated leak balloons are used as delivery devices. Moreover, two patients hemorrhaged hours to days after the procedure, making this an unlikely explanation. The normal perfusion breakthrough syndrome has been invoked as a possible cause of swelling and hemorrhage after arteriovenous malformation occlusion (15). However, it is not at all certain that the degree of arteriovenous malformation occlusion produced by the embolization procedures would be sufficient to induce that phenomenon, and the pathophysiologic basis of the syndrome is controversial.

The current study suggests four characteristics of silk suture that, at least theoretically, might predispose to bleeding. These are: 1) the high pressure required for delivery of the emboli; 2) the possible uncontrolled deposition either in the feeding artery or, if a fistula is present or if fragmentation occurs, in the venous drainage; 3) the inflammatory response; and 4) the mechanism of vessel occlusion, in which a small silk

fiber is associated with thrombus, which can resorb and restore flow to possibly necrotic vessels. All embolic agents share one or more of these characteristics, and immediate and delayed postembolization hemorrhages are well described sequelae of any embolic agent or technique (6, 9, 10, 19, 26). In the absence of a large series comparing different embolic agents in a controlled fashion, it will be impossible to convincingly demonstrate a higher risk of one compared with another. However, none of the most common embolic agents including cyanoacrylates, polyvinyl alcohol, thrombotic mixtures, and microcoils, shares all of the above characteristics of silk that might predispose to hemorrhage.

All the above considerations suggest that silk has considerable disadvantages compared with other embolic agents. It may be possible to avoid any potential problems with inflammation if the arteriovenous malformation is excised soon after embolization, before the inflammatory process becomes far advanced, and before any possible recanalization could occur. This approach would not avoid the risks associated with high-pressure injections for delivery of the silk or the potential bleeding from venous-outlet obstruction. Moreover, this approach would not allow for any staging of the embolization procedure. The use of synthetic suture material also could help avoid the consequences of inflammation. Benati et al (27) have shown that synthetic polyene threads induced a milder degree of acute inflammatory changes after embolization, with no necrotizing vasculitis. Polyene thread still would be expected to share some of the other characteristics of silk suture, as discussed above.

On the basis of this study, and given the availability of other embolic agents, it seems that silk suture should be recommended only in lesions that are unlikely to bleed, such as extracranial or at least extradural arteriovenous malformations.

References

1. Luessenhop AJ, Rosa L. Cerebral arteriovenous malformations. Indications for and results of surgery, and the role of intravascular techniques. *J Neurosurg* 1984;60:14-22
2. Pelz DM, Fox AJ, Vinuela F, Drake CC, Ferguson GG. Preoperative embolization of brain AVMs with isobutyl-2-cyanoacrylate. *AJNR Am J Neuroradiol* 1988;9:757-764
3. Drake CG. Arteriovenous malformations of the brain. The options for management. *N Engl J Med* 1983;309:308-309
4. Halbach VV, Higashida RT, Yang P, et al. Preoperative balloon occlusion of arteriovenous malformations. *Neurosurgery* 1988;22:301-308

5. Cromwell LD, Harris AB. Treatment of cerebral arteriovenous malformations. A combined neurosurgical and neuroradiological approach. *J Neurosurg* 1980;52:705-708
6. Vinuela F, Dion JE, Duckwiler G, et al. Combined endovascular embolization and surgery in the management of cerebral arteriovenous malformations: experience with 101 cases. *J Neurosurg* 1991;75:856-864
7. Hilal SK, Khandji AG, Chi LT, Stein BM, Bello JA, Silver AJ. Synthetic fiber-coated platinum coils successfully used for the endovascular treatment of arteriovenous malformations, aneurysms and direct arteriovenous fistulas of the CNS (abstr). *AJNR Am J Neuroradiol* 1988;9:1030
8. Purdy PD, Batjer HH, Risser RC, Samson D. Arteriovenous malformations of the brain: choosing embolic materials to enhance safety and ease of excision. *J Neurosurg* 1992;77:217-222
9. Germano IM, Davis RL, Wilson CB, Hieshima GB. Histopathological follow-up study of 66 cerebral arteriovenous malformations after therapeutic embolization with polyvinyl alcohol. *J Neurosurg* 1992;76:607-614
10. Purdy PD, Samson D, Batjer HH, Risser RC. Preoperative embolization of cerebral arteriovenous malformations with polyvinyl alcohol particles: experience in 51 adults. *AJNR Am J Neuroradiol* 1990;11:501-510
11. Schumacher M, Horton JA. Treatment of cerebral arteriovenous malformations with PVA: results and analysis of complications. *Neuroradiology* 1991;33:101-105
12. Fox AJ, Lee DH, Brothers MF, Deveikis JP. Thrombotic mixture as "polymerizing agent" (abstr). *AJNR Am J Neuroradiol* 1988;9:1029
13. Dion JE, Vinuela FV, Lylyk P, Lufkin R, Bentson J. Ivalon-33% ethanol-avitene embolic mixture: clinical experience with neuroradiological endovascular therapy in 40 arteriovenous malformations (abstr). *AJNR Am J Neuroradiol* 1988;9:1029
14. Eskridge JM, Scott JA. Preoperative embolization of brain AVMs using surgical silk and polyvinyl alcohol (abstr). *AJNR Am J Neuroradiol* 1989;10:882
15. Spetzler RF, Wilson CB, Weinstein P, Mehdorn M, Townsend J, Telles D. Normal perfusion pressure breakthrough theory. *Clin Neurosurg* 1978;25:651-672
16. Vinters HV, Galis KA, Lundie MJ, Kaufmann JCE. The histotoxicity of cyanoacrylates. A selective review. *Neuroradiology* 1985;27:279-291
17. Vinuela F, Nombela L, Roach MR, Fox AJ, Pelz DM. Stenotic and occlusive disease of the venous drainage system of deep brain AVMs. *J Neurosurg* 1985;63:180-184
18. Barth KH, Strandberg JD, Kaufman SL, White RI. Chronic vascular reactions to steel coil occlusion devices. *AJR Am J Roentgenol* 1978;131:455-458
19. Vinters HV, Lundie MJ, Kaufmann JCE. Long-term pathological follow-up of cerebral arteriovenous malformations treated by embolization with bucrylate. *N Engl J Med* 1986;314:477-483
20. Brothers MF, Kaufmann JCE, Fox AJ, Deveikis JP. n-Butyl 2-cyanoacrylate—substitute for IBCA in interventional neuroradiology: histopathologic and polymerization time studies. *AJNR Am J Neuroradiol* 1989;10:777-786
21. Lee DH, Wriedt CH, Kaufmann JCE, Pelz DM, Fox AJ, Vinuela F. Evaluation of three embolic agents in pig rete. *AJNR Am J Neuroradiol* 1989;10:773-776
22. Robbins KC. The plasminogen-plasmin enzyme system. In: Colman RW, Hirsh J, Marder VJ, Salzman EW, eds. *Hemostasis and thrombosis: basic principles and clinical practice*. Philadelphia: Lippincott, 1982:623-639
23. White RI, Strandberg JV, Gross GS, Barth KH. Therapeutic embolization with long-term occluding agents and their effects on embolized tissues. *Radiology* 1977;125:677-687
24. Quisling RG, Mickle JP, Ballinger WB, Carrer CC, Kaplan B. Histopathologic analysis of intraarterial polyvinyl alcohol microemboli in rat cerebral cortex. *AJNR Am J Neuroradiol* 1984;5:101-104
25. Troupp H, Martila I, Halonen V. Arteriovenous malformations of the brain. Prognosis without operation. *Acta Neurochir* 1970;22:125-128
26. Debrun G, Vinuela F, Fox A, Drake CG. Embolization of cerebral arteriovenous malformations with bucrylate. Experience in 46 cases. *J Neurosurg* 1982;56:615-627
27. Benati A, Beltramello A, Colombari R, et al. Preoperative embolization of arteriovenous malformations with polyene threads: techniques with wing microcatheter and pathologic results. *AJNR Am J Neuroradiol* 1989;10:579-586