



Discover Generics

Cost-Effective CT & MRI Contrast Agents



FRESENIUS
KABI

WATCH VIDEO

AJNR

A method for sonographic counting of the lower vertebral bodies in newborns and infants.

F J Beek, M S van Leeuwen, N M Bax, E H Dillon, T D Witkamp
and A P van Gils

AJNR Am J Neuroradiol 1994, 15 (3) 445-449

<http://www.ajnr.org/content/15/3/445>

This information is current as
of June 4, 2025.

A Method for Sonographic Counting of the Lower Vertebral Bodies in Newborns and Infants

Frederik J. A. Beek, Maarten S. van Leeuwen, Nikolaas M. A. Bax, Evan H. Dillon, Theo D. Witkamp, and Ad P. G. van Gils

PURPOSE: To determine whether the lumbosacral junction of the vertebral column can be identified with sonography in newborns and infants and thus serve as a method for counting the lumbar and sacral vertebral bodies. **METHODS:** In 32 newborns and infants, the number of ossified vertebral bodies distal to the lumbosacral junction was counted with sonography and radiography. **RESULTS:** Sonographic and radiographic findings agreed in 29 of 32 examinations (91%). **CONCLUSIONS:** The lordotic transition at the lumbosacral junction can be identified with sonography in the majority of newborns and infants, allowing intraspinal structures to be related to a specific vertebral level.

Index terms: Spine, anatomy; Spine, ultrasound; Spine, vertebrae; Infants; Infants, newborn

AJNR Am J Neuroradiol 15:445-449, Mar 1994

Cartilage is hypoechoic and transsonic on sonography. Because the vertebral arch is mostly cartilaginous in newborns and infants, there is an acoustic window for sonographic examination of the contents of the spinal canal, and abnormalities can be detected (1-5). An important finding is a position of the conus medullaris at or below the level of the third lumbar vertebra, as this low position can be associated with a tethered cord syndrome (6, 7). However, it is difficult to correlate intraspinal structures to a specific vertebral level because anatomic landmarks are not easily discerned. It is possible to mark the skin with a lead marker at the level of the conus medullaris or at the site of pathologic structures and obtain a plain film. Placement and fixation of a mark can be troublesome in newborns and infants. A sonographic method for counting the vertebral bodies would be superior to marking, and has the

additional advantage of avoiding the acquisition of plain films after marking (8, 9).

The purpose of this study was to assess whether the lumbosacral junction (LSJ) of the vertebral column could be identified as a distinct entity with sonography. If this were possible, the LSJ could serve as a landmark for sonographic counting of the lumbosacral vertebral bodies, which would determine the position of intraspinal structures.

Materials and Methods

The aim of the study was to identify the LSJ with sonography and to count the number of ossified vertebral bodies distal to it. The results were compared with a radiographic count of ossified vertebral bodies distal to the LSJ.

Thirty-two children entered into the study from December 1991 until August 1992. The age at examination varied from 0 to 249 days, with a mean age of 69 days and a median age of 23 days. One child was premature, of 35 weeks postconceptual age. Eight children had an anorectal malformation, 7 had urologic abnormalities, 6 had upper gastrointestinal tract disorders, 3 had a metabolic disorder, and 3 were suspected of having hip dysplasia. The remaining 5 children had miscellaneous diseases. All children were referred for sonography and either plain films of

Received January 12, 1993; accepted pending revision March 1; revision received April 13.

From the Departments of Radiology (F.J.A.B.) and Surgery (N.M.A.B.), University Childrens Hospital; and the Department of Radiology (F.J.A.B., M.S.V.B., H.D., T.D.W., A.P.G.V.G.), University Hospital Utrecht, Utrecht, The Netherlands.

Address reprint requests to F. J. A. Beek, MD, Department of Radiology, University Hospital Utrecht, Heidelberglaan 100, 3584 CX, Utrecht, The Netherlands.

AJNR 15:445-449, Mar 1994 0195-6108/94/1503-0445

© American Society of Neuroradiology

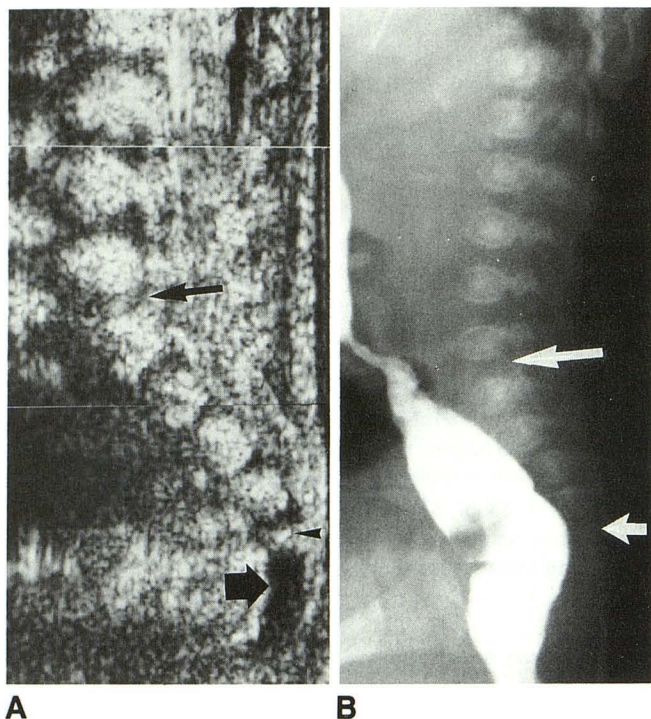


Fig. 1. (A) Composition sonogram of the lower spine. The LSJ is shown as a lordotic transition (*long arrow*) between the lumbar and sacral vertebrae. The fifth sacral body ossification center is visible (*arrowhead*). The coccyx is composed of hypoechoic cartilage (*short arrow*).

(B) The LSJ (*long arrow*) is seen in the same patient on a lateral film of a barium enema. The fifth sacral vertebral body ossification center is just visible (*short arrow*).

the vertebral column or voiding cystourethrography or colon enema.

Sonography of the lower spine was done via a dorsal approach with the patient in a lateral decubitus position. Sagittal images using a 5 MHz linear array probe (Advanced Technology Laboratories, Bothel, WA) were obtained. The LSJ was identified as the point of lordotic transition from the relatively straight line of the dorsal side of the lumbar vertebrae to the gentle kyphosis of the sacral vertebrae (Fig 1). If the LSJ was not obvious on sonography, the distal spine was flexed and extended gently or the child was placed in a prone position. Because the sacral vertebrae move as a block with movement taking place at the LSJ, the LSJ can be identified. The vertebra proximal to the LSJ was labeled the fifth lumbar vertebra (L-5) and the vertebra distal to the LSJ was labeled the first sacral vertebra (S-1). The ossified vertebral bodies distal to the LSJ were counted and the most distal vertebral body was annotated on film. For example, if 4 ossified vertebral bodies were present below the LSJ, the

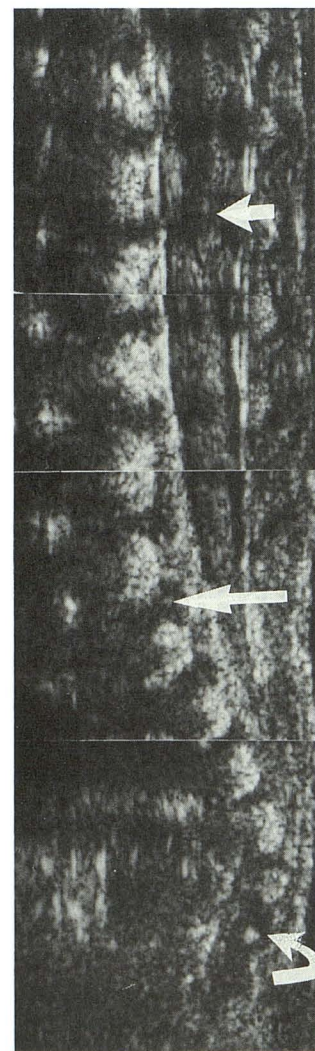
lowest was named S-4; if 7 were present, the lowest was named C-2. The radiographs were reviewed by two radiologists (T.W., A.G.). They agreed independently on the number of ossified vertebral bodies distal to the LSJ in 24 studies. In the remaining 8 cases, consensus was reached.

TABLE 1: Comparison of the number of ossified vertebral bodies distal to the LSJ, counted with radiography and sonography

	Radiography			
	S-4	S-5	C-1	C-2
Sonography				
S-4	1			
S-5	1	13	2	
C-1			12	
C-2				4

Note.—S-4 is the fourth sacral vertebral body, four vertebral bodies present; S-5, fifth sacral vertebral body; C-1, first coccygeal vertebral body; and C-2, second coccygeal vertebral body.

Fig. 2. Composition sonogram of the lower spine. The lumbar vertebral bodies form an almost straight line. The lordotic transition is gentle and the LSJ (*long arrow*) could be overlooked if a probe with a small field of view is used. The tip of the conus medullaris (*short arrow*) is visible at the interspace between the first and second lumbar vertebral body. The first ossification center of the coccyx is seen (*curved arrow*).



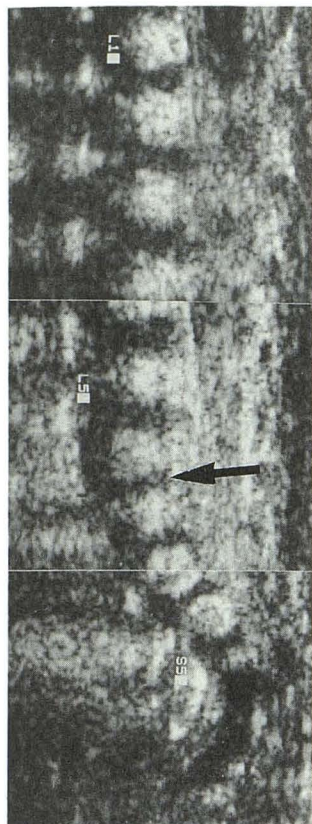


Fig. 3. Miscalculation in an early study of a patient with four ossified sacral vertebral bodies. Although the LSJ is well seen (arrow), it was not recognized, probably because of the expectation that five ossified sacral vertebral bodies should be present. The most caudal ossification center, believed to be the fifth sacral vertebral body (S-5), is actually the fourth. Counting upward, the fourth lumbar vertebral body is erroneously labeled L-5 and the twelfth thoracic vertebral body is erroneously labeled L-1. Four sacral ossified vertebral bodies were seen on a lateral plain film of the vertebral column.

All sonographic examinations of the spinal column were done after parental consent. The study was approved by the hospital ethics committee.

Results

The results of the radiographic and sonographic count are shown in Table 1. Sonographic and radiographic findings agreed in 29 of 32 examinations (91%). The results were discordant in 3 patients: in one patient radiography showed 4 elements and sonography 5; in 2 patients radiography showed 6 elements and sonography 5. Flexion and extension of the spine or changing of the position of the child from lateral decubitus to prone improved the visibility of the LSJ in 5 children.

Discussion

In some articles on sonography of the spinal canal, no mention is made of a method of counting the vertebrae (1, 5, 10). Others refer to palpation of surface landmarks. The end of the lower ribs is said to indicate the level of L-2 (11) and the supracristal line, connecting the top of the palpated iliac crests, is supposed to transect the

L3–4 level (7). In newborns and infants, palpation of these landmarks is not easy to do.

A sonographic landmark would be more convenient. The termination of the dural sac at S-2 is mentioned as such a landmark (12), but this termination can be difficult to discern because the most distal, echogenic spinal roots are not always surrounded by cerebrospinal fluid and can merge gradually with echogenic tissue in the distal sacral canal. Naidich et al (13) advises comparing a lateral radiograph to a sonogram and looking for a prominent anatomical fixed feature.

The LSJ is such a fixed feature and is often well seen on sonography and radiography (Fig 1). The lordosis of the lumbar vertebral bodies develops mostly when the child starts walking (14, 15). Therefore, the dorsal surfaces of the lumbar vertebrae form a rather straight line on sonography in newborns and infants, both in a prone or lateral decubitus position. The sacral vertebral bodies form a kyphosis, which is present from

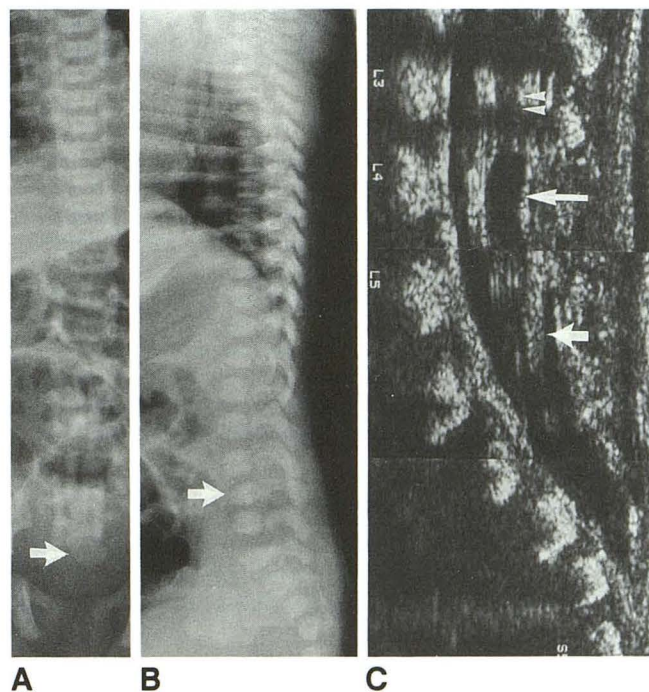


Fig. 4. Newborn boy with multiple congenital abnormalities. A frontal radiograph of the spine (A) demonstrates an abnormally large and asymmetric fifth sacral vertebral body (arrow). The lower lumbar vertebral bodies are obscured by an umbilical cord clamp. A lateral plain film (B) shows a kyphosis at L-4 (arrow). Sonography of the spine (C) shows a low conus medullaris (double arrow) at L3–4 with a sonolucent collection at the tip, representing a cerebrospinal fluid cyst (long arrow) and a thickened filum terminale (short arrow) in a dural sac, which ends at S3–4. The final diagnosis was trisomy 13. The child died of muscle weakness and apnea.

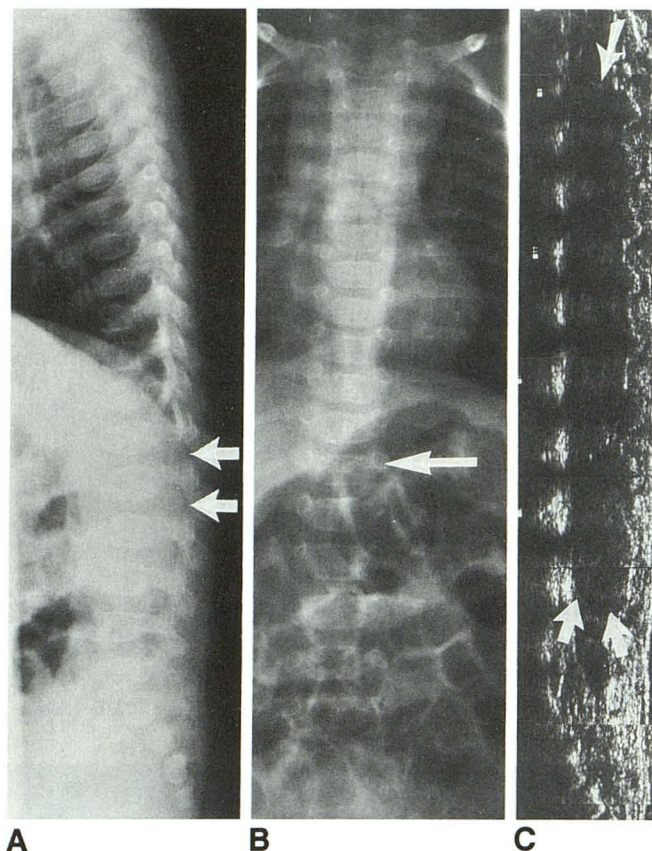


Fig. 5. Four-month-old boy with a 2-month history of micturition disturbances who was admitted for further investigation. A few hours after admission, he developed a paraplegia. A lateral spinal radiograph (A) shows some discrete scalloping of the dorsal surface of the lower thoracic and upper lumbar vertebral bodies with widening of the intervertebral foramina of L1-2 and L2-3 (arrows). Increased interpedicular distance of T-12 is seen on a frontal film (arrow, B). Sonography (C) demonstrated an intraspinal tumour extending from the eighth thoracic vertebral body (arrow) to the fourth lumbar vertebral body (arrows). He was referred to another hospital for further imaging and operation. The final diagnosis was a poorly differentiated Ewing sarcoma.

fetal life and thereafter (14). At the LSJ, a angular lordotic transition of the spinal column can be seen sonographically in most patients. In this study, the LSJ was correctly identified in 91% of the patients.

The described method for the sonographic identification of the LSJ has some limitations. Experience is needed to discern the LSJ, especially with the limited field of view of the linear array transducer, which was used in this study. A transducer with a longer field of view, combined with a split-screen, dual-image feature could improve the visibility of the LSJ, which is often obvious on composition sonograms (Fig 2).

In patients with congenital vertebral abnormalities, sonography can be confusing. Because plain films will be available in these patients, a sono-

graphic count of the ossified vertebral bodies can be related to a radiographic count and the position of intraspinal structures can be determined.

The study is limited by the use of radiography as a standard of reference. On radiography, it can be difficult to appreciate tiny ossification centers. The expected number of ossified vertebral bodies distal to the LSJ in newborns and infants is five or six (14). A tiny ossification center in a seventh vertebral body tends to be overlooked on radiography. This happened in some of the patients, for whom consensus had to be reached on the radiographic films. The LSJ was well seen in most of these cases, but the number of ossified vertebral bodies distal to the LSJ was used as comparison between radiography and sonography in the study. The sonographic counting was also influenced by this expected number in the beginning of the study. This can be seen in one of the first examinations of a child with four ossified sacral vertebral bodies. Although the LSJ is evident in retrospect, five ossification centers were counted (Fig 3). In two other patients, the LSJ was not well seen, leading to a miscalculation. This means that the described method can be applied only in patients in whom the LSJ is well seen.

The described method of sonographic counting can be helpful in locating possible intraspinal abnormalities in newborns and infants, especially if access to magnetic resonance imaging equipment is limited. The results can be used to direct therapeutic measures or diagnostic workup. Finding intraspinal abnormalities can be an additional argument to refrain from treatment in children with multiple congenital abnormalities (Fig 4). The method can be helpful as a screening examination to direct additional examinations (Fig 5).

In summary, the lordotic transition at the LSJ can be identified with sonography in the majority of newborns and infants, allowing intraspinal structures to be related to a specific vertebral level.

References

1. Naidich TP, Fernback SK, McLone DG, Shkolnik A. Sonography of the caudal spine and back: congenital abnormalities in children. *AJR Am J Roentgenol* 1984;142:1229-1242
2. Zieger M, Dörr U. Pediatric signal sonography Part 1: Anatomy and examination technique. *Ped Radiol* 1988;18:9-13
3. Moore KL. *The developing human. Clinically oriented embryology*, 4th ed. Philadelphia: Saunders, 1988:338-340
4. Gusnard DA, Naidich TP, Yousefzadeh DK, Haughton VM. Ultrasonic anatomy of the normal neonatal and infant spine: correlation with cryomicrotome sections and CT. *Neuroradiology* 1986;28:493-511

5. Byrd SE, Darling CF, McLone DG. Developmental disorders of the pediatric spine. *Radiol Clin North Am* 1991;29:711-752
6. Scheible W, James HE, Leopold GR, Hilton SW. Occult spinal dysraphism in infants: screening with high-resolution real-time ultrasound. *Radiology* 1983;146:743-746
7. Raghavendra BN, Epstein FJ, Pinto RS, et al. The tethered spinal cord: diagnosis by high-resolution real-time ultrasound. *Radiology* 1983;149:123-128
8. Gray DL, Crane JP, Rudloff MA. Prenatal diagnosis of neural tube defects: origin of midtrimester vertebral ossification centers as determined by sonographic water-bath studies. *J Ultrasound Med* 1988;7:421-427
9. Kollias SS, Goldstein RB, Cogen PH, Filly RA. Prenatally detected myelomeningoceles: sonographic accuracy in estimation of the spinal level. *Radiology* 1992;185:109-112
10. Naidich TP, Radkowski MA, Britton J. Real-time sonographic display of caudal spinal anomalies. *Neuroradiology* 1986;28:512-527.
11. Raghavendra BN, Epstein FJ. Sonography of the spine and spinal cord. *Radiol Clin North Am* 1985;23:91-105
12. Rubin JM, DiPietro MA, Chandler WF, Venes JL. Spinal ultrasonography. Intraoperative and pediatric applications. *Radiol Clin North Am* 1988;26:1-27
13. Naidich TP, McLone DG, Shkolnik A, Fernbach SK. Sonographic evaluation of caudal spine anomalies in children. *AJNR Am J Neuroradiol* 1983;4:661-664
14. Williams PL, Warwick R, Dyson M, Bannister LH. *Gray's anatomy*, 37th ed. Edinburgh: Churchill Livingstone, 1989:329
15. Rabischong P. Functional anatomy of the spine and spinal cord. In: Manelfe C, ed. *Imaging of the spine and spinal cord*. New York: Raven Press, 1992:115-137