

Generic Contrast Agents

Our portfolio is growing to serve you better. Now you have a *choice*.



FRESENIUS
KABI

[VIEW CATALOG](#)

AJNR

Imaging quiz. Intravenous drug use; multiple broken needle tips in the neck.

S Aggarwal and A Kumar

AJNR Am J Neuroradiol 1994, 15 (4) 658

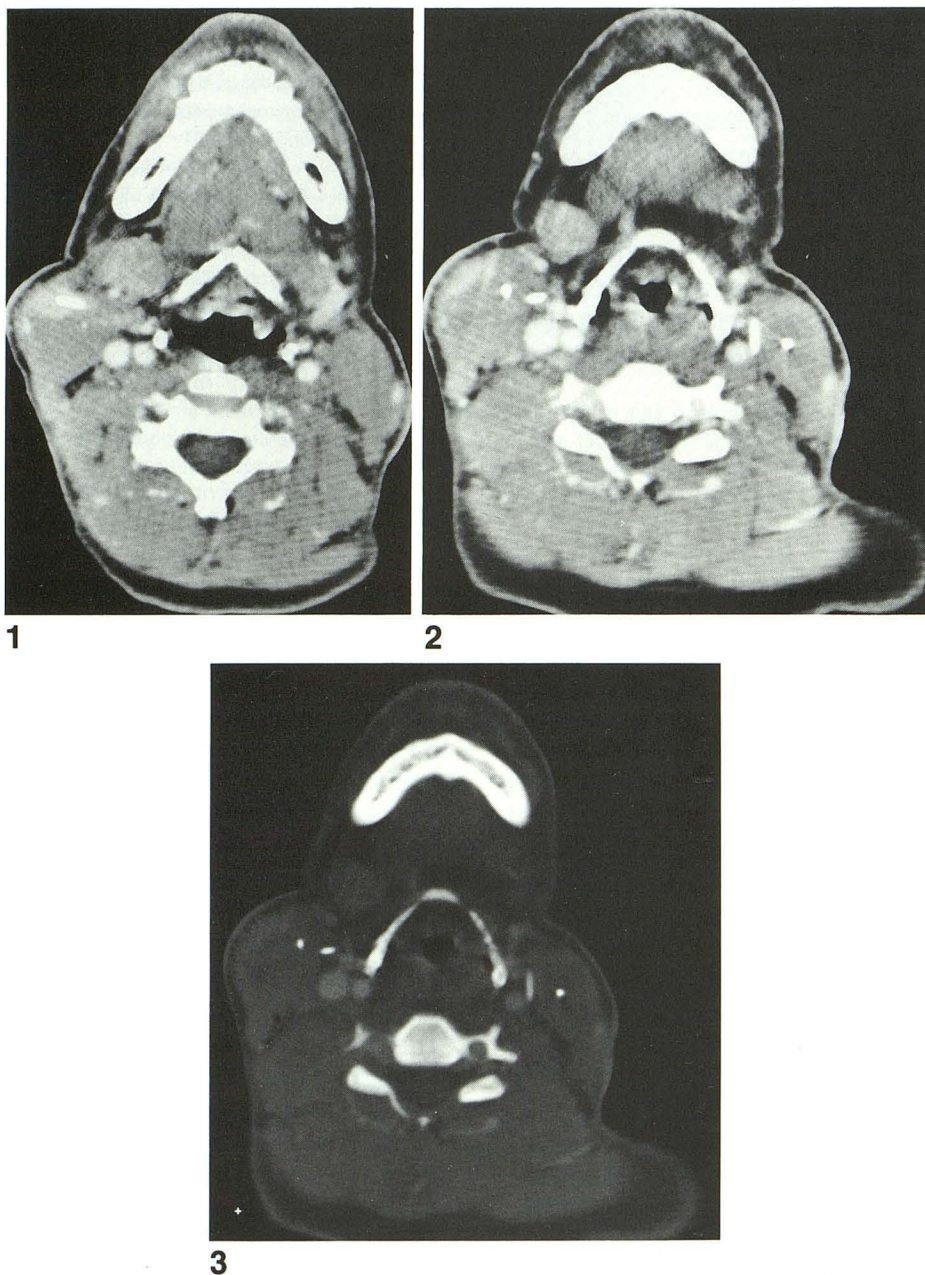
<http://www.ajnr.org/content/15/4/658.citation>

This information is current as
of May 30, 2025.

QUIZ

Shashi Aggarwal and Alka Kumar

A 42-year-old woman had a CT scan of the neck because of swelling and neck pain. No further history was available. Three images of the study done with intravenous contrast enhancement, are shown in Figures 1 through 3.



Diagnosis is on page 774.

Received September 14, 1993; accepted for publication October 29.

From the Department of Radiology, Boston City Hospital.

AJNR 15:658, Apr 1994 0195-6108/0195-6108/94/1504-0658 © American Society of Neuroradiology

Solution to Quiz on page 658.

Diagnosis: Intravenous drug use; multiple broken needle tips in the neck.

All three images show linear, high-density foreign bodies in the soft tissues of the neck (Figs 1–3, page 658). The foreign bodies are either pointing toward, or are in the vicinity of, the carotid sheaths. In Figure 1, there is swelling of the right sternocleidomastoid muscle and increased density surrounding the foreign body track, likely caused by hemorrhage. In Figure 2, a foreign body is actually touching the wall of the left internal carotid artery. A small left internal jugular vein was seen high up in the neck but is not opacified at these lower levels, indicating that it is thrombosed. Figure 3 shows the high density of the foreign bodies.

The differential diagnosis of high densities in the soft tissues includes calcification and foreign bodies (either metallic or nonmetallic, such as glass). The linear, smooth nature and the metallic density of the foreign bodies in our patient suggested these to be needles; plain radiographs were confirmatory (Fig 4). On further questioning, the patient admitted long-standing intravenous drug use.

There is widespread recreational (nonmedical) use of drugs throughout the United States. Inhalation, ingestion, and injection are the usual routes of administration. When injected, the peripheral intravenous route is frequently chosen. Once the superficial veins become unusable because of progressive venous thrombosis (a common problem), the user may turn to the more central jugular and femoral veins. However, some people use the granulation tissue, or surrounding engorged veins, of chronic skin ulcers for injection purposes: it has even been suggested that chronic skin ulcers in young adults be considered a marker for intravenous drug use (1).

The risks of repeated venous punctures are well known and include thrombosis, soft tissue hematoma, and infection (2). Furthermore, because most deep veins such as the internal jugular vein are accompanied by an artery, the artery is susceptible to accidental puncture with the potential for traumatic pseudoaneurysm (3) or arteriovenous fistula formation (see broken needle tip in relation to the left internal carotid artery in Fig 2). In the neck, there is also the potential risk of cervical osteomyelitis caused by direct inoculation from the tip of an unsterile needle (4). All these risks are in addition to the effects of the drug itself and any impurities it may contain.

There is also the ever-present risk of disease transmission, especially the hepatitis B virus and the human immunodeficiency virus, because of shared contaminated needles and/or syringes. Indeed, it has been estimated that needle and syringe sharing is the primary mode of human immunodeficiency virus transmission in the United States (5). To combat this, syringe and needle exchange programs have been initiated in several US cities, and elsewhere, with variable success (5, 6).

In addition, unsuspected broken needle tips deep within the soft tissues pose a hazard of accidental puncture and disease transmission to the surgical personnel (7). Depending on the situation, whenever clinical suspicion arises, plain radiographs of the concerned region and/or other "target" areas should be obtained before a surgical procedure.

Radiologists should be aware of the patterns of drug

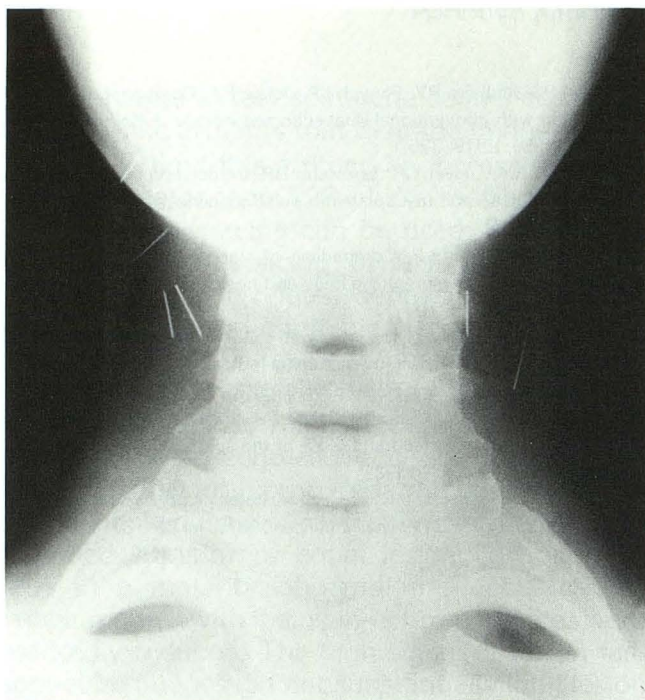


Fig. 4. Soft tissue radiograph of the neck, anteroposterior view. Note the multiple broken needle tips bilaterally.

use, which can lead to puzzling and often bizarre appearances on various imaging studies (4, 8, 9, 10–12). Drug use should be considered when needle-like foreign bodies are seen in the vicinity of veins or unusual patterns of disease are observed.

References

1. Abidin MR, Gillinov MA, Topol BM, Francel TJ. Injection of illicit drugs into the granulation tissue of chronic ulcers. *Ann Plast Surg* 1990;24:268–270
2. Brett RP. Infection and injection drug use. *J Infect* 1992;25:121–131
3. Cheng SW, Fok M, Wong J. Infected femoral pseudoaneurysm in intravenous drug abusers. *Br J Surg* 1992;79:510–512
4. Endress C, Guyot DR, Fata J, Saliciccoli G. Cervical osteomyelitis due to iv heroin use: radiologic findings in 14 patients. *AJR Am J Roentgenol* 1990;155:333–335
5. Schwartz RH. Syringe and needle exchange programs, I. *South Med J* 1993;86:318–322
6. Schwartz RH. Syringe and needle exchange programs worldwide, II. *South Med J* 1993;86:323–327
7. Walker PJ, White GH, Harris JP, Alle KM, May J. Bilateral mycotic axillary artery false aneurysms in an intravenous drug user: unsuspected broken needle-tips pose a risk to the treated personnel. *Eur J Vasc Surg* 1992;6:434–437
8. Swayne LC. Gallium-67 detection of intramammary injection sites secondary to intravenous drug abuse. *Clin Nucl Med* 1989;14:693–694
9. McCrea MS, Rust RJ, Cook DL, Stephens BA. Cocaine-induced rhabdomyolysis. Findings on bone scintigraphy. *Clin Nucl Med* 1992;17:292–293
10. Villareal DT, Murphy WA, Teitelbaum SL, Arens MQ, Whyte MA. Painful diffuse osteosclerosis after intravenous drug abuse. *Am J Med* 1992;93:371–381
11. Padley SP, Adler BD, Staples CA, Miller RR, Muller NI. Pulmonary talcosis: CT findings in three cases. *Radiology* 1993;186:125–127
12. Cranston PE, Pollack CV Jr, Harrison RB. CT of crack cocaine ingestion. *J Comput Assist Tomogr* 1992;16:560–563