

# Generic Contrast Agents

Our portfolio is growing to serve you better. Now you have a *choice*.



FRESENIUS  
KABI

[VIEW CATALOG](#)

# AJNR

## **Lack of age-related differences in temporal lobe volume of very healthy adults.**

C DeCarli, D G Murphy, J A Gillette, J V Haxby, D Teichberg, M B Schapiro and B Horwitz

*AJNR Am J Neuroradiol* 1994, 15 (4) 689-696

<http://www.ajnr.org/content/15/4/689>

This information is current as  
of May 27, 2025.

# Lack of Age-Related Differences in Temporal Lobe Volume of Very Healthy Adults

C. DeCarli, D. G. M. Murphy, J. A. Gillette, J. V. Haxby, D. Teichberg, M. B. Schapiro, and B. Horwitz

**PURPOSE:** To evaluate age-related differences in temporal and supratemporal brain regions in carefully selected, very healthy men 19 to 92 years of age. **METHODS:** MR quantification of brain regions used image segmentation into cerebrospinal fluid and brain matter based on nonlinear modeling of pixel intensity distributions. **RESULTS:** There was a significant age-related decrease (approximately 1% per decade) of posterior frontal lobe volume, but not of temporal lobe volume. The mean volume of the right temporal lobe was significantly greater than the left, and this relation did not change with age. **CONCLUSION:** In very healthy aging, the volume of the temporal lobes remains constant over the age range of human life.

**Index terms:** Brain, magnetic resonance; Brain, measurements; Brain, temporal lobe; Brain, volume; Age and aging

*AJNR Am J Neuroradiol* 15:689–696, Apr 1994

Neuroanatomic and brain imaging studies of apparently healthy individuals conclusively show decreases in the amount of cerebral tissue and associated increases in cerebrospinal fluid (CSF) spaces with advancing age. Postmortem studies show age-related decreases in brain weight and in the absolute amount of cerebral gray and white matter (1–4). Neuron numbers also are decreased to a variable degree in different brain regions (5). Age-related increases in central CSF space size have been described and are proportionally larger per decade of life than loss of cerebral tissue or neurons (4). There has been, however, limited and inconclusive work using postmortem material to study age-related differences in temporal lobe volume (4).

In vivo studies using quantitative computed tomography and quantitative magnetic resonance (MR) have substantiated the finding of generalized age-related decreases in brain matter

and have focused on regional differences in brain volumes. Quantitative computed tomographic studies have conclusively shown age-related increases in the size of central CSF spaces, with reductions in the volumes of caudate nuclei and the thalami (6–7). An age-related decline in the percent of cerebral gray matter without age-related differences in percent white matter also has been described (6). MR has further shown age-related decreases in total brain and regional gray matter volumes (8–12). Despite ongoing interest in measuring temporal lobe disease from MR in patients with Alzheimer disease, studies of age-related differences in temporal lobe volume for healthy subjects have been limited. Two studies of subjects over a large age range have shown age-related declines in temporal lobe volume (13, 14), but both studies included subjects of both sexes and subjects with “risk factors” for cerebral vascular disease (13, 14) (Petersen, RC, written communication, March 1993). Another study has shown no age-related change in temporal lobe volume, but this subject population was young and had a limited age range (15).

To study age-related differences in regional brain volumes in a group of very healthy subjects of a single gender, we quantified the MRs of 30 men free of medical illness 19 to 92 years of age.

---

Received February 22, 1993; accepted pending revision June 14; revision received July 19.

From the Laboratory of Neurosciences, National Institute on Aging, National Institutes of Health, Bethesda, Md.

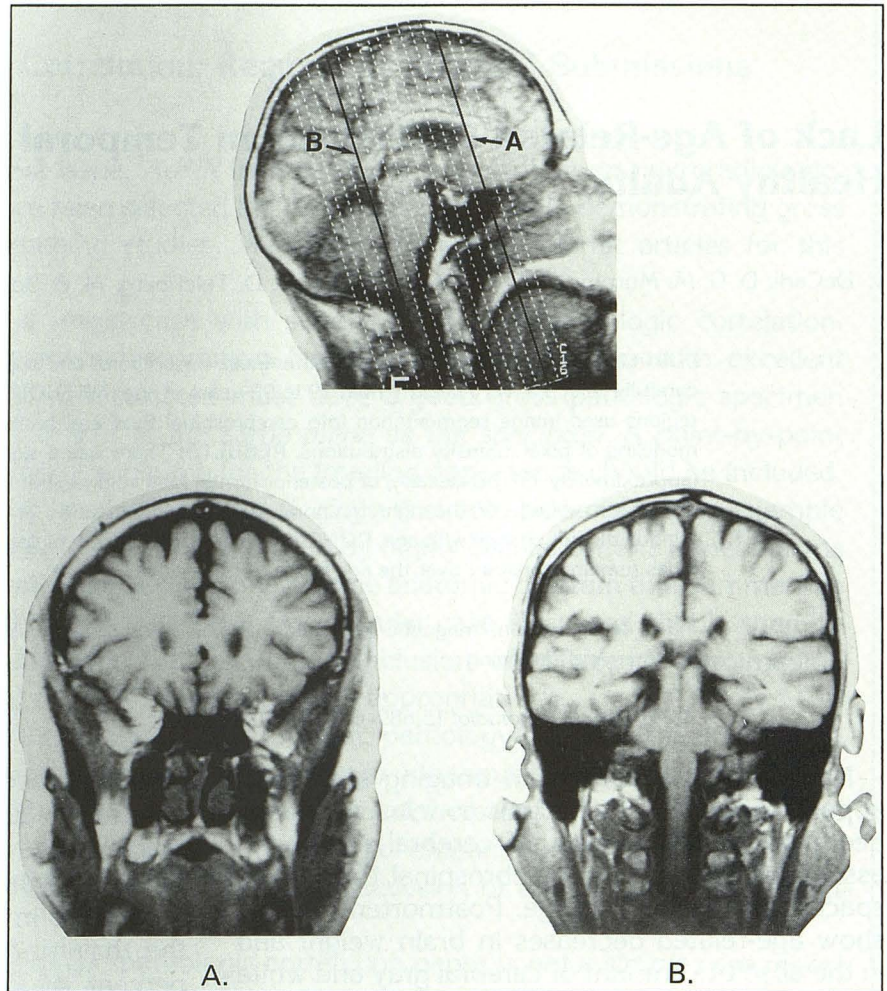
Address reprint requests to Charles DeCarli, MD, Building 10, Room 6 c414, National Institutes of Health, 9000 Rockville Pike, Bethesda, MD 20892.

*AJNR* 15:689–696, Apr 1994 0195-6108/94/1504-0689

© American Society of Neuroradiology



Fig. 1. Temporal lobe boundaries. Temporal lobe boundaries were defined as *A*, the most anterior MR image on which middle cranial fossa could be seen, to *B*, the posterior MR image on which the aqueduct of Sylvius could be seen.



## Methods

### Subjects

MRs were analyzed for 10 young adult men with a mean age  $\pm$  SD of  $25 \pm 4$  years, 9 middle-aged men aged  $59 \pm 4$  years, and 11 older men aged  $75 \pm 8$  years. All subjects were recruited for a longitudinal study on healthy aging (National Institutes of Health protocol 80-AG-26), underwent rigorous medical, neurologic, and laboratory screening (16), and had no evidence of cardiovascular, cerebrovascular, or neurologic disorder, history of drug or alcohol abuse, major psychiatric disorder, or head trauma resulting in unconsciousness. Twenty-nine of 30 subjects were right handed.

The demographics of this sample reflect a highly select group of well-educated and intelligent men. All subjects received at least high school educations, but many completed advanced degrees (mean  $\pm$  SD years of education  $17.1 \pm 2.2$  years, range 13 to 20 years). All subjects were of at least normal intelligence, and many were in the superior range (mean  $\pm$  SD Wechsler full scale intelligence scores  $128.5 \pm 9.3$ , range 110 to 145) (17).

To exclude incipient dementia in the older subjects, longitudinal neuropsychologic test scores were reviewed

for subjects having more than one assessment. Fifteen of the 20 men over the age of 45 years had at least two cognitive assessments. Mean Wechsler full scale intelligent quotients and Wechsler memory scores (18) increased approximately one-half point a year, over an average of 4.8 years between testing. These values did not differ significantly from zero, militating against the presence of an incipient dementia.

### MR Protocol

MR was performed on a 0.5-T machine using a T1-weighted image, 500/12/4 (repetition time/echo time/excitations). Images were acquired with a section thickness of 6 mm and no gap. The imaging matrix was  $256 \times 256$ , and the field of view was 25 cm. Voxel size for this sequence was  $6 \text{ mm}^3$ . Coronal images were obtained perpendicular to an estimated orbital meatal line, beginning anterior to the temporal pole and extending past the posterior aspect of the diencephalon (Fig 1).

To control for image quality and consistency, the MR machine was tested each morning using a standardized phantom.



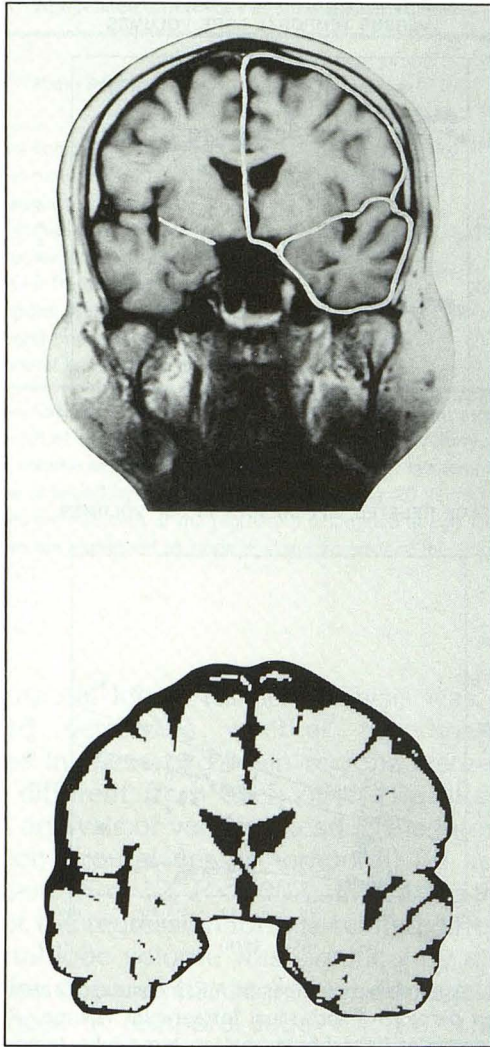


Fig. 2. Traced regions of interest for temporal lobe volumes. The traced intracranial boundaries can be seen on the upper half of the image for the temporal lobe and hemisphere regions of interest. The *traced line* indicates the medial temporal lobe boundary (see text for more detail). A brain segmentation image created from modeling of the image is seen below.

#### Image Analysis

Complete details of the image analysis system have been previously described (19). In summary, quantification of each MR image was performed by segmentation into brain matter and CSF pixels using a nonlinear model which accurately described underlying CSF and brain matter pixel distributions and determined an optimum separation threshold. To exclude nonbrain data from the image, the operator first traced along the dura of the cranium for each section (Fig 1). A pixel intensity histogram was then generated from these data, and an optimal separation threshold was determined. After determining the optimal separation threshold, all pixels within the cranial section were classified into CSF and brain matter. For this analysis, each image was further divided into the right and left temporal lobe

compartments and the right and left supratemporal compartments.

The anterior and posterior boundaries of the temporal lobe compartment were defined as the most anterior MR section image containing middle cranial fossa to the first MR section image on which the aqueduct of Sylvius was seen (Fig 1). In the more caudal portions of the temporal lobe, just posterior to the anterior commissure, the temporal and frontal lobe boundary was defined as a straight line drawn from the angle of the medial temporal lobe where it is attached to the temporal stem, to the midpoint of the operculum (Fig 2). The operator then traced the dura of the middle cranial fossa around each temporal lobe to complete the region of interest. The dura of the supratemporal compartment was similarly traced, dividing the right and left hemispheres by tracing along the falx cerebri and bisecting the third ventricle, if this structure was present on the image. The number of CSF and brain matter pixels in each compartment were counted, summed across cranial sections, and multiplied by the section thickness to give a regional CSF and brain matter volume. The brain matter in the supratemporal compartment corresponded primarily to the posterior half of the frontal lobe but also included small amounts of postcentral gyrus (20; approximately +20 mm to -35 mm in the Talairach anterior-posterior space). As an approximate neuroanatomic location, the brain matter within the supratemporal compartment was designated the posterior frontal lobe. The total volume of CSF and brain matter within the traced cranial volume were designated intracranial CSF and intracranial brain matter, respectively.

Only cerebral structures above the tentorium (this excludes brain stem and cerebellum) were analyzed (Fig 2). Central CSF spaces, which included portions of the lateral ventricles, the entire third ventricle, and the temporal horns of the lateral ventricles, were outlined by hand tracing on each image on which they were present (7). All traced ventricular volumes were summed as an estimate of central CSF. Because the entire extent of the lateral ventricles was not contained in the analysis, these measures were not analyzed individually, but were included as part of the measure of central CSF. Age-related differences in the volumes of the central CSF, the temporal horns of the lateral ventricles, and the third ventricle, however, were analyzed individually because complete information about these volumes was available. Subarachnoid CSF volumes were calculated by subtraction of central CSF volumes from total CSF volumes determined by the segmentation method.

Volumes were expressed both as absolute volumes in cubic centimeters and as the percent of intracranial volume, where intracranial volume was defined as the sum of each traced cranial area from the first to the last section analyzed multiplied by the section thickness.

All the data presented were analyzed by a single operator (C.D.); however, we have previously published high intra-rater and interrater reliabilities for this method (19).



### Statistical Analyses

Because regional cerebral volumes are known to be highly correlated with head size (15), we present results analyzed both as absolute brain volumes ( $\text{cm}^3$ ) and percent of intracranial volume.

Age-related differences in brain matter and CSF volumes were determined using least square linear regression with age as a continuous variable for which the intercept was forced to equal the age of the youngest subject (21). Repeated-measures analysis of variance also was used to compare the differential effect of age on posterior frontal lobe and temporal lobe volumes (21). Measures of cerebral asymmetry (left minus right) were compared using the paired *t* test statistic (21). Significance was defined as  $P < .05$ .

### Results

No significant age-related differences in intracranial volumes were found. Although not statistically significant, the mean intracranial volume was 5% smaller in the older subjects than the younger subjects. Because a smaller head size might spuriously decrease our estimations of absolute brain volume, we calculated the ratios of the four brain compartments to intracranial volume across subjects to see if the relative proportions of regional brain volumes to head size were maintained. The ratio of supratemporal and temporal compartment regions of interest to intracranial volume did not change with age (right and left supratemporal compartments: mean 36%, range 35% to 37%; right and left temporal compartments: mean 13%, range 12% to 13%).

As expected, the absolute volumes of total brain, posterior frontal brain, and temporal brain matter volumes correlated significantly with intracranial volume and the traced supratemporal and temporal compartment region of interest volumes (mean  $r = .85$ ,  $P < .001$ ). Because we were interested in age-related differences in brain and CSF irrespective of head size, we corrected for the effect of head size on regional brain volumes by dividing each regional MR measure by the intracranial volume. After dividing by intracranial volume, correlations between the traced supratemporal or temporal compartment regions of interest and brain matter or CSF volumes were no longer significant (mean  $r = .16$ ,  $P > .05$ ).

Graphic display of age-related differences for CSF and brain matter volumes can be seen in Fig 3. A significant age-related decline in frontal lobe but not temporal lobe brain volumes was found.

Tables 1 and 2 summarize age-related differences in absolute volumes ( $\text{cm}^3$ ) and volumes

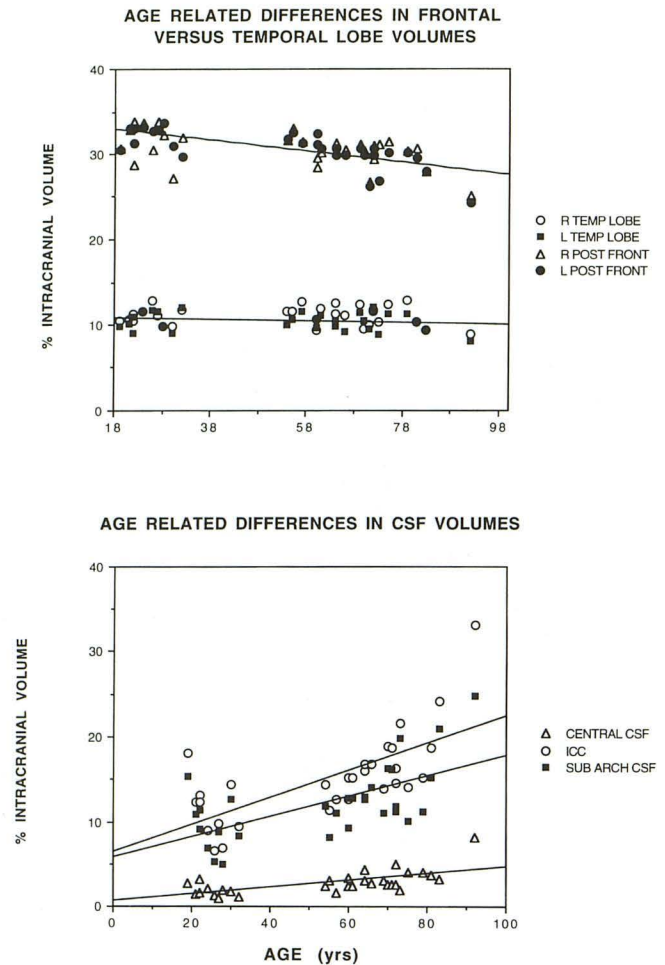


Fig. 3. Age-related changes in MR measures. Graphs are displayed as percent of individual intracranial volume. *Post front* denotes posterior frontal brain matter; *temp lobe*, temporal lobe; *sub arch*, subarachnoid; *LV*, lateral ventricle; *R*, right; and *L*, left.

expressed as percent of intracranial volume for brain matter and CSF. The slopes of the regressions ( $\pm$  standard error) are presented as differences per decade of life between 19 and 92 years. We also show the intercept volumes ( $\pm$  standard error) to allow for comparison with the literature and of relative volumes among the regions.

Significant age-related increases in all ventricular measures were found. Frontal subarachnoid CSF measures showed age-related increases, but less definite age-related increases in temporal subarachnoid CSF were found. Of the brain matter measures, only posterior frontal brain volumes showed age-related decreases. Significant age-related differences in posterior frontal brain volumes but not temporal brain volumes were found whether these volumes were tested as absolute volumes or as a proportion of intracranial volume.

Although age-related differences in brain volume were significant for the frontal lobes but not



TABLE 1: Age-related differences in brain matter volumes

Brain Region	Intercept of the Regression (cm <sup>3</sup> ) <sup>a</sup>	Age Difference in Absolute Volumes (cm <sup>3</sup> /decade) <sup>b</sup>	Intercept of the Regression (% Intracranial Volume) <sup>a</sup>	Age Difference in Percent Intracranial Volume (% Intracranial Volume/decade) <sup>b</sup>
Intracranial volume	658 ± 23.0	-5.1 ± 5.5		
Intracranial brain matter	594 ± 18.9	-14.4 ± 4.5 <sup>c</sup>	90.5 ± 1.3	-1.6 ± 0.3 <sup>e</sup>
Right hemisphere brain matter	284 ± 10.3	-5.1 ± 2.5 <sup>d</sup>	43.2 ± 0.9	-0.46 ± 0.2 <sup>d</sup>
Left hemisphere brain matter	285 ± 9.6	-6.7 ± 2.3 <sup>c</sup>	43.6 ± 0.8	-0.73 ± 0.2 <sup>e</sup>
Right posterior frontal brain matter	211 ± 7.7	-4.3 ± 1.9 <sup>d</sup>	32.1 ± 0.6	-0.43 ± 0.2 <sup>d</sup>
Left posterior frontal brain matter	215 ± 6.8	-5.7 ± 1.6 <sup>c</sup>	32.9 ± 0.5	-0.65 ± 0.1 <sup>e</sup>
Right temporal brain matter	73.6 ± 3.2	-0.78 ± 0.8	11.2 ± 0.4	-0.03 ± 0.1
Left temporal brain matter	70.5 ± 3.3	-1.0 ± 0.8	10.7 ± 0.4	-0.08 ± 0.1
Total temporal brain matter	144 ± 6.2	-1.8 ± 1.5	21.9 ± 0.7	-0.11 ± 0.2

Note.—Absolute brain volumes expressed in cubic centimeters and brain matter volumes expressed as the percent of individual intracranial volume. The intercept of the regression is the calculated brain volume at age 19 years. Age difference denotes the slope of the linear regression between age and brain volume expressed as changes in percent of intracranial volume per decade of life. Calculation of an estimated brain volume for any particular age can be obtained by determining the decade (eg, 25 years = 3.5 decades), multiplying by the slope, and adding to the intercept.

<sup>a</sup> Values are intercept of the regression (estimated at age 19) ± standard error.

<sup>b</sup> Values are expressed as slope ± standard error of the slope.

<sup>c</sup>  $P < .01$ .

<sup>d</sup>  $P < .05$ .

<sup>e</sup>  $P < .001$ .

the temporal lobes, further analysis was necessary to determine whether the age-related changes in these two brain regions were significantly different from each other. Results of repeated analysis of variance testing the interaction of region (frontal versus temporal) by age was significant ( $F = 12$ ,  $P < .002$ ), indicating that the slope of the regression for age-related differences in frontal lobe volume was significantly different from the slope of the regression for age-related differences in temporal lobe volume. This was true for both absolute volumes and brain volumes expressed as the percent of intracranial volume.

Left-right differences in cerebral and CSF volumes also were calculated. The right temporal lobe was  $3.96 \pm 5.4$  cm<sup>3</sup> larger than the left ( $P < .01$ ) but did not differ by subject age ( $r = .14$ ;  $P = .51$ ). Removing the one left-handed subject did not alter this relation. Posterior frontal brain matter, temporal horn of the lateral ventricle, and hemisphere subarachnoid asymmetries were not significantly different from zero.

## Discussion

In very healthy adult men between the ages of 19 and 92 years we found no significant age-related difference in temporal lobe volume but a significant age-related decrease in posterior frontal lobe volume. These results are in contrast with two previous quantitative MR studies which show significant age-related differences in temporal lobe volume (13, 14). Consistent with our results,

however, Coffey et al (14), did show a slope for the age-related decrease in frontal lobe volume twice that of the temporal lobe volume, also suggesting differences in age-related decreases in volume between the frontal and temporal lobes.

Limitations of the method must be carefully considered, given our lack of age-related differences in temporal lobe volume. Unlike Coffey et al (14) and Jack et al (13), we used image segmentation based on a single threshold value for each section in the image. Volume determinations by this method are potentially more susceptible to regional differences in pixel intensities because of radio-frequency inhomogeneities (10). Although the exact effect of radio-frequency inhomogeneity on segmentation of MR images into brain matter and CSF is unknown, the artifact induced is low in spatial frequency (10) and seems to have little effect on volume determinations when the segmentation is limited to distinguishing CSF from brain matter and T1-weighted images are used (19). Moreover, if the method showed age-related decreases in frontal and not temporal lobe volumes, it would suggest that the radio-frequency artifact is somehow systematically different for the two brain regions. This is unlikely and is not borne out by the segmented image shown in Figure 2.

A second source for methodologic error could be in the determination of our brain regions. As we have discussed previously (19), our definition of the temporal lobe boundaries are 6 mm caudal to those of Jack et al (13), resulting in larger



TABLE 2: Age-related differences in CSF volumes

Brain Region	Intercept of the Regression (cm <sup>3</sup> ) <sup>a</sup>	Age Difference in Absolute Volumes (cm <sup>3</sup> /decade) <sup>b</sup>	Intercept of the Regression (% Intracranial Volume) <sup>a</sup>	Age Difference in Percent Intracranial Volume (% Intracranial Volume/decade) <sup>b</sup>
Intracranial CSF	64.1 ± 10.1	9.3 ± 2.4 <sup>c</sup>	9.5 ± 1.3	1.6 ± 0.3 <sup>c</sup>
Central CSF	8.4 ± 2.3	2.0 ± 0.5 <sup>c</sup>	1.3 ± 0.3	0.3 ± 0.1 <sup>c</sup>
Total subarachnoid CSF	55.7 ± 9.1	7.3 ± 2.2 <sup>d</sup>	8.2 ± 1.2	1.3 ± 0.3 <sup>c</sup>
Third ventricle	0.9 ± 0.2	0.22 ± 0.05 <sup>c</sup>	0.13 ± 0.03	0.04 ± 0.007 <sup>c</sup>
Right temporal horn of the lateral ventricle	-0.08 ± 0.13	0.11 ± 0.03 <sup>d</sup>	-0.1 ± 0.03	0.03 ± 0.007 <sup>d</sup>
Left temporal horn of the lateral ventricle	-0.1 ± 0.1	0.13 ± 0.03 <sup>c</sup>	-0.07 ± 0.03	0.03 ± 0.007 <sup>c</sup>
Right posterior frontal CSF	22.0 ± 3.5	3.4 ± 0.9 <sup>c</sup>	3.2 ± 0.5	0.6 ± 0.1 <sup>c</sup>
Left posterior frontal CSF	21.0 ± 3.6	3.8 ± 0.9 <sup>c</sup>	3.1 ± 0.5	0.6 ± 0.1 <sup>c</sup>
Right temporal CSF	8.5 ± 1.6	0.67 ± 0.4	1.3 ± 0.2	0.1 ± 0.05 <sup>e</sup>
Left temporal CSF	7.1 ± 1.4	0.71 ± 0.3 <sup>e</sup>	1.1 ± 0.2	0.1 ± 0.05 <sup>e</sup>
Right posterior frontal subarachnoid CSF	17.9 ± 3.0	2.4 ± 0.7 <sup>d</sup>	2.6 ± 0.4	0.4 ± 0.1 <sup>c</sup>
Left posterior frontal subarachnoid CSF	16.8 ± 3.0	2.7 ± 0.7 <sup>c</sup>	2.4 ± 0.4	0.5 ± 0.1 <sup>c</sup>
Right temporal subarachnoid CSF	8.5 ± 1.6	0.55 ± 0.4	1.4 ± 0.2	0.08 ± 0.05
Left temporal subarachnoid CSF	7.2 ± 1.3	0.52 ± 0.3	1.1 ± 0.2	0.09 ± 0.05

Note.—Absolute CSF volumes expressed in cubic centimeters and CSF volumes expressed as the percent of individual intracranial volume. The intercept of the regression is the calculated CSF volume at age 19 years. Age difference denotes the slope of the linear regression between age and brain volume expressed as changes in percent of intracranial volume per decade of life. Calculation of an estimated CSF volume for any particular age can be obtained by determining the decade (eg, 25 years = 3.5 decades), multiplying by the slope, and adding to the intercept.

<sup>a</sup> Values are intercept of regression (estimated at age 19) ± standard error.

<sup>b</sup> Values are expressed as slope ± standard error of the slope.

<sup>c</sup>  $P < .001$ .

<sup>d</sup>  $P < .01$ .

<sup>e</sup>  $P < .05$ .

volumes. Use of these boundaries enables us to have high interrater and intrarater reliabilities and has proved a valid measure of temporal lobe volume in a postmortem study (19). Moreover, although the operator traces the region of interest boundaries, the temporal lobe brain volumes were calculated by counting pixels above the CSF-brain matter threshold within the region of interest, reducing the effect of interrater and intersubject differences in region of interest boundaries. However, the more caudal extension of our temporal lobe definition may include portions of the temporal lobe that are less susceptible to age-related changes, and therefore could be another explanation for the differences between our study and those reported previously. Because our method was designed specifically to measure temporal lobe volumes, our measure of frontal lobe volume was limited to the portion of the frontal lobe superior to the temporal lobe. It is possible that the posterior half of the frontal lobe has age-related changes that are different from the anterior aspect of the frontal lobe. We doubt there could be significant regional differences in

age-related changes within the frontal lobe, because we found a similar relative difference between age-related decreases in frontal versus temporal lobe volumes as Coffey et al (14), and our age-related differences in percent brain volume coincide closely with postmortem studies (4).

Finally, it could be that our method is insensitive to small changes in cerebral size. This seems unlikely, because our method has been shown to be very sensitive to subtle changes in temporal lobe volumes of patients with the earliest clinical signs of dementia of the Alzheimer type (22) and the minor changes in cerebral size accompanying chronic essential hypertension (23).

Data from postmortem studies also support the validity of our method as a measure of brain volume. Hubbard and Anderson (4) reported that brain matter occupied 77% of the skull in 12 control subjects with a mean age of 73.4 years, which compares favorably to an estimation of 80% calculated from the regression in Table 1. Also, Miller et al (2) found a decline in brain volume of 2% per decade, which is similar to our



finding of 1.6% per decade (Table 1). Although Hubbard and Anderson (4) did not comment on temporal lobe volume in relation to age, examination of their data suggests no difference in temporal lobe volume between the ages of 68 and 95 years. Only three measures were made in younger subjects.

Although the volume of the entire temporal lobe did not differ significantly with age, the volume of the temporal horn of the lateral ventricle differed significantly with age. One explanation would be that the volume of the hippocampus is smaller in the older group, and this is reflected in the volume of the temporal horn of the lateral ventricle (14). Some (13, 14) but not all MR studies (24) have found significant age-related differences in hippocampal volume when measured directly. Because the hippocampus and the temporal horn of the lateral ventricle are small in comparison with the total volume of the temporal lobe, age-related changes in these structures did not significantly impact on age-related differences in temporal lobe volume. Moreover, the age-related differences in these CSF measures may suggest a more focal process in our very healthy subjects as compared with the generalized temporal lobe atrophy seen with Jack et al (13) and Coffey et al (14).

We believe the excellent health of our subjects is the most likely explanation for the difference between our results and the results of Coffey et al (14) and Jack et al (13). Our health-screening criteria were very rigorous and excluded all diseases known to affect temporal lobe function and structure, such as dementia, stroke, alcohol abuse, and epilepsy. Recent reports have shown that the presence of hypertension is associated with brain atrophy (23, 25), and the two previous reports of age-related changes in temporal lobe volume contained subjects with hypertension (13, 14) (Petersen RC, written communication, March 1993). Hypertension would not be expected to preferentially affect temporal lobe volume, however, and we believe that the exclusion of other diseases or cerebrovascular risk factors also contributed to the difference between our results and the results of others.

Despite differences in the magnitude of age-related changes in temporal lobe volume, we and Coffey et al (14) show that frontal lobe volumes decrease approximately twice as much as temporal lobe volumes with age. The differential effect of age on temporal versus frontal brain regions may relate to the content of white matter

found in these two portions of the brain. Approximately 45% of the frontoparietal cortex is white matter (4), whereas only 33% of the temporal lobe is white matter. Miller et al (2) has shown that advancing age is associated with a disproportional loss of cerebral white matter volume. Preferential loss of cerebral white matter, because white matter is a smaller proportion of the temporal lobe volume, may account for differential effect of age on the posterior frontal versus temporal lobes.

In summary, we found that in very healthy aging (ie, no diseases) as compared with "successful aging" (14; ie, there may be diseases but not dementia) there is no age-related difference in temporal lobe volumes. We suggest that the degree to which our results differ from Coffey et al (14) and Jack et al (15) is the result of excluding the untoward effects of superimposed processes such as latent cerebrovascular disease or dementia. Further quantitative MR studies of patients with cerebrovascular risk factors without dementia are needed to understand these possible latent effects on brain structure.

## Acknowledgments

We thank the MR technicians for their assistance and Stanley I. Rapoport, MD, and A. R. McIntosh, PhD, for reviewing the manuscript.

## References

1. Dekaban AS, Sadowsky D. Changes in brain weights during the span of human life: relation of brain weights to body heights and body weights. *Ann Neurol* 1978;4:345-356
2. Miller AKH, Alston RL, Corsellis JAN. Variation with age in the volumes of grey and white matter in the cerebral hemispheres of man: measurements with an image analyzer. *Neuropathol Appl Neurobiol* 1980;6:119-132
3. Davis PJM, Wright EA. A new method for measuring cranial cavity volume and its application to the assessment of cerebral atrophy at autopsy. *Neuropathol Appl Neurobiol* 1977;3:341-358
4. Hubbard BM, Anderson JM. Age, senile dementia and ventricular enlargement. *J Neurol Neurosurg Psychiatry* 1981;44:631-635
5. Brody H, Vijayashankar N. Anatomical changes in the nervous system. In: Finch CE, Hayflick L, eds. *Handbook of the biology of aging*. New York: Raven, 1976:241-261
6. Schwartz M, Creasey H, Grady CL, et al. CT analysis of brain morphometrics in 30 healthy men, aged 21 to 81 years. *Ann Neurol* 1985;17:146-157
7. DeLeo JM, Schwartz M, Creasey H, Cutler N, Rapoport SI. Computer-assisted categorization of brain computerized tomography pixels into cerebrospinal fluid, white matter, and gray matter. *Comput Biomed Res* 1985;18:79-88
8. Filipek PA, Kennedy DN, Caviness VS, Rossnick SL, Spraggins TA, Starewicz PM. Magnetic resonance imaging-based brain morphometry: development and application to normal subjects. *Ann Neurol* 1989;25:61-67



9. Kohn MI, Tanna NK, Herman GT, et al. Analysis of brain and cerebrospinal fluid volumes with MR imaging. *Radiology* 1991;178:115-122
10. Lim KO, Pfefferbaum A. Segmentation of MR brain images into cerebrospinal fluid spaces, white and gray matter. *J Comput Assist Tomogr* 1989;13:588-593
11. Jernigan TL, Press GA, Hesselink JR. Methods for measuring brain morphologic features on magnetic resonance images. *Arch Neurol* 1990;47:27-32
12. Rusinek H, de Leon MJ, George AE, et al. Alzheimer disease: measuring loss of cerebral gray matter with MR imaging. *Radiology* 1991;178:109-114
13. Jack CR, Petersen RC, O'Brien PC, Tangalos EG. MR-based hippocampal volumetry in the diagnosis of Alzheimer's disease. *Neurology* 1992;42:183-188
14. Coffey CE, Wilkinson WE, Parashos IA, et al. Quantitative cerebral anatomy of the aging human brain: a cross-sectional study using magnetic resonance image. *Neurology* 1992;42:527-536
15. Jack CR, Twomey CK, Zinsmeister AR, Sharbrough FW, Peterson RC, Cascino GD. Anterior temporal lobes and hippocampal formations: normative volumetric measurements from MR images in young adults. *Radiology* 1989;172:549-554
16. Duara R, Margolin RA, Robertson-Tchabo EA, et al. Cerebral glucose utilization, as measured with positron emission tomography in 21 resting healthy men between the ages of 21 and 83 years. *Brain* 1983;106:761-775
17. Wechsler DA. *Wechsler adult intelligence scale*. New York: Psychological Corp, 1955:1-110
18. Wechsler DA. A standardized memory scale for clinical use. *J Psychol* 1945;19:87-95
19. DeCarli C, Maisog J, Murphy DGM, Teichberg D, Rapoport SI, Horwitz B. A method for quantification of brain, central and peripheral CSF volumes from magnetic resonance images. *J Comput Assist Tomogr* 1992;16:274-284
20. Taliairach J, Tournoux P. *Co-planar stereotaxic atlas of the human brain*. New York: Thieme, 1988:59-80
21. *Statistical analysis systems (SAS) version 6.3*. Cary: SAS Institute, 1990:1351-1456
22. Murphy DGM, DeCarli C, Daly E, et al. Volumetric magnetic resonance imaging in men with dementia of the Alzheimer type: correlations with disease severity. *Biol Psychiatry* 1993;34:612-621
23. Salerno JA, Murphy DGM, Horwitz B, et al. Brain atrophy in older hypertensive men: a volumetric magnetic resonance study. *Hypertension* 1992;20:340-348
24. Lim KO, Zipursky RB, Murphy GM, Pfefferbaum A. In vivo quantification of the limbic system using MRI: effects of normal aging. *Psychiatry Res Neuroimaging* 1990;35:15-26
25. Hatazawa J, Yamaguchi T, Ito M, Yamaura H, Matsuzawa T. Association of hypertension with increased atrophy of brain matter in the elderly. *J Am Geriatr Soc* 1984;32:370-374