

Generic Contrast Agents

Our portfolio is growing to serve you better. Now you have a *choice*.



FRESENIUS
KABI

[VIEW CATALOG](#)

AJNR

CT and MR of temporal bone malignancies primary and secondary to parotid carcinoma.

S W Horowitz, J P Leonetti, B Azar-Kia, M Fine and R Izquierdo

AJNR Am J Neuroradiol 1994, 15 (4) 755-762

<http://www.ajnr.org/content/15/4/755>

This information is current as
of May 29, 2025.

CT and MR of Temporal Bone Malignancies Primary and Secondary to Parotid Carcinoma

Sandra W. Horowitz, John P. Leonetti, Behrooz Azar-Kia, Michael Fine, and Ricardo Izquierdo

PURPOSE: To review the CT and MR characteristics of temporal bone malignancy, and to evaluate the relationship between malignancies of the temporal bone and parotid gland. **METHODS:** A group of 15 surgical patients with diagnosis of temporal bone malignancy were retrospectively reviewed. These included 11 cases of primary temporal bone malignancy and four cases of secondary carcinoma of the temporal bone from a primary tumor of the parotid gland. Three primary temporal bone malignancies were recurrences, and two secondary tumors were parotid recurrences. **RESULTS:** Five of the 11 patients with primary temporal bone malignancy had parotid infiltration (45%). All four patients with secondary temporal bone destruction caused by parotid carcinoma had erosion of the mastoid, two with erosion of the external auditory canal, and one of the middle ear. **CONCLUSIONS:** It is important radiographically to recognize the close relationship between malignancies of the temporal bone and parotid gland, because either may secondarily invade the other. Suspicion of malignancy in either the temporal bone or parotid gland necessitates complete imaging of the other structure. Temporal bone or skull base erosion were best seen on CT at bone algorithm. MR with and without infusion provided excellent delineation of soft-tissue tumor margins, muscle infiltration, intracranial extension, and vascular encasement.

Index terms: Temporal bone, computed tomography; Temporal bone, magnetic resonance; Temporal bone, neoplasms; Parotid gland, neoplasms

AJNR Am J Neuroradiol 15:755-762, Apr 1994

There is a diverse group of malignant neoplasms that originate in or extend to the temporal bone, the most common being squamous cell carcinoma, basal cell carcinoma, and parotid malignancies (1). The role of radiology includes: 1) diagnosis of malignancy by bone erosion of the external auditory canal most commonly, but also of middle ear and mastoid; and 2) preoperative delineation of disease extent beyond the external auditory canal and middle ear (2).

Surgical resection of basal cell carcinoma has an excellent prognosis, but the prognosis of squamous cell carcinoma of the temporal bone is poor and is mostly related to tumor extent at presen-

tation. There is little chance for cure when tumor is left behind at the time of surgery (1-5). Thus, accurate preoperative radiologic assessment of temporal and extratemporal extent of tumor is important.

The purpose of this study was to review the magnetic resonance (MR) and computed tomographic (CT) characteristics of temporal bone malignancy, examine the relationship between malignancies of the temporal bone and parotid gland, and advise appropriate radiologic examination to permit best preoperative assessment of tumor extent.

Methods

CT and MR scans of a group of 15 surgical patients with temporal bone malignancy were retrospectively reviewed. These tumors included both primary and secondary temporal bone malignancy. The CT and MR scans were analyzed for sites of bone erosion at temporal bone and skull base, sites of soft-tissue involvement including parotid gland, infratemporal fossa, and intracranial extension, and vascular involvement of the jugular bulb, sigmoid sinus,

Received February 26, 1993; accepted after revision June 21.

From the Departments of Radiology (S.W.H., B.A.-K., M.F.), Otolaryngology (J.P.L.), and Plastic Surgery (R.I.), Loyola University Chicago Medical Center, Maywood, Ill.

Address reprint requests to Sandra W. Horowitz, MD, Department of Radiology, Loyola University Medical Center, 2160 South First Ave, Maywood, IL 60153.

AJNR 15:755-762, Apr 1994 0195-6108/94/1504-0755

© American Society of Neuroradiology

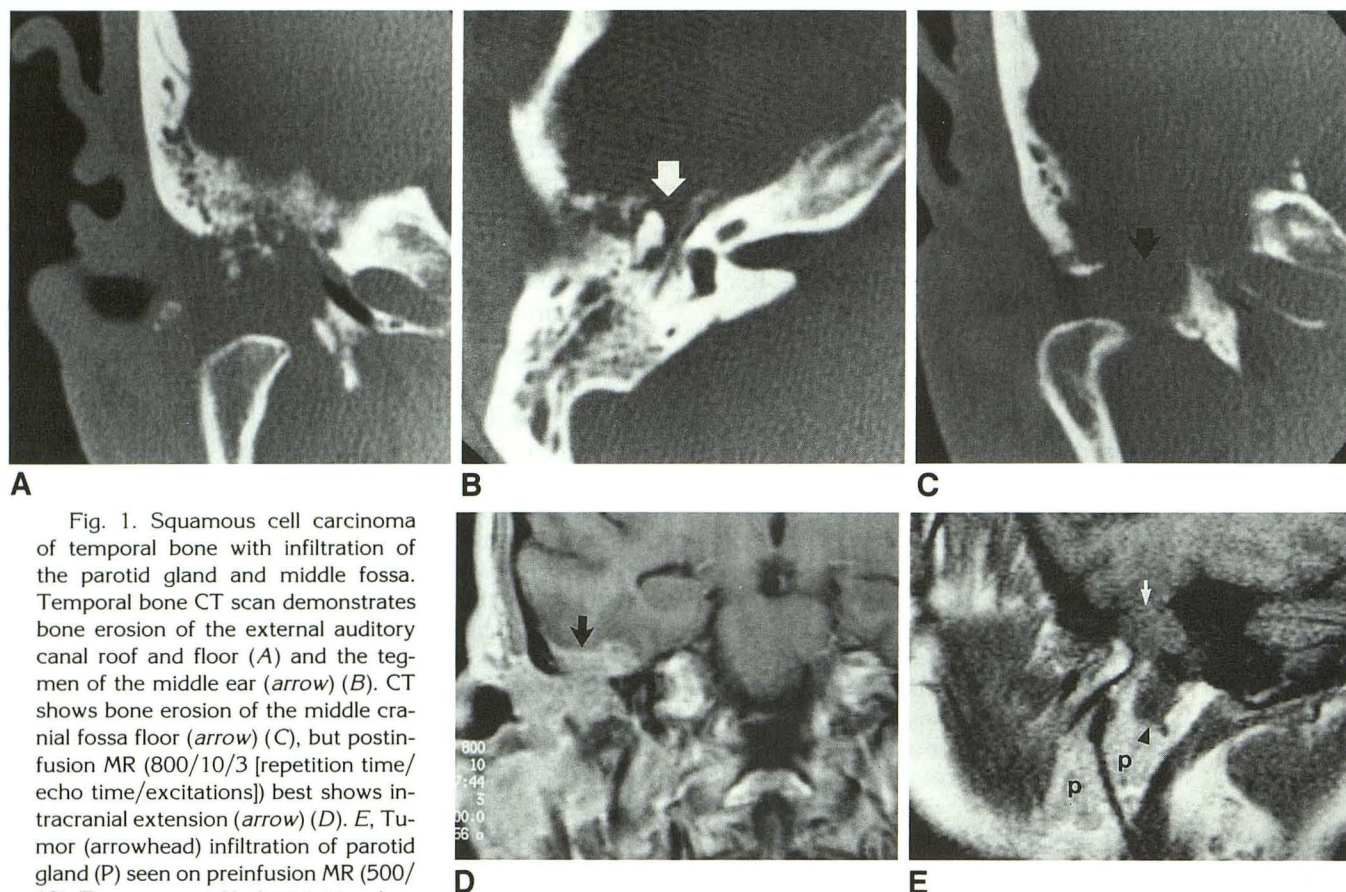


Fig. 1. Squamous cell carcinoma of temporal bone with infiltration of the parotid gland and middle fossa. Temporal bone CT scan demonstrates bone erosion of the external auditory canal roof and floor (A) and the tegmen of the middle ear (arrow) (B). CT shows bone erosion of the middle cranial fossa floor (arrow) (C), but postinfusion MR (800/10/3 [repetition time/echo time/excitations]) best shows intracranial extension (arrow) (D). E, Tumor (arrowhead) infiltration of parotid gland (P) seen on preinfusion MR (500/10). Temporomandibular joint involvement is best seen on sagittal MR (E) but is also seen on CT (A and C). The arrow indicates the eroded floor of the middle cranial fossa.

and internal carotid artery. Correlation with surgery and pathology reports was obtained in all cases.

Temporal bone CT was performed on a General Electric (Milwaukee, Wis) 9800 unit with 1.5-mm consecutive sections obtained in coronal and axial planes at bone algorithm and filmed at extended scale, window 4000. Section thickness of soft-tissue CT windows varied from 1.5 mm to 3 mm to 5 mm. Contrast-enhanced CT scans were obtained on 12 of the 15 patients. MR scans were performed on a GE Signa 1.5-T unit, including preinfusion T1-weighted and T2-weighted sequences and postinfusion T1-weighted sequences after intravenous injection of 0.1 mmol/kg of gadopentatate dimeglumine. All three planes were included on T1-weighted MR sequences of the temporal bones at a 3-mm section thickness, interleaved.

Results

Of the 15 patients with temporal bone malignancy, eight were male and seven were female. Mean age was 64 years old with a range of 16 to 90 years.

Of the 11 cases of primary temporal bone malignancy, basal cell carcinoma (three patients), squamous cell carcinoma (five patients), adenocarcinoma (two patients), and osteosarcoma (one patient), three were recurrences. There were four cases of temporal bone carcinoma secondary to primary parotid malignancy: squamous cell carcinoma (one patient), high-grade mucoepidermoid carcinoma (two patients, one recurrent), and adenoid cystic carcinoma (one patient, recurrent).

Overall, sites of temporal bone destruction were seen best on thin-cut CT with bone algorithm. The most common sites of bone destruction seen on CT in cases of primary temporal bone carcinoma were the external auditory canal (eight patients) (Fig 1), middle ear (seven patients) (Fig 1), and mastoid (five patients) (Fig 2). In cases of primary parotid carcinoma involving the temporal bone, all four patients showed mastoid destruction (three of four at inferior mastoid),

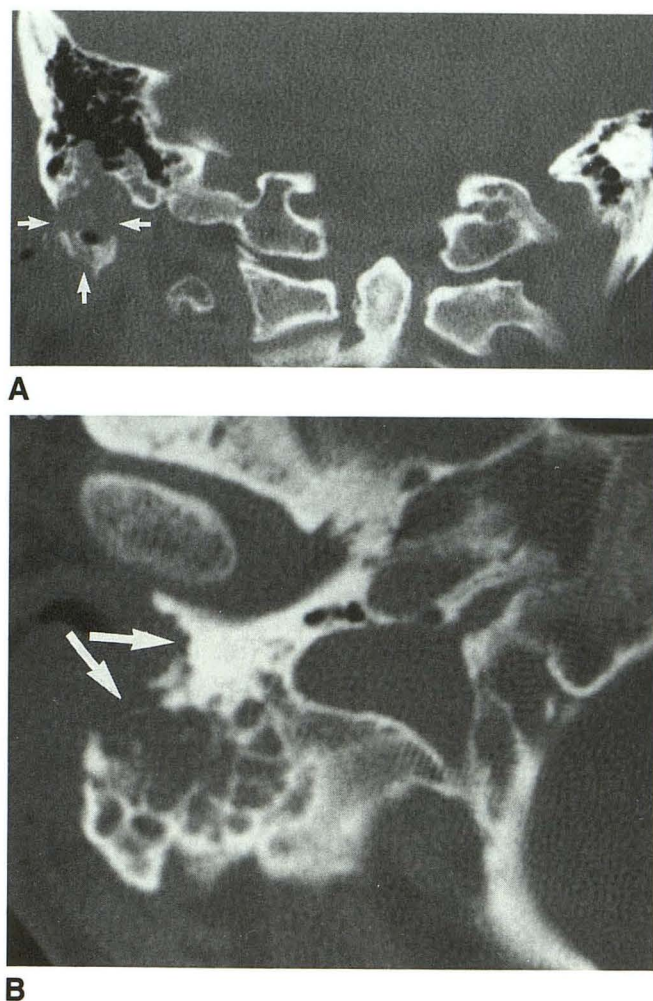


Fig. 2. Recurrent basal cell carcinoma of right ear. A and B, CT shows bone erosion of inferior mastoid and styloid process (arrows).

with erosion of the external auditory canal in two patients and the middle ear in one patient (Fig 3). Mastoid erosion was seen on MR in some cases as loss of hypointense cortex, but in one case, MR failed to delineate mastoid cortical erosion, showing increased signal intensity in mastoid air cells on T1-weighted and T2-weighted sequences.

Other sites of bone destruction in a smaller number of patients, listed in Table 1, included the floor of middle cranial fossa (Fig 1), posterior fossa (Figs 4 and 5), jugular bulb (Figs 4 and 5), carotid canal, petrous apex (Fig 5), clivus, and foramen magnum. Bone erosion of middle cranial fossa and posterior fossa was seen on both CT and MR in some cases, but in one case, MR failed to show a defect in the sinodural plate visible on CT because both the dura and cortex are hypodense on MR, precluding differentiation. CT best detected bone erosion of middle and posterior

fossa; intracranial soft tissue extension into the middle (Fig 1) and posterior fossa (Fig 4) was seen best on postinfusion MR.

Bone destruction of carotid canal and jugular fossa was seen best on CT (Fig 5) with only one case of CT failure to detect jugular fossa destruction. MR delineated involvement of the internal carotid artery and jugular bulb by enhancing tumor adjacent to signal flow void of the carotid or by obliterating flow enhancement at the jugular bulb or sigmoid sinus (Fig 4). Although CT best detected bone destruction, MR was considered to be better for evaluation of patency, obstruction, or encasement of carotid, jugular, and dural sinuses.

Glenoid fossa erosion in four patients with primary temporal bone malignancy was seen on both CT and MR (Figs 1 and 6) without destruction of the mandibular condylar head. Soft-tissue tumor extension into the joint space was seen particularly well on sagittal MR.

Sites of soft-tissue extension of temporal bone malignancy, listed in Table 2, include infratemporal fossa (Figs 6 and 7) and parapharyngeal space. Soft-tissue tumor margins (Fig 7) and infiltration of adjacent masseter and pterygoid muscles were better seen on postinfused MR than on CT (not shown). Encasement of internal carotid artery by parapharyngeal tumor extension was better seen on MR because of signal flow void.

Parotid infiltration by primary temporal bone malignancy was present in five of 11 patients (Figs 1, 6, and 7) and was seen on MR in three planes (seen best on coronal or sagittal) and on soft-tissue CT windows of parotid, not on the bone algorithm CT of the temporal bones.

CT appearance of the parotid gland in all four patients with primary parotid malignancy (and secondary temporal bone involvement) showed irregular borders of the parotid tumors (Fig 3). The area of tumor involvement within the parotid gland included both deep and superficial lobes in three of four patients and deep lobe alone in one of four patients. Density of parotid tumor was higher than that of normal parotid gland on CT, some being heterogeneous. MR signal intensity of the parotid tumors was low on T1-weighted images. On T2-weighted images, signal intensity was predominantly low (three of four patients); it was hyperintense in one patient and inhomogeneous in one patient. All four parotid tumors enhanced after infusion; three were inhomogeneously and one densely homogeneous, the one

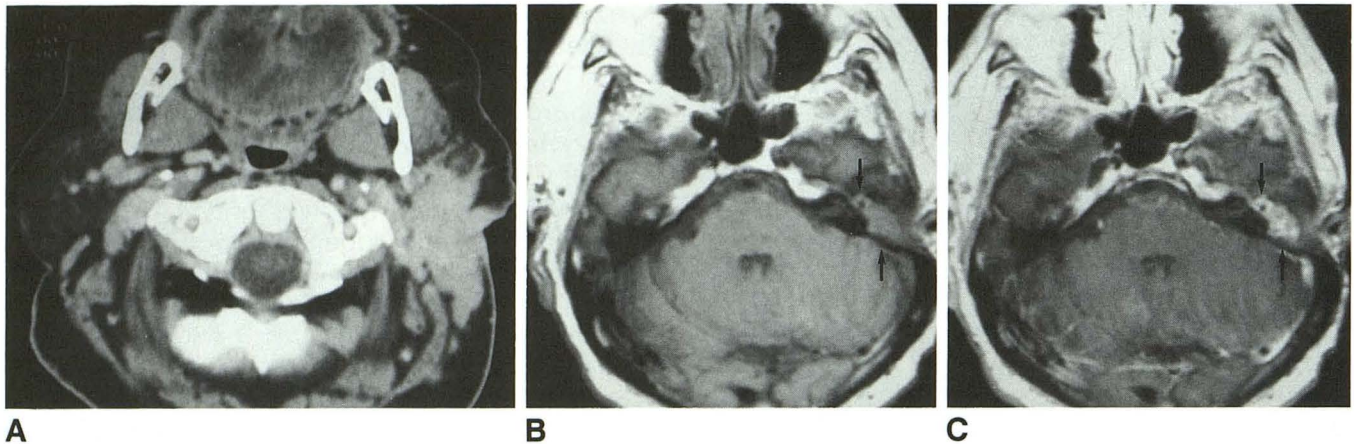


Fig. 3. Adenoid cystic carcinoma of the parotid gland, recurrent to temporal bone.

A, Large high-attenuation mass with irregular tumor margins, replacing most of the left parotid gland, both superficial and deep lobes. Parotidectomy, mastoidectomy, and neck dissection were then performed. Three years later preinfusion (B) and postinfusion (C) MR (550/20) shows densely enhancing tumor recurrence at the middle ear (arrows).

patient with recurrent adenoid cystic carcinoma to temporal bone (Fig 3).

Discussion

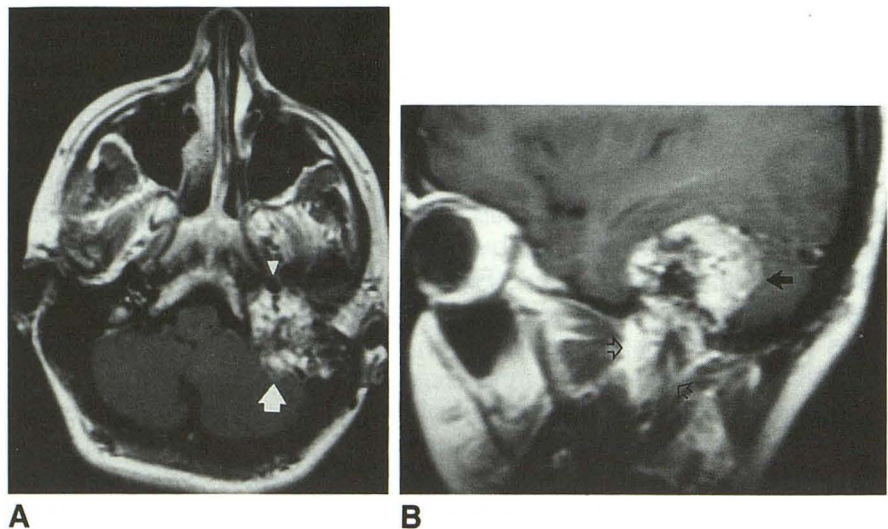
A diverse group of malignant neoplasms originate in or extend to the temporal bone, the most common being squamous cell carcinoma, basal cell carcinoma, and parotid malignancies (1). Squamous cell carcinoma is the most common malignancy of the temporal bone, but it is still relatively rare, beginning in the external auditory canal (most common), skin, or middle ear (6, 7). It may not be possible to determine whether tumor began in the deep bony external auditory canal and invaded the middle ear or vice versa, because in most cases both regions will be in-

involved at time of presentation (8). The aggressive parotid malignancies which may extend to the temporal bone include high-grade mucoepidermoid, undifferentiated, squamous cell, and adenocarcinoma (9, 10). Less common tumors of the temporal bone include adenocarcinoma, adenoid cystic carcinoma, metastases, and rhabdomyosarcoma in pediatric patients.

Recognition of the anatomic relationships between temporal bone, parotid gland, and facial nerve is essential to understanding the spread of neoplasm between these structures (Fig 8). The parotid gland is anterior to the external auditory canal and mastoid process. Primary malignancies arising in the external auditory canal spread primarily by direct extension into contiguous structures, anteriorly into the parotid gland and tem-

Fig. 4. Low-grade cystic papillary adenocarcinoma of temporal bone with posterior fossa extension.

A and B, Postinfusion MR (600/20) shows an enhancing mass that extends into the posterior fossa (arrow), extends below the skull base (open arrows), abuts the internal auditory canal (arrowhead), and obliterates the jugular bulb and sigmoid sinus.



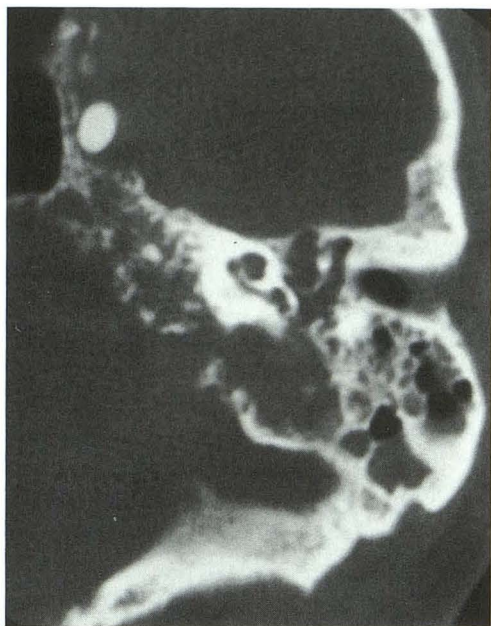


Fig. 5. Adenocarcinoma of temporal bone. CT shows bone destruction of margins of the posterior fossa, jugular bulb, carotid canal, middle ear, and petrous apex. A contrast-filled balloon is in the cavernous carotid (second balloon in the high cervical carotid, not shown).

poromandibular joint, and posteriorly into the mastoid air cell system (5, 11). The parotid gland is important in control of temporal bone malignancy (12). The superficial lobe of the parotid gland can be the site of major lymphatic spread from the cartilaginous canal; the deep lobe is the site of lymphatic spread from the bony canal. Tumor may spread to preauricular nodes and, rarely, to cervical nodes. Tumor may spread along vascular channels or nerve roots. Facial nerve paralysis almost always indicates malignancy in parotid tumors and is found in 40% of malignant ear tumors (7, 13, 14).

In our patients, the reciprocal routes of extension between temporal bone malignancy and parotid malignancy included direct erosion of the external auditory canal, temporomandibular joint, and mastoid process, and possible perineural extension along the facial nerve with erosion of mastoid and stylomastoid foramen.

The role of radiology in temporal bone carcinoma includes: 1) diagnosis of temporal bone malignancy using the most important radiologic sign, bone erosion of the external auditory canal; and 2) preoperative indication of the extent of disease beyond the external auditory canal and middle ear (2). Gross bone erosion may be seen on MR as loss of the marked hypointensity of petrous bone and mastoid cortex, but the fine

detail of petrous bone erosion is best seen on high-resolution bone algorithm CT of temporal bone, with reported 93% to 98% accuracy in determining extent of malignancy in resected temporal bone specimens (3, 7, 12). A reported limitation of CT is difficulty distinguishing between mucosal thickening and tumor in the middle ear in the absence of bone erosion. Avascular labyrinthine bone is reportedly relatively unaffected in temporal bone malignancy (11). One of our cases, primary low-grade cystic papillary ad-

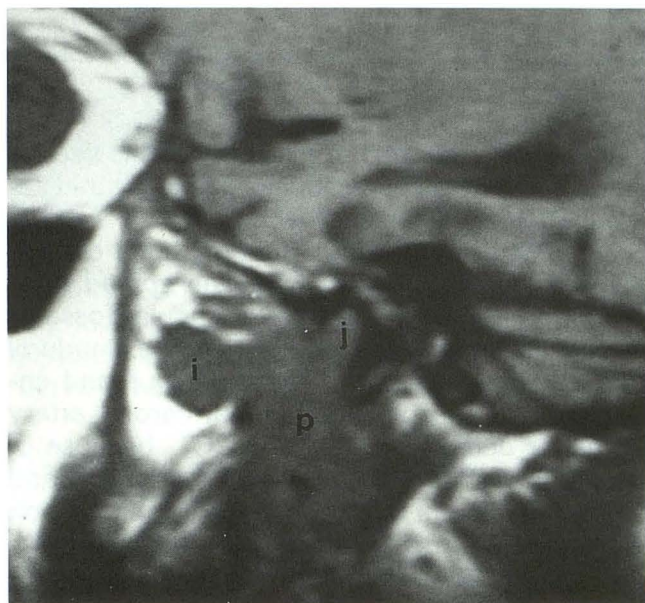


Fig. 6. Recurrent squamous cell carcinoma of the right temporal bone. MR (600/20) shows soft-tissue mass at the parotid gland (P), temporomandibular joint (J), and infratemporal fossa (I).

TABLE 1: Bone destruction, number of patients

Sites of Bone Destruction	Primary Temporal Bone Malignancy	Temporal Bone Carcinoma Secondary to Parotid Carcinoma	Total*
External auditory canal	8	2	10
Middle ear	7	1	8
Mastoid	5	4	9
Jugular bulb	2	1	3
Carotid canal	2	0	2
Internal auditory canal	1	0	1
Petrous apex	1	0	1
Clivus	2	0	2
Temporomandibular joint	4	0	4
Floor of middle fossa	1	0	1
Posterior fossa	2	1	3
Foramen magnum	2	0	2

* Patients were included in more than one category.

TABLE 2: Soft tissue extension, number of patients

Sites of Soft Tissue Extension	Primary Temporal Bone Malignancy	Temporal Bone Carcinoma Secondary to Parotid Carcinoma	Total ^a
Parotid	5	4	9
Infratemporal fossa	3	1	4
Parapharyngeal	1	0	1
Glenoid fossa	4	0	4
Intracranial middle fossa	1	0	1
Intracranial posterior fossa	2	1	3
Lymph nodes	1	2	3

^a Patients were included in more than 1 category.

enocarcinoma of the temporal bone, showed inner ear involvement including labyrinth and internal auditory canal encroachment.

CT at bone algorithm can show bone erosion beyond the middle ear; tumor can spread from the middle ear inferiorly into the jugular fossa or carotid canal or posteriorly through the sinodural plate. Obstruction of the sigmoid sinus and encasement of the petrous internal carotid artery are better detected on MR than CT, because of the vascular signal void on preinfusion MR and flow enhancement of the sigmoid on postinfusion MR. A gradient-recalled acquisition in steady state sequence or MR angiography are options during MR for further evaluation of dural sinus and internal carotid artery. Encroachment of the internal carotid artery shown by CT or MR may necessitate four-vessel cerebral angiography with balloon test occlusion if carotid resection is needed.

Tumor can spread into middle cranial fossa either from the middle ear through the tegmen tympani or superiorly from the external auditory canal or glenoid fossa of temporomandibular joint. Although bone erosion of posterior fossa or floor of middle cranial fossa may be seen with either CT or MR, detection of bone destruction at those sites is more sensitive with CT because the hypointensity of dura is indistinguishable from hypointensity of cortical bone on MR. However, intracranial extension of tumor is best seen on postinfusion MR.

MR with and without infusion provides excellent delineation of soft-tissue tumor margins and infratemporal muscle infiltration. Sagittal and coronal planes are helpful to demonstrate contiguous involvement of petrous and mastoid bones, temporomandibular joint, infratemporal fossa, and

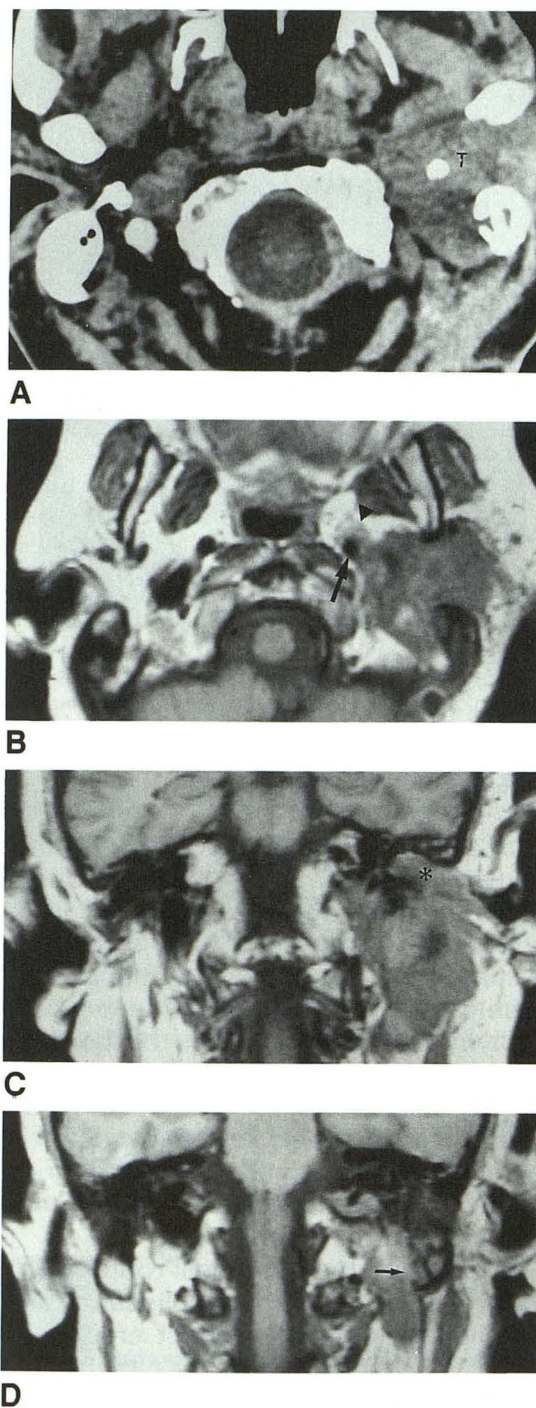


Fig. 7. Osteosarcoma with destruction of temporal bone and parotid infiltration.

A, CT preinfusion shows a mass (T) involving both superficial and deep lobes of parotid without clear delineation of anterior and medial tumor margins.

B, MR preinfusion (500/20) delineates tumor margins better than CT and shows encasement of the left internal auditory canal (arrowhead) by parapharyngeal extension (arrowhead).

C and D, MR (450/20) shows temporal bone destruction at the external auditory canal (C) and the middle ear (*) and mastoid (D) (arrow). Infratemporal extension.

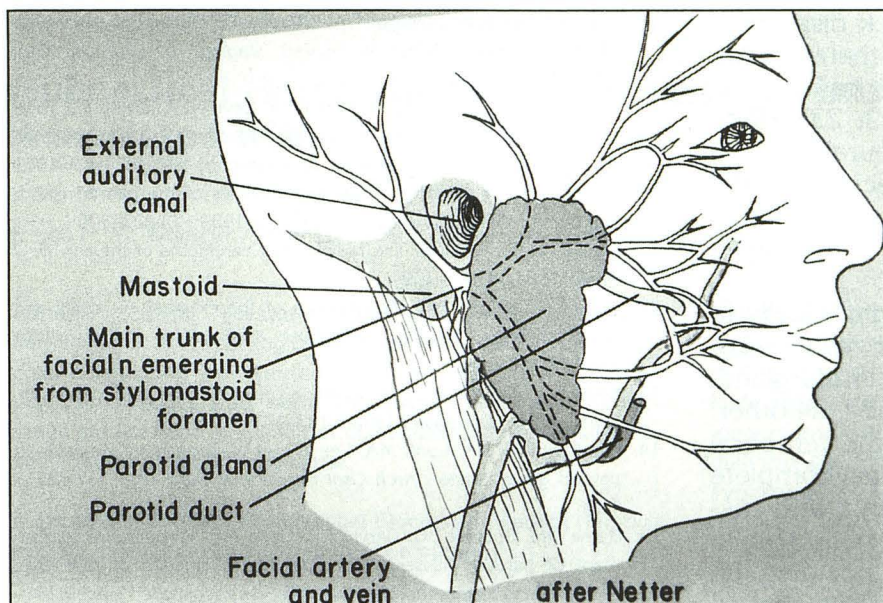


Fig. 8. The parotid gland lies anterior to the external auditory canal and mastoid process, and inferior to the external auditory canal. The pathway of the facial nerve extends from the stylomastoid foramen, proceeds anterolateral to the digastric muscle and lateral to styloid process, and enters the parotid gland, where it lies lateral to retro-mandibular vein.

parotid gland. Evaluation of tumor infiltration of the parotid gland by temporal bone malignancy requires specific attention to the parotid gland on MR scan in three planes, or by soft-tissue CT of the parotid gland in coronal and axial planes. The small number of patients in our study does not permit evaluation of whether MR or soft-tissue CT is better to detect parotid infiltration.

With respect to temporal bone malignancy secondary to parotid mass, high-grade aggressive parotid tumors usually have irregular or poorly defined margins, seen in all of our malignant parotid lesions (15, 16). Although some CT and MR features may be used to attempt to differentiate between malignant and benign parotid disease, it is not possible to predict histology correctly in a substantial number of cases (16, 17). Signal intensities of parotid malignancies were low on T1-weighted sequences. Although Som found consistently low signal intensity on T2-weighted images of high-grade parotid carcinoma (10), other authors have reported variable signal intensity on T2-weighted sequences (17). Our cases displayed variability in signal intensity on T2-weighted images, more often hypointense, but sometimes inhomogeneous or hyperintense. All parotid tumors, primary or recurrent to temporal bone, showed MR enhancement, ranging from inhomogeneous to densely enhancing. In particular, the parotid adenoid cystic carcinoma recurrent to the temporal bone showed dense homogeneous enhancement.

Parotid tumors invading the temporal bone can cause bone erosion, usually of the mastoid tip or

stylomastoid foramen. Perineural extension along the facial nerve can erode the bone around the stylomastoid foramen or can enlarge the facial nerve canal within the temporal bone.

Treatment and Prognosis of Primary Temporal Bone Malignancy

Treatment of carcinoma of the temporal bone is largely surgical, often combined with postoperative radiation therapy (12, 18–21). Some surgeons include either a superficial parotidectomy or total parotidectomy for temporal bone carcinoma and track the facial nerve from the stylomastoid foramen into the parotid gland. Surgical resection of basal cell carcinoma has an excellent prognosis, but there is dismal 5-year survival with squamous cell carcinoma of temporal bone. Predictors of poor survival include extensive tumor, middle ear involvement, facial nerve paralysis, and cervical or periparotid lymphadenopathy. There is a high rate of postoperative local recurrence of squamous cell carcinoma and little chance for cure when tumor is left behind at the time of surgery, so accurate preoperative radiologic assessment of temporal and extratemporal tumor extent is essential.

Treatment and Prognosis of Parotid Carcinoma with Spread to Temporal Bone

Treatment for those parotid malignancies with extraparotid extension (grade IV) to temporal bone and skull base is radical parotidectomy,

subtotal petrosectomy, possible neck dissection, and routine postoperative radiation therapy (22). Recurrences are frequent in parotid cancer, the majority being local recurrences (22, 23). High-grade lesions and tumors with perineural invasion recur more frequently (14). Once recurrence develops, treatment by any means is not very effective, with survival being only a few years (10, 14, 24–27).

In summary, it is important radiographically to recognize the close relationship between malignancies of the temporal bone and parotid gland, because either may secondarily invade the other. Suspicion of malignancy in either the temporal bone or the parotid gland necessitates complete imaging of the other structure. Patients with suspected malignancy of the temporal bone should have either CT or MR examinations including the parotid gland. In patients with suggested parotid malignancy, thin-cut high-resolution CT of the temporal bone is needed for complete evaluation. Sites of bone erosion at the temporal bone and skull base were best seen on CT at bone algorithm. MR with and without infusion provides excellent delineation of soft-tissue tumor margins, muscle infiltration, intracranial extension, and vascular encasement.

References

- Goodwin WJ, Jesse RH. Malignant neoplasms of the external auditory canal and temporal bone. *Arch Otolaryngol* 1980;106:675–679
- Lloyd GAS, Phelps PD. The investigation of petro-mastoid tumors by high resolution CT. *Br J Radiol* 1982;55:483–491
- Arriaga M, Curtin H, Hirsch BE, Takahashi H, Kamerer DB. Staging proposal for external auditory meatus carcinoma based on preoperative clinical examination and computed tomography findings. *Ann Otol Rhinol Laryngol* 1990;99:714–721
- Baker SR, Latack JT. Magnetic resonance imaging of the head and neck. *Otolaryngol Head Neck Surg* 1986;95:82–89
- Bird CR, Hasso AN, Stewart CE, Hinshaw DB, Thompson JR. Malignant primary neoplasms of the ear and temporal bone studied by high-resolution computed tomography. *Radiology* 1983;149:171–174
- Olsen KD, DeSanto LW, Forbes GS. Radiographic assessment of squamous cell carcinoma of the temporal bone. *Laryngoscope* 1983;93:1162–1167
- Russell EJ. The radiologic approach to malignant tumors of the head and neck, with emphasis on computed tomography. *Clin Plast Surg* 1985;12:343–374
- Clark LJ, Narula AA, Morgan DAL, Bradley PJ. Squamous carcinoma of the temporal bone: a revised staging. *J Laryngol Otol* 1991;105:346–348
- Matsuba HM, Thawley SE, Devineni VR, Levine LA, Smith PG. High grade malignancies of the parotid gland: effective use of planned combined surgery and irradiation. *Laryngoscope* 1985;45:1059–1063
- Som PM, Biller HF. High grade malignancies of the parotid gland: Identification with MR imaging. *Radiology* 1989;173:823–826
- Phelps PD, Lloyd GAS. The radiology of carcinoma of the ear. *Br J Radiol* 1981;54:103–109
- Kinney SE, Wood BG. Malignancies of the external ear canal and temporal bone: surgical techniques and results. *Laryngoscope* 1987;97:158–164
- Sone S, Higashihara T, Morimoto S, et al. CT of parotid tumors. *AJNR Am J Neuroradiol* 1982;3:143–147
- Frankenthaler RA, Luna MA, Lee SS, et al. Prognostic variables in parotid gland cancer. *Arch Otol Head Neck Surg* 1991;117:1251–1256
- Byrne NM, Spector JG, Garvin CF, Gado MH. Preoperative assessment of parotid masses: A comparative evaluation of radiologic techniques to histopathologic diagnosis. *Laryngoscope* 1989;99:284–292
- Vogl TJ, Dresel SHJ, Spath M, et al. Parotid gland: plain and gadolinium-enhanced MR imaging. *Radiology* 1990;177:667–674
- Freling NJM, Molenaar WM, Vermey A, et al. Malignant parotid tumors: Clinical use of MR imaging and histologic correlation. *Radiology* 1992;185:691–696
- Sinha PP, Aziz HI. Treatment of carcinoma of the middle ear. *Radiology* 1978;126:485–487
- Graham MD, Sataloff RT, Kemink JL, Wolf GT, McGillicuddy JE. Total en bloc resection of the temporal bone and carotid artery for malignant tumors of the ear and temporal bone. *Laryngoscope* 1984;94:528–533
- Gacek RR, Goodman M. Management of malignancy of the temporal bone. *Laryngoscope* 1977;87:1622–1634
- Izquierdo R, Origiano TC, Al-Mefty O, Leonetti JP, Anderson DE, Reichman OH. Use of vascularized fat from the rectus abdominis myocutaneous free flap territory to seal the dura of basicranial tumor defects. *Neurosurgery* 1993;32:192–197
- Johns ME. Parotid cancer: a rational basis for treatment. *Head Neck Surg* 1980;3:132–144
- Schantz SP, Potter JR. Primary parotid cancer: factors influencing recurrence. *Am Surg* 1983;49:477–482
- Kagan AR, Nussbaum H, Handler S, et al. Recurrences from malignant parotid salivary gland tumors. *Cancer* 1976;37:2600–2604
- Theriault C, Fitzpatrick PJ. Malignant parotid tumors. *Am J Clin Oncol* 1986;9:510–516
- Spiro RH, Armstrong J, Harrison L, Geller NL, Lin SY, Strong EW. Carcinoma of the major salivary glands. *Arch Otol Head Neck Surg* 1989;115:316–321
- Spitz MR, Batsakis JG. Major salivary gland carcinoma. *Arch Otolaryngol* 1984;110:45–49