



## Discover Generics

Cost-Effective CT & MRI Contrast Agents



FRESENIUS  
KABI

WATCH VIDEO

# AJNR

## CT of sebaceous adenoma of the parotid gland.

W C Shen, P C Kwan, Y J Ho and S K Lee

*AJNR Am J Neuroradiol* 1994, 15 (7) 1265-1266

<http://www.ajnr.org/content/15/7/1265>

This information is current as  
of June 5, 2025.

# CT of Sebaceous Adenoma of the Parotid Gland

Wu-Chung Shen, Po-Cheung Kwan, Yung-Jen Ho, San-Kan Lee

**Summary:** We report a large sebaceous adenoma of the parotid gland. CT showed soft-tissue mass in the lateral portion of the adenoma corresponding to the histologic finding of proliferation of sebaceous glands and fibrous stromal tissue. There were numerous fatty cysts (-65Hu). Some of the cystic component ruptured, and CT demonstrated leaking of fatty material into the parapharyngeal space.

**Index terms:** Adenoma; Salivary glands, computed tomography; Salivary glands, neoplasms

Sebaceous adenoma originating in a salivary gland is rare (1–8). Most previously reported cases included microscopic findings (1–7). One report cited computed tomography (CT) findings of a nodular mass in the parotid gland, which was considered indistinguishable from other adenomas or cysts (8). Herein we report a sebaceous adenoma originating in the parotid gland that underwent cystic fatty changes. The CT findings reflected the pathologic picture.

## Case Report

A 39-year-old man reported a progressively enlarging mass over the right infraauricular area for 6 months. There was no fever, pain, or tenderness. Physical examination showed a soft mass in the region of the right parotid gland. All laboratory findings were normal.

CT was done with 4-mm sections and intravenous administration of iodinated contrast medium. It disclosed a heterogeneous-density lesion in the superficial lobe of the right parotid gland (Fig 1). The majority of the lesion appeared fatty (-65Hu), and there was soft tissue mixed with fatty cysts in the lateral portion of the lesion. The fatty part extended medially into the parapharyngeal space.

During surgery, a lobulated tumor mass with cystic content measuring about 5 x 6 x 4 cm in size was noted in the superficial lobe of the right parotid gland. Fatty material was seen to have leaked into the deep lobe and the parapharyngeal space. The tumor was well encapsulated and easy to remove. The leaked fatty material was aspirated. The tumor had a well-defined margin and a greasy yellow appearance.

Microscopically, the tumor was composed of a proliferation of sebaceous glands of which a large number had undergone cystic change caused by accumulation of secreted sebaceous material. Some of the cystic component of the tumor had ruptured. The sebaceous material from the ruptured cyst infiltrated the parenchyma of the parotid gland and caused foreign body reaction and fibrosis. The residual ductal elements and the normal fatty infiltration of the parotid gland are still present (Fig 2). Nineteen months later, follow-up CT showed no residual or recurrent adenoma and no fatty material in the parapharyngeal space (Fig 3).

## Discussion

Sebaceous glands are sometimes found in the normal salivary glands (9, 10) or in the normal salivary gland tissue adjacent to a tumor (4, 9, 10). Meza-Chavez studied 100 cases of normal parotid glands obtained at autopsy and found that 28 (28%) contained sebaceous glands (9). However Linhartova found that only 10.6% of the normal parotid glands contained sebaceous glands (5 of 47 normal glands) (10). Embryologically the epithelium of the ducts of parotid gland is a derivative of the oral ectoderm and thus possesses the potential for forming sebaceous glands like the epithelium of the epidermis. Sebaceous gland foci occur particularly in the terminal duct system of the parotid gland (11).

Although sebaceous glands in the salivary gland are not uncommon, the incidence of primary sebaceous tumor in the salivary gland is low. In our own series of 156 salivary gland tumors, only 1 case was sebaceous adenoma. Sebaceous neoplasms in the salivary gland can be classified histologically into adenoma and carcinoma and sebaceous differentiation (normal sebaceous cells without metaplasia) into other tumors; the adenoma can be further subclassified into sebaceous adenoma and lymphadenoma

Received May 14, 1992; accepted after revision February 22, 1993.

From the Departments of Radiology (W.-C.S., Y.-J.H., S.-K.L.) and Pathology (P.-C.K.), Taichung Veterans General Hospital, Taiwan.

Address reprint requests to Wu-Chung Shen, MD, Section of Neuroradiology, Department of Radiology, Taichung Veterans General Hospital, Taichung, Taiwan, Republic of China.

AJNR 15:1265–1266, Aug 1994 0195-6108/94/1507-1265 © American Society of Neuroradiology



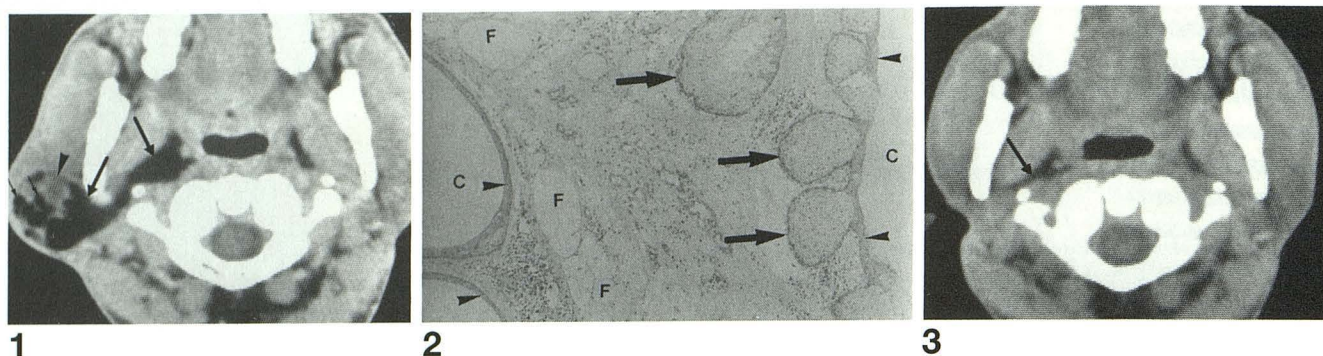


Fig 1. Preoperative postcontrast CT scan reveals a tumor mass in the right parotid gland. The lateral portion of the tumor is the sebaceous adenoma (arrowhead), which is composed of soft tissue masses, corresponding to the histologic findings of hyperplastic sebaceous glands and fibrous stroma, and multiple cystic lesions with fatty content, corresponding to the cystic parts (small arrow) with inclusion of fatty material. The medial portion of the lesion shows homogeneous fatty density (-65Hu) (large arrows). This represents sebaceous material leaking from the cystic parts of the adenoma. The fatty material extends medially to the parapharyngeal space.

Fig 2. Microscopic examination of surgical specimen (hematoxylin and eosin stain,  $\times 80$ ). The residual ductal elements and the normal fatty infiltration (F) of the parotid gland are present in the central portion. There are proliferations of sebaceous glands (large arrows) and numerous cystic parts (C) of variable size. The cystic parts are lined with squamous epithelium (arrowheads). The fatty sebaceous material in the cysts was washed out during preparation of the specimen.

Fig 3. Follow-up CT was performed 19 months after surgery. There is no residual or recurrent adenoma, and the fatty tissue in the parapharyngeal space (arrow) has returned to normal.

(5, 6). Of 20 cases of sebaceous adenomas arising from the salivary glands (1–8), most were in the parotid gland (13 cases), and others were in the minor salivary glands or Stensen's duct of the buccal mucosa (4 cases), in the submandibular gland (2 cases), or in a lower molar (1 case). The ages of the patients ranged from 22 to 90 years, most in fifth and sixth decades, and male predominance was noted. Tumor size ranged from 0.4 to 3 cm in diameter. The tumors were commonly well encapsulated or sharply circumscribed and varied in color (grayish white, pinkish white, or yellowish gray). Histologically, many tumors revealed a microcystic appearance with abundant sebaceous glands. All the neoplasms were embedded in a fibrotic stroma with marked oncocyctic metaplasia.

The CT finding of the sebaceous adenoma in Dillon's report was a cystlike tumor similar to Warthin tumor, inflammatory cyst, or first branchial cleft cyst (8), but they did not discuss the histology of their case. In our case, the soft tissue part of the lesion was mainly in the lateral portion, histologically composed of proliferations of sebaceous glands and fibrous stroma. Some of these glands had cystic change indicating active secretion of sebaceous material by the sebaceous glands. Some of the fatty material leaked from the ruptured cysts, so there was abundant fatty material in the medial part of the lesion and in the parapharyngeal space (Fig 1).

Most sebaceous adenomas are solid, although occasionally cystic change may be seen

(5). Our case was found in conjunction with cysts of various sizes. The differential diagnosis is lipoma. Lipoma of the parotid gland is also rare, making up about 1% of all parotid gland tumors (8). Histologically, lipoma arises from adipose cells (11), and there is homogeneous fatty density demonstrated on CT (8).

## References

1. Albores-Saavedra J, Morris AW. Sebaceous adenoma of the submaxillary salivary gland. *Arch Otolaryngol* 1963;77:500–503
2. Miller AS, McCrea MW. Sebaceous gland adenoma of the buccal mucosa: report of a case. *J Oral Surg* 1968;26:593–595
3. Epker BN, Henny FA. Intra-oral sebaceous gland adenoma. *Cancer* 1971;27:987–989
4. Bab IA, Ulmansky M. Simultaneously occurring salivary gland tumors of different types. *J Oral Surg* 1979;37:826–828
5. Gnepp DR. Sebaceous neoplasms of salivary gland origin: a review. *Pathol Annu* 1983;18:71–101
6. Gnepp DR, Brannon R. Sebaceous neoplasms of salivary gland origin: report of 21 cases. *Cancer* 1984;53:2155–2170
7. Orlian AI, Salman L, Reddi T, Yamane GM, Chaudhry AP. Sebaceous adenoma of the oral mucosa. *J Oral Med* 1987;42:38–39
8. Dillon WP, Mancuso AA. The oropharynx and nasopharynx. In: Newton TH, Hasso AN, Dillon WP, eds. *Computed Tomography of the Head and Neck*. New York: Raven Press, 1988;10:56–59
9. Meza-Chavez L. Sebaceous glands in normal and neoplastic parotid glands possible significance of sebaceous glands in respect to the origin of tumors of the salivary glands. *Am J Pathol* 1949;25:627–645
10. Linhartova A. Sebaceous glands in salivary gland tissue. *Arch Pathol* 1974;98:320–324
11. Seifert G, Mielhke A, Haubrich J, Chilla R. *Disease of the Salivary Glands*, 1st ed. New York: Georg Thieme Verlag Thieme, Inc, 1986:106