



Discover Generics

Cost-Effective CT & MRI Contrast Agents

 FRESENIUS
KABI

[WATCH VIDEO](#)

AJNR

MR findings in seven patients with organic mercury poisoning (Minamata disease).

Y Korogi, M Takahashi, J Shinzato and T Okajima

AJNR Am J Neuroradiol 1994, 15 (8) 1575-1578

<http://www.ajnr.org/content/15/8/1575>

This information is current as
of June 5, 2025.

MR Findings in Seven Patients with Organic Mercury Poisoning (Minamata Disease)

Yukunori Korogi, Mutsumasa Takahashi, Jintetsu Shinzato, and Toru Okajima

PURPOSE: To study the long-term MR findings in seven patients with Minamata disease.

METHODS: All patients examined were affected after eating daily considerable amounts of the methylmercury-contaminated seafoods from 1955 through 1958 and showed typical neurologic findings. T1- and T2-weighted images were obtained in axial, coronal, and sagittal sections.

RESULTS: The visual cortex, the cerebellar vermis and hemispheres, and the postcentral cortex were significantly atrophic. The visual cortex was slightly hypointense on T1-weighted images and hyperintense on T2-weighted images, probably representing the pathologic changes of status spongiosus. **CONCLUSION:** MR demonstrated the lesions, located in the calcarine area, cerebellum, and postcentral gyri, which are probably related to three of the characteristic manifestations of this disease: the constriction of the visual fields, ataxia, and sensory disturbance, respectively.

Index terms: Mercury; Nervous system, diseases; Brain, magnetic resonance

AJNR Am J Neuroradiol 15:1575-1578, Sep 1994

Late in 1953, a mysterious illness began to affect the inhabitants, especially fishermen and their families, around Minamata Bay located near the coast in southwestern Kyushu in Japan (1). By 1956, the outbreak had reached epidemic proportions and the illness was named *Minamata disease*. It was found that the patients had eaten large amounts of fish and shellfish. Also, a high content of mercury was found in organs of human autopsy cases. This mercury resulted from the effluent of a new industrial plant, which had been producing vinyl chloride, acetaldehyde, and its derivatives on a large scale since 1952 (1). Minamata disease, one of the first outbreaks of methylmercury poisoning in the world, is a neurologic illness caused by ingestion of contaminated seafood (2). The

clinical manifestations are characterized by sensory disturbance, concentric constriction of the visual fields, and ataxia, reflecting the cerebral and cerebellar lesions. Patients with severe cases died after subacute or chronic clinical courses; many patients have survived. We examined the long-term magnetic resonance (MR) findings of seven patients who are survivors of Minamata disease.

Patients and Methods

Patients

MR images of seven patients with Minamata disease, ages 46 to 59 years (mean age, 52.0 ± 5.3 years), four men and three women, were evaluated in correlation with neurologic findings. All patients were affected from 1955 through 1958, with the characteristic clinical features including sensory disturbance, concentric constriction of the visual fields, and ataxia; their clinical findings have been periodically followed for more than 30 years. The clinical manifestations of the patients are summarized in the upper part of the Table. Although case 3 had shown concentric constriction of the visual fields at least until 1969, the visual fields were almost normal at the time of examination. All cases were verified as methylmercury poisoning epidemiologically, caused by daily eating of considerable amounts of seafood caught in Minamata Bay.

Received September 14, 1993; accepted after revision January 21, 1994.

This study was partly supported by research grants from the Environment Agency and the Government of Kumamoto Prefecture, Japan.

From the Department of Radiology, Kumamoto University School of Medicine, Kumamoto, Japan (Y.K., M.T., J.S.); and the Third Department of Medicine, Medical College of Oita, Oita, Japan (T.O.).

Address reprint requests to Yukunori Korogi, MD, Department of Radiology, Kumamoto University School of Medicine, 1-1-1, Honjo, Kumamoto City, 860, Japan.

AJNR 15:1575-1578, Sep 1994 0195-6108/94/1508-1575

© American Society of Neuroradiology

Clinical manifestations and MR findings in patients with Minamata disease

Case Initials Age/Sex	1 Y.T. 59/M	2 Y.N. 58/M	3 T.H. 54/M	4 T.N. 52/F	5 T.S. 46/F	6 S.Y. 48/F	7 H.I. 46/M
Neurologic findings							
Constriction of visual fields	+	++	— ^a	++	++	++	++
Ataxia	+	++	+	+	++	+	+
Sensory disturbance	+	++	++	+	++	++	+
MR findings							
Atrophy							
Calcarine cortex	++	++	+	++	++	++	++
Postcentral gyrus	+	+	±	+	±	+	++
Cerebellar hemispheres	++	+	+	++	++	++	+
Cerebellar vermis	++	+	+	++	++	++	+
Brain stem	—	—	—	—	±	±	—

Note.— — indicates negative; ±, equivocal; +, mild; and ++, moderate to marked.

^a Previously, case 3 showed concentric constriction of the visual fields.

MR Unit and Techniques

The MR unit used was a 1.5-T superconductive type. T1-weighted images were obtained in axial, coronal, and sagittal sections using spin-echo (500–600/13/2 [repetition time/echo time/excitations]) or field-echo techniques (300/9/4, 90° flip angle), and T2-weighted images were obtained in axial, coronal, and sagittal sections using the spin-echo technique (2000–3000/80/1). The section thickness was 5 to 6 mm with a 1.0- to 1.2-mm intersection gap. The field of view was 25 cm, and the matrix size was 192 to 256 × 256. No patients were studied with contrast enhancement.

Results

The MR findings were essentially the same in the seven patients (Fig 1 and Table). However, there was some variability in degrees of atrophy of the cerebellar vermis and hemispheres, the calcarine cortex, and the postcentral gyrus.

Dilatation of the calcarine sulcus caused by atrophy of the calcarine cortex was clearly demonstrated on T1-weighted coronal and sagittal images (Figs 1A, C, and D). In case 3 the visual fields were normal at the time of study, and the calcarine sulcus was less atrophic than other patients. The calcarine cortex was slightly hypointense on T1-weighted images and hyperintense on T2-weighted images (Figs 1A and B). The parietooccipital sulcus was also dilated (Fig 1C). The central sulcus was dilated probably because of atrophy of the postcentral gyrus (Fig 1E). Signal intensities of the paracentral gyri was normal.

In the cerebellar vermis and cerebellar hemispheres, shrinkage of the folia and widening of the sulci were major findings, whereas the

cerebellar white matter was relatively spared. Neither T1- nor T2-weighted images showed any abnormal signal intensity areas within the cerebellum. The grade of cerebellar atrophy was poorly correlated with the severity of cerebellar signs. The brain stems and middle cerebellar peduncles were intact.

Discussion

There have been extensive reports on organic mercury poisoning in many countries (2–10). Hunter and Russell (3) reported a first human autopsy case of methylmercury poisoning in 1954. Minamata disease was the first outbreak of methylmercury poisoning in the world (2). Minamata disease was caused by ingestion of methylmercury-contaminated seafood of the Minamata Bay and its neighboring sea in Japan. In 1953, inhabitants of the area first showed evidence of the disease, and more than 2000 patients have been found. Typical neurologic findings in Minamata disease are sensory disturbance, concentric constriction of the visual fields, and cerebellar ataxia. These findings are consistent with the features of organic mercury poisoning first described by Hunter and Russell (3). In Iraq, about 6000 people were affected, and 500 died after mistakenly eating wheat seeds treated with mercury-containing fungicide (9, 10).

The pathologic lesions of the cerebrum are relatively severe in the calcarine, temporal, and postcentral cortices (1). Usually, the anterior regions of both calcarine areas are disturbed most severely, followed by the postcentral gyri.

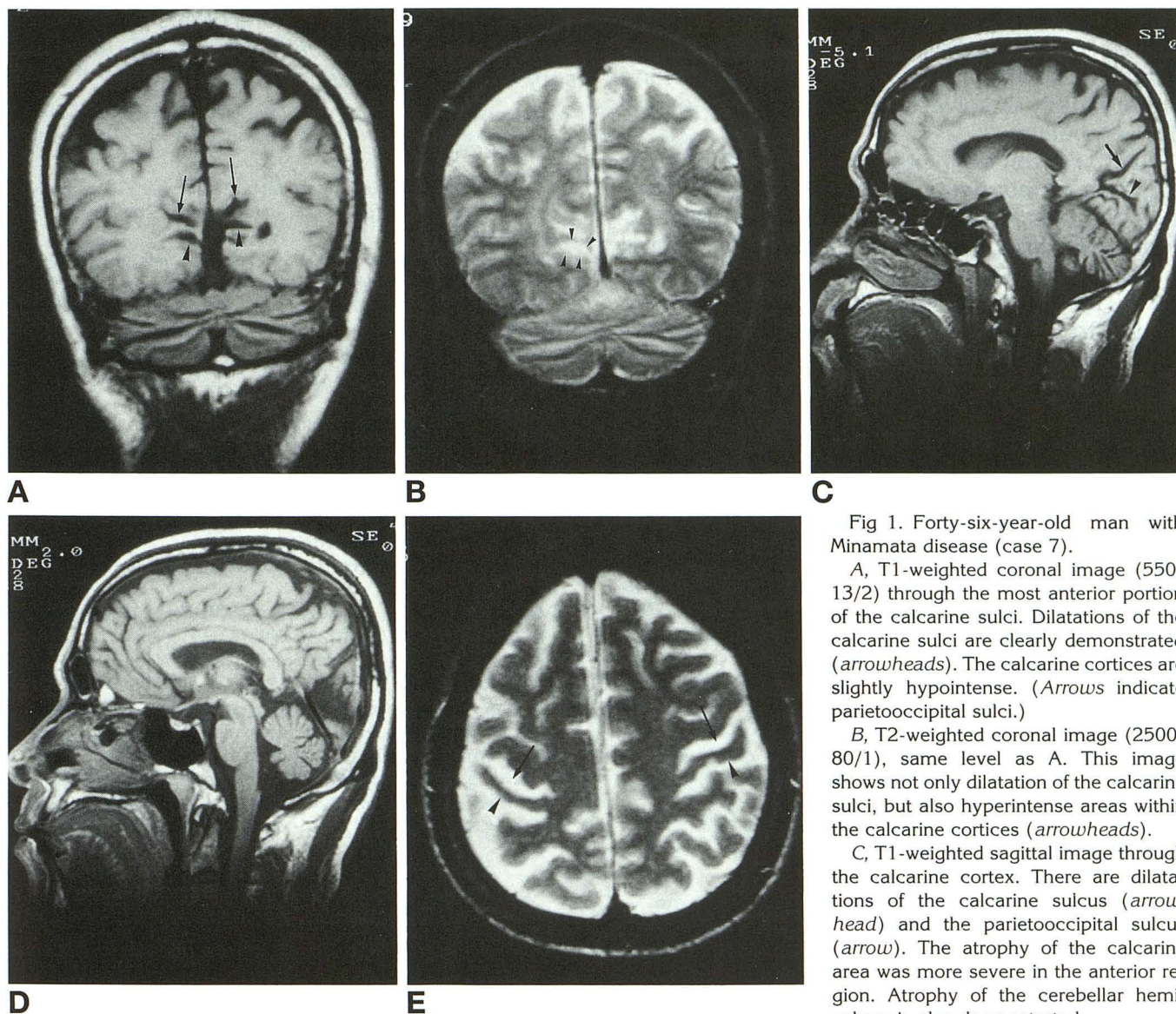


Fig 1. Forty-six-year-old man with Minamata disease (case 7).

A, T1-weighted coronal image (550/13/2) through the most anterior portion of the calcarine sulci. Dilatations of the calcarine sulci are clearly demonstrated (arrowheads). The calcarine cortices are slightly hypointense. (Arrows indicate parietooccipital sulci.)

B, T2-weighted coronal image (2500/80/1), same level as A. This image shows not only dilatation of the calcarine sulci, but also hyperintense areas within the calcarine cortices (arrowheads).

C, T1-weighted sagittal image through the calcarine cortex. There are dilatations of the calcarine sulcus (arrowhead) and the parietooccipital sulcus (arrow). The atrophy of the calcarine area was more severe in the anterior region. Atrophy of the cerebellar hemisphere is also demonstrated.

D, T1-weighted sagittal image through the midline. Atrophy of the cerebellar vermis is well demonstrated. The brain stem is almost normal.

E, T2-weighted axial image. There are dilatations of the central sulci (arrows) and atrophy of the postcentral gyri (arrowheads).

The normal cortical striation of Gennari is usually destroyed. Disintegration and loss of neurons are basic findings on microscopic examination, and in moderate to severe cases, the neurons in the calcarine area almost always disappear entirely (status spongiosus) (1). The loss of neurons considerably varies in different fields of the cerebral cortex. On MR images, the calcarine sulci and central sulci were significantly dilated, reflecting the atrophy of the visual cortex and postcentral cortex, respectively. The sagittal MR views clearly depicted the unique location of calcarine involvement (Fig

1C). Long T1 and T2 relaxation time within the calcarine cortex may represent status spongiosus.

In the cerebellum, there is gross atrophy of both vermal and hemispheric folia macroscopically. The most characteristic lesion is preferential disintegration after diffuse loss of the granular cells; the Purkinje cells were, in general, spared (the so-called granular type of cerebellar atrophy) (1). These changes are most advanced in the depths of the sulci. The cortex at the surface of the cerebellum is relatively spared. MR demonstrated the macroscopic

pathologic changes of the cerebellar vermis and hemispheres in detail. There has been no good explanation why the methylmercury poisoning preferentially involves the calcarine area and the cerebellum.

Valk and van der Knapp reported an interesting case of intoxication with mercury-containing fungicide, in which T2-weighted gradient-echo MR images demonstrated low signal intensity in the cerebellum and occipital lobes (11). The MR signal intensities might have been related to local inhomogeneity of the magnetic field caused by the mercury itself. Abnormal signals related to mercury were not observed in our patients, probably because of their chronic clinical courses.

Matsumoto et al (12) reported the computed tomographic findings of Minamata disease, describing atrophy of the occipital lobe and the cerebellum. However, MR findings of Minamata disease have not been reported yet. MR was apparently superior to computed tomography for demonstration of fine anatomic structures and pathologic changes, such as the localized degeneration in the cerebellum and occipital lobe. In conclusion, MR demonstrated macroscopic pathologic changes of the cerebellum and the cerebrum in detail. The lesions, located in the calcarine area, the cerebellum, and post-central gyri, are probably related to three of the

characteristic manifestations of this disease: the constriction of the visual fields, ataxia, and sensory disturbance, respectively.

References

1. Takeuchi T, Morikawa N, Matsumoto H, Shiraishi Y. A pathologic study of Minamata disease in Japan. *Acta Neuropathol (Berl)* 1962;2:40-57
2. Tokuomi H, Okajima T, Kanai J, et al. Minamata disease. *World Neurol* 1961;2:536-545
3. Hunter D, Russell DS. Focal cerebral and cerebellar atrophy in a human subject due to organic mercury compounds. *J Neurol Neurosurg Psychiatry* 1954;17:235-241
4. Engelson G, Herner T. Alkyl mercury poisoning. *Acta Paediatr Scand* 1952;41:289-294
5. Jalili MA, Abbasi AH. Poisoning by ethyl mercury toluene sulphonanilide. *Br J Int Med* 1961;18:303-308
6. Haq IU. Agrosan poisoning in man. *Br Med J* 1963;1:1579-1582
7. Ordonez JV, Carillo JA, Miranda M. Epidemiological study of an illness in the Guatemala highlands believed to be encephalitis. *Bol Of Sanit Panam* 1966;60:18-24
8. Snyder RD. Congenital mercury poisoning. *New Engl J Med* 1971;284:1014
9. Bakir F, Damluji SF, Amin-Zaki L, et al. Methyl mercury poisoning in Iraq. *Science* 1973;181:230-240
10. Rustam H, Hamdi T. Methyl mercury poisoning in Iraq. *Brain* 1974;97:511-520
11. Valk J, van der Knaap MS. Mercury intoxication. In: Valk J, van der Knaap MS, eds. *Magnetic Resonance of Myelin, Myelination, and Myelin Disorders*. Berlin: Springer-Verlag. 1989:270-271
12. Matsumoto SC, Okajima T, Inayoshi S, Ueno H. Minamata disease demonstrated by computed tomography. *Neuroradiology* 1988;30:42-46