



Discover Generics

Cost-Effective CT & MRI Contrast Agents



FRESENIUS
KABI

WATCH VIDEO

AJNR

Just the artifacts, ma'am.

L E Ginsberg

AJNR Am J Neuroradiol 1994, 15 (8) 1590

<http://www.ajnr.org/content/15/8/1590.citation>

This information is current as
of June 5, 2025.

LETTER

Just the Artifacts, Ma'am

A 42-year-old woman was admitted with a history of severe headaches. She had normal head CT findings. To rule out central nervous system vasculitis, arteriography was performed. One of the lateral views from a common carotid injection (with vertebral reflux) had a very worrisome finding. A large aneurysmlike density was noted just above the distal carotid/basilar tip (Fig 1). Our index of suspicion for true disease was low because the "lesion" could not be seen on prior or subsequent images from the same run and could not be identified on the anteroposterior view. A subtraction of the offending image revealed a technologist's handprint on the film, with the palm print

causing the aneurysmlike artifact on the angiogram (Figs 2 and 3). (Of course it was easy to identify the offending technologist.)

We relate this as an interesting angiographic finding, though one not likely to result in misdiagnosis. Nonetheless, technologists should use caution to avoid touching films during processing. The increasingly widespread use of digital technique should eliminate this type of artifact.

Lawrence E. Ginsberg
Department of Diagnostic Radiology
MD Anderson Cancer Center
Houston, Tex

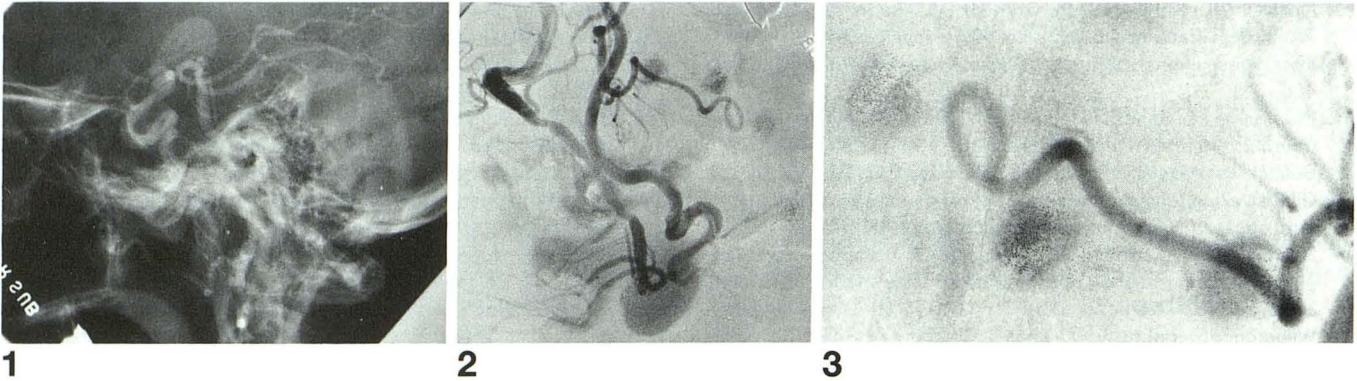


Fig 1. Lateral view, carotid arteriogram with vertebral reflux. Superior to the distal carotid and basilar tip is a large abnormal density mimicking an aneurysm.

Fig 2. Inverted subtraction view of Figure 1 showing handprint.

Fig 3. Close-up view of Figure 2 showing typical swirls of a fingerprint.