

Generic Contrast Agents

Our portfolio is growing to serve you better. Now you have a *choice*.



FRESENIUS
KABI

[VIEW CATALOG](#)

AJNR

Proton MR Spectroscopy for the Evaluation of Brain Injury in Asphyxiated, Term Neonates

A. James Barkovich, Karen Baranski, Daniel Vigneron, J. Colin Partridge, Daniel K. Hallam, Beatrice Latal Hajnal and Donna M. Ferriero

This information is current as of May 16, 2025.

AJNR Am J Neuroradiol 1999, 20 (8) 1399-1405

<http://www.ajnr.org/content/20/8/1399>

Proton MR Spectroscopy for the Evaluation of Brain Injury in Asphyxiated, Term Neonates

A. James Barkovich, Karen Baranski, Daniel Vigneron, J. Colin Partridge, Daniel K. Hallam, Beatrice Latal Hajnal, and Donna M. Ferriero

BACKGROUND AND PURPOSE: Neurologic and developmental outcomes of asphyxiated, term neonates are difficult to predict applying clinical or laboratory criteria. In this study, we investigated the association of MR spectroscopy (MRS) results with neurodevelopmental status at age 12 months.

METHOD: Thirty-one term neonates, who were enrolled in a prospective study of the utility of MR imaging for the determination of neurologic and developmental status, underwent single-voxel proton MRS of the basal nuclei and intervascular boundary zones. Ratios of lactate, choline, creatine, and *N*-acetylaspartate (NAA) peaks were calculated and tested for association with neuromotor scores and Mental Development Index of the Bayley Scores of Infant Development obtained at age 12 months.

RESULTS: Elevated lactate and diminished NAA were the most common findings in infants with neurologic and developmental abnormalities at age 12 months. Although many ratios had statistically significant associations with outcome ($P < .05$), the highest significance was obtained with lactate/choline ratios in the basal nuclei. A false-positive finding was seen in a patient who was born after a 36-week gestation period (high lactate/choline but normal neurodevelopmental status at 12 months) and in three patients with apparent watershed injury (high watershed lactate/choline but normal neurodevelopmental status at 12 months). A false-negative MRS finding (normal lactate/choline but abnormal outcome) was seen in a patient who had an apparent prenatal injury.

CONCLUSION: Proton MRS appears to be a useful tool for assessing brain injury in neonates who have suffered hypoxia or ischemia. Correlation with gestational age and imaging findings are essential for proper interpretation of the spectra. Patients with apparent watershed injuries may have normal neurodevelopmental status at age 12 months.

MR imaging has been found to be a useful tool for the early evaluation of brain injury in asphyxiated neonates (1–6). In addition, a number of studies (7–10) have suggested the potential utility of proton MR spectroscopy (MRS) for the evaluation of brain injury in asphyxiated neonates. Herein, we report the results of proton MRS of 31 neonates who were studied as part of an ongoing prospective study of the utility of MR imaging of neonates who have

had hypoxia or ischemia in the perinatal period. In addition, we correlate the MRS results with neurologic and developmental status at age 12 months.

Methods

Patient Data

As part of an ongoing study of the utility of neonatal brain MR imaging for the assessment of brain damage in asphyxiated, term neonates, 3361 consecutive, term neonates born at or transferred to our institution's intensive care nursery were screened using the following entry criteria: 1) umbilical-artery pH less than 7.1; 2) umbilical-artery base deficit greater than 10; and 3) 5-minute Apgar score less than or equal to 5. Patients fulfilling any one of these criteria were considered eligible for this study. Patients with suspected or confirmed congenital malformations or congenital infections and patients born prior to reaching a 36-week gestational age were excluded from the study. The protocol was approved by the Committee on Human Research. Participation in the study was voluntary; the infants were studied after informed consent from their parents was obtained.

Received August 7, 1998; accepted after revision December 14 1998.

From the Department of Radiology (A.J.B., K.B., D.V., D.K.H.), Department of Neurology (A.J.B., B.L.H., D.M.F.), and Department of Pediatrics (A.J.B., J.C.P., D.M.F.), University of California, San Francisco, CA.

Address reprint requests to A. James Barkovich, MD, Department of Radiology, University of California, 505 Parnassus Ave, San Francisco, CA 94143-0628.

Supported by National Institutes of Health grant 1P50NS32553-01 and National Institutes of Health Clinical Research Center Grant MO1RR01271.

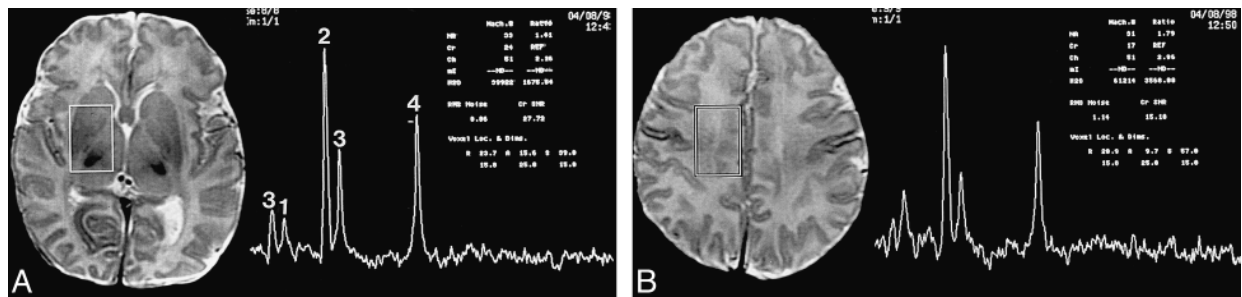


FIG 1. Location of voxels and normal neonatal proton spectra. A, The deep gray nuclei voxel includes most of the lentiform nucleus, the ventrolateral thalamus, and the posterior limb of the internal capsule. The spectrum reveals: 1) a small myoinositol peak, 2) a large choline peak, 3) two small creatine/phosphocreatine peaks, and 4) a medium-sized NAA peak. B, The watershed voxel includes primarily white matter from the intravascular boundary zone. Note that the NAA and choline peaks are relatively smaller in the less mature watershed zone than in the more mature deep gray nuclei. Minimal or no lactate was seen in most patients who were developmentally normal at 12 months.

Of the 3361 patients screened, 84 patients have been enrolled and studied by MR imaging, 63 have been studied by proton MRS. Of the 63, five died before the 12-month neurodevelopmental examinations; 31 completed the 12-month neurodevelopmental examinations; 24 are awaiting the 12-month neurodevelopmental examinations, and three are lost to follow-up. The 31 patients with completed 12-month examinations comprise the group reported in this article. Patient age at the time of the MR examination ranged from 1 to 11 days, with a mean age of 4.5 days. An attempt was made to image the patients as soon as they were stable enough to be transported safely to the MR scanner; thus, most patients (68%) were imaged during the first week of life. Nevertheless, factors such as patient instability, constraints of the MR schedule, availability of a physician to transport and monitor the infant, and delays in obtaining parental consent sometimes caused delays in performing MR imaging.

MR Data

In all patients, proton spectra were acquired in 2 voxels, one located in the deep gray matter nuclei, including the thalamus and lentiform nucleus, and the other in the frontal intervascular boundary zone (“watershed zone”) (Fig 1). The spectra were all acquired in conjunction with an MR imaging study of the brain that included 4-mm (1-mm “gap”) sagittal spin-echo (SE) (500/11/2 [TR/TE/excitations]) images, 4-mm (1-mm “gap”) axial SE (500/11/2) images, and 4-mm (2-mm “gap”) axial SE (3000/60,120/1) images through the entire brain. These images were used to guide the MRS volume selection, which was performed using the point-resolved spectroscopy (PRESS) technique to acquire the MR spectra from approximately 5.5 cm³ of tissue for both regions. The spectrum for each location was acquired using the PROBE (PROton Brain Exam, General Electric, Milwaukee, WI) sequence in under 5 minutes with a TR of 2 seconds, a TE of 288 milliseconds, and a total of 128 acquisitions. The MRS timings and voxel localization were chosen to maximize the detection of lactate and to minimize the spectral contamination from extracranial adipose tissues. The two spectra were obtained with the same parameters and voxel size centered on the deep gray matter and then on the white matter. In five of the patients who had doublet peaks centered at 1.31 ppm, a PRESS spectrum was acquired with a TR of 2 seconds, a TE of 135 milliseconds, and a total of 128 acquisitions to determine whether the doublet inverted. Inversion of the doublet was interpreted as a confirmation that the doublet represented lactate. After acquisition, the MRS data were transferred off-line and analyzed on a SPARC Workstation (Sun Microsystems, Mountain View, CA) equipped with software developed in-house for spectral quantitation. All of the spectra were analyzed by both

TABLE 1: Neuromotor scoring system

Score	Features
0	Normal
1	Abnormal tone or reflexes or primitive reflexes
2	Abnormal tone and reflexes
3	Decreased power in addition to tone or reflex abnormality
4	Cranial-nerve involvement in addition to any motor abnormality
5	Cranial-nerve involvement and spastic quadriplegia (tone, reflexes, and power affected)
6	Expired

a neuroradiologist and a basic scientist with extensive experience in MRS. The MRS data were Fourier-transformed and baseline-fitted; the peak areas were integrated for the choline, creatine, *N*-acetylaspartate (NAA), and lactate resonances. Peak-area ratios of lactate/choline, lactate/NAA and NAA/choline were calculated for each voxel.

Developmental Examinations

At age 12 months, the patients were examined by an experienced pediatric neurologist who was blinded to the results of the imaging studies and to the neonatal course of the infants. In a standard neurologic examination, the infants were graded by a score ranging from 0 to 6 (Table 1). In addition, neurodevelopment was assessed by administering the Mental Developmental Index (MDI) of the Bayley Scales of Infant Development II (BSID) (11).

Data Analysis

Statistical analysis was performed using Statistica-TMStatsoft (Statistica, Tulsa, OK). Predictor variables were the ratios of the MRS peaks (NAA/creatine, NAA/choline, lactate/creatine, lactate/choline, lactate/NAA, choline/creatine) in each voxel. Outcome variables included the results of the neuromotor examination and the MDI of the BSID. Association with neuromotor outcome was calculated using both numerical scores and using normal (score = 0), unclear (score = 1), mildly abnormal (score = 2 or 3), or severely abnormal (score = 4–6) scores as outcome variables. Association between ratios of MRS peaks with neurologic outcome (as measured by neurologic examination) and mental/cognitive outcome (as measured with the MDI of the BSID) was performed using Kruskal-Wallis analysis of variance by ranks.

TABLE 2: Correlation of MRS ratios with 1-year neuromotor scores

NM Score	0	1	2-3	5-6
N of patients	13	7	7	4
BG Lac/Cho	0.02 (0.06)	0.06 (0.03)	0.12 (0.06)	0.42 (0.24)
BG Lac/NAA	0.11 (0.08)	0.14 (0.09)	0.13 (0.09)	0.48 (0.16)
WS Lac/Cho	0.10 (0.07)	0.20 (0.11)	0.13 (0.10)	0.48 (0.22)
WS Lac/NAA	0.21 (0.11)	0.28 (0.16)	0.33 (0.27)	1.10 (0.5)

Note.—No patients had a score of 4, so this score is not listed in the table. Standard deviations are in parentheses. MRS indicates magnetic resonance spectroscopy; NM, neuromotor; N, number; BG, basal ganglia; Lac, lactate; Cho, choline; NAA, *N*-acetylaspartate; WS, watershed.

Results

Spectroscopy Findings

The most consistently noted abnormality on the spectra of our patients was the presence of a variably sized lactate doublet centered at 1.31 ppm; proof of this peak as lactate was established by observing the inversion of the doublet peaks in all five patients in whom this extra sequence was performed. The amount of lactate (determined by integration of the lactate doublet) was either very small or nonexistent in those patients who later had low neuromotor scores. In contrast, lactate levels were high in those patients with severe injuries or high neuromotor scores. Intermediate levels were found in those patients with neurologic examinations scored in the intermediate range (Table 2). The area under the NAA peaks was decreased in some patients who subsequently had neurodevelopmental impairment as compared with the NAA level in those patients in our series who had normal neonatal clinical courses and who developed normally. NAA diminution primarily was found in patients studied more than 3 days after birth.

In those patients with elevated lactate, the lactate level was increased in both the deep gray matter

voxel and in the watershed voxel (Figs 2 and 3). Patients with the deep gray matter pattern of injury (1, 2) on their accompanying imaging study had greater elevations of lactate in the deep gray matter than in the watershed region (Fig 2). Patients with the watershed pattern of injury on their imaging study (1, 2) had greater elevations of lactate in the watershed region than in the deep gray matter (Fig 3). Table 2 shows the high degree of association of many ratios of peak heights with clinical outcome. No new or unexpected peaks were seen on the MRS studies of any of the affected infants.

A very high association was seen between multiple MRS peak ratios (basal ganglia lactate/choline, lactate/NAA, and NAA/choline, watershed lactate/choline, lactate/NAA, and NAA/choline) and both the 12-month neuromotor score and the 12-month MDI (Table 3). For both outcome parameters, the strongest association was with the basal ganglia lactate/choline ratio.

Discussion

This study reveals highly significant associations between the results of proton MRS of asphyxiated infants performed in the early postnatal period and both neurologic and mental/cognitive status at age 12 months. Our findings support those of Penrice et al (8), Hanrahan et al (9), and Leth et al (10). Our findings also substantiate those of Shu et al (7) and those of Holshouser et al (12), and show that the presence of lactate in the brain of an injured neonate is a poor prognostic sign. We wish to point out, however, that we have seen minimal amounts of lactate in the watershed regions of neonates, particularly premature neonates, without any evidence of asphyxia or other brain damage. Therefore, the presence of a small amount of lactate in the neonatal brain is not, in itself, evidence of brain injury.

We found that lactate/choline ratios were more strongly associated with neurodevelopmental status

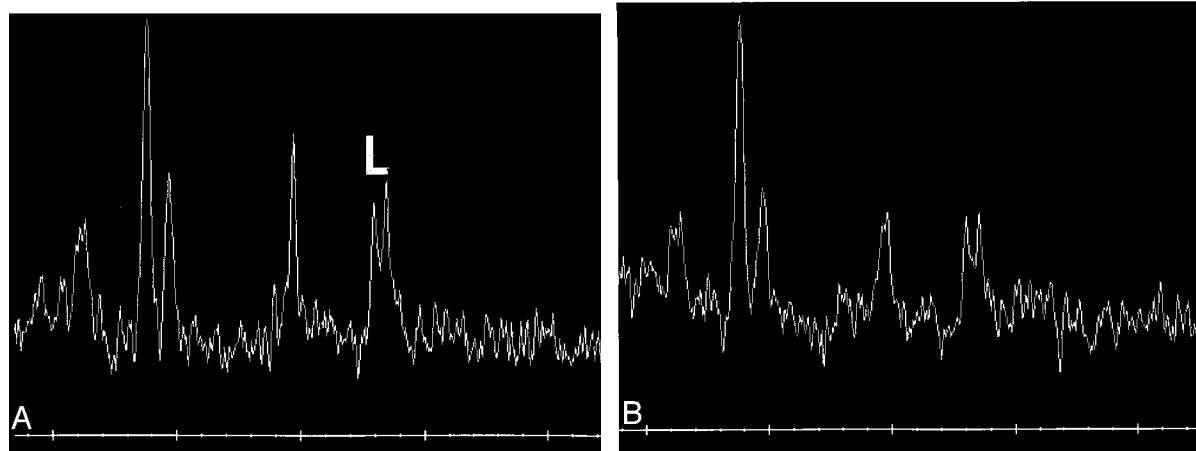


FIG 2. Neonate with basal nuclei pattern of injury.

A and B, The basal nuclei voxel (A) shows marked elevation of the lactate peak (L) centered at 1.31 ppm. In this acute phase, the relative sizes of the choline, creatine, and NAA peaks are normal. The watershed voxel (B) shows less elevated lactate (compare with A).

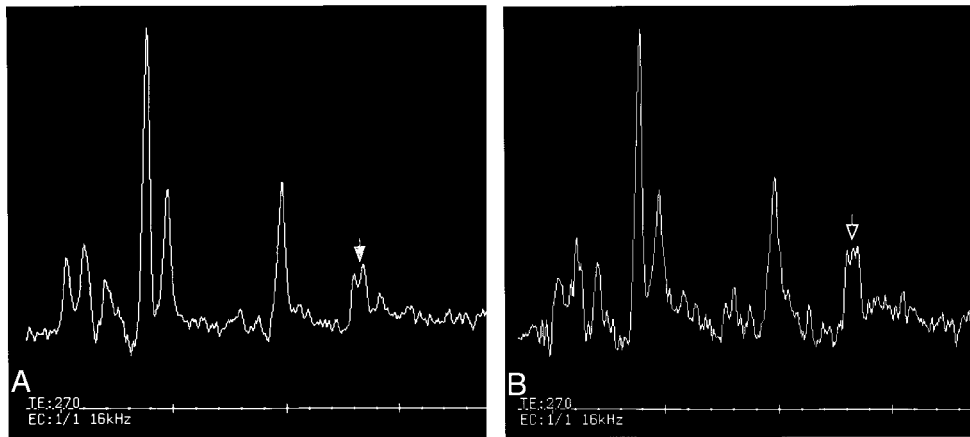


FIG 3. Neonate with watershed pattern of injury.

A and B, Both spectra show some lactate elevation at 1.31 ppm. The spectrum from the basal nuclei voxel (A), however, shows a relatively smaller elevation of lactate (*filled arrow*) than the spectrum (*open arrow*) from the watershed voxel (B).

TABLE 3: Significance of MRS with 12-month neurodevelopmental status

Significance of associations of MRS ratios with neuromotor outcome (Kruskal-Wallis)	
BG Lac/Cho: $P = .0001$	WS Lac/Cho: $P = .005$
BG Lac/NAA: $P = .0003$	WS Lac/NAA: $P = .01$
BG NAA/Cho: $P = .001$	WS NAA/Cho: $P = .001$
Significance of correlations of MRS ratios with cognitive outcome (Kruskal-Wallis)	
BG Lac/Cho: $P = .0003$	WM Lac/Cho: $P = .003$
BG Lac/NAA: $P = .001$	WM Lac/NAA: $P = .02$
BG NAA/Cho: $P = .004$	WM NAA/Cho: $P = .004$

Note.—MRS indicates magnetic resonance spectroscopy; BG, basal ganglia; Lac, lactate; Cho, choline; WS, watershed; NAA, *N*-acetylaspartate; WM, white matter.

at age 12 months than were NAA levels (NAA/choline, creatine/NAA, or lactate/NAA ratios), a finding that supports Cady's discovery that choline levels are reduced and lactate levels are increased in the deep gray matter of human infants with hypoxic-ischemic injury (13). Our results differed from those of Shu et al (7) and of Groenendaal et al (14), who found stronger associations with NAA levels. It seems likely that this difference is related to the timing of the MRS with respect to the hypoxic-ischemic event. The mean time from injury to MRS in our patients was 4.5 days; for the patients of Hanrahan et al it was less than 24 hours; and for those of Leth et al it averaged less than 5 days. In contrast, the patients of Shu et al experienced injury an average of more than 6 days before MRS and those of Groenendaal et al had a hypoxic/ischemic event an average of 7.1 days before imaging. It has been reported (8, 9) that the lactate level of the injured brain increases within the first 24 hours and remains elevated after 24 hours, presumably because of energy failure and the necessity to metabolize glucose anaerobically. Nevertheless, the NAA level does not diminish significantly until some time beyond 48 hours (15). The precise time

at which NAA begins to diminish in asphyxiated neonates is not precisely known. We postulate, therefore, that the reason the NAA was more significantly diminished in some previous studies is that those patients were further removed temporally from the hypoxic-ischemic event at the time of the MRS studies; therefore, the NAA had adequate time to diminish.

Another factor that might have contributed to the differences between our results and those of others (7) is the difference in the TE used to acquire the spectra. We used long TE to acquire our spectra. Lactate has a long T2 relaxation time and is, therefore, detected and quantitated well on long TE spectra. In contrast, Shu et al used a short (20 milliseconds) TE, which is not as accurate for the detection and quantitation of lactate.

Although the correlations between MRS ratios and neurodevelopmental status were excellent, we nonetheless found five patients whom we classified as "outliers" because their lactate/choline MRS ratios did not fall within 2 standard deviations of the mean ratio of their outcome group. These patients fell into three categories. The first category included one patient. This infant had a low NAA value and a high lactate value (Fig 4) in both the watershed and deep gray nuclei voxels. Nonetheless, the patient had normal 12-month neuromotor and cognitive scores. This patient was the youngest in our cohort, with a postconceptional age of 36 weeks, 3 days on the day of his scan and spectrum. It is known that premature infants normally have detectable lactate peaks and small NAA peaks and that the lactate diminishes and NAA increases as the infants reach term (8, 16, 17). Therefore, it is likely that the spectrum in this child, with its small NAA peak and detectable lactate peak, was normal for this postconceptional age. This false-positive result raises the important issue that one must know the postconceptional age of the patients before trying to interpret their spectra.

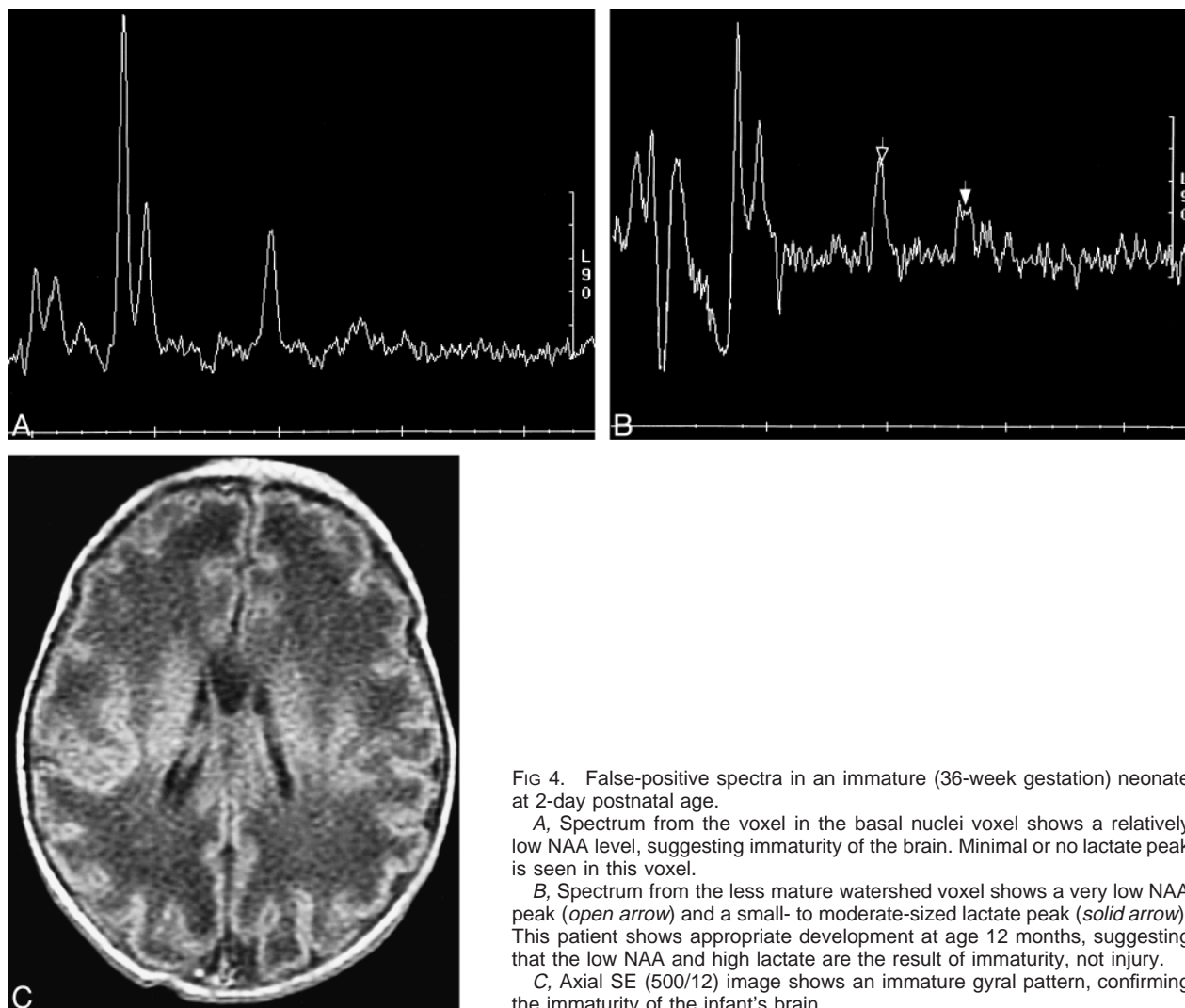


FIG 4. False-positive spectra in an immature (36-week gestation) neonate at 2-day postnatal age.

A, Spectrum from the voxel in the basal nuclei voxel shows a relatively low NAA level, suggesting immaturity of the brain. Minimal or no lactate peak is seen in this voxel.

B, Spectrum from the less mature watershed voxel shows a very low NAA peak (open arrow) and a small- to moderate-sized lactate peak (solid arrow). This patient shows appropriate development at age 12 months, suggesting that the low NAA and high lactate are the result of immaturity, not injury.

C, Axial SE (500/12) image shows an immature gyral pattern, confirming the immaturity of the infant's brain.

The second category also included only a single patient. This patient was abnormal in both neurologic and cognitive outcome despite normal lactate/choline ratios on the MRS performed on the second day of life (Figs 5A-B). Examination of the images of this patient revealed that the T1 shortening in the basal ganglia (indicative of hypoxic-ischemic injury) was in a globular configuration (Fig 5C) that has been described in patients only at times between 1 week and several months after injury (1). Thus, we suspect that the injury in this patient was prenatal, occurring at least (and probably more than) 8 days prior. We postulate that the lactate level would have been higher if the patient had been studied earlier in the post-injury period. Indeed, in the work of Leth et al (10), although the presence of lactate persisted, the lactate level always dropped on follow-up spectra performed weeks to several months after the injury. This false-negative result raises the important issue that the MRS cannot be interpreted without interpreting the MR imaging study in conjunction with it. It also raises the issue that we do not know the precise rate at which lactate levels return to normal after hypoxic-ischemic

injury in the neonate. Evidence suggests that, in certain patients, some lactate persists in injured regions for months to years (18). This is an important area for future research.

The final group of outliers included three children who had elevated watershed lactate levels (lactate/cholineCho ranging from 0.25 to 0.35, lactate/NAA ranging from 0.35 to 0.44) but had normal neurodevelopmental status at age 12 months. Interestingly, all three of these children had abnormal neuromotor scores (neuromotor scores of 2 or 3) at age 3 months. Imaging studies of all three at the time of the MRS showed edema in the watershed cortex, a finding highly suggestive of watershed injury. We postulate that the plasticity of the neonatal brain allows axons that normally would regress to take over the function of the axons damaged by the watershed injury and that this process takes place during the entire first year of life. Such plasticity would, perhaps, be expected to be greater in the white matter than in the basal ganglia and thalami, where alternative white matter pathways and alternative synaptic connections at birth may be fewer. It is well known, however, that some chil-

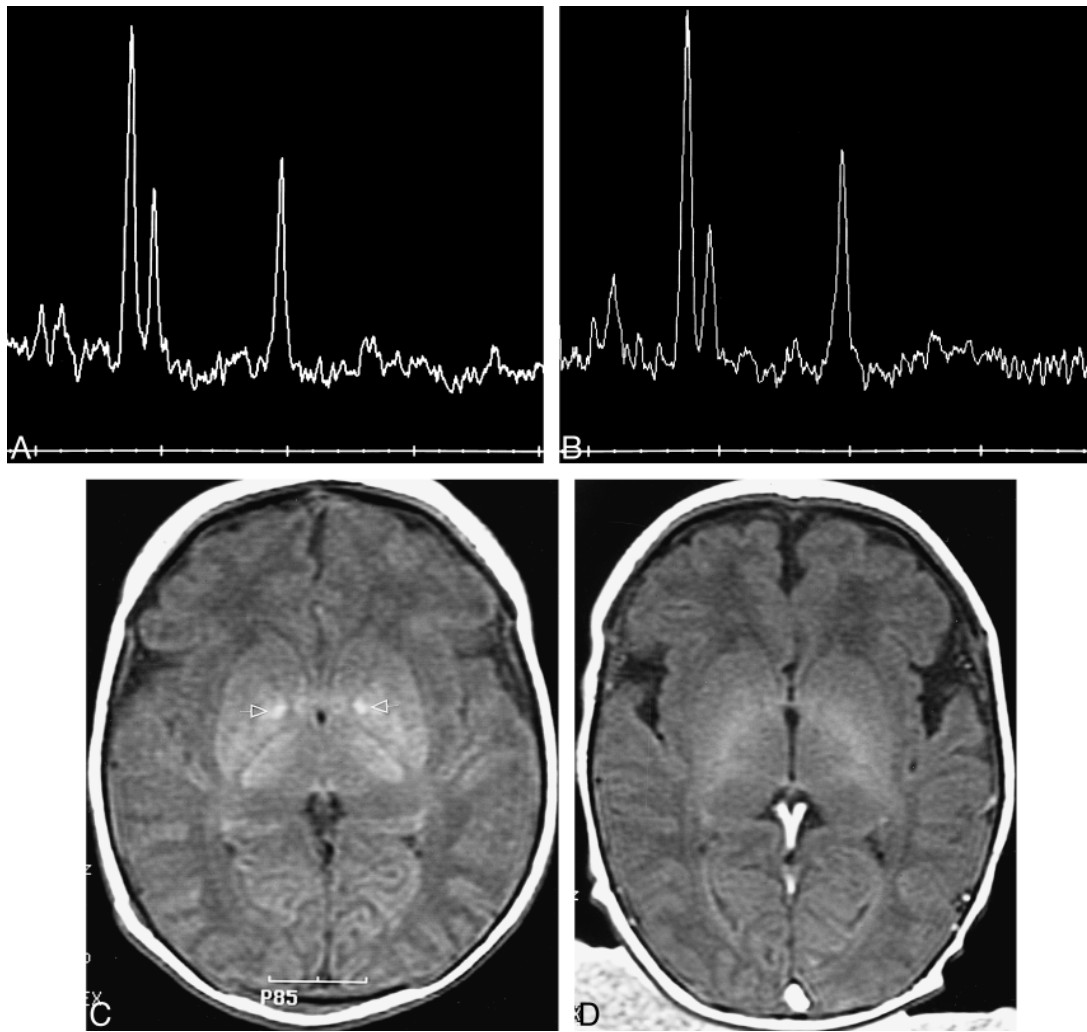


FIG 5. Normal spectra in a 2-day-old infant with neonatal encephalopathy and abnormal neurologic development at age 12 months.

A, Spectrum from voxel in the basal nuclei voxel shows normal NAA, choline, and creatine/phosphocreatine peaks (compare with Fig 1A). Minimal lactate (arrow) is seen at 1.31 ppm; this level of lactate was seen in many infants who developed normally and was interpreted as normal.

B, Spectrum from the watershed zone voxel also shows normal relative peak areas for choline, creatine/phosphocreatine, and NAA (compare with Fig 1B). No lactate is appreciated in this voxel.

C, Axial SE (500/12) image at the level of the basal nuclei shows globular hyperintensity (arrows) in the lentiform nuclei, indicative of an injury more than 1 week old.

D, Axial SE (500/12) image in a child with normal neonatal course and normal postnatal development shows the normal appearance of the neonatal basal nuclei. The hyperintensity in the vein of Galen and superior sagittal sinus is the result of inflow of unsaturated protons.

dren with white matter injury can be neurologically and cognitively normal in infancy and early childhood, only to manifest minor neurodevelopmental abnormalities and learning disabilities upon reaching school age (19–21). Therefore, it will be necessary to follow up our cohort of patients for a number of years before we can be confident of truly normal outcomes.

Conclusion

Our study suggests that proton MRS is a valuable tool in the assessment of asphyxiated neonates. We found statistically significant associations between results of proton MRS and both neurologic and cognitive status at age 12 months. Neverthe-

less, it is important to be aware of the postconceptional age of the infant and to correlate the MRS findings with MR imaging findings to interpret the spectra properly. Some patients with MR imaging and MRS findings of watershed injury have only subtle abnormalities on examination at age 12 months.

References

1. Barkovich AJ, Hallam D. Neuroimaging in perinatal hypoxic-ischemic injury. *MRDD Research Reviews* 1997;3:28–41
2. Barkovich AJ, Hajnal BL, Vigneron D, et al. Prediction of neuromotor outcome in perinatal asphyxia: evaluation of MR scoring systems. *AJNR Am J Neuroradiol* 1998;19:143–150
3. Baenziger O, Martin E, Steinlin M, et al. Early pattern recognition in severe perinatal asphyxia: a prospective MRI study. *Neuroradiology* 1993;35:437–442

4. Kuenzle C, Baenziger O, Martin E, et al. **Prognostic value of early MR imaging in term infants with severe perinatal asphyxia.** *Neuropediatrics* 1994;25:191–200
5. Martin E, Barkovich AJ. **Magnetic resonance imaging in perinatal asphyxia.** *Arch Dis Child* 1995;72:F62–F70
6. McArdle CB, Richardson C, Hayden C, et al. **Abnormalities of the neonatal brain: MR imaging part I. Intracranial hemorrhage.** *Radiology* 1987;163:387–394
7. Shu SK, Ashwal S, Holshouser BA, Nystrom G, Hinshaw Jr DB. **Prognostic value of 1-H MRS in perinatal CNS insults.** *Pediatr Neurol* 1997;17:309–318
8. Penrice J, Cady EB, Lorek A, et al. **Proton magnetic resonance spectroscopy of the brain in normal preterm and term infants and early changes after perinatal hypoxia-ischemia.** *Pediatr Res* 1996;40:6–14
9. Hanrahan JD, Sargentoni J, Azzopardi D, et al. **Cerebral metabolism within 18 hours of birth asphyxia: a proton magnetic resonance spectroscopy study.** *Pediatr Res* 1996;39:584–590
10. Leth H, Toft PB, Peitersen B, Lou HC, Henriksen O. **Use of brain lactate levels to predict outcome after perinatal asphyxia.** *Acta Paediatr* 1996;85:859–864
11. Bayley N. **The Bayley Scales of Infant Development II.** New York: New York Psychological Corporation 1993;
12. Holshouser BA, Ashwahl S, Luh GY, et al. **Proton MR spectroscopy after acute central nervous system injury: outcome prediction in neonates, infants, and children.** *Radiology* 1997;202:487–496
13. Cady EB. **Metabolite concentrations and relaxation in perinatal cerebral hypoxic-ischemic injury.** *Neurochem Res* 1996;21:1043–1052
14. Groenendaal F, Veenhoven EH, van der Grond J, Jansen GH, Witkamp TD, de Vries L. **Cerebral lactate and N-acetyl-aspartate/choline ratios in asphyxiated full-term neonates demonstrated in-vivo using proton magnetic resonance spectroscopy.** *Pediatr Res* 1994;35:148–151
15. Penrice J, Lorek A, Cady EB, et al. **Proton magnetic resonance spectroscopy of the brain during acute hypoxia-ischemia and delayed cerebral energy failure in the newborn piglet.** *Pediatr Res* 1997;41:795–802
16. Cady EB, Penrice J, Amess PN, et al. **Lactate, N-acetylaspartate, choline, and creatine concentrations, and spin-spin relaxation in thalamic and occipito-parietal regions of the developing human brain.** *Magn Res Med* 1996;36:878–886
17. Toft PB, Leth H, Lou HC, Pryds O, Henriksen O. **Brain metabolite concentrations in the developing brain estimated by proton magnetic resonance spectroscopy.** *J Magn Reson Med* 1994;30:674–680
18. Hanrahan JD, Azzopardi D, Cowan FM, Rutherford MA, Cox IJ, Edwards AD. **Persistent increases in cerebral lactate concentration after birth asphyxia.** *Pediatr Res* 1998;44:304–311
19. Fawer CL, Diebold P, Calume A. **Periventricular leucomalacia and neurodevelopmental outcome in preterm infants.** *Arch Dis Child* 1987;62:30–36
20. Calame A, Fawer C, Claeys V, Arrazola Z, Ducret S, Jaunin L. **Neurodevelopmental outcome and school performance of very-low-birthweight infants at 8 years of age.** *Eur J Pediatr* 1986;145:461–466
21. Volpe JJ. **Brain injury in the premature infant-current concepts of pathogenesis and prevention.** *Biol Neonate* 1992;62:231–242