

Generic Contrast Agents

Our portfolio is growing to serve you better. Now you have a choice.



[VIEW CATALOG](#)

AJNR

Heparin-Induced Thrombocytopenia in a Case of Endovascular Aneurysm Coiling

V. Gupta, R. Tanvir, A. Garg, S.B. Gaikwad and N.K. Mishra

AJNR Am J Neuroradiol 2007, 28 (1) 155-158

<http://www.ajnr.org/content/28/1/155>

This information is current as of May 22, 2025.

CASE REPORT

V. Gupta
R. Tanvir
A. Garg
S.B. Gaikwad
N.K. Mishra

Heparin-Induced Thrombocytopenia in a Case of Endovascular Aneurysm Coiling

SUMMARY: We report a case of 46-year-old man who underwent endovascular coil embolization for left anterior inferior cerebellar and posterior inferior cerebellar aneurysms. During embolization of both aneurysms, thrombotic complications were observed along with a relative lack of response to heparin. Intra-arterial abciximab was used to recanalize an almost completely occluded posterior inferior cerebellar artery. A marked decrease in platelet counts was found soon after embolization, which normalized within a few days. Serologic tests confirmed heparin-induced thrombocytopenia. This syndrome should be considered in cases with thromboembolic complications during endovascular procedures, particularly in patients undergoing repeated heparin exposure. A sudden decrease in platelet counts and lack of response to heparin, manifested as a relative lack of increasing activated clotting time, should make one suspect this syndrome.

Detachable coil embolization of intracranial aneurysms has become a valid therapeutic alternative to open surgery.¹ Potential complications include intraprocedural aneurysm rupture and thromboembolic events. Thromboembolic complications (typically platelet-derived events) occur during aneurysm coiling in approximately 3% of the cases, resulting in permanent neurologic disability in 1.7%–5% of patients.^{2–4} Heparin is commonly used as an anticoagulant in the prevention and treatment of thromboembolism during such procedures. Although the clinical effects of heparin are meritorious, side effects do occur, with bleeding being the most common. However, heparin rarely leads to the syndrome of heparin-induced thrombocytopenia (HIT), which can result in thromboembolic or bleeding complications.^{5–9} We report a case of endovascular aneurysm coiling during which thrombotic complications occurred due to HIT.

Case Report

A 46-year-old man presented with a sudden onset of severe headache and loss of consciousness on January 9, 2004. The patient was a non-smoker and nonhypertensive, and he had no history of diabetes mellitus. CT revealed diffuse subarachnoid hemorrhage associated with a small left pontine hematoma, intraventricular bleed, and hydrocephalus. He recovered consciousness 3 days later and was found to have severe right hemiparesis. Digital subtraction angiography was performed on March 13, which revealed occlusion of bilateral internal carotid arteries in their supraclinoid segments, with anterior circulation being supplied through bilateral posterior communicating arteries. Left anterior inferior cerebellar artery (AICA) and left posterior inferior cerebellar artery (PICA) aneurysms were suspected, and the patient was referred to our center for endovascular coiling. On March 17, a cerebral angiogram was repeated in our center along with a 3D study for better visualization of the aneurysms (Fig. 1). The angiogram confirmed the findings of the previous digital subtraction angiogram. A third small aneurysm was seen arising from the P1 segment of the left posterior cerebral artery. During both of the diagnostic angiograms, 2500 IU heparin was given as an intra-arterial

bolus. Blood investigations were normal, with baseline platelet count on March 16 being $292 \times 10^3/\mu\text{L}$.

On March 22, embolization of the left AICA and PICA aneurysms was performed. Heparin was given as a bolus (5000 IU) soon after placement of an introducer sheath. An additional 2000 IU/h of heparin was given as an infusion through the guide catheter (FasGuide 6F, Target Therapeutics, Fremont, Calif) placed in the right vertebral artery. A microcatheter (Excelsior SL-10, Boston Scientific, Natick, Mass) was navigated into the AICA aneurysm. Although significant residual filling of the aneurysm (Fig 2B) was seen after the first coil placement (GDC 10, 3D, 4 mm \times 8 cm; Boston Scientific), significant resistance was experienced during the attempt to place the second coil (GDC 10, soft, 3 mm \times 10 cm; Boston Scientific) and the coil was withdrawn.

Repeat angiogram revealed complete occlusion of the aneurysm, with a small thrombus at the neck of the aneurysm projecting into the basilar artery (Fig 2C, -D). Flow was well maintained in the AICA and basilar artery. A bolus of heparin (3500 IU) was given through the guide catheter. Activated clotting time (ACT) at this stage was 216 seconds. Repeat ACT after 15 minutes was 230 seconds. As is our routine practice, we had not performed a baseline ACT measurement before the procedure. Thereafter, the left PICA aneurysm was embolized with 2 GDC 10 coils (4 mm \times 8 cm, 3D, and 3 mm \times 6 cm). After the second coil detachment (Fig 3B), there was progressive slowing of flow in the PICA (Fig 3C). A further 2500 IU of heparin was given through the guide catheter, followed by 8 mg of abciximab through the microcatheter placed near the neck of the aneurysm. The final angiogram revealed brisk antegrade flow in the PICA (Fig 3D).

During extubation, pharyngeal ooze was noticed and heparin was reversed with protamine. A coagulation profile performed a few hours after the procedure revealed a low platelet count ($40 \times 10^3/\mu\text{L}$). The other coagulation parameters were within normal limits. Two units of platelet-rich plasma were transfused, and after 48 hours the platelet count was $198 \times 10^3/\mu\text{L}$. The postoperative period was uneventful with no fresh infarct on CT.

In view of the the unusual thrombotic reaction during embolization, the relatively mild elevation of the ACT despite the large amount of heparin used, and the sudden decrease in the platelet count, the possibility of HIT was considered. Serologic tests, including heparin-induced platelet aggregation and enzyme-linked immunosorbent assay for heparin-associated antibodies, were positive and the diagnosis of HIT was confirmed. Follow-up hematologic investigations did not reveal any other abnormality.

At 1-year follow-up, the patient had mild residual hemiparesis

Received September 26, 2005; accepted after revision December 8.

From the Department of Neuroradiology, All India Institute of Medical Sciences, New Delhi, India.

Address correspondence to Vipul Gupta, MD, Department of Neuroradiology, Neurosciences Center, All India Institute of Medical Sciences, New Delhi, India 110029; e-mail: vipulgupta25@yahoo.com

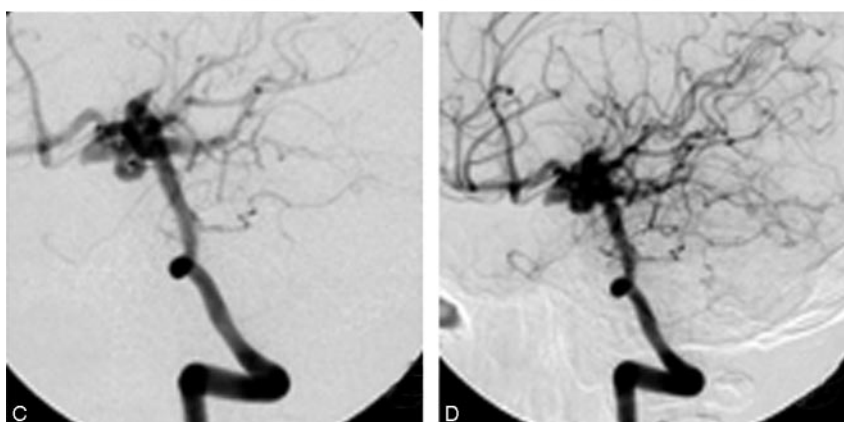
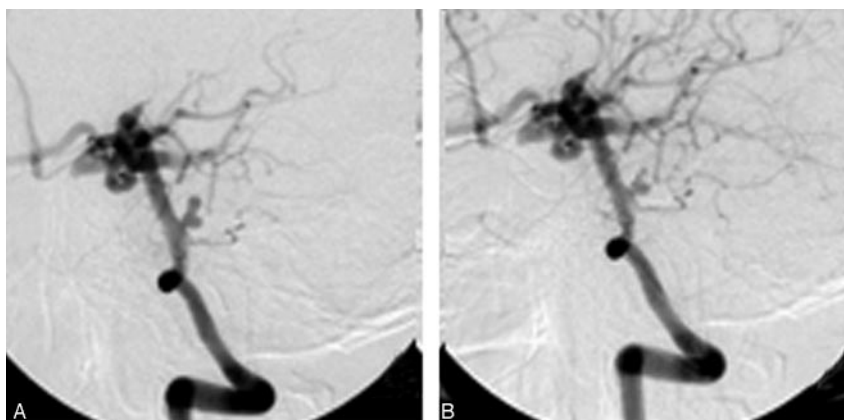
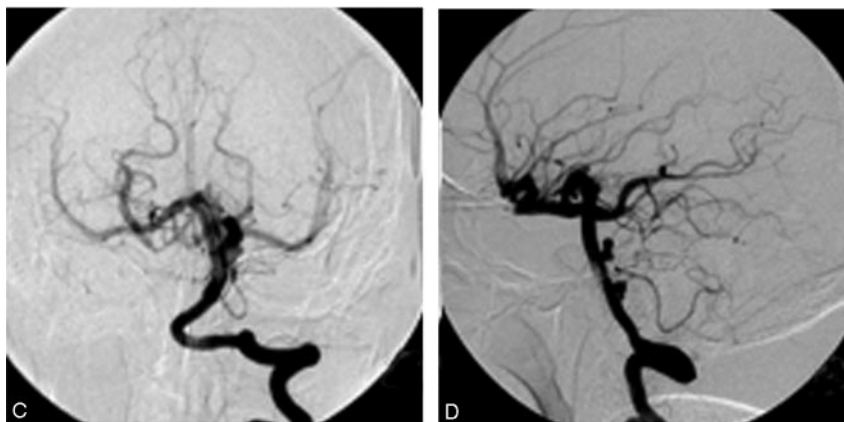
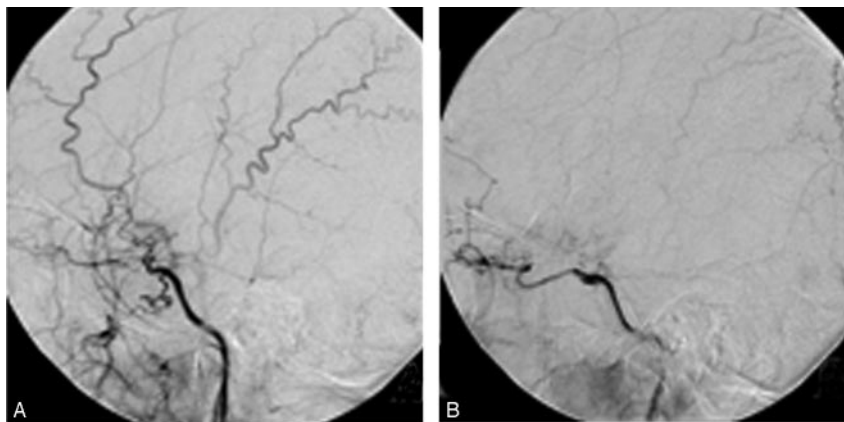


Fig 1. Digital subtraction angiography (lateral view) of right (A) and left (B) internal carotid arteries shows occlusion of both vessels beyond the origin of the ophthalmic artery. Hypertrophy of perforator arteries likely to provide collateral flow (more prominent on the left side) is noted. Left vertebral artery injection: anteroposterior (C) and lateral (D) views show hypertrophied posterior communicating arteries supplying the anterior circulation. Aneurysms are noted in the left AICA (arrow), the left PICA (arrowhead), and the left posterior cerebral artery (double arrow). The small posterior cerebral artery aneurysm was better profiled in 3D angiograms (not shown).

Fig 2. Images depicting embolization of the left AICA aneurysm. The bilobed AICA aneurysm was better profiled in oblique view (A). Although the aneurysm was filling well after detachment of the first coil (B), a repeat angiogram after a few minutes shows complete occlusion of the aneurysm (C). Progressive thrombus formation was noticed in a repeat angiogram done after a few minutes, which shows a small thrombus projecting into the basilar artery from the neck of the aneurysm (D).

(4+/5) and was able to walk with support. MR angiography performed 6 months and 1 year after the procedure revealed persistent

occlusion of the coiled aneurysms with patent left AICA and PICA. There was no change in the small posterior cerebral artery aneurysm.

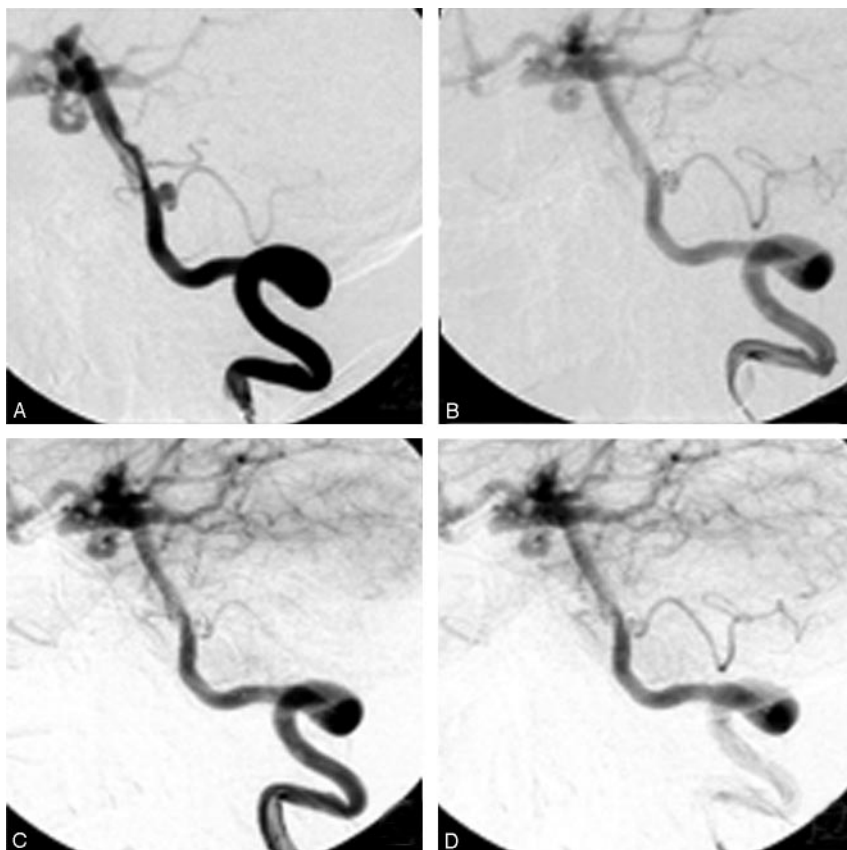


Fig 3. Images depicting coiling of the left PICA aneurysm. The aneurysm (A) was coiled with two detachable coils. Although residual aneurysm filling with well patent left PICA was seen after detachment of the second coil (B), a repeat angiogram done after a few minutes shows almost complete occlusion of the aneurysm with marked slowing of flow in the PICA (C). Abciximab infusion near the neck shows a patent PICA (D).

Discussion

Clots at the aneurysmal neck that form during or immediately after embolization are the likely cause of many thromboembolic events during coiling of intracranial aneurysms.¹⁰ Other sources of thromboembolism include thrombus forming on catheters during procedures, stenosis of an adjacent artery due to the coil mass or coil herniation, and displacement of chronic intraaneurysmal thrombus during coil placement. Slow flow due to vasospasm or presence of a large-size guide catheter in the parent artery can also promote thrombus formation.¹⁰ Thromboembolic events tend to occur more often with wide-necked aneurysms because of increased exposed surface area of thrombogenic coil material.¹⁰ Rare and unlikely causes of thromboembolism include a hypercoagulable state such as antiphospholipid antibody syndrome.¹¹ In our case, the thrombotic complication during coiling occurred due to HIT, which, to the best of our knowledge, has not been reported in the English literature. There are few reports of HIT complications during interventional procedures. van Sambeek et al reported a case in which an endovascular graft placement in an extracranial internal carotid artery aneurysm thrombosed within a few days of the procedure due to HIT.¹² Also, Sakai et al reported a massive thrombotic complication during percutaneous coronary intervention due to this syndrome.¹³

Classically, 2 clinical forms of HIT are described. HIT type I is a benign form with a reversible mild thrombocytopenia that often resolves despite persistent heparin treatment. Platelet proaggregating effects of high doses of heparin itself with an increased binding of fibrinogen seem to be the mechanism

leading to a decrease in the platelet count.⁵ Type II HIT is an autoimmune reaction often associated with thromboembolic complications that result from the development of antibodies in response to heparin binding with circulating platelet and endothelial-bound platelet factor 4. These immunoglobulin G, M, and A antibodies then bind strongly with the heparin–platelet factor 4 complex. The immune complex reacts with the platelet FcγIIa receptors, leading to platelet activation and thrombosis and rarely bleeding. These antibodies also bind to the same epitope on endothelial cells, resulting in endothelial cell activation with the release of tissue factor, which can produce a hypercoagulable state.⁶

Various laboratory tests, such as platelet ¹⁴C serotonin release assay,⁷ heparin-induced platelet aggregation,⁶ and enzyme-linked immunosorbent assay,⁸ are used in the diagnosis of HIT. These tests are complementary, and no test is completely reliable in confirming HIT.⁸ As seen in our case, features that may help in suspecting HIT during endovascular procedures include unusual thromboembolic events and the lack of a response to heparin, which is seen as a relative lack of increasing ACT. These features in a patient with a history of exposure to heparin should raise suspicion of HIT, and repeat platelet counts should be done along with the serologic tests.

The incidence of HIT remains uncertain.⁸ Generally, HIT type II occurs in 1%–3% of patients treated for 1–2 weeks with unfractionated heparin compared with about 0.1% for patients receiving low-molecular-weight heparin.⁹ These figures have been obtained in patients receiving postoperative prophylactic heparin treatment. Gluckman et al reported that platelet factor 4–heparin antibody induction occurred in a significant number of patients (17%) receiving unfractionated heparin during percutaneous revascularization.¹⁴ In their study, however, antibody conversion was infrequently associated with in vitro evidence of heparin-dependent platelet activation or HIT. The timing of HIT depends on prior exposure to heparin. In patients without previous exposure to heparin, a fall in platelet count occurs at about 5–10 days after initial treatment (delayed onset).¹⁵ In patients who have received heparin within 3 months, thrombocytopenia may occur within the first 24 hours after reexposure to heparin (acute onset). HIT is not well recognized as a potential cause of complication during neurointerventional procedures, probably because of the concept that this syndrome develops after a few days of heparin therapy.⁸ However, as seen in the study by Gluckman et al, significant numbers of patients undergoing endovas-

cular procedures may develop heparin-induced antibodies. Once sensitized, patients may develop this syndrome a short time after the repeat exposure to heparin and may manifest symptoms during or soon after the procedure.^{12,13}

Thrombotic complications are much more common in HIT than are bleeding ones. Clinical features of HIT due to venous thromboembolism include deep venous thrombosis, pulmonary embolism, venous limb gangrene, and adrenal hemorrhagic necrosis.⁸ Arterial thrombosis commonly involves distal aorta and major limb arteries, resulting in limb ischemia.⁸ Thrombotic stroke and myocardial infarction are also possible consequences. As seen in our patient and in previously reported cases,^{12,13} HIT rarely may also manifest as thrombotic complication at the site of intervention during or soon after an endovascular procedure.

Treatment of a patient with HIT includes prompt removal of all sources of heparin and replacement with an anticoagulant therapy that does not cross-react with HIT antibodies.^{8,16} Alternative anticoagulants with recorded success in HIT include danaparoid, lepirudin, and argatroban.^{8,16} Because of frequent cross-reactivity with HIT antibodies, low-molecular-weight heparin should not be used. Early use of warfarin should be avoided in patients with HIT because of reported risk of venous limb gangrene.¹⁷ Antiplatelet agents, such as aspirin and dipyridamole, have also been used.⁸ As seen in our case, abciximab was effective in recanalization of an almost completely occluded artery. Sakai et al reported successful use of argatroban to treat HIT-induced thrombus formation during coronary stent placement procedures.¹³ In the case reported by van Sambeek et al, thrombectomy and local fibrinolysis were used to clear the HIT-induced thrombus formation in an endovascular graft.¹² However, the graft completely rethrombosed a day after the procedure. Platelet transfusion is not advisable to correct thrombocytopenia because of possible accelerated aggregation and thrombotic complications.

In view of dilated posterior communicating arteries, the bilateral carotid occlusions seen in our case were probably of long duration. There was no historical or imaging evidence of ischemic stroke. Bilateral supraclinoid carotid artery occlusion can occur from various etiologies, and in many cases no cause can be found.¹⁸⁻²⁰ In our case, there were no predominant risk factors of vascular occlusive disease such as hypertension, smoking, diabetes mellitus, or hypercholesterolemia. Bilateral stenosis and occlusions of intracranial carotid arteries are also seen in Moyamoya disease. In our case, an angiogram did not show the typical "puff of smoke" appearance characteristic of this disorder, and the collateral flow through the enlarged posterior communicating arteries was also unlike the pattern seen in Moyamoya disease. Various disorders that can lead to a secondary Moyamoya-like angiographic pattern include neurofibromatosis, pseudoxanthoma elasticum, cranial irradiation, and Down syndrome. Prothrombotic conditions such as protein S deficiency or antiphospholipid antibodies, sickle cell anemia, paroxysmal nocturnal hemoglobinuria, and essential thrombocythemia have also been linked to Moyamoya disease.²⁰ For our patient, the detailed history, examination, and investigations did not reveal any of these disorders. Also, a review of the literature did not reveal any reported association

between the above-mentioned vascular occlusive disorders and the occurrence of HIT.

Conclusion

Rarely, thromboembolic complication during an endovascular embolization of an intracranial aneurysm may occur due to a hypercoagulable state because of HIT. Features that may help in suspecting HIT during the procedure include unusual thromboembolic events and lack of response to heparin, which is seen as relative lack of increasing ACT. These features in a patient with a history of previous exposure to heparin should raise suspicion of HIT. Abciximab may be useful in such cases to resolve the thrombus.

References

1. Molyneux A, Kerr R, Stratton I, et al. **International Subarachnoid Aneurysm Trial (ISAT) of neurosurgical clipping versus endovascular coiling in 2143 patients with ruptured intracranial aneurysms: a randomised trial.** *Lancet* 2002;360:1267-74
2. Eskridge JM, Song JK. **Endovascular embolization of 150 basilar tip aneurysms with Guglielmi detachable coils: results of the Food and Drug Administration multicenter clinical trial.** *J Neurosurg* 1998;89:81-86
3. McDougall CG, Halbach VV, Dowd CF, et al. **Endovascular treatment of basilar tip aneurysms using electrolytically detachable coils.** *J Neurosurg* 1996;84:393-99
4. Vinuela F, Duckwiler G, Mawad M. **Guglielmi detachable coil embolization of acute intracranial aneurysm: perioperative anatomical and clinical outcome in 403 patients.** *J Neurosurg* 1997;86:475-82
5. Chong BH. **Heparin-induced thrombocytopenia.** *Br J Haematol* 1995;89:431-39
6. Mureebe L, Silver D. **Heparin-induced thrombocytopenia: pathophysiology and management.** *Vasc Endovascular Surg* 2002;36:163-70
7. Sheridan D, Carter C, Kelton JG. **A diagnostic test for heparin-induced thrombocytopenia.** *Blood* 1986;67:27-30
8. Elalamy I, Lecrubier C, Horellou MH, et al. **Heparin-induced thrombocytopenia: laboratory diagnosis and management.** *Ann Med* 2000;32(suppl 1):60-67
9. Warkentin TE, Levine MN, Hirsh J, et al. **Heparin-induced thrombocytopenia in patients treated with low-molecular-weight heparin or unfractionated heparin.** *N Engl J Med* 1995;332:1330-35
10. Workman MJ, Cloft HJ, Tong FC, et al. **Thrombus formation at the neck of cerebral aneurysms during treatment with Guglielmi detachable coils.** *AJNR Am J Neuroradiol* 2002;23:1568-76
11. Pierot L, Condette-Auliac S, Piette AM, et al. **Thromboembolic events after endovascular treatment of unruptured intracranial aneurysms in two patients with antiphospholipid-antibody syndrome.** *Neuroradiology* 2002;44:355-57
12. van Sambeek MR, Segeren CM, van Dijk LC, et al. **Endovascular repair of an extracranial internal carotid artery aneurysm complicated by heparin-induced thrombocytopenia and thrombosis.** *J Endovasc Ther* 2000;7:353-58
13. Sakai K, Oda H, Honsako A, et al. **Obstinate thrombosis during percutaneous coronary intervention in a case with heparin-induced thrombocytopenia with thrombosis syndrome successfully treated by argatroban anticoagulant therapy.** *Catheter Cardiovasc Interv* 2003;59:351-54
14. Gluckman TJ, Segal JB, Fredde NL, et al. **Incidence of antiplatelet factor 4/heparin antibody induction in patients undergoing percutaneous coronary revascularization.** *Am J Cardiol* 2005;95:744-47
15. Warkentin TE, Kelton JG. **Temporal aspects of heparin-induced thrombocytopenia.** *N Engl J Med* 2001;344:1286-92
16. Hirsh J, Heddle N, Kelton JG. **Treatment of heparin-induced thrombocytopenia: a critical review.** *Arch Intern Med* 2004;164:361-69
17. Warkentin TE, Elavathil LJ, Hayward CP, et al. **The pathogenesis of venous limb gangrene associated with heparin-induced thrombocytopenia.** *Ann Intern Med* 1997;127:804-12
18. Cloft HJ, Kallmes DF, Snider R, et al. **Idiopathic supraclinoid and internal carotid bifurcation steno-occlusive disease in young American adults.** *Neuroradiology* 1999;41:772-76
19. Lagreze HL, Hartmann A, Ries F, et al. **Isolated supraclinoid occlusive disease of the internal carotid artery.** *Eur Neurol* 1987;26:40-45
20. Kornblihtt LI, Cocorullo S, Miranda C, et al. **Moyamoya syndrome in an adolescent with essential thrombocythemia: successful intracranial carotid stent placement.** *Stroke* 2005;36:e71-e73