

Generic Contrast Agents

Our portfolio is growing to serve you better. Now you have a *choice*.



FRESENIUS
KABI

[VIEW CATALOG](#)

AJNR

Traction device to improve CT imaging of lower cervical spine.

D C Boger

AJNR Am J Neuroradiol 1986, 7 (4) 719-721

<http://www.ajnr.org/content/7/4/719.citation>

This information is current as
of May 16, 2025.

Traction Device to Improve CT Imaging of Lower Cervical Spine

Donald C. Boger¹

CT demonstration of lower cervical spine detail is often limited by a streak artifact created by the shoulders within the tomographic field of view (Fig. 1). The patient may be instructed to hold the shoulders low; however, this position is difficult to maintain without moving throughout the often lengthy examination. Various methods for achieving optimal CT cervical spine images have been described [1–3]. These involved manipulating the radiographic factors and section thickness, positioning silicone gel pads about the neck, adjusting the gantry angle, and choosing a small versus a large field-of-view calibration. Beyond removing the shoulders from the scanning area, no technique has been described that routinely eliminates the streak artifacts.

This article describes an easily applied device that facilitates a classic maneuver and effectively depresses the shoulders from the lower cervical spine and eliminates much of the shoulder artifact. A search of the computer literature failed to disclose any published devices described for this purpose in CT of the cervical spine. Methods of application and a representative case are included.

Materials and Methods

The device (Fig. 2) is composed of padded wrist straps and lengths of flexible automotive webbing joined by a quick-release buckle that allows rapid adjustment of the strap length. The two T-shaped straps, which use Velcro for secure closure, are first wrapped about the wrists. The adjustable connector strap is then placed about the plantar surfaces of the feet and the strap is shortened. This places tension on the wrists and depresses the shoulders. The process may be aided by bending the knees slightly before placing the adjustable strap beneath the feet and straightening the knees after tightening the strap. This maneuver usually increases the tension of the wrists.

The following two methods of application were found to be most effective.

1. Axial scans of the cephalad cervical spine are made after the initial pilot view is generated. Upon reaching a level in the lower cervical spine where the shoulder-generated artifact obscures adequate detail, the CT-modified autotracting device is applied. Another pilot view is generated, and axial scanning is continued, starting 1–2 cm cephalad to the lowest original axial level imaged. This small

overlap assures that all areas of the cervical spine are imaged, that important bone and soft-tissue diseases are not overlooked, and that the exact levels imaged are clearly identified.

2. An alternative technique may be used when need for the device is anticipated before the examination begins. The traction device is applied at the beginning of the exam. The axial scans are started at the cervicothoracic junction, or the lowest level necessary, with scans performed in a cephalad direction. Traction may be maintained until the scans reach an appropriate mid-cervical level, where the shoulder artifact is no longer troublesome. Tension on the wrists may then be released slowly without moving the patient, and scanning may be completed. This technique is somewhat faster than the first, but the image sequence format (T1–C3) is the reverse of the usual sequence (C3–T1).

Results

The CT-modified autotracting device was used to examine 92 patients, who represent approximately 75% of the cervical spine CT examinations performed since the device was introduced. The average patient age was 49 years (range, 26–79 years) and all were evaluated for nontraumatic cervical complaints. The shoulder-generated streak artifact most often degraded the image detail beginning at the C5–C6 level. The change in image clarity after application of the device was evaluated by comparing initial suboptimal CT images to post-traction images of similar levels. Occasionally, the C6–C7 levels and frequently the C7–T1 levels were obscured or not scanned on the initial series because of increasingly severe artifact. The images of these lower levels were considered improved when upper-extremity traction allowed clearly diagnostic images of lower cervical levels that had initially been obscured by shoulder artifact to an extent that the images were nondiagnostic. Image detail was significantly improved at least at one level in 93% of patients and at two levels in 52% of patients.

Application of the CT traction device and subsequent pressure from the padded wrist straps caused moderate discomfort in some patients' wrists and shoulders. This discomfort did not prevent completion of the examination in any patient.

Received August 21, 1985; accepted after revision January 12, 1986.

¹ Department of Radiology, Centinela Hospital Medical Center 555 East Hardy St., Inglewood, CA 90307. Address reprint requests to D. C. Boger.

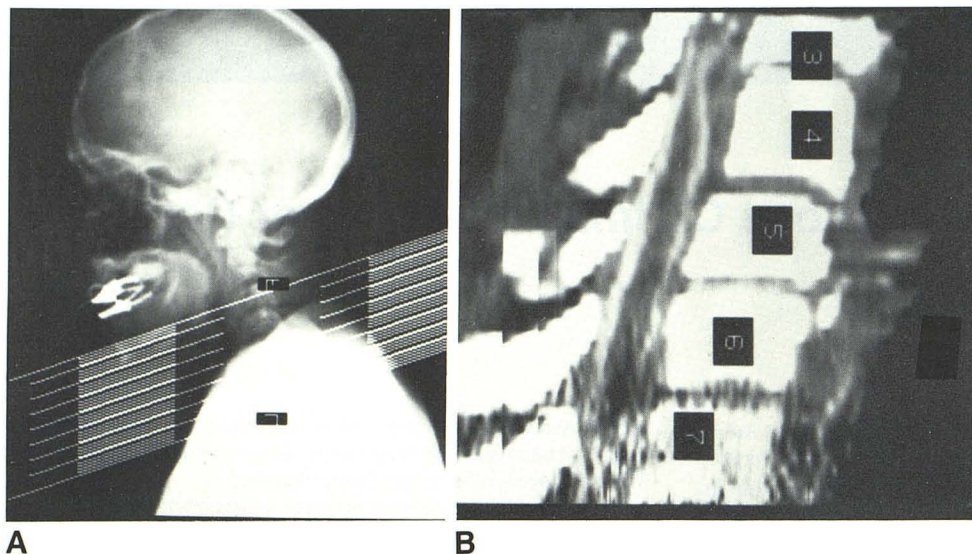


Fig. 1.—**A**, Pilot view shows lateral cervical spine obscured by shoulders below C4. **B**, Sagittal reconstruction shows shoulder artifact that obscures detail at mid C6 and below.

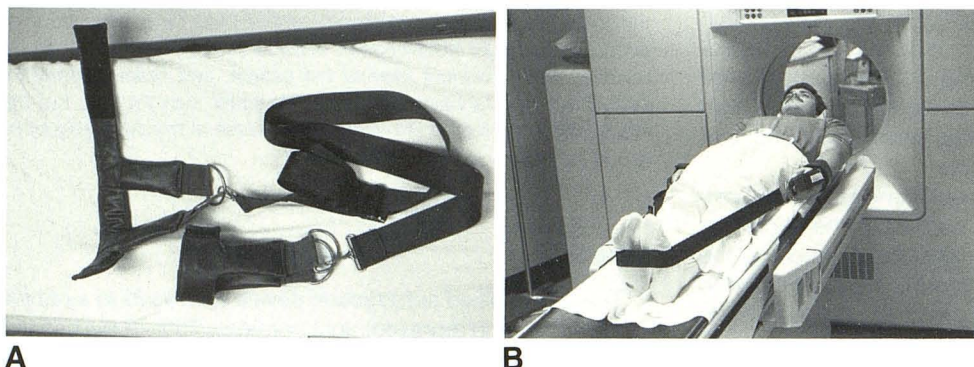


Fig. 2.—**A**, Configuration of CT-modified autotraction device. **B**, Technique of application.

Representative Case Report

A 41-year-old man was referred to Centinela Hospital Medical Center for evaluation of neck and right shoulder pain. Clinical examination revealed right C6 or C7 radiculopathy. A nerve-conduction study was positive for right seventh cervical nerve injury. Plain radiographs showed C5–C6 degenerative spondylosis, right C5–C6 uncovertebral spur, and right C5–C6 neural foraminal stenosis. Initial cervical spine CT study was suboptimal because of increasingly severe shoulder artifact, which obscured detail below C5. After several months of conservative therapy, pain had subsided although right upper-extremity numbness persisted. Follow-up CT examination was performed. The CT traction device was available at that time and was applied. Adequate shoulder depression allowed clear images of right C5–C6 neural foraminal stenosis, a small right-sided herniated nucleus pulposus (HNP), which partially occluded the right C5–C6 foramen and right C6–C7 foraminal stenosis due to osteophytes from the right C6–C7 uncovertebral joint (Fig. 3). Foraminal stenosis at C5–C6 and C6–C7 had been seen initially; however, C5–C6 HNP and C6–C7 uncinate spurs had been obscured by artifact.

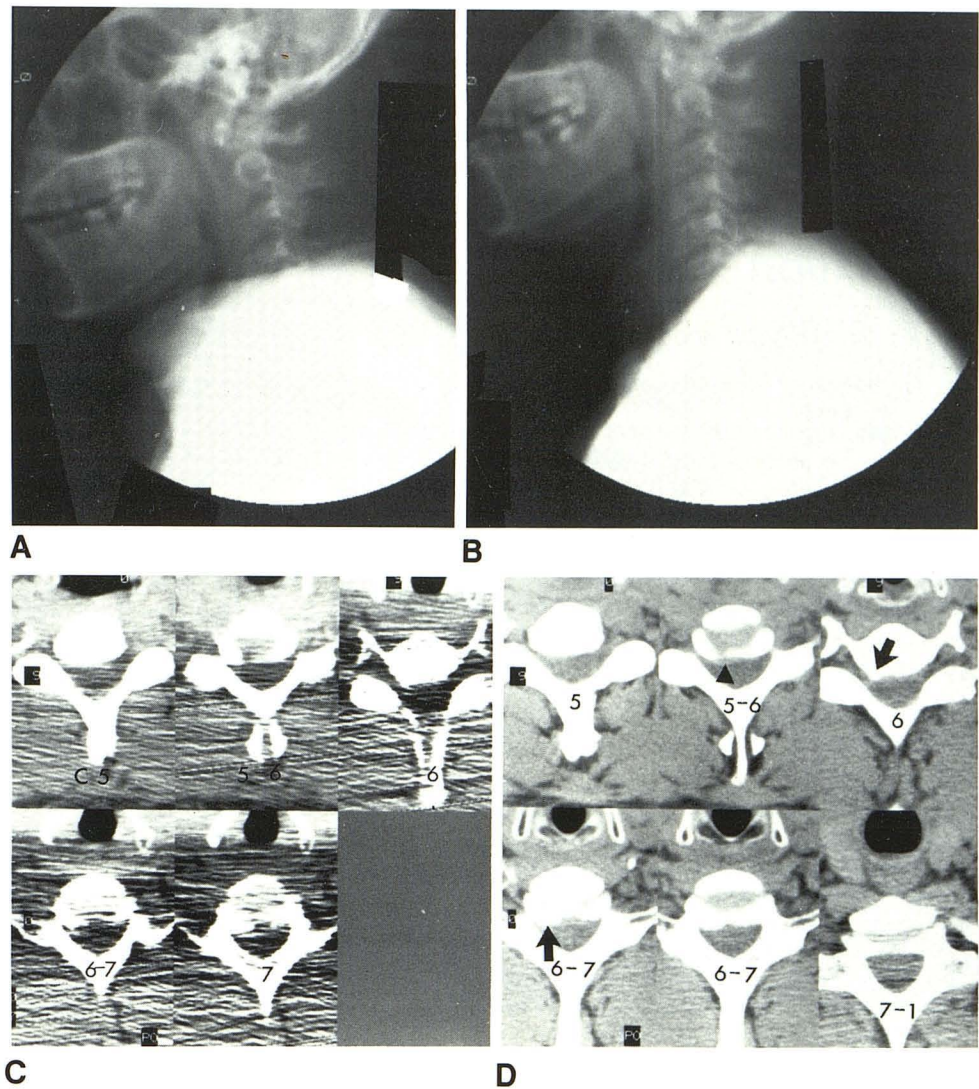
Discussion

Degenerative and posttraumatic pathology of the cervical spine occur most commonly at the C5 level and below. These lower segments of the cervical spine and canal are often

obscured by artifact from superimposed shoulders in plain radiography, as well as conventional and CT radiography. A classic and obvious maneuver to depress the shoulders has been to apply traction to the upper extremities, which uncovers the lower cervical spine and eliminates artifact. Such traction may be applied by an assistant at the foot of the radiographic table or by hanging weights that are attached to or held by the patient. Another technique involves a strap (or more likely a sheet or towel) that is looped around the patient's feet and held by the patient while pushing downward on the strap. These maneuvers are helpful, but are not optimal owing to such factors as unnecessary radiation exposure to the assistant, motion artifact created by the effort of holding the strap, and inability of the patient to hold the strap throughout the exposure. Other devices normally used to hold the patient securely in place during cervical myelography may be used to depress the shoulders, although the restraining device about the shoulders may create its own obscuring artifact.

In 1981 I developed a traction device for use in conventional radiography of the cervical spine that proved helpful for depressing the shoulders and avoiding the problems mentioned above [4]. The device was effective in reducing streak artifact during CT of the cervical spine, but caused considerable pain in the wrists after prolonged application. A modified autotrac-

Fig. 3.—**A**, Pilot view without traction. Details below C4 obscured by shoulders. **B**, Pilot view with CT-traction device in place. **C**, Axial images from C5 to C6–C7 before traction show increasingly severe shoulder artifact. **D**, Axial images from C5 to C7–T1 after traction reveal details not visible on initial examination. Note right C5–C6 herniated nucleus pulposus (arrowhead) and right uncovertebral osteophytes (arrows).



tion device for CT was devised that was as effective as the original design, easier to apply, and caused much less discomfort. Since introduction of the CT traction device, fewer suboptimal or nondiagnostic images of the lower cervical spine due to superimposed shoulders have been encountered.

REFERENCES

1. Orrison WW, Johansen JG, Eldevik OP, Haughton VM. Optimal computed-tomographic techniques for cervical spine imaging. *Radiology* **1982**;144:180–182
2. Taylor S. CT of the normal and abnormal spine. In: Latchaw RE, ed. *Computed tomography of the head, neck, and spine*. Chicago: Year Book Medical Publishers, **1985**:595–618
3. Yeates AE. Computed tomographic evaluation of cervical pain syndromes. In: Genant HK, ed. *Spine update 1984*. San Francisco: Radiology Research and Education Foundation, **1984**:291–293
4. Boger D, Ralls PW. New traction device for radiography of the lower cervical spine. *AJNR* **1981**;2:467–469, *AJR* **1981**;137:1202–1204