

Generic Contrast Agents

Our portfolio is growing to serve you better. Now you have a *choice*.



FRESENIUS
KABI

[VIEW CATALOG](#)

AJNR

The mucopolysaccharidoses: characterization by cranial MR imaging.

C Lee, T E Dineen, M Brack, J E Kirsch and V M Runge

AJNR Am J Neuroradiol 1993, 14 (6) 1285-1292

<http://www.ajnr.org/content/14/6/1285>

This information is current as
of May 31, 2025.

The Mucopolysaccharidoses: Characterization by Cranial MR Imaging

Charles Lee, Timothy E. Dineen, Mitchell Brack, John E. Kirsch, and Val M. Runge

PURPOSE: To characterize MR findings in mucopolysaccharidoses (MPS), to aid in diagnosis and categorization, and to define the role of MR in preoperative evaluation. **MATERIALS AND METHODS:** Six children with Hurler syndrome (MPS IH), five with Hunter syndrome (MPS II), and three with Sanfilippo A syndrome (MPS IIIA) were studied by routine T1-weighted and T2-weighted images at 1.5 T. MR findings were graded retrospectively. **RESULTS:** All had hallmark cribriform changes (sieve-like or multicystic) involving peri- and supraventricular, parietal, white matter (12), corpus callosum (8), and basal ganglia (4), which did not enhance. The cerebellum and brain stem were not involved with these cribriform changes. The most severe degree of cribriform changes occurred in children with Hunter and Hurler syndromes, correlating with non-central nervous system somatic involvement, but inversely related to degree of atrophy, ventricular enlargement, and white matter changes. Mental retardation was most severe in children with Hurler syndrome and correlated with chronicity of the disease. Severity of mental retardation did not correlate with severity of cribriform changes. **CONCLUSIONS:** Based on our observations, we postulate that in the natural course of MPS, cribriform changes occurred first, followed by white-matter changes and, last, atrophy. More severe degrees of cribriform changes plus involvement of the corpus callosum may suggest a poorer prognosis. Optimal therapeutic intervention may be at the time of cribriform changes before atrophy has occurred. MR can define and grade these changes.

Index terms: Degenerative brain disease; Brain, magnetic resonance; Pediatric neuroradiology

AJNR 14:1285-1292, Nov/Dec 1993

Mucopolysaccharidosis (MPS) is caused by inherited lysosomal enzyme deficiencies, which result in deposition of glycosaminoglycans (GAG) in subendothelial locations in the central nervous system (CNS) and other organ systems, resulting in dysfunction. All of the MPSs are autosomal recessive inherited except Hunter syndrome, which is X-linked recessive. The classification is complex (1), consisting of five major types with variable clinical manifestations: Hurler (MPS IH), Scheie (MPS IS), Hunter (MPS II, mild and severe), Sanfilippo (MPS III A-D), and Morquio (MPS IV A and B) syndromes. Other types include Mar-

teaux-Lamy (MPS VI) and Sly (MPS VII) syndromes. The progression of disease is relentless and chronic with eventual multisystem involvement, musculoskeletal dysostosis, abnormal facies, neurosensory disorders, and mental retardation. Severe mental retardation occurs with the Hurler, Hunter, and Sanfilippo A types.

Recently, implementation of allogenic bone-marrow transplantation has resulted in dramatic reversal of the various systemic manifestations of the disease and even reversal of CNS findings on magnetic resonance (MR) (1, 2). Therefore, the role of MR becomes increasingly important not only in preoperative evaluation but also in monitoring response to bone-marrow transplantation.

We report our experience with 14 patients who came to the bone-marrow transplant service because preoperative MR evaluation demonstrated characteristic CNS findings, which may have prognostic value. MR also demonstrated various types of radiologic changes that we felt illustrated the natural course of MPS intracranially.

Received June 11, 1992; revision requested September 14; final revision received November 5 and accepted November 9.

Presented at the 29th Annual Meeting of the ASNR, Saint Louis, Mo, May 31-June 5, 1992.

All authors: Department of Radiology and Magnetic Resonance Imaging and Spectroscopy Center, University of Kentucky Medical Center, HX-315D, 800 Rose St, Lexington, KY 40536-0084. Address reprint requests to C. Lee, MD.

AJNR 14:1285-1292, Nov/Dec 1993 0195-6108/93/1406-1285

© American Society of Neuroradiology

Materials and Methods

A total of 14 patients with MPS came to the bone marrow transplant service, of which there were six with Hurler syndrome (MPS IH), five with Hunter syndrome (MPS II, severe), and three with Sanfilippo A syndrome (MPS IIIA). Specific diagnosis of MPS was established by a combination of urinary analysis for glycosaminoglycans and cultured fibroblast enzyme assays.

All were studied by MR and eight with gadopentetate dimeglumine (the other six were 2 years of age or younger) on a 1.5-T unit using routine axial T1-weighted (600/22/1) (repetition time/echo time/excitations) and T2-weighted pulse sequences (2500/30, 90/1) with sagittal and coronal T1-weighted views. All patients were evaluated for the numbers and sizes of cribriform lesions on the T1-weighted images, degree of atrophy and ventricular enlargement, myelination delay on T2-weighted images, and abnormal, increased signal intensity in the periventricular white matter on T2-weighted images.

There were multiple cystic or sieve-like lesions of the white matter, which we defined as cribriform changes. The degree of cribriform changes were graded as follows: 0 = none, 1 = mild (10 or less small cystic areas on T1-weighted images located in peri- and supraventricular white matter <3 mm in size) (Fig 1), 2 = moderate (more than 10 small cystic areas on T1-weighted images but with basal ganglia and corpus callosum involvement as well), and 3 = severe (many small and large (>3 mm) cysts, involving all of the above areas) (Fig 2A).

The degree of atrophy was graded as follows: 0 = none, 1 = mild (mild prominence and widening of the Sylvian and interhemispheric fissure by <3 mm, but not all of the sulci are involved) (Fig 2D), 2 = moderate (widening of all fissures and gyri from 3 to 5 mm, with visualization of the entire mesencephalic cistern) (Fig 3A), and 3 = severe (widening of all fissures and gyri >5 mm with definite loss

of cortex and white matter). Likewise the degree of ventricular enlargement was graded as follows: 0 = none, 1 = mild (<3-mm widening of the III but no temporal horn dilatation) (Fig. 2D), 2 = moderate (widening of the ventricles >5 mm but <1 cm) (Fig 1B), and 3 = severe (>1-cm dilatation of ventricle with bulbous configuration). With severe ventricular enlargement, it was difficult to differentiate hydrocephalus from ex vacuo dilatation.

White matter signal changes on the T2-weighted images were graded as 0 = none, 1 = mild (thin [<3 mm thick], patchy, or focal areas of increased signal in periventricular white matter) (Fig 2D), 2 = moderate (confluent thicker areas [4 to 10 mm] of increased signals with polar capping) (Figs 1B, 4), and 3 = marked (areas >1 cm thick) (Fig 3B). The increased signal changes did not conform morphologically to the increased signal of immature white matter seen on T2-weighted images in healthy children.

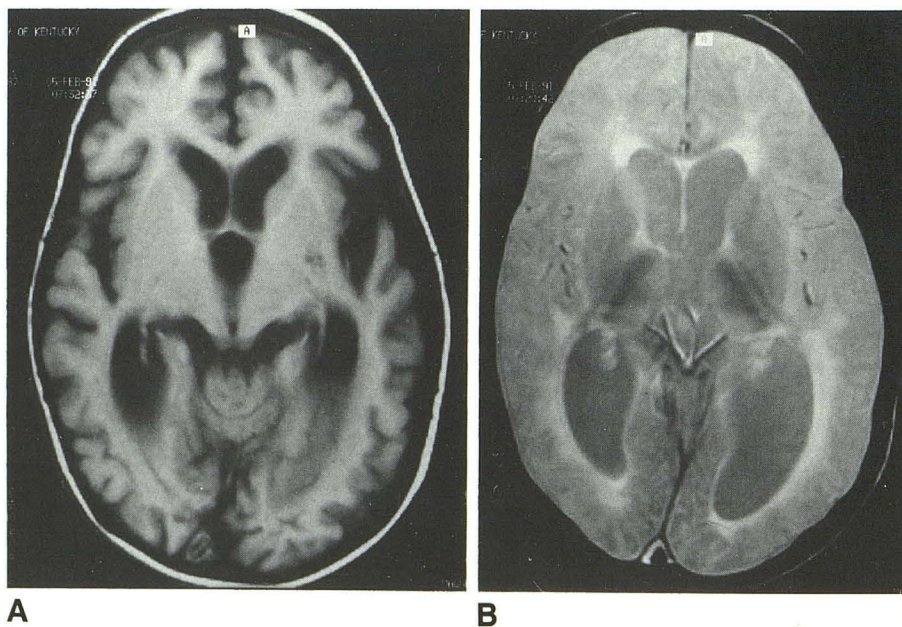
Delay in myelination was graded by comparing the images of the children with MPS to published images with age-related white matter development in healthy children. We used Barkovich's approach to assessment based on expected milestones at 1.5 T (3). The normal adult pattern is expected at 18 months on the T2-weighted images. Because the children whom we studied were ages 1 year and older, all were expected to and did demonstrate hypointensity of the cerebellar white matter, corpus callosum, and at least the anterior limb of the internal capsule on the T2-weighted images.

Grading of myelination delay was as follows: 0 = no delay, 1 = mild (normal arborization pattern of forceps, but thinner than what one sees in a normal 18-month-old child), 2 = moderate (decrease in or lack of arborization pattern of forceps as well as thinner regions, or with milestones equivalent to that expected only for a 1-year-old child), and 3 = severe (lack of normal arborization with minimal patchy areas of hypointensity if any in the forceps).

Fig. 1. Four-year-old patient with Sanfilippo A syndrome (MPS IIIA).

A, Axial T1-weighted image showing cribriform changes in the left lentiform nuclei graded as mild involvement.

B, Axial intermediate T2-weighted image showing increased signal in the periventricular white matter graded as moderately severe. The ventricles are moderately enlarged.



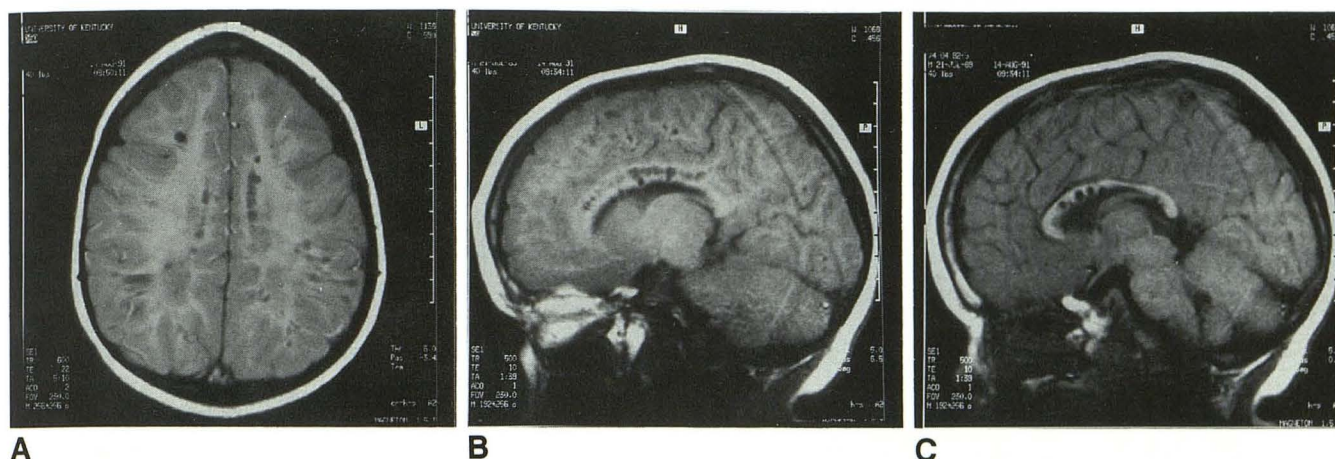


Fig. 2. Two-year-old boy with severe form of Hunter syndrome (MPS II severe).
 A, Axial T1-weighted image showing multiple cribriform lesions graded as severe involvement. Lesions are located in the supraventricular frontal and parietal white matter. The cribriform lesions appear as low signal intensity.
 B, Sagittal T1-weighted image just off the midline showing numerous lesions in a pericallosal location. Lesions are oriented perpendicular to the long axis of the callosum.
 C, Sagittal T1-weighted image showing corpus callosum involvement graded as moderate involvement.
 D, Intermediate T2-weighted image showing increased signal intensity in the periventricular white matter graded as mild. There is no significant atrophy or ventricular enlargement.

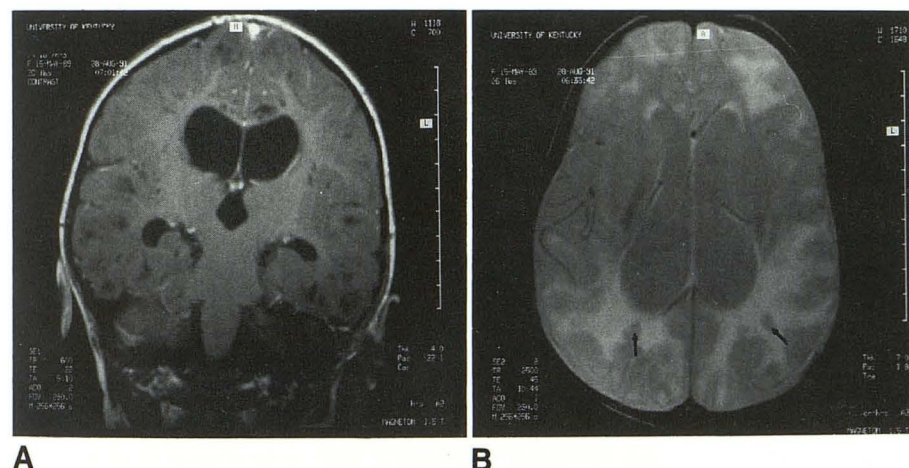
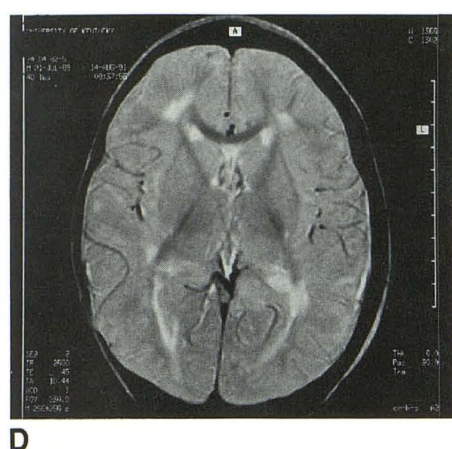

Fig. 3. Two-year-old patient with Hurler syndrome (MPS IH).

A, Coronal T1-weighted image showing cribriform lesions in the corpus callosum, temporal lobe, and supraventricular white matter. Note a moderate degree of cerebral atrophy.

B, Axial intermediate T2-weighted image showing increased signal intensity in the periventricular white matter graded as severe involvement. Note the apparent filling defects (arrow) bilaterally in the posterior periventricular, abnormal signal in the white matter representing the cribriform lesions, which are isointense with respect to brain on proton density images.

Degree of mental retardation was assessed by the clinical service and classified as mild, moderate, or severe based on social and communication skills. The criteria of the *Diagnostic and Statistical Manual of Mental Disorders* (third revised edition) of the American Psychiatric Association was used, because the majority of patients were too young for standard intelligence tests (4). Only two had taken intelligence quotient tests and were found to have severe mental retardation.

According to this manual, mild retardation constitutes the educational category of "educable." These patients develop social and communication skills commensurate with preschool years but have minimal sensorimotor impairment. Moderate retardation falls into the education category of "trainable." These children may learn to talk in the preschool years but rarely progress beyond the second grade level in academic skills. Those with severe retardation do not develop social or communicative skills in the preschool years and have poor motor development. We as-

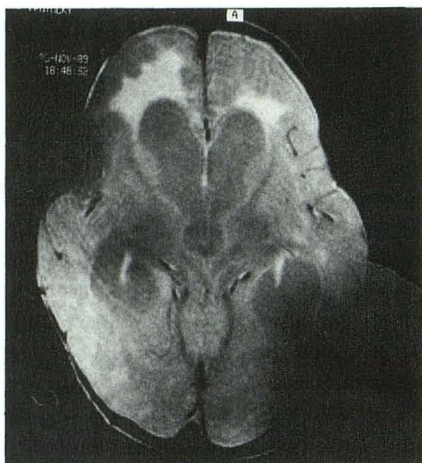


Fig. 4. One-year-old patient with Hurler syndrome (MPS IH). Axial intermediate T2-weighted image showing increased signal in the periventricular white matter graded as moderate changes.

signed mental retardation the following numerical values, based on the clinical assessments: 0 = none, 1 = mild retardation, 2 = moderate retardation, and 3 = severe retardation.

Composite scores of cribriform changes in all areas combined, of atrophy plus ventricular enlargement, and of delay in myelination of white matter and white matter-increased signal intensity changes were created so that relative comparisons could be made among the various categories being graded. (Table 1). We have not had the opportunity as of yet to reevaluate these patients with MR after bone marrow transplantation.

Results

There were six patients with Hurler syndrome, five ranging from ages 1 to 2 years and one 14-year-old patient, five with Hunter syndrome (severe type) ranging from 2 to 10 years age, and three with Sanfilippo A syndrome ranging from 3–4 years of age. In the Hunter group three patients were brothers.

All of these patients exhibited cribriform or cystic changes: low signal intensity with respect to white matter on the T1-weighted images, isointense on proton density images, and high signal intensity on the T2-weighted images. These lesions varied in size from 2 to 8 mm in the largest. Of the eight patients older than 2 years, no abnormal contrast enhancement of these cribriform lesions was noted with gadopentetate dimeglumine. In all but two patients the peri- and supraventricular white matter were involved. The latter two patients belonged to the Sanfilippo A group with mild cribriform changes either in the corpus callosum or basal ganglia. In general the

degree of cribriform changes was graded as mild in patients with Sanfilippo A syndrome. The degree of cribriform changes was more severe in patients with Hunter and Hurler syndromes (Table 1). There was no difference in the degree of cribriform changes between patients with Hurler syndrome and those with Hunter syndrome.

The posterior frontal and anterior parietal supraventricular regions were most commonly involved with cribriform changes (Fig 2A). In patients graded as severe, the cribriform changes involved the temporal and inferior frontal lobes, corpus callosum (Fig 2C), and basal ganglia in addition to the frontal and parietal regions. Corpus callosum involvement occurred more often in children with Hunter and Hurler syndromes (Table 1). The long axis of these cribriform lesions was oriented parallel to the fibers of the corpus callosum or perpendicular to the long axis of the corpus.

There was increased signal in the periventricular white matter on T2-weighted images in 12 of 14 patients which, was graded as mild in the majority (8 of 12). There were two patients with Hunter or Sanfilippo A syndrome graded as moderate increase in signal intensity and two with Hurler syndrome, graded as severe increase. These changes of increased signals were better demonstrated on the proton density images (Fig 1B).

Because the white matter changes were focal, or confluent, and did not conform to the ventricular outline, it was felt that the increased signal in the white matter was not attributable to transpendymal cerebrospinal fluid flow cause by hydrocephalus. Nor did they correspond to the anatomic distribution of increased signal seen on T2-weighted images in healthy children with immature white matter. Therefore these were not felt to represent increased signal from immature white matter. The cribriform lesions appeared as filling defects, or areas of hypointensity within the areas of abnormal signal in the white matter on the proton density images (Fig 3B).

There was myelination delay in all patients, with the majority (8 of 14) being graded either moderate (3 patients) or severe (5 patients). Degree of myelination delay was the least in the children with Sanfilippo A syndrome. In some children there was such severe loss of white matter, evident by the degree of atrophy, that it was difficult to determine whether the lack of hypointensity on the heavily T2-weighted images

TABLE 1: MR changes in MPS

	Hunter					Hurler					Sanfilippo A			
	1	2	3	4	5	6	7	8	9	10	11	12	13	14
Cribriform changes														
Supraventricular brain	2	3	2	2	2	2	3	1	2	2	2	0	0	1
Corpus callosum	2	3	1	1	0	0	3	0	2	0	1	1	0	0
Basal ganglia	0	1	0	0	0	0	0	0	1	2	0	0	1	0
Total score	4	6	3	3	2	2	6	1	5	4	4	1	1	1
Atrophy and ventricular enlargement														
Atrophy	1	0	1	1	1	0	1	3	2	3	0	1	2	1
Ventricular enlargement	1	0	1	1	2	0	3	3	2	3	1	1	2	0
Total score	2	0	2	3	3	0	4	6	4	6	1	2	4	1
Myelination delay and signal change														
Myelination delay	3	1	2	3	3	1	2	3	1	3	1	2	1	1
White matter increased signal	0	1	1	2	1	1	3	3	1	1	1	1	2	0
Total score	3	2	3	5	4	2	5	6	2	4	2	3	3	1
Degree of mental retardation	2	1	1	1	3	1	2	3	1	1	1	1	1	1
Age	4	2	8	5	10	2	2	14	2	1	1	4	4	3
Megacisterna magna	+		+				+							
Posterior fossa arachnoid cyst		+			+				+			+	+	
Temporal fossa arachnoid cyst						+	+			+				
Chiari type I											+			

Scale: 0 = none, 1 = mild, 2 = moderate, 3 = severe. See text for full explanation.

was caused by myelination delay or by absence of any white matter.

Atrophy and ventricular enlargement appeared to be more severe in patients with Hurler syndrome (Table 1). The degree of atrophy and ventricular enlargement was graded as mildest in the patients with Hunter syndrome. It was difficult to separate ex vacuo dilatation of the ventricles from hydrocephalus in all cases. Nevertheless, in general the degree of cerebral atrophy correlated with the degree of ventricular enlargement, making ex vacuo dilation most likely in the majority of the patients.

Mental retardation was more severe in the patients with Hunter or Hurler syndrome and milder in the patients with Sanfilippo A syndrome. The most severe degrees of mental retardation occurred in the two oldest children.

Correlating the various categories, we found in the children with Hunter syndrome, when the cribriform changes were graded as severe, the degree of white matter changes, atrophy, and ventricular enlargement were not as severe, and vice-versa. However, the degree of mental retardation did parallel the degree of white matter changes and especially the degrees of atrophy and ventricular enlargement. There was no correlation between the degree of cribriform changes and the degree of mental retardation.

In the children with Hurler syndrome, with the exception of one (patient 7 in Table 1), we found a similar inverse correlation occurred between the

degree of cribriform changes and the degrees of white matter changes, atrophy, and ventricular enlargement; when the degree of cribriform changes was graded as severe, the degrees of white matter changes, atrophy, and ventricular enlargement were less severe, being mild or moderate. Likewise the degree of mental retardation paralleled the degree of white matter changes and atrophy and ventricular enlargement. There was no correlation between the degree of cribriform changes and degree of mental retardation.

In the children with Sanfilippo A syndrome, we found a similar inverse correlation between the degree of cribriform changes and the degrees of white matter changes, atrophy, and ventricular enlargement. However, because the degree of mental retardation was mild in all of these patients, there appeared to be no correlation with the degree of cribriform changes, white matter changes, atrophy, or ventricular enlargement.

There were eight patients with associated cysts of the posterior fossa. Three had megacisterna magnas or Dandy-Walker complexes (5) with communication between the cyst and fourth ventricle, enlargement of the posterior fossa, and atrophy of the vermis. Of these three children two were brothers with Hunter syndrome (the third brother had no congenital anomalies). The other megacisterna magna occurred in a child with Hurler syndrome. Another child with Hurler syndrome had a Chiari type I hind-brain malformation but no associated syrinx of the spinal

cord. There were five with posterior fossa cysts, of which two were in children with Hunter syndrome and one with Hurler syndrome. The other two posterior fossa cysts occurred in children with Sanfilippo A syndrome. There were also three children with Hurler syndrome who also had temporal fossa arachnoid cysts medial to the temporal lobe; one of these three also had a megacisterna magna.

Discussion

MPSs are genetically inherited disorders of metabolism of GAG with lack of glycosidase, sulfatase, and nonhydrolytic transferase enzymes. The nondegraded GAG molecules accumulate in cells, tissues, and organs within the lysosomes, resulting in similar clinical presentations but with variable degrees of manifestation.

The Hurler syndrome is the prototypical MPS, one of the more severe forms, and is caused by lack of α -L-iduronidase. The other two types of MPS that we encountered were the severe form of Hunter syndrome (lack of iduronate sulfatase) and Sanfilippo A syndrome (lack of heparan N-sulfatase). The former two types are associated with severe somatic disease and all three with severe CNS involvement, which would eventually result in profound mental retardation.

The hallmark MR finding of these three types of MPS was the cribriform changes involving predominantly the corona radiata and periventricular white matter, followed by corpus callosum and, last, basal ganglia. The cerebellum, pons, and medulla appeared to be spared in our series (we do not know of any reports of involvement of these areas).

These cribriform changes were best appreciated on the T1-weighted images and appeared to be of low signal intensity, and of high signal intensity on the T2-weighted images. Sagittal and coronal images increased the detection of corpus callosum lesions, which tended to be perpendicular to the long axis of the callosum. These lesions did not enhance with gadopentetate dimeglumine. These have been described as "pits" (6), "cystic" (7), and "honeycomb" (8) changes corresponding pathologically to perivascular accumulation of GAG (9) within foam cells in the Virchow-Robin spaces (2, 10–12). Occurrence of Virchow-Robin spaces normally in the basal ganglia (13) probably accounts for the cribriform changes found here in MPS (6, 8).

The normal radial orientation (perpendicular to the long axis of the corpus callosum) of the white matter fibers in the corpus callosum probably influences the perpendicular orientation of these depositions of GAG (6, 7, 14). The orientation of the penetrating arterioles of the corpus callosum (arising from the pericallosal artery) is also perpendicular to the long axis of the corpus (15) and may influence the orientation of the GAG molecules, which tend to accumulate in the perivascular spaces.

Within our series there appeared to be an inverse relationship between the degree of cribriform changes and the degrees of atrophy, ventricular enlargement, and white matter changes. On the other hand, there did appear to be correlation with the degree of cribriform changes and nonsomatic expression of the disease documented by visceral organ involvement, and musculoskeletal abnormalities. Those patients with Hurler and Hunter syndromes graded as having severe cribriform changes often had multiple organ involvement, such as that of the liver and kidney, with impaired functions and severe musculoskeletal deformities. Involvement of the corpus callosum and basal ganglia occurred more often in patients graded as having severe cribriform changes. Involvement of the corpus callosum occurred more often with Hunter syndrome, less often with Hurler syndrome.

Degree of mental retardation did not correlate to degree of cribriform changes. This discrepancy may be caused by the difficulty in assessing mental retardation without intelligence quotient tests. And because the most severe degree of cribriform changes occurred in the youngest children between ages 1 and 2 years, the assessment of mental retardation based on social and developmental skills may not be as accurate. On the other hand, degree of mental retardation correlated well with degree of atrophy, ventricular enlargement, and white matter changes. This correlation would be expected, because loss of cerebral tissue should affect cognitive and intellectual skills.

Children with Hurler, Hunter, and Sanfilippo A syndromes have more severe visceral, musculoskeletal, and CNS involvement than those with the other forms of MPS. Because of severity of their disease, these children came to the bone-marrow transplant service as a last resort for therapy. This may explain why cribriform changes in the brain, a hallmark finding of GAG deposition, were present in all of our patients,

whereas they may not be present in the milder forms of MPS. Murata et al (6) suggests that absence of these lesions in patients with Scheie syndrome may allow differentiation from Hurler syndrome. In the same study they also noted that these lesions were absent in the mild form of Hunter syndrome. We did not study any of the milder forms of MPS. However, these cribriform changes have been reported to occur in other forms of MPS, including Scheie (MPS IS) (16), Hurler/Scheie (MPS IH) (17), and Maroteaux-Lamy (MPS VIA) syndromes (6).

The more severe degrees of cribriform changes occurred in the younger patients, suggesting that deposition of GAG in the perivascular spaces is the first pathologic change to occur. The cribriform changes appeared to have a predilection for the subcortical and periventricular white matter. The parietal lobe was involved in all cases with cribriform changes. Frontal and temporal lobe involvement occurred with more severe degrees of cribriform changes.

The abnormal periventricular white matter signal intensity changes and delayed myelination appeared to be more severe with Hurler syndrome. Before MR, studies based on computed tomography described periventricular low density in the white matter felt to be related to the perivascular deposition of GAG within the Virchow-Robin spaces (18, 19). Atrophy also appeared to be more pronounced in Hurler syndrome and correlated with severity of mental retardation in our series, a relationship reported by others (1, 18). It also was more severe in older patients, as one would expect with chronicity of the disease process.

Based on our observations we would propose the natural course of MPS as follows. Cribriform changes in the CNS are the hallmark of GAG deposition and occur first. It has been shown that the walls of the blood vessels are also thickened by collagen fibers, presumably a gliotic response to the GAG molecules, which are made by the mesenchymal tissues in the walls of the vessels (20). We would then propose that this thickening impairs delivery of blood to the brain, resulting in ischemic injury. Ischemic injury and neuronal damage results in loss of cerebral tissue and gliosis. Loss of cerebral tissue may explain why we observed a decrease in the numbers of cribriform lesions the longer the child was affected with MPS, or the older the child was. This would suggest that the lesions disappear or rather are replaced by gliosis. Both the presence of GAG

molecules and gliotic tissue response were probably responsible for the increased signal changes on T2-weighted images in the periventricular white matter. Normal brain development was also impaired resulting in delayed myelination and decreased gray and white matter contrast. Atrophy and ventricular dilatation eventually developed, representing end-stage changes.

Another finding that we observed, which to our knowledge has not been reported for MPS, was posterior fossa cysts. This consisted of megacisterna magna (or Dandy-Walker complex) or posterior fossa arachnoid cysts. There were also temporal fossa arachnoid cysts. The significance of this finding simply may reflect the superior imaging properties of MR in the posterior fossa compared with computed tomography, and may not necessarily be related to MPS.

In summary, high-field MR imaging can play a definitive role in determining the degree of cerebral involvement with MPS and aid in patient selection for bone marrow transplant. Once atrophy has occurred, transplant therapy may not be able to affect mental retardation. Therefore, the presence of severe atrophy may suggest a poor prognostic outcome with regard to mental function. Although mental retardation probably cannot be reversed by this therapy, its progression may be slowed or stopped (17). Optimal therapeutic intervention with regard to the CNS may be when cribriform changes are detected early in the disease process before atrophy. MR also has a potential for monitoring response to bone marrow transplantation as suggested by Johnson et al (2).

The most characteristic finding is cribriform or cystic changes best seen on T1-weighted images, which most likely represents undegraded glycosaminoglycan molecules within the perivascular spaces. Sagittal and coronal views increase the detection of corpus callosum involvement, which generally indicates more severe disease. Whether corpus callosal location becomes characteristic for MPS remains to be seen. Clearly, high-resolution imaging of the corpus callosum before MR has been limited, and the increased detection of corpus callosum lesions may reflect the superior imaging properties of MR.

Other lesions with predilection for the Virchow-Robin spaces, most notably cryptococcus and sarcoidosis, may produce cribriform changes but would be unlikely in infants and children, except for cryptococcus in immunosuppressed patients. However, cryptococcus also would manifest itself

with abnormal meningeal enhancement, particularly in the basal cisternal region, and would have a predilection for the basal ganglia and may exhibit a characteristic bubbly appearance (20).

The size, location, and numbers of the cribriform lesions as well as the young age would make dilated perivascular spaces less likely. However, in the cases of MPS with mild cribriform changes, particularly the Sanfilippo A type, the MR appearance was virtually indistinguishable from dilated perivascular spaces. To our knowledge, dilated perivascular spaces have not been reported in the corpus callosum. Lacunae and état criblé would be unlikely in the pediatric population.

Addendum

We have since studied two patients with Sanfilippo A syndrome at least 6 months after bone-marrow transplantation. Both patients developed severe mental retardation. On MR both patients showed progressive ventricular dilatation, atrophy, and white-matter changes graded as severe. There were no new cribriform lesions.

References

1. Neufeld EF, Muenzer J. The mucopolysaccharidoses. In: Scriver CR, et al, eds. *The metabolic basis of inherited disease*. New York: McGraw-Hill, 1989:1565-1587
2. Johnson MA, Desai S, Hugh-Jones K, et al. Magnetic resonance imaging of the brain in Hurler syndrome. *AJNR: Am J Neuroradiol* 1984;5:816-819
3. Barkovich AJ, Lyon G, Evrad P. Formation, maturation, and disorders of white matter. *AJNR: Am J Neuroradiol* 1992;13:447-461
4. *Diagnostic and statistical manual of mental disorders*. Washington, D.C.: American Psychiatric Association, 1987;2:8-33
5. Barkovich AJ, Kjos BO, Norman D, et al. Revised classification of posterior fossa cysts and cyst-like malformations based on the results of multiplanar MR imaging. *AJNR: Am J Neuroradiol* 1989;10:977-988
6. Murata R, Nakajima S, Tanaka A, et al. MR imaging of the brain in patients with mucopolysaccharidosis. *AJNR: Am J Neuroradiol* 1989;10:1165-1170
7. Afifi AK, Yutaka S, Waziri MH, et al. Computed tomography and magnetic resonance imaging of the brain in Hurler's disease. *J Child Neurol* 1990;5:235-241
8. Shimoda-Matsubayashi S, Kuru Y, Sumie H, et al. MRI findings in the mild type of mucopolysaccharidosis II (Hunter's syndrome). *Neuroradiology* 1990;32:328-330
9. Green MA. Gargoylism (lipochondrodystrophy). *J Neuropathol Exp Neurol* 1948;76:399-416
10. Winters PR, Harrod MJ, Molenich-Heetred SA, et al. α -L-Iduronidase deficiency and possible Hurler-Scheie genetic compound. Clinical, pathologic, and biochemical findings. *Neurology* 1976;26:1003-1007
11. Watts RWE, Spellacy E, Adams JH. Neuropathological and clinical correlations in Hurler disease. *J Inherited Metab Dis* 1986;9:261-272
12. Norman RM, Ulrich H, Rance NE. Perivascular cavitation of the basal ganglia in gargoylism. *J Ment Sci* 1959;105:1070-1077
13. Braffman BH, Zimmerman RA, Trojanowski JQ, et al. Brain MRI: pathologic correlation with gross and histopathology I. Lacunar infarction and Virchow-Robin spaces. *AJNR: Am J Neuroradiol* 1988;9:621-628
14. Naidoo D. Gargoylism (Hurler's disease): a neuropathological report. *J Ment Sci* 1953;99:74-83
15. Salamon G, Huang YP. *Radiologic anatomy of the brain*. New York: Springer-Verlag, 1976:49-50,198
16. Kulkarni MV, Williams JC, Yeakley JW, et al. Magnetic resonance imaging in the diagnosis of the cranio-cervical manifestations of the mucopolysaccharidoses. *Magn Reson Imaging* 1987;5:317-323
17. Hugh-Jones K. Psychomotor development of children with mucopolysaccharidoses type 1-H following bone marrow transplantation. *Birth Defects* 1986;22:25-32
18. Nelson J, Grebbell FS. The value of computed tomography in patients with mucopolysaccharidosis. *Neuroradiology* 1987;29:544-549
19. Watts RWE, Spellacy E, Kendall BE, et al. Computed tomography studies on patients with mucopolysaccharidoses. *Neuroradiology* 1981;21:9-23
20. Tien RD, Chu PK, Hesselink JR, et al. Intracranial cryptococcus in immunocompromised patients: CT and MR findings in 29 cases. *AJNR: Am J Neuroradiol* 1991;12:283-289