



## Discover Generics

Cost-Effective CT & MRI Contrast Agents

 FRESENIUS  
KABI

[WATCH VIDEO](#)

# AJNR

## **Intramedullary abscess, an unusual manifestation of a dermal sinus.**

J M Rogg, D L Benzil, R L Haas and N W Knuckey

*AJNR Am J Neuroradiol* 1993, 14 (6) 1393-1395

<http://www.ajnr.org/content/14/6/1393.citation>

This information is current as  
of June 1, 2025.

# Intramedullary Abscess, an Unusual Manifestation of a Dermal Sinus

Jeffrey M. Rogg,<sup>1</sup> Deborah L. Benzil,<sup>2</sup> Richard L. Haas<sup>1</sup> and Neville W. Knuckey<sup>2</sup>

**Summary:** The authors describe the clinical manifestations and present MR findings in a case of an intramedullary abscess, a potentially lethal lesion, which was the result of infection of a dermal sinus.

**Index terms:** Spine, abscess; Epidermoid cyst; Spinal cord, cysts; Spinal cord, magnetic resonance; Pediatric neuroradiology

Dermal sinuses are well-characterized lesions (1–3). A patient with a dermal sinus frequently has a hairy nevus or dimple overlying the tract. Yet, despite having this cutaneous marker, these patients often seek medical attention only after they suffer an infectious complication of the tract. Although infection most commonly will occur in the form of a cutaneous abscess, another more serious and not uncommon manifestation is meningitis. Rarely, infection may result in an intramedullary abscess (2, 3).

## Case Report

A 2-year-old girl with spina bifida occulta was evaluated at another institution for complaints of abdominal pain. She was admitted with a presumed diagnosis of gastroenteritis and treated symptomatically. She improved and was discharged after 2 days, and she did well until 4 days later when she fell off a counter 1 m high, landing on her back. There was no trauma to the head, loss of consciousness, or specific complaints at that time. The following morning, her parents noted that she was dragging her left foot and unable to bear weight on her left leg. Over the next 24 hours, she did not void. She returned to the hospital for evaluation. The patient was noted to be anorectic, irritable, and listless.

Initial physical examination revealed a young girl in no apparent distress who was afebrile with normal vital signs. Her neck was supple with full range of motion. A hair patch and small external opening were present over the lower lumbar region. No spinal processes were palpable in this

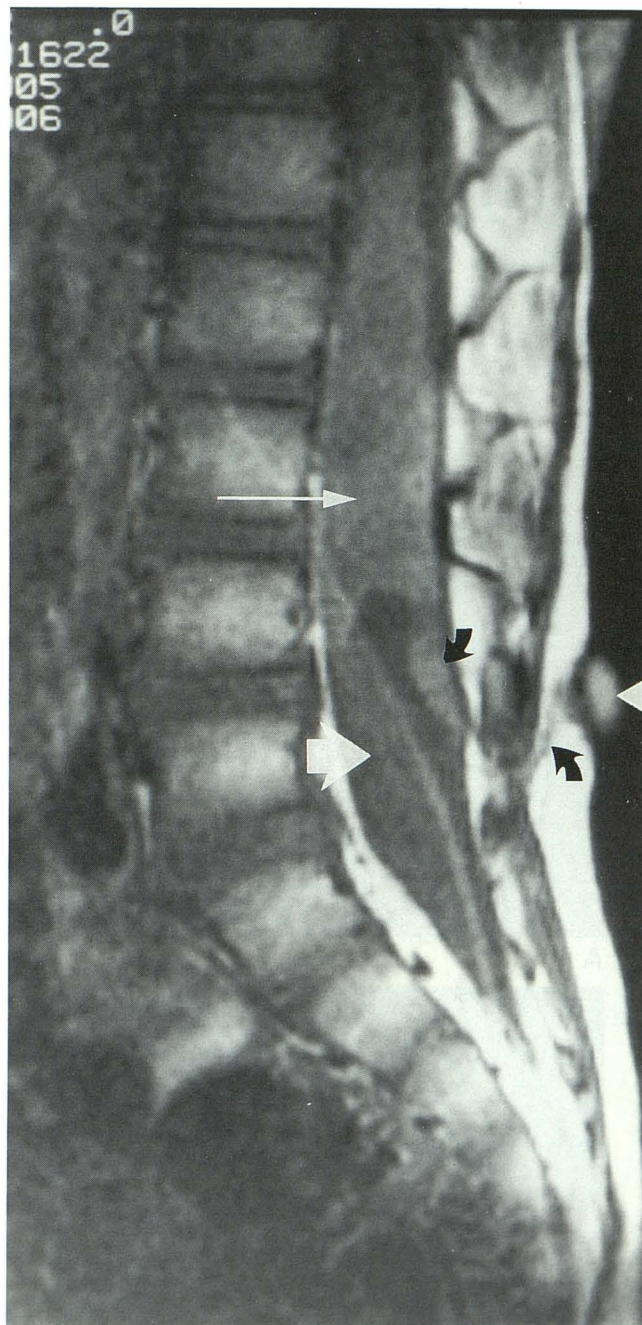


Fig. 1. Sagittal T1-weighted image (600/20). Spinal cord tethering is noted to the L3 to L4 level. The dermal sinus tract is identified at the skin surface by a Vit E marker (*white arrowhead*). Tract extension subcutaneously and intradurally is also identified (*curved black arrows*). The area of focal cord expansion representing the site of intramedullary abscess is shown (*white arrow*). An epidermoid tumor is noted inferior to and insinuating itself into the conus (*large white arrow*). A linear artifact extends obliquely across the image.

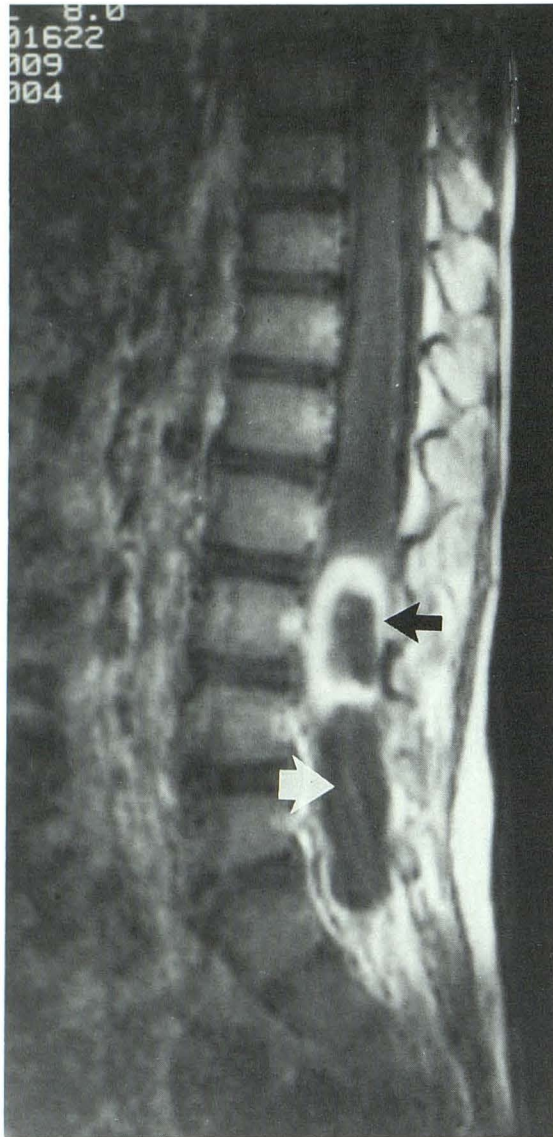
Received December 18, 1991; revision requested February 3, 1992; final revision received and accepted November 4.

Departments of <sup>1</sup>Diagnostic Imaging and <sup>2</sup>Neurosurgery, Rhode Island Hospital, Brown University Program in Medicine, 593 Eddy Street, Providence, RI 02902. Address reprint requests to Jeffrey M. Rogg, MD.

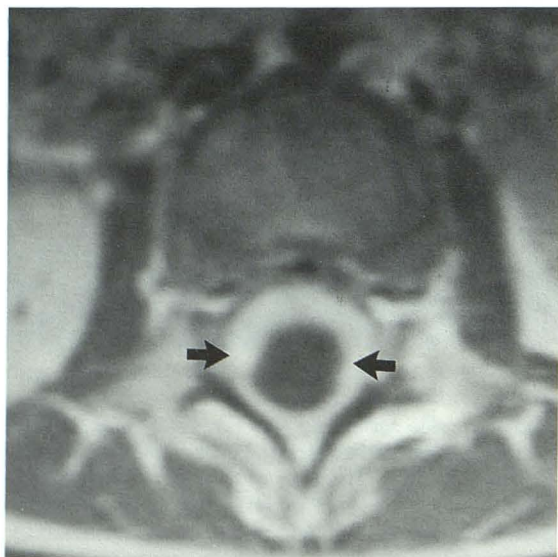
AJNR 14:1393–1395, Nov/Dec 1993 0195-6108/93/1406–1393

© American Society of Neuroradiology





A



B

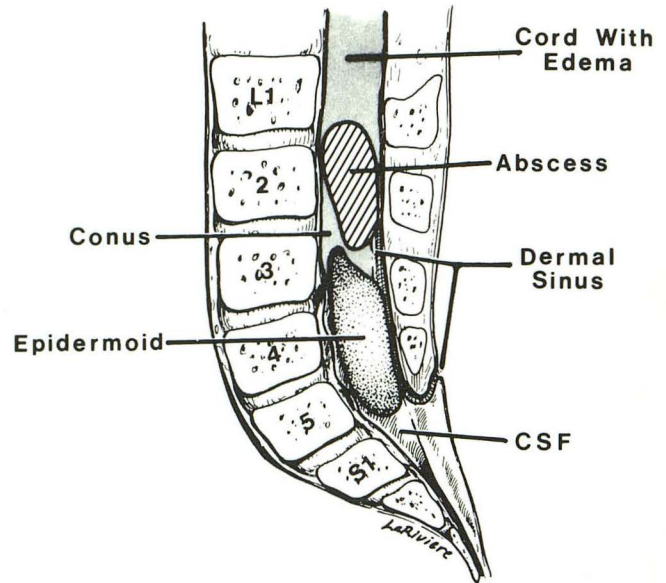


Fig. 3. Line drawing demonstrates the relationship of the spinal cord, abscess, sinus tract, and dermoid noted at surgery.

area. Muscle strength in both lower extremities was strong proximally and weak (1/5) distally with decreased muscle tone below both knees. Knee-jerk and Achilles tendon reflexes were absent. Laboratory examinations were significant only for a peripheral white blood cell count of 12,800 and an erythrocyte sedimentation rate of 17.

Magnetic resonance images were obtained on a 1.5-T system. Sagittal and axial spin-echo images 600/20/2 (repetition time/echo time/excitations) were acquired before and after administration of gadopentetate dimeglumine (0.1 mmol/kg). Nonenhanced images demonstrated a sinus tract extending intradurally and tethering of the spinal cord to the lumbar vertebra 4 (L4) level (Fig 1). The conus was noted to be markedly expanded, with heterogeneously decreased T1 signal intensity. Cord expansion existed to the L1 level. Inferior to the cord, there was an area of homogeneously decreased T1 signal intensity, isointense to cerebrospinal fluid (CSF), deforming the inferior aspect of the conus. After administration of contrast material, thick irregular ring enhancement appeared within the broadest area of the spinal cord centered at the L2 to L3 level (Fig 2). An expanded hypointense cord is noted extending to the L1 level.

At surgery (Fig 3) the dermal sinus tract was followed through the subcutaneous tissue and lumbar fascia and traced between the spinous processes of L4 to L5 where it entered the dura. The dermal sinus was found to enter a pearly tumor that originated rostrally as an intramedullary lesion of the lower end of the conus medullaris at L3 and

Fig. 2. Sagittal (A) and axial (B) T1-weighted series (600/20). After administration of gadopentetate dimeglumine (0.1 mmol/kg) peripheral enhancement of the intramedullary abscess is shown (black arrow). Nonenhancing epidermoid is again noted inferior to the enhanced abscess cavity (large white arrow). Reactive cord edema results in cord expansion to the T10 level.



extended distally to L5 with the nerve roots of the cauda equina draped laterally around the extramedullary portion of the lesion. Intraoperative ultrasound demonstrated an intramedullary cystic cavity within the swollen cord. A 15-gauge needle inserted at the L2 to L3 level aspirated approximately 4 ml of green purulent material, so a small midline myelotomy was made to completely drain the intramedullary abscess. After complete drainage of this purulent collection, the epidermoid tumor was dissected from the conus and nerve roots and removed completely.

Microbial analysis of the abscess aspirate grew *Escherichia coli*, *Bacteroides fragilis*, and *Proteus mirabilis*. The patient was treated with appropriate intravenous antibiotics and rapidly regained neurologic function. Follow-up ultrasound demonstrated evidence of a collapsed cavity within the conus and resumption of normal cord size and overall echogenicity.

## Discussion

Intramedullary abscess is the least common infectious presentation of a dermal sinus (4–6). More common presentations are meningitis and epidural abscess (7). The clinical presentation of intramedullary abscess will vary. In previously reported cases symptoms have included incontinence (88%), paraplegia (72%), and paraparesis (11%). Normal motor function also has been reported (17%) (8).

Rapid diagnostic evaluation for potential intramedullary abscess is indicated in any patient with a dermal sinus presenting with the above-noted spectrum of symptoms, as the quality of clinical improvement will relate to the rapidity of diagnosis and the degree of preoperative deficit (8).

Magnetic resonance appears well suited to the detection of intramedullary abscess. Cord expansion was clearly seen, as well as heterogeneous hypointense signal within the area of expansion on short repetition time sequences. After administration of gadopentetate dimeglumine, localized

peripheral enhancement of the hypointense zone defined the abscess cavity from the adjacent cord edema (Figs 1, 2A, and 2B).

In the presented case, an epidermoid cyst was found at surgery extending caudally from the conus, distal to the abscess cavity, inferior to the conus (Fig 3). This cyst was difficult to discern on short-repetition time, short echo time images, aside from its deforming effect on the conus.

In conclusion, the diagnosis of intramedullary abscess should be considered and aggressively ruled out in any patient with a dermal sinus who presents with symptoms of a partial or complete transverse myelitis and/or cerebrospinal fluid suggesting meningitis. Immediate contrast-enhanced MR evaluation of the spinal cord in the region of the dermal sinus would appear to be both a useful and directed first step in this evaluation.

## References

1. Barkovich AJ, Edwards MS, Cogen PH. MR evaluation of spinal dermal sinus tracts in children. *AJNR: Am J Neuroradiol* 1991;12:1453–1460
2. Naidich TP, McLane DG, Hawood-Nash DC. Spinal dysraphism. In: Newton TH, Potts DG, eds. *Modern neuroradiology*. Vol 1. Computed tomography of the spine and spinal cord. San Anselmo, Cal: Claudel, 1982:299–353
3. Wright RL. Congenital dermal sinuses. *Prog Neurol Surg* 1971;4:175–191
4. Foley J. Intramedullary abscess of the spinal cord. *Lancet* 1949;2:193–195
5. Gindi SE, Fairburn B. Intramedullary spinal abscess as a complication of congenital dermal sinus. *J Neurosurg* 1969;30:494–497
6. Matson DD, Ingraham FD. Intracranial complications of congenital dermal sinuses. *Pediatrics* 1951;8:463–474
7. Maurice-Williams RS, Pamphilon D, Coakham HB. Intramedullary abscess - a rare complication of spinal dysraphism. *J Neurol Neurosurg Psychiatry* 1980;43:1045–1048
8. DiTullio MV. Intramedullary spinal abscesses: a case report with a review of 53 previously described cases. *Surg Neurol* 1977;7:351–354