



Discover Generics

Cost-Effective CT & MRI Contrast Agents



FRESENIUS
KABI

WATCH VIDEO

AJNR

MR of superficial siderosis.

A C Mamourian

AJNR Am J Neuroradiol 1993, 14 (6) 1445-1448

<http://www.ajnr.org/content/14/6/1445.citation>

This information is current as
of June 5, 2025.

LETTERS

Role of MR Imaging in the Evaluation of the Functional Status of the Posterior Pituitary Gland: The View of a Pediatric Endocrinologist

Moses et al describe 18 patients with polyuria and polydipsia of different origins (six with primary polydipsia, eight with neurogenic diabetes insipidus [DI], and four with nephrogenic DI) in whom magnetic resonance (MR) of the posterior pituitary gland made it possible to differentiate patients with central DI from those with primary polydipsia (1). Posterior pituitary hyperintensity was present in the patients with primary polydipsia, absent in all those with central DI, and lacking in three out of the four patients with nephrogenic DI.

The differential diagnosis of DI is achieved via a series of steps beginning with routine clinical observations and then proceeding to more sophisticated methods of laboratory analysis and finally imaging. MR sheds a new light in the hypothalamic-pituitary area, identifying the characteristically hyperintense signal of the posterior pituitary gland, which appears to be a hallmark of the "functional integrity" of the hypothalamic-neurohypophyseal tract. However, this appears to be only partially correct.

We recently reported the results of the correlation between MR of posterior pituitary and neurohypophyseal function in children with DI of different origins: familial autosomal dominant, idiopathic, secondary to craniopharyngioma, langerhans cell histiocytosis, excessive water intake, renal vasopressin insensitivity, and osmoreceptor dysfunction (2, 3). Unexpectedly, three of our patients (two with autosomal-dominant DI and one with idiopathic DI) treated with 1-desamino-8-D-arginine vasopressin because of central DI showed a normal bright posterior pituitary signal (2); the hyperintensity is still present after 2-year MR follow-up. Moreover, in one patient with excessive water intake simulating partial neurogenic DI the hyperintensity of the posterior pituitary was recognized (4). The presence of normal hyperintensity of the posterior pituitary gland was also reported in two out of five members of the same family with autosomal-dominant DI (5).

If, as suggested by Kucharczyk (6), we should be very cautious in attributing any possible functional significance to the lack of hyperintensity of the neurohypophysis, what can we conclude about the posterior pituitary function in patients with central DI and posterior pituitary hyperintensity? What can we expect from the MR of the posterior pituitary gland in the presence of transitory-central DI, partial-central DI, and partial-nephrogenic DI—the biochemical differential diagnosis of which may be sometimes very difficult—absence of bright signal? Small bright signal? Normal bright signal? Bright signal sometimes present and sometimes absent?

Posterior pituitary hyperintensity occasionally may be observed in patients with central DI. This is in contrast with the apparently clear-cut definition stated in the paper by

Moses et al (1) (ie, absence of bright signal in neurogenic DI and its presence in primary polydipsia) as well as in a previous statement by Tien that "the presence of a bright signal is inconsistent with the diagnosis of DI" (7). These rigid categorical conclusions may create some confusion and uncertainty.

We believe that *posterior pituitary bright signal in DI does not necessarily indicate that the functional integrity of the hypothalamic-neurohypophyseal axis is preserved, but only that normal packaging of the hormone has occurred, though not necessarily its release, which might be impaired by local proteolytic degradation* (8). The absence of MR posterior pituitary signal in patients with clinical and biochemical evidence of central DI represents the final stage of neurosecretory hypothalamic depletion (perhaps the end result of lesions?) and consequent functional exhaustion. Because it is well known that neurogenic DI develops when more than 80% of the paraventricular-supraoptic neurons are destroyed, the evolution of the posterior pituitary hyperintensity needs to be clarified by MR follow-up studies of patients with central DI and bright posterior signal.

What is the role of MR in the diagnosis and treatment of DI, from the point of view of the pediatric endocrinologist? MR is the most fascinating and valuable method of imaging; it makes a substantial contribution to our understanding of the basic pathophysiologic abnormality of the DI of many of our patients and sometimes alone plays a functional diagnostic role (2). The differential diagnosis of DI is still exclusively clinical and biochemical. MR is not informative for therapeutic decisions and so cannot be considered in the first-line evaluation of polyuric and polydipsic conditions. It does, however, help to rule out organic lesions responsible for central DI.

M. Maghnie
M. G. Sommaruga
G. Beluffi
F. Severi

*Departments of Pediatrics, Radiology, and Pediatric
Radiology
IRCCS
Policlinico S. Matteo
University of Pavia
Pavia, Italy*

References

1. Moses AM, Clayton B, Hochhauser L. Use of T1-weighted MR imaging to differentiate between primary polydipsia and central diabetes insipidus. *AJNR: Am J Neuroradiol* 1992;13:1273-1277
2. Maghnie M, Villa A, Arico' M, et al. Correlation between magnetic resonance imaging of posterior pituitary and neurohypophyseal function in children with diabetes insipidus. *J Clin Endocrinol Metab* 1992;74:795-800

3. Maghnie M, Arico' M, Villa A, Genovese E, Beluffi G, Severi F. MR of the hypothalamic-pituitary axis in langerhans cell histiocytosis. *AJNR: Am J Neuroradiol* 1992;13:1365-1371
4. Salvatori A, Maghnie M, Lorini R, Marni E. Hyponatremia and seizures during desmopressin acetate treatment in hypothyroidism. *J Pediatr* 1990;116:835-836
5. Miyamoto S, Nasaki N, Tanabe Y. Magnetic resonance imaging in familial central diabetes insipidus. *Neuroradiology* 1991;33:272-273
6. Kucharczyk W. MR of the pituitary gland: functional imaging. *AJNR: Am J Neuroradiol* 1992;13:1293-1294
7. Tien R, Kucharczyk J, Kucharczyk W. MR imaging of the brain in patients with diabetes insipidus. *AJNR: Am J Neuroradiol* 1991;12:533-542
8. Schmale H, Richter D. Single base deletion in the vasopressin gene is the cause of diabetes insipidus in brattleboro rats. *Nature* 1984;308:705-709

Reply

We will confine our comments to the value of the presence or absence of the hyperintense signal of the posterior pituitary gland in evaluating the cause of a patient's excretion of a large amount of dilute urine when the possibility of nephrogenic DI has been ruled out by a deficient antidiuretic response to arginine vasopressin (AVP) or desmopressin, or if necessary by finding elevated levels of AVP in blood or urine (1-3). The focus is on the potential problem of improperly distinguishing between primary polydipsia and central DI on the basis of the presence or absence of the hyperintense signal of the neural lobe, conducted properly by T1-weighted MR imaging. We have now studied a total of 13 adult patients with hypothalamic DI either caused by trauma, germinoma, suprasellar epidermoid cyst, sarcoidosis, lymphoma, and metastatic carcinoma of the breast and lung, or idiopathic, in addition to seven patients with primary polydipsia. In these studies (which do not include patients with autosomal-dominant hypothalamic DI), the hyperintense signal has *always* been absent in patients with hypothalamic DI and present in those with primary polydipsia. When the patient had both causes of vasopressin-sensitive hypotonic polyuria, the hyperintense signal was absent. We have evaluated one patient who illustrates the last point. This is a 34-year-old black man with vasopressin-sensitive hypotonic polyuria who repeatedly developed hyponatremia with dilute urine when untreated with either AVP or desmopressin. This is considered diagnostic of primary polydipsia. However, the hyperintense signal of his neural lobe was absent. An osmotic threshold study conducted by saline infusion (4) revealed no antidiuresis and very low levels of plasma AVP with a plasma osmolality as high as 305 mOsm/kg. This patient with sarcoidosis therefore had both central DI and an excessive thirst mechanism, and a diagnosis would almost certainly have been erroneous if the MR had not been obtained. To emphasize, the absence of the hyperintense signal in the properly conducted radiologic study means that the patient does not have primary polydipsia unless there is an associated central DI. The other potential problem, that of falsely diagnosing primary polydipsia because of the presence of the hyperintense signal when the

patient truly has central DI caused by osmoreceptor failure, was commented on in our paper. Although we have studied a woman with symptomatic central DI from birth who had an absent hyperintense signal, we do not challenge Dr Maghnie and associates in their claim that the hyperintense signal may be present in patients with hereditary hypothalamic DI (5). The hyperintense signal was also found by Miyamoto et al in two of five patients with familial hypothalamic DI (6). Molecular biologic studies in a small number of these patients have revealed a single-base substitution of one AVP-neurophysin gene allele (7). This mutation converts a glycine to a valine in the vasopressin precursor protein, which in turn causes DI by interfering with the patient's ability to process and release AVP with appropriate stimuli (7). In these subjects the secretion rather than the synthesis of AVP is impaired. We therefore agree that *caution must be exercised when interpreting a positive hyperintense signal in patients with a family history of hypothalamic DI whose symptoms develop before the age of 6 years* (polyuria in these patients usually begins between the ages of 2 and 6 years).

In our experience, the presence or absence of the hyperintense signal has accurately differentiated between primary polydipsia and hypothalamic DI even when the only means of establishing the correct diagnosis was by doing osmotic threshold studies, which are demanding and difficult to perform except in very specialized research settings. This is especially so because patients with primary polydipsia may have modestly depressed AVP levels in relation to plasma osmolality, which become close to values observed in patients with partial central DI (8).

We agree with the editorial comment by Dr Kucharczyk that "the presence of the signal indicates normal vasopressin stores and therefore, an intact neurohypophyseal system," and "MR can assess neurohypophyseal reserves of neurosecretory material, and qualifies MR as a functional imaging method for the posterior pituitary gland" (9). There may be a problem in the occasional patient who has adequate stores of AVP that cannot be released properly into the circulation (autosomal-dominant hypothalamic DI or osmoreceptor failure). The problem as it relates to patients with autosomal-dominant hypothalamic DI must continue to be evaluated in additional families, as does the problem of subtle changes in the hyperintense signal in incomplete disease states. These questions are being addressed at our institution by improved investigational MR techniques.

Arnold M. Moses
Leo Hochhauser

State University of New York Health Science Center
Syracuse, New York 13210

References

1. Moses AM, Streeten DHP. Disorders of the neurohypophysis. In: Braunwald E, Isselbacher KJ, Petersdorf RG, et al, eds. *Harrison's principles of internal medicine*. New York: McGraw-Hill, 1990:1682-1691

2. Moses AM. Clinical and laboratory observations in the adult with diabetes insipidus and related syndromes. *Front Horm Res* 1985;13:156-175
3. Moses AM. Clinical and laboratory features of central and nephrogenic diabetes insipidus and primary polydipsia. In: Reichlin S, ed. *Neurohypophysis*. New York: Plenum, 1984:115-138
4. Moses AM, Streeten DHP. Differentiation of polyuric states by measurement of responses to changes in plasma osmolality induced by hypertonic saline infusions. *Am J Med* 1967;42:368-377
5. Maghnie M, Villa A, Arico M, et al. Correlation between magnetic resonance imaging of posterior pituitary and neurohypophyseal function in children with diabetes insipidus. *J Clin Endocrinol Metab* 1992;74:795-800
6. Miyamoto S, Sasaki N, Tanabe Y. Magnetic resonance imaging in familial central diabetes insipidus. *Neuroradiology* 1991;33:272-273
7. Bahnsen U, Oosting P, Swaab DF, et al. A missense mutation in the vasopressin-neurophysin precursor gene cosegregates with human autosomal dominant neurohypophyseal diabetes insipidus. *EMBO J* 1992;11:19-23
8. Moses AM, Clayton B. Impairment of osmotically stimulated AVP release in patients with primary polydipsia. *Am J Physiol* (in press)
9. Kucharczyk W. MR of the pituitary gland: functional imaging? *AJNR: Am J Neuroradiol* 1992;13:1293-1294

Editor's note: This letter was sent to Dr Robert Tien for additional comment. His reply follows.

Reply

I have read with interest the manuscript of Dr Maghnie's correlation between MR imaging of the posterior pituitary and neurohypophyseal function in children with DI.

Both the data from this manuscript and my own personal experience would indicate that absence of the posterior pituitary bright spot is abnormal in most instances (1). Caution, however, still should be used, as in some healthy patients a normal posterior pituitary bright spot cannot be demonstrated possibly secondary to the imaging technique. I have previously reported that in my clinical experience, patients with central DI will lack a normal posterior pituitary bright spot on MR (1). I am pleased to learn from Dr Maghnie that there are cases, however, of patients with central DI that have a normal posterior pituitary bright spot. This would indicate to me that a heterogeneous group of lesions may comprise the category of central DI and in certain cases may show a normal posterior pituitary bright spot. I am pleased that MR has been used to investigate this heterogeneous group of conditions and, in fact, does show a difference between several causes of central DI. It is interesting to speculate that in cases of central DI with a normal posterior pituitary bright spot, a defect in normal release of hormone may explain the presence of a normal signal and absent function.

On the basis of the data presented in Dr Maghnie's work, I would disagree with the conclusion that the difference of diagnosis of DI is exclusively clinical and biochemical and that MR is not informative for therapeutic decisions: it is clear that only with MR can diagnoses of pathologic conditions, including craniopharyngioma and langerhans cell histiocytosis, be made. Of 20 cases presented in his work,

11 had one of these two conditions, and therefore, I would suggest that MR should be considered in the first-line evaluation of these conditions.

Robert D. Tien
Department of Radiology
Duke University Medical Center
Durham, NC 27710

References

1. Tien RD, Kucharczyk J, Kucharczyk W. MR imaging of the brain in patients with diabetes insipidus. *AJNR: Am J Neuroradiol* 1991;12:533-542

MR of Superficial Siderosis

I found the report "Ependymoma of the Cauda Equina Presenting with Subarachnoid Hemorrhage" in the March issue most interesting (1). I was, however, surprised to see no mention in the article of the presence of superficial siderosis of the distal spinal cord which was well demonstrated in their Figure 1B. I thought this notable in light of the article by Bracchi et al in your January edition on superficial central nervous system siderosis, which included a similar illustration of spinal cord siderosis (2). We also encountered a case of a cauda equina tumor with superficial siderosis (Fig 1). This 72-year-old woman, after 4 months of progressive weakness, presented with bowel and bladder dysfunction. Left-sided hearing loss was noted on exam. Lumbar MR demonstrated an enhancing intraspinal mass at L3-4 and superficial siderosis of the conus. Additional imaging demonstrated superficial siderosis of the entire spinal cord and brain stem as well. The lumbar mass was resected and proved to be a paraganglioma. Although this seemed an uncommon explanation for the extensive superficial siderosis, a subsequent evaluation including cerebral angiography and enhanced MR of the entire spine failed to demonstrate another bleeding site. Such cases emphasize the need to evaluate the brain and spinal canal in patients with superficial siderosis.

Alexander C. Mamourian, MD
Department of Radiology
Pennsylvania State University
Milton S. Hershey Medical Center
Hershey, PA 17033

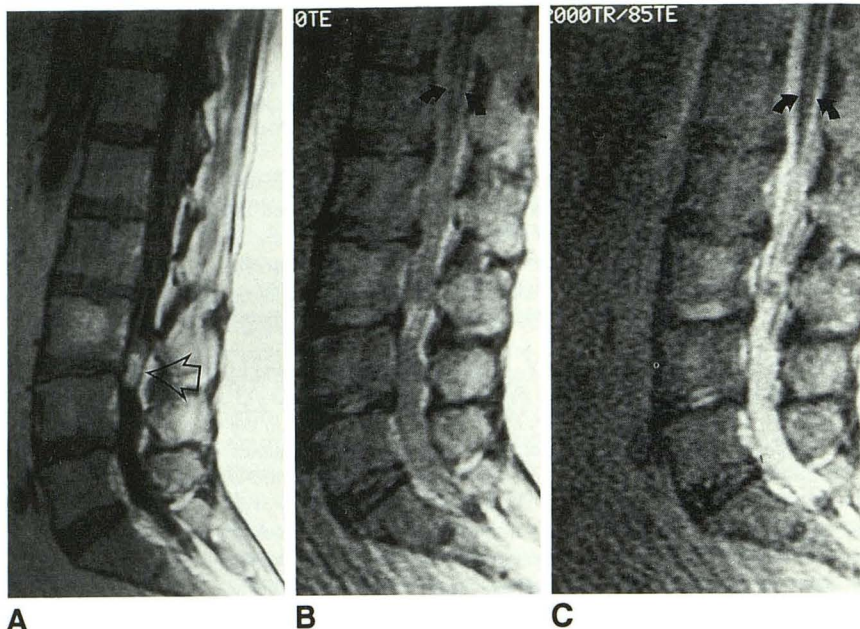
References

1. Shen W, Ho Y, Lee S, Lee K. Ependymoma of the cauda equina presenting with subarachnoid hemorrhage. *AJNR: Am J Neuroradiol* 1993;14:399-401
2. Bracchi M, Savoiardo M, Triulzi F, et al. Superficial siderosis of the CNS: MR diagnosis and clinical findings. *AJNR: Am J Neuroradiol* 1993;14:227-237

Reply

After careful reading of our report Dr Mamourian writes that we neglected to mention the superficial siderosis of

Fig. 1. The enhanced sagittal T1-weighted scan (A) (500/20/2 [repetition time/echo time/excitations]) revealed an enhancing intraspinal paraganglioma at the L3-4 level (*open arrow*). The sagittal 2000/40 (B) and 2000/85 (C) scans demonstrated low signal intensity along the surface of the distal spinal cord, consistent with superficial siderosis (*arrows*).



the distal spinal cord. In the article to which he refers, Bracchi et al mentioned that repeated hemorrhages from tumors, especially ependymoma, is one of the causes of superficial siderosis in the brain and the spinal cord. Indeed, our patient had well-documented repeated tumor bleeding. Ten months before the surgery for removal of the tumor, she suffered from severe headache, vomiting, and neck stiffness, and bloody cerebrospinal fluid (CSF) was found in a lumbar puncture. Because there were no symptoms related to the lumbar spine, meningitis was diagnosed and treated accordingly, and the bloody CSF was mistakenly attributed to traumatic tapping. Ten months later, the patient presented with another episode of the above symptoms, and again bloody CSF was found by a lumbar puncture, so carotid angiography was requested by the clinician for the possibility of any intracranial vascular anomaly. However, because computed tomography (CT) of the brain showed no evidence of visible subarachnoid hemorrhage (Fig 2), we did not think the bleeding source was intracranial. At that time, the patient had soreness of the back and both legs, so MR study of the lumbar spine was performed. Although acute hemorrhage in the tumor and blood mixed with the CSF distal to the tumor were found (1), because of our lack of knowledge we did not notice the possible superficial siderosis on the spinal cord and brain; therefore, MR of the whole spinal cord and brain was not performed.

We thought the best reply to Dr Mamourian's comment was to call the patient back for a follow-up MR, which was done 4 years after the surgery. T2-weighted images of the lumbar spine showed no recurrence of spinal tumor in the surgical region, and there was still superficial siderosis on the spinal cord (Fig 3A). To our surprise, there was diffuse superficial siderosis on the brain stem, superior vermis of the cerebellum, proximal cervical spinal cord, Sylvian fissures, and other infratentorial and supratentorial subarach-

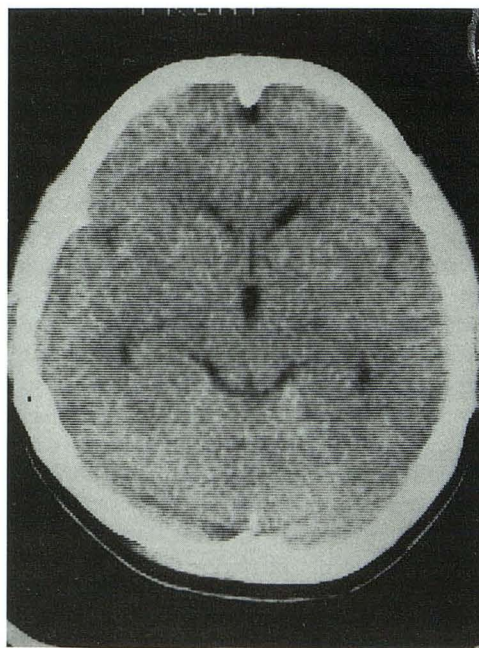


Fig. 2. Plain CT of the brain (September 4, 1989). Clinically the patient had severe headache, vomiting, neck stiffness, and bloody CSF. There was no visible subarachnoid hemorrhage on the CT scan. However, there was slight dilatation of the temporal horns of both lateral ventricles, suggesting that the patient had subarachnoid hemorrhage at that time.

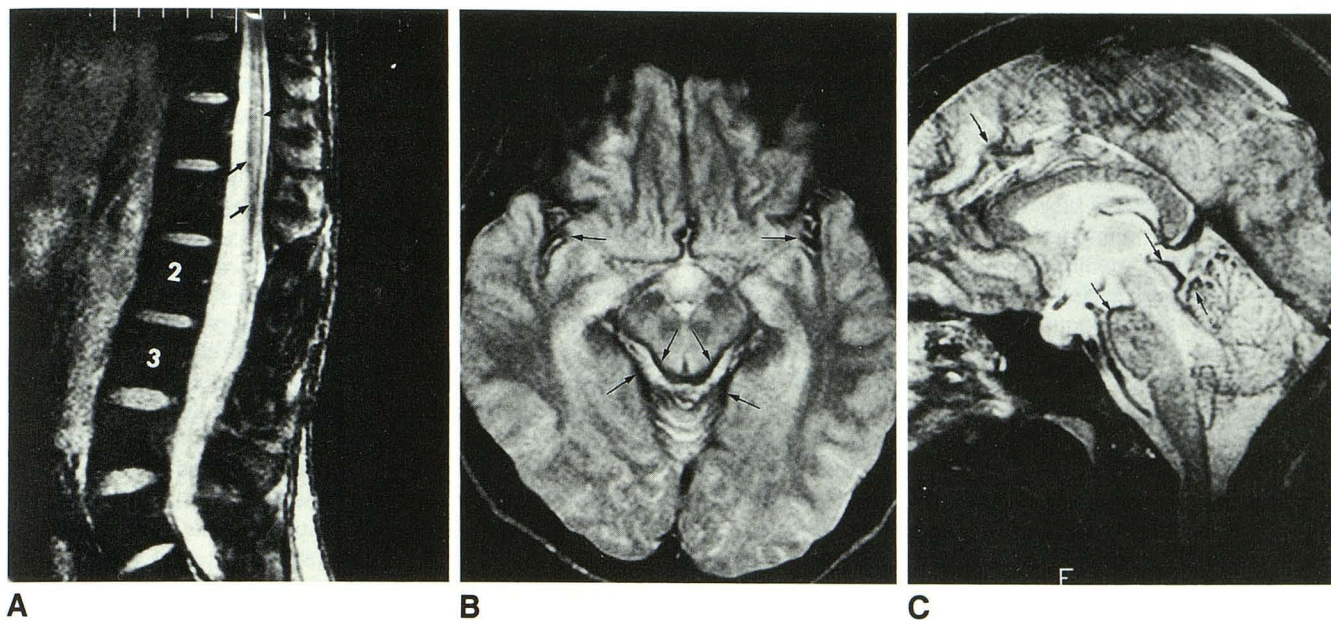


Fig. 3. MR of the spine and the brain (June 5, 1993) 4 years after the caudal equina ependymoma was surgically removed.
 A, Gradient-echo T2-weighted image (400/18, flip angle 10°). There is no recurrent tumor at the L2–3 level. There is siderosis on the surface of the spinal cord (arrows).
 B, T2-weighted image (2600/80/1). Marked siderosis on the surface of the midbrain and the Sylvian fissures (arrows).
 C, T2-weighted image (2600/80/1). Diffuse superficial siderosis in the anterior aspect of the pons, medulla oblongata, tectum of the midbrain, proximal spinal cord, superior vermis, and even in the sulci of frontal lobe (arrows).

noid spaces (Figs 3B and 3C). Now, the patient feels no discomfort, except occasionally mild headache and tinnitus. We already have informed the patient of the possibility of hearing impairment and ataxia in the very far future based on Bracchi's experience and have asked the patient to undergo follow-up MR regularly.

Wu-Chung Shen
 Yung-Jen Ho
 San-Kan Lee
 Kuan-Rong Lee

Department of Radiology
 Taichung Veterans General Hospital
 Taichung, 407 Taiwan, Republic of China

Editor's note: The letter from Dr Mamourian was also referred to Dr Bracchi for his comments. *AJNR* readers will be saddened to learn that Dr Bracchi died tragically in a skiing accident in February 1993. However, his colleagues have kindly agreed to comment on this issue.

Reply

We observed with interest the case of superficial siderosis of the spinal cord associated with an ependymoma of the cauda equina reported by Shen et al and the case of paraganglioma described above by Mamourian. In the May issue of the *AJNR* there is another case of siderosis, related to anticoagulant therapy (1). Since we submitted our paper

we observed two other cases of superficial siderosis of the central nervous system, one spontaneous, the other associated with a cerebellar pilocytic astrocytoma subtotally removed in 1979 and 1982, and causing progressive myelopathy and hearing loss.

Undoubtedly, the number of observations of siderosis is rapidly increasing because of the simplicity of recognition offered by MR.

Minor degrees of local siderosis in tumors operated on repeatedly are common, but of slight importance, because they rarely progress to cause symptoms and signs.

It seems to us that the ratio between the number of cases of siderosis caused by bleeding tumors or vascular malformations and the number of the so-called spontaneous ones is changing in favor of the latter. Intraventricular tumors or tumors of the cauda equina that may cause siderosis are diagnosed (and removed) earlier.

The main problem with superficial siderosis of the central nervous system remains the cause of the spontaneous cases.

We think that the association with severe traumas and dural lacerations occurring in a considerable number of cases even decades earlier should not be dismissed; such patients may form a distinctive subgroup for which, perhaps, something can be done. One problem, however, is to convince a neurosurgeon to explore an old dural scar, for which there is no evidence, on imaging studies, of being responsible for the repeated minor subarachnoid hemorrhages.

So far, we have had only one patient (case 7 in our paper) who underwent surgery at age 50 for a posttrau-

matic meningocele and left C8 root avulsion caused by a trauma that occurred at age 20. This patient had repeated lumbar punctures in the past 2 years, which always yielded bloody and xanthochromic CSF. At surgery (Dr Stefano Ferraresi, Department of Neurosurgery, Ospedali Riuniti di Bergamo) a left C7-T1 hemilaminectomy was performed; no significant oozing of blood was observed either from the dural wall of the meningocele or from the arachnoidal scar on the cord. The meningocele was packed with muscle and gel foam and sealed with fibrin glue. A tiny spider angioma was also coagulated on the arachnoidal scar. Three lumbar punctures performed 2, 4, and 6 months after surgery always yielded clear, colorless CSF without any red blood cells.

We think that other operations on posttraumatic scars are necessary before we can establish that they might be responsible for the repeated subarachnoid hemorrhages, but certainly this case is encouraging; operations on old dural scars will not be the cure for the siderosis, but we may be satisfied if we can identify a subgroup of patients in whom we may arrest the progression of the disease.

Mario Savoiardo

Marina Grisoli

Department of Neuroradiology

Istituto Nazionale Neurologico "C. Besta"

Milano, Italy

Fabio Triulzi

Giuseppe Scotti

Ospedale San Raffaele

Milano, Italy

Gianni B. Bradac

Università di Torino

Torino, Italy

Cristina Agostinis

Ospedali Riuniti

Bergamo, Italy

References

1. de Souza NM, Cox TCS, Hoare RD, Clarke CRA. Cerebral siderosis: a complication of anticoagulant therapy? *AJNR: Am J Neuroradiol* 1993;14:774-776

Tissue Plasminogen Activator in Acute Stroke

A recent article by Wolpert and colleagues (1) summarizes some neuroradiologic features of a recently completed study of recombinant tissue plasminogen activator in patients with acute stroke (2). As a member of the study group involved with this protocol, there are several statements in Dr Wolpert's paper that deserve some comment.

In the results section of the abstract, the authors state that, "in general patients displaying recanalization tended to develop small infarcts . . ." This statement is somewhat misleading; in the results section of the paper the authors state that there was no statistically significant correlation between smaller infarcts and recanalization. Even among

the group of patients with middle-cerebral artery occlusion, which showed the highest rate of recanalization, there was no statistically significant correlation between recanalization and smaller infarcts. Because recanalization was a hard end point for the study, those results should be analyzed objectively. By using the phrase, "tended to develop small infarcts," readers may be misled as to the statistical significance of that result.

The last line of the abstract states, "fibrinolytic therapy in the doses utilized in this study is more effective with distal than with proximal carotid artery occlusions." This statement is not supported by the study, simply for the reason that no placebo group was included. It is equally possible that distal thrombi are more likely to lyse spontaneously than are proximal thrombi. Without the presence of a placebo group, no clear statements as to the efficacy of fibrinolytic therapy can be made. In fact, the absence of a dose-response effect could support the hypothesis that recombinant tissue plasminogen activator as used in this study was not effective in lysing clots. In the body of the paper, the authors acknowledge the possibility of spontaneous clot lysis and the need for placebo controls. However, this cautious note is not reflected in the abstract.

With the expansion of computerized literature searches and the ability to review abstracts on line, it is very important that abstracts not make unreasonable or unsupported conclusions. For the reasons stated above, I feel that the abstract in Wolpert's article may mislead some readers to draw conclusions that are not supported by the data.

Mark J. Alberts

Division of Neurology

Duke University Medical Center

Durham, NC 27710

References

1. Wolpert SM, Bruckmann H, Greenlee R, et al. Neuroradiologic evaluation of patients with acute stroke treated with recombinant tissue plasminogen activator. *AJNR: Am J Neuroradiol* 1993;14:3-13
2. del Zoppo GL, Proeck K, Pessin MS, et al. Recombinant tissue plasminogen activator in acute thrombotic and embolic stroke. *Ann Neurol* 1992;32:78-86

Reply

Dr Alberts raises two points:

1) The apparent inconsistency between the statement in the abstract, "in general patients displaying recanalization tended to developed small infarcts," and the statement in the paper, "small infarcts tended to occur in patients with recanalized arteries compared to those without recanalization although this was statistically not significant ($P = .047$ and $2P = .094$)," rests on the manner in which the statistic was performed. Because of the *theoretical* possibility that the mean size of an infarct could be inversely proportional to the occurrence of recanalization (ie, that recanalization could cause a larger stroke than no recanalization) we chose a two-tailed probability statistic, $2P$. Dr Alberts would

agree that it is highly improbable that recanalization would cause large strokes. The $2P$ statistic is extremely conservative, a P value less than .05 could be appropriate, and the statement in the abstract is correct.

2) Dr Alberts also objects to the statement that fibrinolytic therapy in doses used in this study was more effective with distal than with proximal carotid artery occlusions. As mentioned in the paper, we agree that a placebo group is necessary to validate this observation and that this caveat should have appeared in the abstract.

Regarding Dr Alberts's comment about computerized literature searches being given greater importance than they deserve, our belief is that abstracts function as summaries, and interested readers always should examine the primary papers.

Samuel M. Wolpert
Department of Radiology
New England Medical Center Hospitals
Boston, MA 02111

Harmut Bruckmann
Department of Radiology
Institut Für Radiologie
Lubeck, Germany

Ralph Greenlee
Department of Neurology
University of Texas Southwest Medical Center
Dallas, TX 75235

Lawrence Wechsler
Department of Neurology
Pittsburgh Neurology Group
Pittsburgh, PA 15213

Michael S. Pessin
Department of Neurology
New England Medical Center Hospitals
Boston, MA 02111

Gregory J. del Zoppo
Department of Molecular and Experimental Medicine
Research Institute of Scripps Clinic
La Jolla, CA 92037

1972 Einstein Neuroradiology Course

I read with great interest and pleasure the special article, "Historical Vignette: Introduction of Computed Tomography in North America," by Hillier L. Baker, Jr (1). The description of the visit to London of the Mayo group and the dates are detailed and precise.

The article, however, is imprecise in one point. It says "an early opportunity came in the autumn of 1971 at the annual New York City neuroradiology refresher course, conducted in that year by Mannie Schechter, chief neuroradiologist at the Albert Einstein School of Medicine. Bull, a member of the faculty, was accompanied by Hounsfield, who was making his first visit to the United States. On the final day of the course, after all of the scheduled lectures

<p style="text-align: center;">Program of the NEURORADIOLOGY POSTGRADUATE COURSE</p> <p style="text-align: center;"><i>Sponsored by</i> DEPARTMENT OF RADIOLOGY ALBERT EINSTEIN COLLEGE OF MEDICINE Bronx Municipal Hospital Center Hospital of the Albert Einstein College of Medicine Montefiore Hospital & Medical Center New York, New York</p> <p style="text-align: center;">ROBBINS AUDITORIUM May 15 - 19, 1972</p>		<p>NOTE: There has been a change in our printed program for Monday, May 15th, only! It is our pleasure to introduce Mr. Godfrey Hounsfield, from England, who, together with Dr. James Bull, will speak to us on a new and exciting radiologic system designed by EMI.</p> <p>MONDAY, MAY 15</p> <p>9:00 Greetings Milton Elkin, M.D. Ernst Jaffe, M.D., Acting Dean</p> <p>TECHNIQUES AND NEWER MODALITIES AND ANATOMY Chairman—Milton Elkin, M.D.</p> <p>9:15 Methods of Selective Opacification and Anatomy of the Vessels of the Head and Neck. Mannie M. Schechter, M.D.</p> <p>9:45 Visualization of the Ventricular System and Subarachnoid Spaces. Juan M. Taveras, M.D.</p> <p>10:30 Coffee Break</p> <p>10:50 Cerebellar Positive Angle Examination. Colin B. Holman, M.D.</p> <p>11:20 Brain Scanning and RISA Encephalography. Lawrence H. Zingesser, M.D.</p> <p>12:05 Computerized Transverse Axial Tomography. Mr. Godfrey Hounsfield, James Ambrose, M.D., and James W. D. Bull, M.D.</p> <p>12:50 Imaging—Magnification, Subtraction, Angiotomography. Norman E. Leeds, M.D.</p> <p>1:30 Lunch 2:30</p>
--	--	---

had been presented, Bull was allowed to introduce Godfrey Hounsfield, who would make an extra presentation."

In fact, the Neuroradiology Postgraduate Course was held from May 15 to May 19, 1972; a loose page was introduced in the program: "Note: There has been a change in our printed program for Monday, May 15th, only! It is our pleasure to introduce Mr Godfrey Hounsfield, from England, who, together with Dr James Bull, will speak to us on a new and exciting radiologic system designed by EMI."

The presentation by the title "Computerized Transverse Axial Tomography" was scheduled at 12:05, under the names of G. Hounsfield, J. Ambrose, and J. Bull.

To the surprise of everybody, we could for the first time see hydrocephalus, tumors, and hematomas on the 80 × 80 matrix. I was fortunate enough to be a resident in Neuroradiology (1971–1973) at the Montreal Neurological Institute, and as part of my training, I had been sent to the Albert Einstein Course. I remember vividly the impression that I had at that presentation; I also remember that it was difficult for me to understand precisely the technical and physical aspects of that new technique. When I returned to Montreal I tried to explain it to Dr Romeo Ethier, who, despite my confused explanation, immediately understood the importance of the EMI scanner.

Giuseppe Scotti
Servizio di Neuroradiologia
Ospedale, San Raffaele
Milano, Italy

References

1. Baker HL. Historical vignette: introduction of computed tomography in North America. *AJNR: Am J Neuroradiol* 1992;14:283–287

Reply

I am indebted to Professor Scotti for enhancing the precision of my historical vignette concerning the arrival

of computed tomography in North America. He has the advantage over me in two regards: 1) he was present at the historic May 15, 1972, lecture; and 2) he has a copy of the Neuroradiology Postgraduate Course program.

Even now, 20 years later, I continue to be amazed by the simplicity and rapidity with which events evolved in 1972.

Hillier L. Baker, Jr
*Department of Radiology
Mayo Clinic
Rochester, MN 55905*

Editor's note: In looking at the program of the Einstein Neuroradiology Course, I noted that Dr Norman Leeds was the individual scheduled to give the talk that would immediately follow the one by Prof Bull. I asked Dr Leeds to give his recollection of the events of that morning.

Reply

In May 1972, the Einstein Neuroradiology course was to begin. One of my several lectures was for the first day,

Monday, at 11:30 a.m. to 12:00 p.m., on new techniques in neuroradiology. This was to include the angiographic techniques of magnification, subtraction, and angiotomography. Dr Elkin advised me 1 week before the course that Dr James Bull requested 15 minutes to present the preliminary results of the first EMI scans (computed tomography) of the brain obtained at the Atkinson Morley surgical unit at St George's Hospital. I granted his request with great reluctance, wondering how I was to shorten my talk by half and still get across the major teaching points of new techniques to the audience. I did not want them to feel cheated.

Well, as history has shown, a major change in the neuroradiologic investigation of patients began that day. I, as well as others, was privileged that day to witness the beginning of a new era of examination of the brain with the use of computers, to visualize the inside of the brain without interventional techniques. The neuroradiologist's investigation was to be changed forever, and those in attendance that day did not feel cheated.

Norman E. Leeds
*Department of Radiology
M.D. Anderson Hospital
Houston, TX 77030*

ERRATUM

The first article published in the September/October 1993 issue of the *AJNR*, "Measurement of Human Brain Lithium In Vivo by MR Spectroscopy," by R. Gilberto González, Alexander R. Guimaraes, Gary S. Sachs, Jerrold F. Rosenbaum, Michael Garwood, and Perry F. Renshaw, was one of the two Cornelius G. Dyke Award-winning papers of 1992. The editors regret that this honor was not noted on the title page of the article.