



Discover Generics

Cost-Effective CT & MRI Contrast Agents

 FRESENIUS
KABI

[WATCH VIDEO](#)

AJNR

Characterization of arteriovenous malformation feeding vessels by carbon dioxide reactivity.

A R Massaro, W L Young, A Kader, N Ostapkovich, T K Tatemichi, B M Stein and J P Mohr

AJNR Am J Neuroradiol 1994, 15 (1) 55-61

<http://www.ajnr.org/content/15/1/55>

This information is current as
of June 3, 2025.

Characterization of Arteriovenous Malformation Feeding Vessels by Carbon Dioxide Reactivity

A. R. Massaro,^{1,4} W. L. Young,^{2,3,5} A. Kader,³ N. Ostapkovich,² T. K. Tatemichi,¹ B. M. Stein,³ and J. P. Mohr¹

PURPOSE: To characterize cerebral hemodynamics in patients immediately before microsurgical resection of moderate to large arteriovenous malformations during isoflurane anesthesia. **METHODS:** In angiographically defined arteriovenous malformation feeding and nonfeeding arteries, transcranial Doppler studies were performed in 25 surgeries on 22 patients. The mean blood flow velocity and pulsatility index were recorded in the middle, anterior, and posterior cerebral arteries. Transcranial Doppler velocities were measured at end-tidal carbon dioxide tensions (PetCO₂) of about 25 and 35 mm Hg. Carbon dioxide reactivity was calculated as percentage mean blood flow velocity change per mm Hg PetCO₂ change. **RESULTS:** Patient demographic and clinical data for the arteriovenous malformation group followed the expected strata of a large arteriovenous malformation population. All patients were neurologically stable before surgery. A total of 43 feeding arteries and 55 nonfeeding arteries were studied. Compared with nonfeeders, feeders exhibited higher mean blood flow velocity (68 ± 5 vs 31 ± 3 cm/sec, $P < 0.0001$) and lower pulsatility index (0.64 ± 0.03 vs 0.88 ± 0.04 , $P < 0.001$); anterior and middle cerebral artery velocities at normo- and hypocapnia were significantly higher than posterior cerebral arteries for both feeders and nonfeeders ($P < 0.001$). Carbon dioxide reactivity was 0.2 ± 0.2 %/mm Hg in feeders and 2.1 ± 0.2 %/mm Hg in nonfeeders, with no significant difference between arteries. In four of eight patients with lesions fed by the anterior circulation (middle cerebral artery with or without anterior cerebral artery feeders), posterior cerebral artery nonfeeders exhibited low reactivity. In 2 of 5 patients with ipsilateral posterior cerebral artery feeders, contralateral posterior cerebral artery nonfeeders exhibited impaired reactivity. **CONCLUSIONS:** Quantitative transcranial Doppler studies are technically feasible in the operating room or interventional suite during anesthesia. Hemodynamic assessment using physiologic challenges of arteriovenous malformation feeders as well as angiographically uninvolved vessels may be useful as criteria in the assessment of malformations and arteriovenous malformation patients may exhibit abnormal vasoreactivity in distant uninvolved perfusion territories, suggesting a deranged neural control mechanism.

Index terms: Arteriovenous malformations, cerebral; Blood vessels, flow dynamics; Ultrasound, Doppler; Cerebral blood, flow

AJNR Am J Neuroradiol 15:55–61, Jan 1994

Cerebral arteriovenous malformations (AVMs) consist of three main vascular components: the

Received July 13, 1992; accepted pending revision October 24; revision received December 2.

This work was supported in part by National Institutes of Health grant RO1-NS27713.

Departments of ¹Neurology, ²Anesthesiology, and ³Neurological Surgery, College of Physicians and Surgeons, Columbia University, New York, NY 10032.

⁴ Present address for Dr. Massaro: Rua Jacirendi 279, Tatuapé, São Paulo - SP, Brazil 03080.

⁵ Address reprint requests to William L. Young, MD, Atchley Pavilion Room 901, 161 Ft Washington Avenue, New York, NY 10032.

AJNR 15:55–61, Jan 1994 0195-6108/94/1502-0055

© American Society of Neuroradiology

nidus, the feeding arteries supplying the fistula, and the venous drainage. Morphologically, the nidus consists of abnormal arteries and veins that lack muscular resistance vessels and a true capillary bed (1). Feeding arteries may exhibit a lower-than-systemic intravascular pressure with a corresponding hypertension in the draining venous structures (2–4). The combination of arterial *hypotension* and venous *hypertension*, if transmitted to contiguous normal circulatory beds, can result in a decrease in cerebral perfusion pressure (2). The abrupt increase in cerebral perfusion pressure with treatment (either embolization or surgery) may be involved in the pathogenesis of certain complications such as brain swelling or

hemorrhage (2, 5). The ability to identify severe physiologic disturbances in cerebral hemodynamics that might lead to postoperative complications would be beneficial.

Standard angiography can identify feeding arteries and their parent vessels but cannot provide quantitative information about shunt flow or the physiologic effects of the fistula on normal circulatory beds. The hemodynamic effects of shunt flow through AVMs on adjacent and distant normal tissue beds have been studied with xenon-133 clearance (6), single-photon emission computed tomography (7), and positron emission tomography (8). Transcranial Doppler studies have also contributed insights into the hemodynamic consequences of the fistula; feeding arteries are characterized by high velocity and low pulsatility, which revert to normal values after obliteration of the AVM shunt (3, 9–12).

Provocative physiologic challenges have been used to assess autoregulatory function in the brain. Carbon dioxide (CO₂) or its functional analog, acetazolamide, have been applied widely for several cerebral blood flow methodologies in patients with cerebrovascular disease (7, 13, 14). Carbon dioxide (CO₂) reactivity in normal arteries measured with transcranial Doppler is similar to values reported for hemispheric CBF (tissue perfusion) techniques (15, 16). Lindegaard et al (11) studied middle cerebral artery (MCA) CO₂ reactivity in AVM patients and reported a diminished reactivity to changes in carbon dioxide tension.

The purpose of this investigation was to determine the range of CO₂ reactivity in angiographically defined feeding and nonfeeding arteries in the MCA, anterior cerebral artery (ACA), and posterior cerebral artery (PCA) in the intraoperative setting and attempt to classify AVM feeding and nonfeeding vessels from a physiologic perspective.

Methods

All patients underwent elective microsurgical resection of moderate to large AVMs. Preoperative standard four-vessel angiography was used to identify feeding and nonfeeding arteries (feeders and nonfeeders). AVM volume was estimated as described by Pasqualin et al (17).

Intraoperative transcranial Doppler studies were performed during general anesthesia with 0.75% isoflurane and 60% nitrous oxide in oxygen, after induction but before incision. A 2-MHz pulsed Doppler probe (Transpect, Medasonics, Fremont, CA) was placed over the temporal bone to insonate MCAs, ACAs, and PCAs as previously described (10). All vessels were insonated in the proximal

portions in approximately the same location and the depth of maximum signal was recorded. Mean blood-flow velocity (MV) and pulsatility index were registered for each artery. The pulsatility index was calculated as: [systolic velocity – diastolic velocity]/MV.

After induction of anesthesia, mechanical ventilation was managed by titration of end-tidal CO₂ tension (PetCO₂) to moderate hypocapnia (about 25 mm Hg). PetCO₂ was assessed using capnography (RGM 5250, Ohmeda, Madison, WI) as an index of PaCO₂ (18). To assess transcranial Doppler velocities at normocapnia (about 35 mm Hg), CO₂ was added to the fresh gas mixture. The MV and pulsatility index were then measured bilaterally in the ACA, MCA, and PCA (for technical reasons it was not possible to obtain transcranial Doppler velocities in all arteries in all patients). Patients were assigned randomly to begin the sequence of examinations with either hypocapnia or normocapnia.

CO₂ reactivity (%/mm Hg) was calculated as:

$$\frac{100\{MV_{NC} - MV_{HC}\}/MV_{NC}}{\Delta PetCO_2}$$

The slope of the CO₂ response (cm/sec/mm Hg) was calculated as:

$$\frac{MV_{NC} - MV_{HC}}{\Delta PetCO_2}$$

Although the protocol called for maintenance of stable blood pressure between normocapnia and hypocapnia, there were random variations in mean arterial pressure (MAP) between measurements and this change (Δ MAP) was introduced as another covariate for statistical analysis. Data were analyzed by analysis of variance with the MV, pulsatility index, and CO₂ reactivity as dependent variables and feeder classification (feeder vs nonfeeder) and artery (ACA, MCA, PCA) as grouping factors. χ^2 analysis was used for nonparametric data. Linear regression and analysis of covariance was used to determine whether the Δ MAP between measurements influenced the CO₂ reactivity between feeders and nonfeeders. A value of $P < 0.05$ was taken as the threshold of significance. Data are expressed as mean \pm standard error.

Results

There were 25 surgeries on 22 patients; three patients underwent staged resection. Their mean ages were 35 ± 2 years (range, 18 to 54) and included 14 men and eight women with 11 left- and 11 right-sided lesions. Five of the 22 patients underwent preoperative embolization. The mean AVM size (cm) was 4.7 ± 0.4 by 3.9 ± 0.3 by 3.5 ± 0.4 and volume was 38 ± 10 cm³.

The feeding arterial complex was MCA/ACA in eight, MCA/PCA in two, MCA/PCA/ACA in five, MCA-only in one, and PCA-only in six. The predominant location of the AVM was frontal

(eight), parietal (three), temporal (three), occipital (seven) and dural-cerebellar (one). Patients presented with headache (six), hemorrhage (nine) and seizures (five); two were asymptomatic. All patients were neurologically stable at the time of surgery and no patient had clinical or radiologic evidence of vasospasm or increased intracranial pressure.

AVM volume was smaller in patients who presented with hemorrhage than those with other presentations (15 ± 2 vs 60 ± 13 cm³, $P < 0.05$). Otherwise, the above demographic data and anatomic considerations were not related to MV, pulsatility index, or CO₂ reactivity by subsequent statistical analysis. The depth of insonation was 65 ± 1 cm for ACA and PCA and 50 ± 1 cm for MCA. A total of 43 feeding arteries and 55 non-feeding arteries were studied.

All MV and pulsatility index mean values are presented in Figure 1A and 1B. Hypocapnic (22 ± 0.2 mm Hg) and normocapnic (36 ± 0.3 mm Hg) PetCO₂ levels were significantly different, with no effect of artery or feeder versus nonfeeder classification. Compared with nonfeeders, feeders exhibited higher mean MV (68 ± 5 vs 31 ± 3 cm/sec, $P < 0.001$) and lower pulsatility index (0.64 ± 0.03 vs 0.88 ± 0.04 , $P = 0.001$); ACA and MCA velocities at normo- and hypocapnia were significantly higher than PCA for both feeders and nonfeeders ($P < 0.001$). There was no significant difference in pulsatility index between ACA, MCA, and PCA in both feeders and nonfeeders.

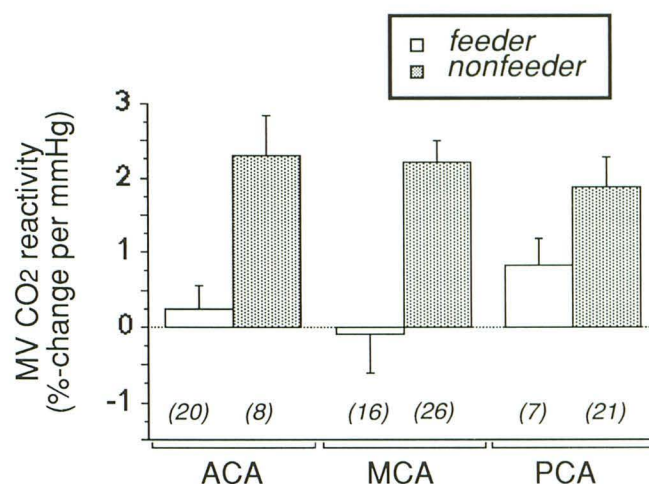


Fig. 2. CO₂ reactivity in feeders versus nonfeeders for ACA, MCA, PCA. See text for explanation. Numbers in parentheses are numbers of vessels examined.

CO₂ reactivity values were significantly different between feeders and nonfeeders and data are shown in Figure 2. CO₂ reactivity was $0.2 \pm 0.2\%$ /mm Hg in feeders and $2.1 \pm 0.2\%$ /mm Hg in nonfeeders. The slope of the CO₂ response was 0.16 ± 0.17 cm/sec/mm Hg in feeders and 0.99 ± 0.11 cm/sec/mm Hg in nonfeeders. Although feeders had a significantly lower CO₂ reactivity than nonfeeders, there were no significant differences between ACA, MCA, and PCA in either feeders or nonfeeders. For feeders, however, MCA CO₂ reactivity tended to be the lowest.

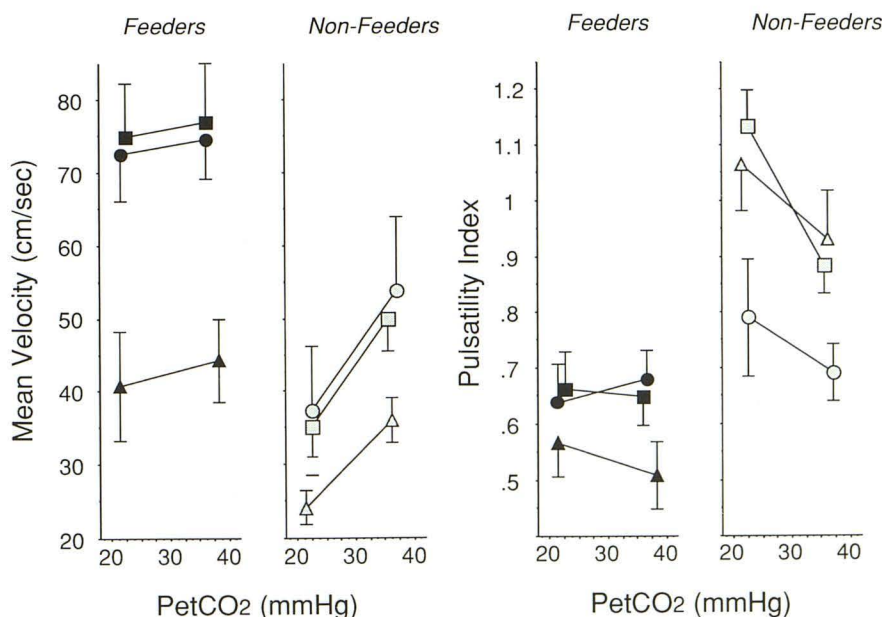


Fig. 1. A, Mean velocity as a function of PetCO₂ in feeders and nonfeeders. See text for explanation. B, Pulsatility index as a function of PetCO₂ in feeders and nonfeeders. See text for explanation. □ Indicates MCA; ○, ACA; and △, PCA.

By analysis of covariance of feeders vs nonfeeders, there was a significant effect of Δ MAP on CO_2 reactivity ($P = 0.0001$). By linear regression, there was a weak but significant correlation between the Δ MAP and the slope of the CO_2 response, as shown in Figure 3. When feeders and nonfeeders were analyzed separately, the effect of Δ MAP on the CO_2 response was significant for feeders only.

Where applicable, a comparison was made between matched sets of ipsilateral feeders and their corresponding contralateral nonfeeders. Four sets of ACAs, 15 MCAs, and five PCAs were examined. Flow velocities, pulsatility index, and CO_2 reactivity were compared by analysis of variance for ACA, MCA, and PCA. Similar to the analysis of all arteries studied, ipsilateral feeders were significantly less reactive than contralateral nonfeeders, with no significant difference between arteries. Although PCA and MCA pulsatility index values were significantly different between feeders and nonfeeders during hypocapnia, as seen in Figure 4, contralateral nonfeeding ACAs had pulsatility index values that were low and not significantly different from ipsilateral feeders. This was surprising because there was a marked difference in CO_2 reactivity between ACA ipsilateral feeders and contralateral nonfeeders.

In two patients with large frontal AVMs (in whom blood pressure did not change between hypo- and normocapnic measurements), feeding arteries demonstrated a strongly *negative* reactivity to CO_2 (-3% to -4% /mm Hg); that is, lowering PetCO_2 increased flow through the fistula. There were also several nonfeeders with appar-

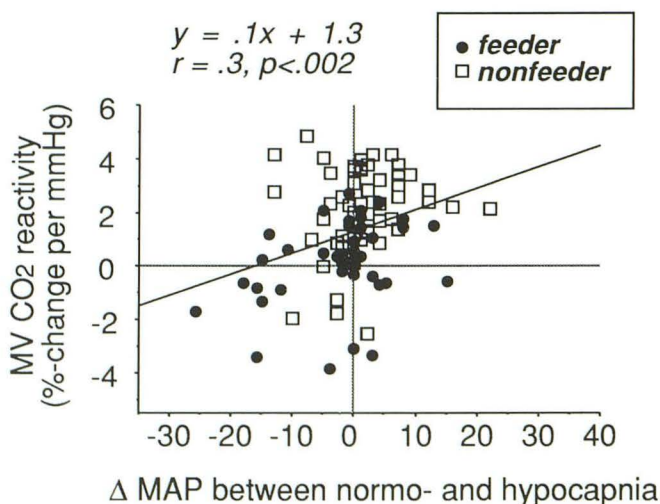


Fig. 3. Scattergram of the slope of the CO_2 response versus Δ MAP between normo- and hypocapnic measurements.

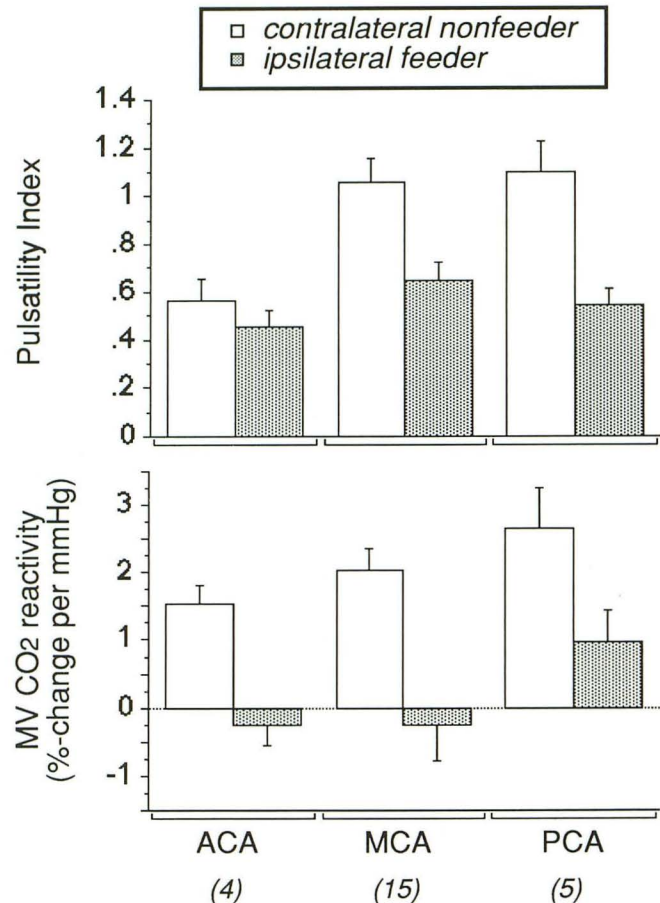


Fig. 4. Pulsatility index and CO_2 reactivity in paired groups (ipsilateral feeders and contralateral nonfeeders) by artery. Data for pulsatility index are taken from the hypocapnic measurements. There is a significant effect by analysis of variance for both artery and location (ipsilateral vs contralateral). Means were similar for normocapnic measurement but the effect of artery was not significant. For CO_2 reactivity, there was a significant effect of location, but not of artery.

ently impaired ($< 1\%$ -change/mm Hg) CO_2 reactivity. In four of eight patients with lesions fed by the anterior circulation (MCA with or without ACA feeders), PCA nonfeeders exhibited low reactivity. In two of five patients with ipsilateral PCA feeders, contralateral nonfeeders exhibited low (about 1% change/mm Hg) reactivity. This is illustrated in Figure 5. The PCA nonfeeders with low reactivity were anatomically distant from the AVM in all cases.

Discussion

Cerebral AVMs are characterized by feeding vessels with significantly higher MV and lower pulsatility index than angiographically defined nonfeeding vessels and the results presented here agree with previous observations made in the

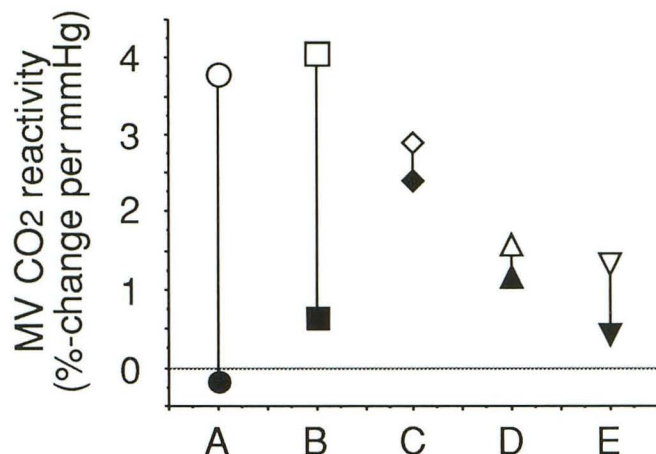


Fig. 5. CO₂ reactivity in ipsilateral (closed symbols) and contralateral (open symbols) PCA in five patients with lesions fed by the ipsilateral PCA, with no angiographic involvement of the contralateral PCA. Two patients exhibited normal contralateral and decreased ipsilateral CO₂ reactivity (A and B), one patient had intermediate reactivity in both vessels (C), and two patients had decreases in both PCAs.

awake state (9–11, 19). The PCA tended to have the lowest MV, but the pulsatility index was similar to the MCA and ACA. This was true for both feeders and nonfeeders, reflecting the relative differences in flow velocities seen in healthy subjects (20). The MV values for nonfeeders were about 20% lower than reports in healthy awake subjects (20), similar to other observations in the isoflurane-anesthetized state (21, 22). Our CO₂ reactivity values agree with previous studies for MCA feeding vessels and their contralateral nonfeeding MCAs (11). This report extends these previous observations to the ACA and PCA, where there were no differences in CO₂ reactivity among the ACA, PCA, and MCA feeders, although there was a tendency for MCA feeders to be the most severely affected. In at least two of our patients, a marked redistribution of flow through the fistula was observed during hypocapnia, similar to previous reports (19). This redistribution is probably explained by vasoconstriction of normal resistive beds and a net increase in the fraction of the intracranial-bound cardiac output that passes through the fistula (12). However, it is not clear what factors will determine when the observed CO₂ reactivity will remain near zero and when it will become negative.

Our data support the previous observation (11) that systemic arterial pressure can modulate vascular reactivity to CO₂ in feeders. Flow through the fistula is directly pressure-passive because the AVM nidus lacks muscular resistance arteri-

oles. Assuming that autoregulatory vasomotion does not effect the proximal conductance vessels being insonated with transcranial Doppler, one would expect that a normal artery flow velocity would remain constant in the normal autoregulatory range with a change in systemic pressure. Hypothetically, however, a nonfeeding artery may be subjected to lower than normal pressure transmitted across Willisian pathways. Such relative hypotension, even if it did not result in frank ischemia, could result in a state of maximal or near-maximal vasodilation (impairing CO₂ reactivity) and would render that territory pressure-passive as well. This remains to be demonstrated in future studies combining other imaging modalities or, ideally, direct intracerebral pressure measurements (23, 24). The influence of systemic arterial pressure on CO₂ reactivity suggests two important considerations for future investigations: 1) Blood pressure changes between transcranial Doppler measurements of CO₂ reactivity should be strictly controlled for accurate quantitative interpretation and 2) this modulating influence may be employed as another means to assess hemodynamic function.

An area that deserves further study is the hemodynamic effect of the AVM across Willisian collateral pathways, such as the anterior communicating artery. Because of the physical proximity of the two proximal ACAs, one might expect any decreased pressure in a feeding ACA to be transmitted easily to its contralateral nonfeeding counterpart. We observed a significant lowering of pulsatility index in nonfeeding contralateral ACA segments, which might suggest such a phenomenon. However, the CO₂ reactivity did not seem to be affected. Intuitively, one would expect vessels with a low pulsatility index to have similarly decreased CO₂ reactivity. This observation awaits corroboration with a larger sample and, ideally, correlation with intravascular pressure measurements to determine which parameter (pulsatility index or CO₂ reactivity) is more closely related to intravascular pressure reductions.

The four cases of diminished CO₂ reactivity in the PCA with lesions fed by the ACA or MCA and the two patients with ipsilateral PCA feeders and decreased reactivity in a contralateral PCA suggest a distant effect of the AVM fistula. There has been suggestion of distant derangements in cerebral perfusion patterns using other CBF methods (6, 7, 8, 25) and complications are not limited to the ipsilateral hemisphere (26). What

remains unclear at present is whether these distant effects are caused by a hemodynamic mechanism (lowered cerebral arterial pressures or a phenomenon functionally analogous to diaschisis seen in the setting of cerebral ischemia) (27). Evidence is accumulating that AVM patients exhibit unusual cerebral blood flow responses to pharmacologic challenges (28, 29). It is tempting to speculate that there may be a derangement in neural modulation or regulation of cerebral blood flow in certain AVM patients; for example, both PCAs may be severely affected by some control defect, even though the contralateral nonfeeding PCA is not involved in feeding the fistula. In fact, this lack of appropriate neurovascular control may very well have importance in the pathogenesis of cerebral AVMs; that is, a localized abnormal vasomotor response to appropriate metabolic or hemodynamic stimuli may lead to gradual enlargement of what might initially be a trivial injury or abnormal area in such a vulnerable zone.

In summary, quantitative transcranial Doppler studies are technically feasible in the operating room or interventional suite during anesthesia; the values reported here agree with previous observations in the awake state. The behavior of the proximal Willisian vessels appears to be similar, but MCA and ACA feeding artery velocities tend to be higher and CO₂ reactivity lower than PCA feeding vessels. AVM patients may exhibit abnormal vasoreactivity in distant uninvolved perfusion territories, suggestive of a deranged neural control mechanism. Hemodynamic assessment using blood pressure or CO₂ challenges of AVM feeders as well as angiographically uninvolved vessels may be developed to be used as physiologic criteria in the assessment of AVMs. It may be possible to characterize a range of abnormal responses that suggest high risk for development of certain complications after treatment (brain swelling or hemorrhage) and are of assistance in making posttreatment management decisions, such as which patients may benefit from aggressive blood pressure control after embolization or surgery to avoid circulatory breakthrough complications.

Acknowledgments

We thank LaSandra Jackson and Elfie Tineo for expert technical assistance; Joyce Ouchi for assistance in preparation of the manuscript; Isak Prohovnik, PhD, for assistance with statistical analysis; Ralph Sacco, MD, for assistance in transcranial Doppler analysis; and Medasonics for use of the TCD equipment.

References

1. Kaplan HA, Aronson SM, Browder EJ. Vascular malformation of the brain: an anatomical study. *J Neurosurg* 1961;18:630-635
2. Nornes H, Grip A. Hemodynamic aspects of cerebral arteriovenous malformations. *J Neurosurg* 1980;53:456-464
3. Hassler W, Steinmetz H. Cerebral hemodynamics in angioma patients: an intraoperative study. *J Neurosurg* 1987;67:822-831
4. Barnett GH, Little JR, Ebrahim ZY, Jones SC, Friel HT. Cerebral circulation during arteriovenous malformation operation. *Neurosurgery* 1987;20:836-842
5. Spetzler RF, Wilson CB, Weinstein P, Mehdorn M, Townsend J, Telles D. Normal perfusion pressure breakthrough theory (Chapter 46). *Clin Neurosurg* 1978;25:651-672
6. Young WL, Prohovnik I, Ornstein E, et al. The effect of arteriovenous malformation resection on cerebrovascular reactivity to carbon dioxide. *Neurosurgery* 1990;27:257-267
7. Batjer HH, Devous MD Sr, Meyer YJ, Purdy PD, Samson DS. Cerebrovascular hemodynamics in arteriovenous malformation complicated by normal perfusion pressure breakthrough. *Neurosurgery* 1988;22:503-509
8. Tyler JL, Leblanc R, Meyer E, et al. Hemodynamic and metabolic effects of cerebral arteriovenous malformations studied by positron emission tomography. *Stroke* 1989;20:890-898
9. Schwartz A, Hennerici M. Noninvasive transcranial Doppler ultrasound in intracranial angiomas. *Neurology* 1986;36:626-635
10. Petty GW, Massaro AR, Tatemichi TK, et al. Transcranial Doppler ultrasonographic changes after treatment for arteriovenous malformations. *Stroke* 1990;21:260-266
11. Lindegaard K-F, Grolimund P, Aaslid R, Nornes H. Evaluation of cerebral AVMs using transcranial Doppler ultrasound. *J Neurosurg* 1986;65:335-344
12. Batjer HH, Purdy PD, Giller CA, Samson DS. Evidence of redistribution of cerebral blood flow during treatment for an intracranial arteriovenous malformation. *Neurosurgery* 1989;25:599-605
13. Bishop CCR, Burnand KG, Brown M, Ross-Russell R, Browse NL. Reduced response of cerebral blood flow to hypercapnia: restoration by extracranial-intracranial bypass. *Br J Surg* 1987;74:802-804
14. Bullock R, Mendelow AD, Bone I, Patterson J, Macleod WN, Allardice G. Cerebral blood flow and CO₂ responsiveness as an indicator of collateral reserve capacity in patients with carotid arterial disease. *Br J Surg* 1985;72:348-351
15. Markwalder T-M, Grolimund P, Seiler RW, Roth F, Aaslid R. Dependency of blood flow velocity in the middle cerebral artery on end-tidal carbon dioxide partial pressure—A transcranial ultrasound Doppler study. *J Cereb Blood Flow Metab* 1984;4:368-372
16. Schroeder T, Schierbeck J, Howardy P, Knudsen L, Skafte-Holm P, Gefke K. Effect of labetalol on cerebral blood flow and middle cerebral arterial flow velocity in healthy volunteers. *Neurol Res* 1991;13:10-12
17. Pasqualin A, Barone G, Cioffi F, Rosta L, Scienza R, Pian RD. The relevance of anatomic and hemodynamic factors to a classification of cerebral arteriovenous malformations. *Neurosurgery* 1991;28:370-379
18. Young WL, Prohovnik I, Ornstein E, Ostapkovich N, Matteo RS. Cerebral blood flow reactivity to changes in carbon dioxide calculated using end-tidal versus arterial tensions. *J Cereb Blood Flow Metab* 1991;11:1031-1035
19. Hassler W. Hemodynamic aspects of cerebral angiomas. *Acta Neurochir (Wien)* 1986;[Suppl 37] 1-136

20. Aaslid R. *Transcranial Doppler sonography*. New York: Springer-Verlag, 1986:177
21. Halsey JH, McDowell HA, Gelmon S, Morawetz RB. Blood velocity in the middle cerebral artery and regional cerebral blood flow during carotid endarterectomy. *Stroke* 1989;20:53-58
22. Lundar T, Lindegaard K-F, Refsum L, Rian R, Nornes H. Cerebrovascular effects of isoflurane in man: intracranial pressure and middle cerebral artery flow velocity. *Br J Anaesth* 1987;59:1208-1213
23. Duckwiler G, Dion J, Vinuela F, Jabour B, Martin N, Bentson J. Intravascular microcatheter pressure monitoring: experimental results and early clinical evaluation. *AJNR Am J Neuroradiol* 1990;11:169-175
24. Fleischer LH, Young WL, Pile-Spellman J, et al. The relationship of transcranial Doppler Flow velocities and arteriovenous malformation feeding artery pressures. *Stroke* (in press)
25. Homan RW, Devous MD Sr, Stokely EM, Bonte FJ. Quantification of intracerebral steal in patients with arteriovenous malformation. *Arch Neurol* 1986;43:779-785
26. Solomon RA, Michelsen WJ. Defective cerebrovascular autoregulation in regions proximal to arteriovenous malformations of the brain: A case report and topic review. *Neurosurgery* 1984;14:78-82
27. Meyer JS. Does diaschisis have clinical correlates? (Editorial). *Mayo Clin Proc* 1991;66:430-432
28. Batjer HH, Devous MD Sr. The use of acetazolamide-enhanced regional cerebral blood flow measurement to predict risk to arteriovenous malformation patients. *Neurosurgery* 1992;31:213-218
29. Young WL, Kader A, Prohovnik I, et al. Pressure autoregulation is intact after arteriovenous malformation resection. *Neurosurgery* 1993;32:491-497