



Discover Generics

Cost-Effective CT & MRI Contrast Agents



FRESENIUS
KABI

WATCH VIDEO

AJNR

The effect of intracarotid nonionic contrast media on the blood-brain barrier in acute hypertension.

C C Whisson, A J Wilson, C A Evill and M R Sage

AJNR Am J Neuroradiol 1994, 15 (1) 95-100

<http://www.ajnr.org/content/15/1/95>

This information is current as
of June 3, 2025.

The Effect of Intracarotid Nonionic Contrast Media on the Blood-Brain Barrier in Acute Hypertension

Christopher C. Whisson, Alan J. Wilson, Charles A. Evill, and Michael R. Sage

PURPOSE: To determine whether acute hypertension (HT) is a risk factor for damage to the blood-brain barrier in carotid angiography with nonionic contrast media. **METHODS:** Anesthetized rats received intravenous injections of technetium-99m-pertechnetate and horseradish peroxidase. Two groups of rats received metaraminol to raise their blood pressure to between 165 and 190 mmHg peak systolic and then received intracarotid injections of saline or iopamidol. Two other groups remained normotensive and received intracarotid injections of saline or iopamidol. Animals were perfused with a fixative solution and their brains removed. Activity of extravasated Tc-99m-pertechnetate was determined to assess blood-brain barrier breakdown. Brains were then sectioned, treated histochemically to visualize extravasated horseradish peroxidase, and ranked visually according to horseradish peroxidase staining. **RESULTS:** Extravasation of both tracers was significantly greater in the hypertensive group that received contrast media than in the other three groups. **CONCLUSIONS:** Acute hypertension potentiates the blood-brain barrier-damaging effects of nonionic contrast media during carotid angiography in rats.

Index terms: Hypertension; Blood-brain barrier; Angiography, contrast media; Angiography; Brain, effects of drugs on; Animal studies; Arteries, carotid

AJNR Am J Neuroradiol 15:95–100, Jan 1994

An increase in the arterial blood pressure of greater than approximately 60 mmHg has been shown to cause a multifocal breakdown of the blood-brain barrier (BBB) in a wide variety of experimental animals (1). Similarly, the intracarotid injection of hyperosmotic solutions, such as occurs in carotid angiography with both ionic and nonionic contrast media (CM), has been shown to cause a multifocal BBB breakdown in both clinical and experimental situations (2–7). In the rat, the threshold for such hyperosmotic BBB breakdown has been reported to be approximately 1400 mosm/kg (8).

It has been reported that when rats are made acutely hypertensive, but at a level below that

known to cause BBB damage, and then receive intracarotid injections of an ionic CM at an osmolality below the hyperosmotic threshold, they display a level of BBB damage that does not occur with either acute hypertension or intracarotid CM alone (9). Acute hypertension therefore seems to be a risk factor in carotid angiography by potentiating the BBB-damaging effects of ionic CM.

The new low-osmolality nonionic CM are generally regarded as being safer than the ionic CM, although there is evidence, both clinical and experimental, to suggest that they are still capable of exerting undesirable effects on the BBB, albeit at a lower level than the ionic CM (3, 4, 6, 7, 10). Accordingly, it is important to determine whether acute hypertension also increases the risk of BBB damage in carotid angiography with nonionic CM.

In this study, a rat model was used to investigate the relationship between acute hypertension, at a level below that associated with BBB damage, and carotid angiography with iopamidol, a nonionic CM with an osmolality well below the reported threshold for hyperosmotic BBB damage. Two intravascular tracers were employed to demonstrate BBB damage, which was manifested by

Received August 7, 1992; accepted pending revision September 28; revision received December 18.

Supported by a grant from the Royal Australasian College of Radiologists. Presented in whole at the 30th Annual Meeting of the American Society of Neuroradiology, St. Louis, Mo, May 31–June 5, 1992.

All Authors: Department of Radiology, Flinders Medical Centre, Bedford Park, South Australia 5042, Australia. Address reprint requests to Alan J. Wilson, PhD.

AJNR 15:95–100, Jan 1994 0195-6108/94/1501-0095
© American Society of Neuroradiology

their extravasation into the cerebral parenchyma. One tracer, technetium-99m-pertechnetate, permitted BBB damage to be quantified directly; the other tracer, horseradish peroxidase (HRP), permitted BBB damage to be visualized histochemically and assessed semiquantitatively.

Methods

Twenty-two young adult Sprague-Dawley rats (Flinders Medical Centre, Adelaide, Australia, 160–390 g, mean 292 ± 60 g) of either sex were anesthetized with urethane (1.25 g/kg intraperitoneally). A femoral vein was catheterized for intravenous administration of drugs. A midline incision was made in the neck and a tracheostomy tube inserted; animals were allowed to breathe room air spontaneously. The left external carotid artery was surgically exposed, ligated distally, and catheterized retrogradely, proximal to the ligature, with an SP31 polyethylene catheter (0.8-mm external diameter, 0.5-mm internal diameter). The catheter tip was located just distal to the carotid bifurcation. This ensured that test solutions passed into the internal carotid artery and that the cerebral circulation was not compromised. Blood pressure was monitored continuously via a pressure transducer (Statham, Oxnard, Calif) connected to the carotid catheter by a three-way tap and was recorded on a polygraph (Grass, Quincy, Mass). Blood pressure monitoring was temporarily unavailable during the 30 seconds in which test solutions were injected through the catheter.

Rats were placed into one of four treatment groups. In the first group (NT/S, $n = 4$), rats remained normotensive and received intracarotid injections of physiologic saline. In the second group (NT/CM, $n = 6$) the rats also remained normotensive but received intracarotid injections of a non-ionic contrast medium, iopamidol (300 mg iodine/ml; Schering, Berlin, Germany). In the third group (HT/S, $n = 5$), rats were made acutely hypertensive and received intracarotid injections of saline. In the fourth group (HT/CM, $n = 7$), rats were made acutely hypertensive and received intracarotid injections of iopamidol.

All rats received intravenous injections of pyrilamine maleate (5 mg/kg; Sigma, St. Louis, Mo) to counter possible hypotensive reactions to subsequent injections of HRP (11). Five minutes later, all rats received intravenous injections of Tc-99m-pertechnetate (3.7 MBq) and 50 mg HRP (type II; Sigma) combined in 0.5 mL saline. Immediately after injection of the tracers, rats that were to be made hypertensive received continuous intravenous infusion of 0.1% metaraminol bitartrate (Aramine, Merck, Sharp & Dohme, Granville, Australia). The metaraminol was infused with a pump (Sage Instruments, Cambridge, Mass) fitted with an infinitely variable infusion rate control, at a rate sufficient to raise the peak systolic blood pressure into the range of 165 to 190 mmHg slowly over a period of several minutes. This pressure is just below the level at which hypertensive BBB damage has been reported in the rat (12). Rats that were to remain normotensive received equivalent infusions of saline.

After blood pressures had stabilized at 165 to 190 mmHg peak systolic in the hypertensive groups, or at an equivalent time (13 ± 4 minutes after commencement of metaraminol infusion (mean \pm SD)) in the normotensive groups, iopamidol or saline was injected into the carotid catheter at a constant rate of 3.75 mL/min for 30 seconds with an infusion pump (Braun, Melsungen, Germany). The iopamidol had an osmolality of 620 mosm/kg, which is well below the reported threshold for hyperosmotic BBB damage of 1400 mosm/kg (8). During the injection, the left common carotid artery was clamped to ensure that all the injectate passed into the internal carotid artery. At the end of the injection, the clamp was removed to reestablish normal cerebral blood flow.

In all animals, the thorax was opened 5 minutes after the carotid injection and approximately 0.5 mL of blood was taken from the left ventricle. Animals were then perfused, via a cannula in the ascending aorta, with 500 mL of 2% glutaraldehyde plus 2.5% formaldehyde in 0.1 M phosphate buffer plus 0.1 M sucrose, pH 7.3, at a perfusion pressure of 120 mmHg.

The fixed brain was removed, rinsed in fresh fixative to remove superficial blood and cerebrospinal fluid, and bisected midsagittally. The hemispheres were blotted dry briefly, and then they and the blood sample were weighed. The Tc-99m activity of the blood sample and of each hemisphere were counted in a gamma-counter (Searle, Des Plaines, Ill) with a well attachment. After a correction for background, the ratio of brain activity (counts per min/g) to blood activity (counts per min/g) was calculated for each hemisphere. The ratio for the right (uninjected) hemisphere was subtracted from the ratio for the left (injected) hemisphere to yield a figure, described as pertechnetate uptake, that is an estimate of the degree of BBB damage in the injected hemisphere.

Differences in pertechnetate uptake between the four treatment groups were analyzed statistically using Student *t* test after a logarithmic transformation of the data (13).

After the hemispheres had been weighed and counted, 50- μ m coronal sections were cut from them at regular intervals using a Vibratome (TPI, St. Louis, Mo). Extravasated HRP was visualized by incubating the sections for 10 minutes in diaminobenzidine (0.5 mg/mL; Sigma) plus 10 mM imidazole (Merck, Darmstadt, Germany) in Tris-buffered saline, pH 7.6, containing 0.01% hydrogen peroxide. The sections were washed, dehydrated in alcohol, and mounted on glass microscope slides. Two blinded observers independently ranked the slides with regard to the degree of macroscopically visible HRP staining in the left hemisphere. The rankings were summed and analyzed statistically by the Kruskal-Wallis test.

Results

Immediately after surgery, but before the administration of any drugs, the mean peak systolic blood pressure in all rats was 128 ± 25 mmHg (mean \pm SD). The peak systolic blood pressures

TABLE 1: Blood pressures and left hemisphere BBB breakdown

Group	Blood Pressure (mmHg) (mean \pm SD)		Pertechnetate Uptake ($\times 10^3$) (mean \pm SD)
	Before Carotid Injection	After Carotid Injection	
NT/S	128 \pm 10	144 \pm 6	1.02 \pm 0.81
NT/CM	125 \pm 11	133 \pm 11	2.76 \pm 3.38
HT/S	169 \pm 7	181 \pm 8	1.08 \pm 0.81
HT/CM	169 \pm 7	174 \pm 11	9.39 \pm 8.33 ^a

Note.—NT/S = normotensive, intracarotid saline; NT/CM = normotensive, intracarotid iopamidol; HT/S = hypertensive, intracarotid saline; HT/CM = hypertensive, intracarotid iopamidol.

^a $P < .02$, versus NT/S, NT/CM, and HT/S.

in the hypertensive rats, immediately before the carotid injections, were 169 ± 7 mmHg for the HT/S group and 169 ± 7 mmHg for the HT/CM group. In the normotensive rats, peak systolic blood pressures immediately before the carotid injections were 128 ± 10 mmHg for the NT/S group and 125 ± 11 mmHg for the NT/CM group. Immediately after the carotid injections, peak systolic blood pressures were 181 ± 8 mmHg for the HT/S group, 174 ± 11 mmHg for the HT/CM group, 144 ± 6 mmHg for the NT/S group, and 133 ± 11 mmHg for the NT/CM group (Table 1).

The pertechnetate uptakes for the four treatment groups are shown in Table 1. The HT/CM group showed significantly greater BBB disruption, as measured by pertechnetate extravasation, than did the NT/S, NT/CM and HT/S groups ($P < .02$). These three groups did not differ significantly from each other ($P > .05$).

HRP extravasation was visible both macroscopically and microscopically as a brown staining of the brain parenchyma. The method is sufficiently sensitive to detect even very subtle leakage of a single vessel microscopically. When the slides holding the left hemispheres were examined macroscopically and ranked on the basis of HRP extravasation by two independent, blinded observers, statistical analysis of the summed ranks showed that the HT/CM group displayed significantly greater HRP extravasation than the other three groups ($P < .02$).

On microscopic analysis, the left hemispheres of HT/CM rats showed large, diffuse, overlapping fields of HRP, located primarily in the cortex, together with small, focal deposits located in the walls of individual blood vessels, both in the cortex and in the deeper regions of the brain (Fig. 1). The right hemispheres of HT/CM rats, which were exposed to hypertension but not to iopam-

idol, showed very minor HRP staining, restricted mostly to the walls of a small number of individual blood vessels (Fig 2), but with occasional small, pale, diffuse fields of HRP. In comparison with the HT/CM rats, the left hemispheres of NT/CM

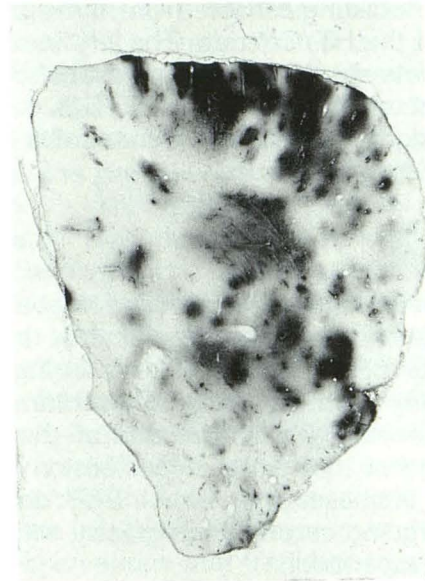


Fig. 1. Section from the left (injected) hemisphere of a rat exposed to acute hypertension and intracarotid iopamidol (HT/CM). Histochemical treatment produces dense staining at sites of HRP extravasation, indicating areas of BBB breakdown.

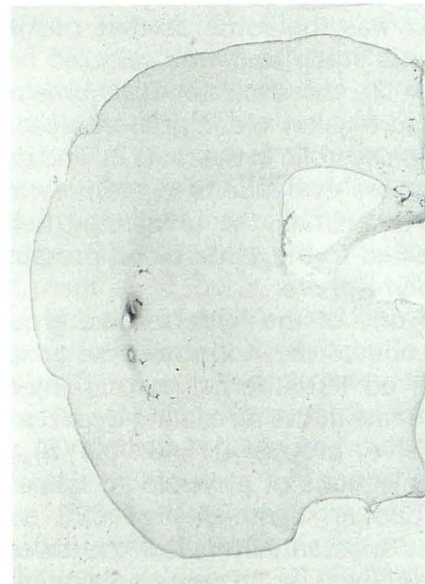


Fig. 2. Section from the right (uninjected) hemisphere of the same rat as in Fig 1, treated in the same manner to demonstrate HRP extravasation. There is substantially less staining in this hemisphere, exposed to hypertension alone, than in the left hemisphere, exposed to both hypertension and intracarotid iopamidol.

and HT/S rats showed substantially less extravasated HRP than the left hemispheres but rather more than the right hemispheres. The HRP was mostly located in the walls of some blood vessels and only occasionally as small diffuse patches. The right hemispheres of the NT/CM and HT/S rats were indistinguishable from the right hemispheres of the HT/CM rats. The left hemispheres of NT/S rats showed less extravasated HRP than the left hemispheres of the NT/CM and HT/S rats; the right hemispheres were similar to those of the other three groups.

Discussion

In a previous study, Harnish and Hagberg found that acute hypertension significantly increased the risk of BBB damage in rats during carotid angiography with an ionic CM, sodium/meglumine diatrizoate (9). The results of the present study suggest that acute hypertension also significantly increases the risk of BBB damage in rats undergoing carotid angiography with a non-ionic CM, iopamidol.

In the present study, two groups of rats (NT/S and NT/CM) remained normotensive, whereas two groups (HT/S and HT/CM) were made acutely hypertensive by raising their peak systolic blood pressures to between 165 and 190 mmHg with intravenous metaraminol. This level of hypertension was the same as that maintained in the previous study and was selected because it was below the threshold for BBB breakdown by acute hypertension alone, reported to be 200 mmHg peak systolic in the rat (12), and confirmed by initial gross evaluations in the previous study (9). In each animal, the uninjected hemisphere was subjected to the same blood pressure as the injected hemisphere.

Rats in one of the hypertensive groups (HT/CM) and one of the normotensive groups (NT/CM) received left internal carotid injections of iopamidol; rats in the remaining hypertensive and normotensive groups (HT/S, NT/S) received identical injections of physiologic saline. The iopamidol had an osmolality of 620 mosm/kg, which was substantially below the threshold for BBB breakdown by hyperosmolality alone, reported to be 1400 mosm/kg in the rat (8). This threshold was subsequently reported to be approximately 1300 mosm/kg for intracarotid injections of sodium/meglumine diatrizoate, on the basis of gross evaluations of BBB breakdown (9). The iopamidol and saline were injected at 3.75

mL/min for 30 seconds, a rate slightly lower than that used by Harnish and Hagberg (9), who injected diatrizoate at 4 mL/min for 30 seconds. A relatively high intracarotid infusion rate such as this has been shown to be necessary in the rat in order to ensure a uniform distribution of infusate throughout the cerebral vasculature (14). Lower infusion rates have been shown to cause intravascular streaming, leading to high local concentrations of infusate, which could, in the case of CM, cause misleading focal BBB damage (14).

BBB breakdown was assessed by the extravasation of two vascular tracers, Tc-99m-pertechnetate and HRP, neither of which are capable of crossing the intact BBB. Pertechnetate was used to provide a quantitative assessment of BBB breakdown by measuring the amount of Tc-99m activity remaining in each hemisphere after intravascular tracer had been flushed out by perfusion of fixative. Subtraction of the activity remaining in the uninjected hemisphere from that remaining in the injected hemisphere gave an estimate of the degree of BBB breakdown occurring in the injected hemisphere. One of the potential drawbacks of this technique is that if BBB breakdown occurred in a small number of highly localized areas, the small increase in Tc-99m activity, averaged out over the entire hemisphere, might not be detectable. Since the presence of extravasated HRP within brain sections, indicating BBB breakdown, can be demonstrated by a histochemical reaction producing a brown reaction product, use of HRP as a vascular tracer in this study provided a visual analog to the results obtained with Tc-99m-pertechnetate. If the BBB breakdown is severe enough, the brown staining can be observed in brain sections with the naked eye as it was in this study, where the brain sections could easily be ranked according to the degree of staining, allowing semiquantitative statistical analysis to be performed. The HRP technique has an advantage over the Tc-99m-pertechnetate technique in that it is very sensitive, so even very subtle perivascular extravasation, in only a small number of vessels in an entire brain, can be observed microscopically.

Both methods of analysis used in this study demonstrated that BBB breakdown in rats that were exposed to acute hypertension and intracarotid iopamidol was significantly greater than in rats exposed to hypertension alone or intracarotid iopamidol alone. Microscopic analysis of the brain sections yielded some further interesting observations. The right, uninjected hemispheres

from all four groups appeared identical, with little if any HRP extravasation evident. A small amount of HRP extravasation has been reported to occur in the normal brain (15). Since the right hemispheres from the HT/S group were exposed to the same level of hypertension as the left injected hemispheres, the virtual absence of staining in the right hemispheres suggests that hypertension at this level was not having any effect on the BBB. In the left hemispheres of the HT/S group however, there was rather more evidence of HRP extravasation than in the right hemispheres, suggesting a role for the saline injection in the increased level of extravasation. It is unlikely that the injection by itself had any effect, however, because in the control NT/S animals, the injected hemispheres showed far less extravasation than the injected hemispheres of the HT/S animals. This suggests that hypertension was potentiating the effects of the saline injection on the BBB in the HT/S animals, possibly by summing to cause a local increase in hypertension, to a level exceeding the threshold, as was also suggested by Rapoport (12). Harnish and Hagberg (9) used similar treatment groups (NT/CM, HT/S, and HT/CM) and used the same range of hypertension, 165 to 190 mmHg peak systolic. However, they observed, using histofluorescent examination of Evans blue extravasation, that in their hypertensive groups, the uninjected hemispheres showed greater extravasation than in the normotensive group, suggesting that the level of hypertension was having an effect on the BBB. The difference between that finding and the present one may be due to the slightly lower levels of hypertension used in the present study: 169 ± 7 mmHg (HT/S) and 169 ± 7 mmHg (HT/CM) versus 182 ± 2 mmHg (HT/S) and 178 ± 3 mmHg (HT/CM). A further difference may be that in the previous study, hypertension was achieved with a bolus intravenous injection of metaraminol, causing a sudden increase, whereas this study employed an intravenous infusion with a slow increase in blood pressure up to the required level.

In the NT/CM rats, the injected hemispheres displayed a reasonable amount of HRP extravasation, more than in the injected hemispheres of NT/S rats but substantially less than in the injected hemispheres of the HT/CM rats, despite the fact that the osmolality of the injected iopamidol was well below the reported hyperosmotic threshold. This suggests that injection of iopamidol was having a low-level disruptive effect on the BBB and supports the contention of Harnish

and Hagberg (9) that the concept of thresholds for BBB damage ought to be reevaluated, and that threshold levels, if they exist, may be dependent on factors such as the sensitivity of the measuring technique and the size of the tracer molecule. This visual observation is in accordance with a recent study using Tc-99m-pertechnetate as a tracer, which demonstrated that carotid angiography with the nonionic CM iohexol, ioversol, iodixanol, and iotrolan caused low-level BBB damage that was not attributable to hyperosmolality but was probably attributable to CM chemotoxicity (6). This disruptive effect of iopamidol is probably also due to chemotoxicity. Other substantial evidence, mostly experimental, but also clinical, indicates that nonionic CM, although safer than ionic CM, are far from inert with regard to their effects on the BBB (3, 4, 7, 10).

These findings suggest that all patients at risk of an acute hypertensive episode should be carefully monitored before and after cerebral angiography with both ionic and nonionic CM. The importance of these findings is underlined by recent observations that transient opening of the BBB in rats, by either acute hypertension or hyperosmolality, can lead to neuronal cell death in affected areas (16–19). Note, however, that the normal clinical dose of CM in common carotid angiography is approximately 10 to 12 mL injected over a period of approximately 1.5 to 2 seconds into a patient with an average body weight of 70 kg. In these experiments, rats with an average body weight of 300 g received an intracarotid dose of 1.875 mL of CM injected over 30 seconds. The rats therefore received substantially higher volumes of CM per kilogram of body weight than are administered in the normal clinical situation. The injection rate was not greatly different, relative to body weight, to that used clinically, but the injection duration, at 30 seconds, was much longer. It remains to be determined whether more clinically relevant injection parameters would cause detectable BBB damage; however, it might be anticipated that the risk of BBB damage in acutely hypertensive patients would be increased in angiographic situations where patients receive multiple injections of CM.

An additional risk factor in cerebral angiography with acutely hypertensive patients may be x-irradiation. Rabbits made acutely hypertensive, at intervals ranging from 1 hour to 4 months, after exposure to therapeutic doses of x-irradiation (774 mC/kg given as a single dose at 80 mC/kg·min) showed substantial BBB breakdown

that was not evident after either irradiation or hypertension alone (20). Although the radiation dose received during angiography is far less than that employed for therapeutic purposes, one could speculate that angiographic radiation exposure may cause subtle changes in cerebral endothelial cells. Such changes would by themselves have no effect on the BBB but may make the cells more susceptible to the BBB-damaging combination of acute hypertension and intracerebral CM. That such low levels of radiation are capable of causing cellular changes in the central nervous system is demonstrated by the observation that doses as low as 0.01 Gy can cause transient electroencephalographic abnormalities (21).

A recent case report has provided some clinical support for these findings. The BBB breakdown observed in a patient undergoing abdominal angiography with nonionic CM was thought to be a consequence of an acute hypertensive episode during angiography (22). This suggests that even extracerebral angiography might jeopardize the BBB in cases of acute hypertension.

References

1. Johansson BB. Hypertension and the blood-brain barrier. In: Neuwelt EA, ed. *Implications of the blood-brain barrier and its manipulation*. Vol 2. New York: Plenum, 1989:389-410
2. Sage MR, Drayer BP, Dubois PJ, Heinz ER, Osborne DR. Increased permeability of the blood-brain barrier after carotid Renografin-76. *AJNR Am J Neuroradiol* 1981;2:272-274
3. Lantos G. Cortical blindness due to osmotic disruption of the blood-brain barrier by angiographic contrast material: CT and MRI studies. *Neurology* 1989;39:567-571
4. Giang DW, Kido DK. Transient global amnesia associated with cerebral angiography performed with use of iopamidol. *Radiology* 1989;172:195-196
5. Numaguchi Y, Fleming MS, Hasuo K, Puyau FA, Nice CM. Blood-brain barrier disruption due to cerebral arteriography: CT findings. *J Comput Assist Tomogr* 1984;8:936-939
6. Wilson AJ, Evill CA, Sage MR. Effects of nonionic contrast media on the blood-brain barrier: osmolality versus chemotoxicity. *Invest Radiol* 1991;26:1091-1094
7. Hayakawa K, Yamashita K, Mitsumori M, Nakano Y. Blood-brain barrier injury following intracarotid injection of radiographic contrast media: in vivo quantification using magnetic resonance imaging and Gd-DTPA. *Acta Radiol* 1990;31:203-208
8. Rapoport SI, Fredericks WR, Ohno K, Pettigrew KD. Quantitative aspects of reversible osmotic opening of the blood-brain barrier. *Am J Physiol* 1980;238:R421-R431
9. Harnish PP, Hagberg DJ. Contrast media-induced blood-brain barrier damage: potentiation by hypertension. *Invest Radiol* 1988;23:463-465
10. Aulie Michelet Å. Effects of intravascular contrast media on the blood-brain barrier: comparison between iohalamate, iohexol, iopentol and iodixanol. *Acta Radiol* 1987;28:329-333
11. Deimann W, Taugner R, Fahimi HD. Arterial hypotension induced by horseradish peroxidase in various rat strains. *J Histochem Cytochem* 1976;24:1213-1217
12. Rapoport SI. Opening of the blood-brain barrier by acute hypertension. *Exp Neurol* 1976;52:467-479
13. Sachs L. *Applied statistics: a handbook of techniques*. 2nd ed. New York: Springer, 1984:107-111
14. Saris SC, Wright DC, Oldfield EH, Blasberg RG. Intravascular streaming and variable delivery to brain following carotid artery infusions in the Sprague-Dawley rat. *J Cereb Blood Flow Metab* 1988;8:116-120
15. Westergaard E, Brightman MW. Transport of proteins across normal cerebral arterioles. *J Comp Neurol* 1973;152:17-44
16. Suzuki M, Iwasaki Y, Yamamoto T, Konno H, Kudo H. Sequelae of the osmotic blood-brain barrier opening in rats. *J Neurosurg* 1988;69:421-428
17. Salahuddin TS, Kalimo H, Johansson BB, Olsson Y. Observations on exudation of fibronectin, fibrinogen and albumin in the brain after carotid infusion of hyperosmolar solutions: an immunohistochemical study in the rat indicating longlasting changes in the brain microenvironment and multifocal nerve cell injuries. *Acta Neuropathol (Berl)* 1988;76:1-10
18. Sokrab T-EO, Johansson BB, Tengvar C, Kalimo H, Olsson Y. Adrenaline-induced hypertension: morphological consequences of the blood-brain barrier disturbance. *Acta Neurol Scand* 1988;77:387-396
19. Sokrab T-EO, Johansson BB, Kalimo H, Olsson Y. A transient hypertensive opening of the blood-brain barrier can lead to brain damage: extravasation of serum proteins and cellular changes in rats subjected to aortic compression. *Acta Neuropathol (Berl)* 1988;75:557-565
20. Blomstrand C, Johansson BB, Rosengren B. Blood-brain barrier lesions in acute hypertension in rabbits after unilateral X-ray exposure of brain. *Acta Neuropathol (Berl)* 1975;31:97-102
21. Mettler FA, Moseley RD. *Medical effects of ionizing radiation*. Orlando: Grune & Stratton, 1985:134
22. Okazaki H, Tanaka K, Shishido T, et al. Disruption of the blood-brain barrier caused by nonionic contrast medium used for abdominal angiography: CT demonstration. *J Comput Assist Tomogr* 1989;13:893-895