



Discover Generics

Cost-Effective CT & MRI Contrast Agents



FRESENIUS
KABI

WATCH VIDEO

AJNR

Anatomic moment. The septal area.

L P Mark, D L Daniels, T P Naidich, L E Hendrix and E Maas

AJNR Am J Neuroradiol 1994, 15 (2) 273-276

<http://www.ajnr.org/content/15/2/273.citation>

This information is current as
of June 2, 2025.

The Septal Area

Leighton P. Mark, David L. Daniels, Thomas P. Naidich, Lloyd E. Hendrix, and Eric Maas

The septal area is an important anterior component of the limbic system. It is located on the medial surface of the cerebral hemisphere nestled inferior to the rostrum of the corpus callosum and anterior to the third ventricle and lamina terminalis (Fig 1) (1). This small area is contiguous with components of the limbic system curving around the corpus callosum (Fig 2) as well as structures on the inferior surface of the brain such as the olfactory stria and diagonal band of

Broca. Routine clinical magnetic resonance (MR) readily demonstrates the septal area.

The septal area consists of two gyri and two sulci, all nearly vertically oriented (Fig 1). The two gyri are the subcallosal area and the smaller paraterminal gyrus. The two sulci are the anterior and posterior parolfactory sulci. Located from anterior to posterior are the anterior parolfactory sulcus, subcallosal area, posterior parolfactory sulcus, paraterminal gyrus, and the lamina terminalis and third ventricle (Fig 2). The medial and lateral septal nuclei are subcortical gray matter nuclei deep to the septal area. Alternate and potentially confusing names for septal area structures are listed in Table 1 (2).

The paraterminal gyrus and subcallosal areas, respectively, are part of the inner and outer curve

TABLE 1: Terminology

Conventional Term	Alternate Term
Subcallosal area	Parolfactory area
Paraterminal gyrus	Subcallosal gyrus
Septal area	Paraterminal body

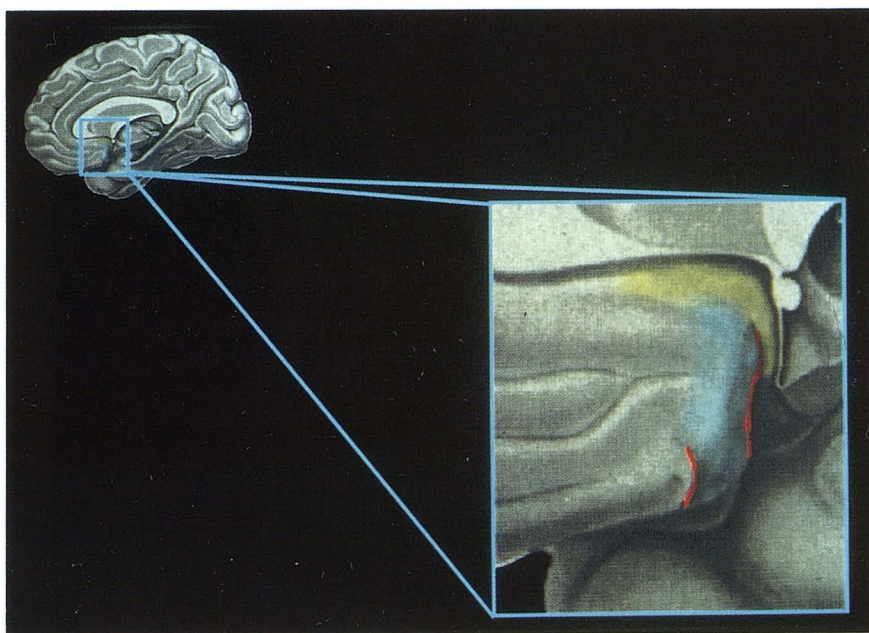


Fig. 1. Sagittal schematic showing the septal area, which consists of the paraterminal gyrus (*yellow*), subcallosal area (*aqua*), and anterior and posterior parolfactory sulci (*red*), nestled inferior to the genu and rostrum of the corpus callosum (modified from Nieuwenhuys et al [5]).

From the Department of Diagnostic Radiology, Neuroradiology Section (L.P.M., D.L.D., L.E.H.), and Department of Neurology (E.M.), Medical College of Wisconsin, Milwaukee, and Baptist Hospital (T.P.N.), Miami, Fla.

Address reprint requests to Leighton P. Mark, MD, Department of Diagnostic Radiology, Neuroradiology Section, Medical College of Wisconsin, c/o MCMC, ACC Building, Box 151, 8700 W Wisconsin Ave, Milwaukee, WI 53226.

Index terms: Brain, anatomy; Brain, magnetic resonance; Anatomic moments

AJNR 15:273-276, Feb 1994 0195-6108/94/1502-0273 © American Society of Neuroradiology

Fig. 2A. Sagittal drawing with a slight rotation to expose part of the inferior surface of the brain showing the position of the septal area relative to the corpus callosum, fornix, gyrus rectus, and olfactory tract. This slightly rotated drawing also provides an overview used for the more detailed labeling in Fig 2B (modified from Nieuwenhuys et al [5]).

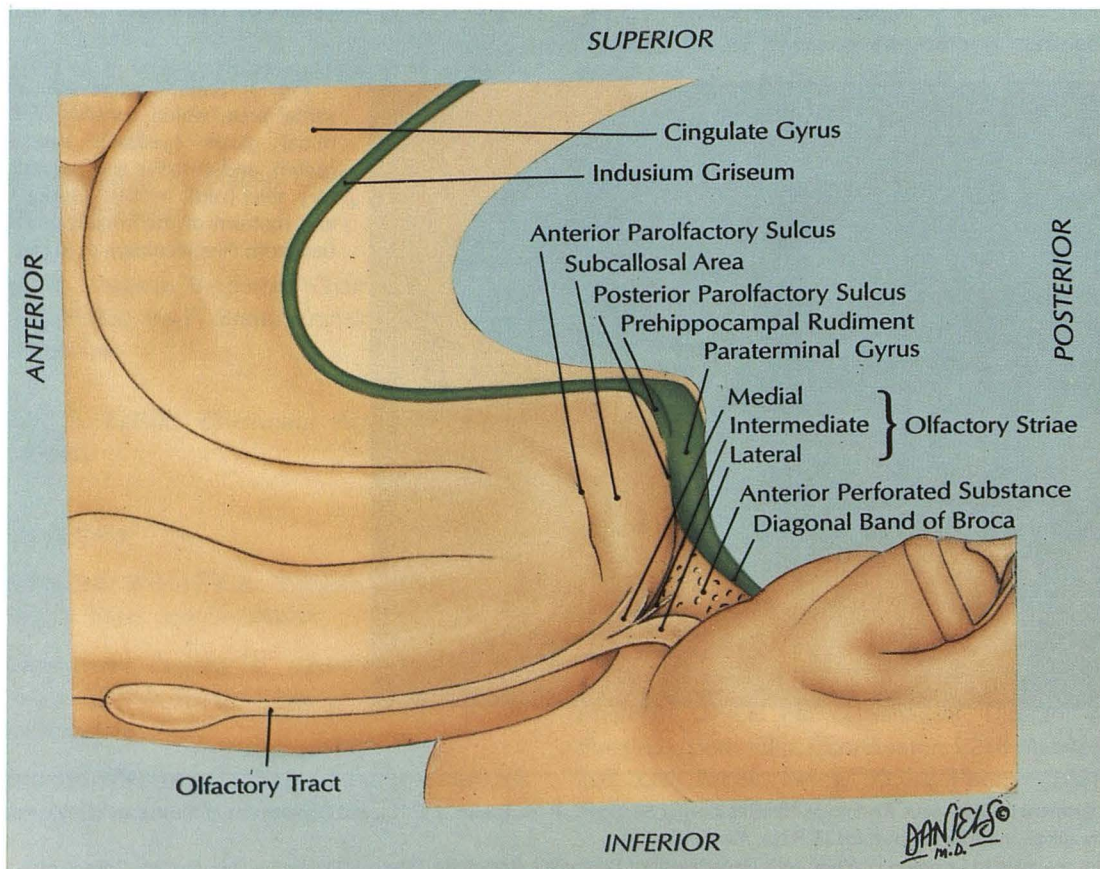
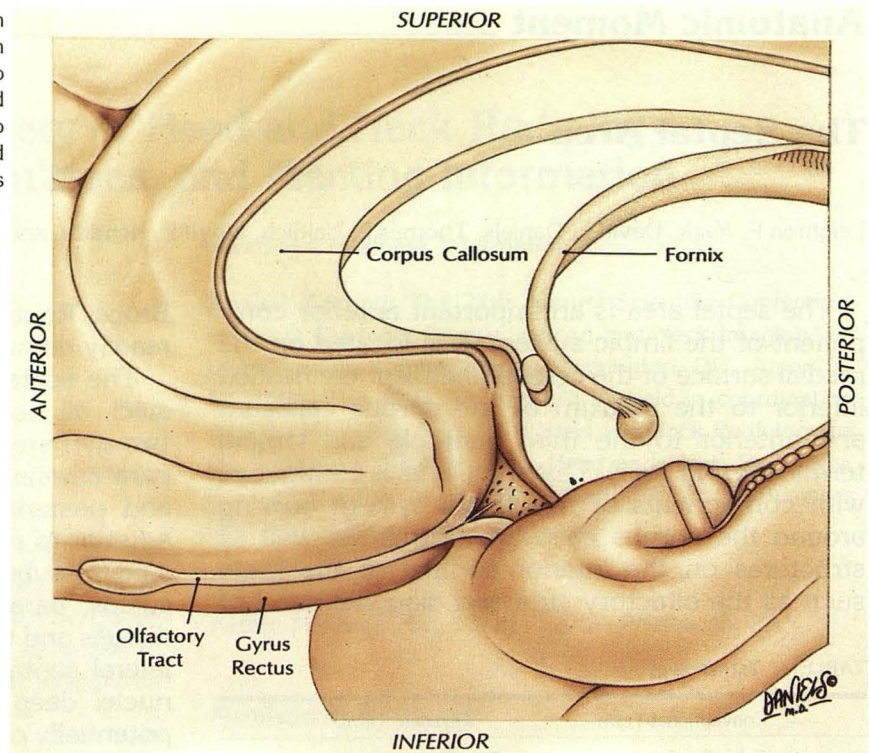


Fig. 2B. From superior to inferior, the indusium griseum, paraterminal gyrus, and the diagonal band of Broca form part of a continuous curve (green). The posterior parolfactory sulcus forms the anterior border of the paraterminal gyrus and separates the subcallosal area from the paraterminal gyrus. The anterior parolfactory sulcus forms the anterior border of the subcallosal area. Also demonstrated are the medial, intermediate, and lateral olfactory striae as well as the anterior perforated substance at the base of the brain.

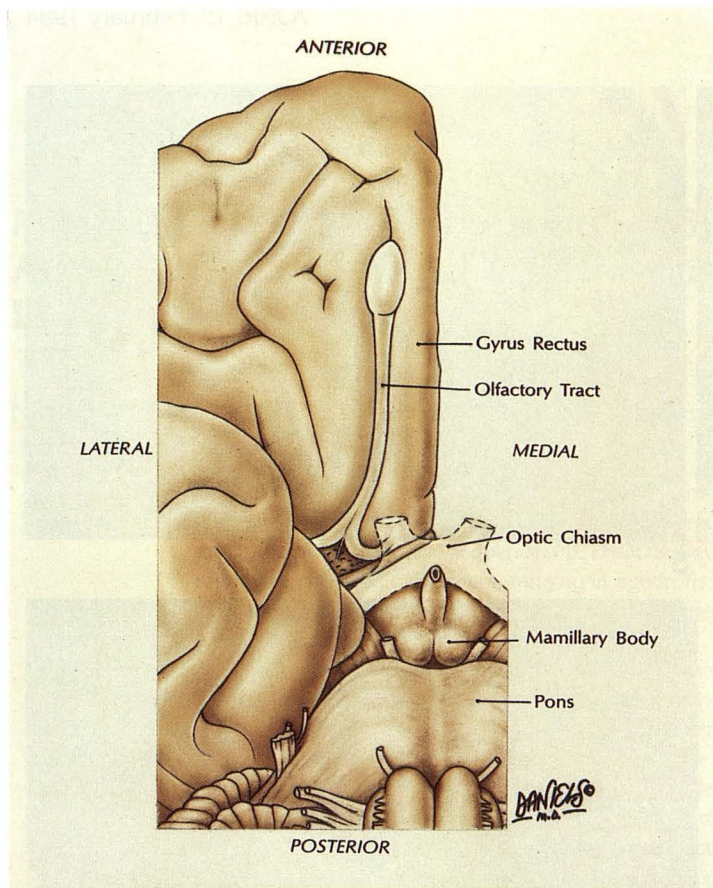


Fig. 3A. Drawing of the inferior surface of the brain showing the gyrus rectus and olfactory tract, optic chiasm (transparent with *dotted outline*), mammillary body, and pons. This drawing provides an overview for Figure 3B (modified from Nieuwenhuys et al [5]).

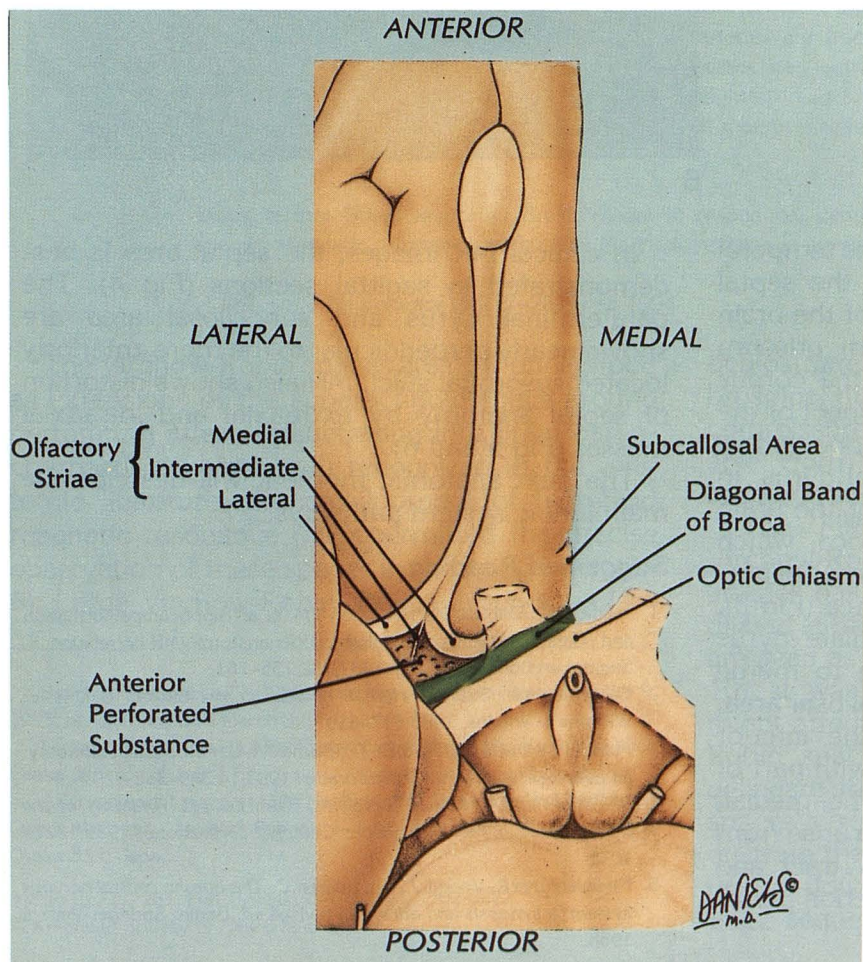
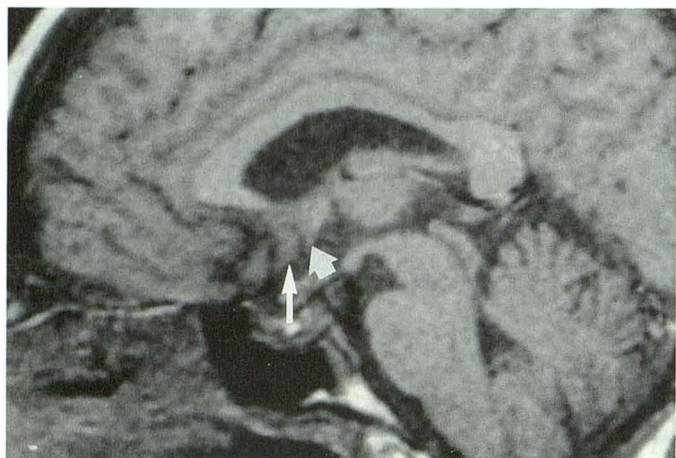

Fig. 3B. This drawing shows the position of the anterior, intermediate, and lateral olfactory striae anterior to the anterior perforated substance. The diagonal band of Broca (*green*) is posterior to the anterior perforated substance and continuous with the paraterminal gyrus on the medial surface of the hemisphere.

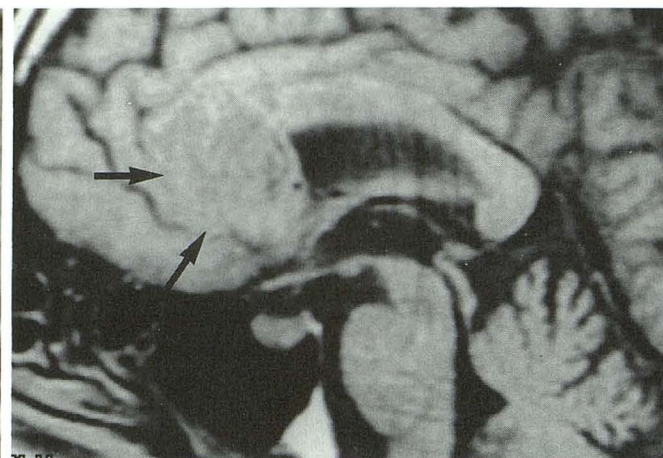


4

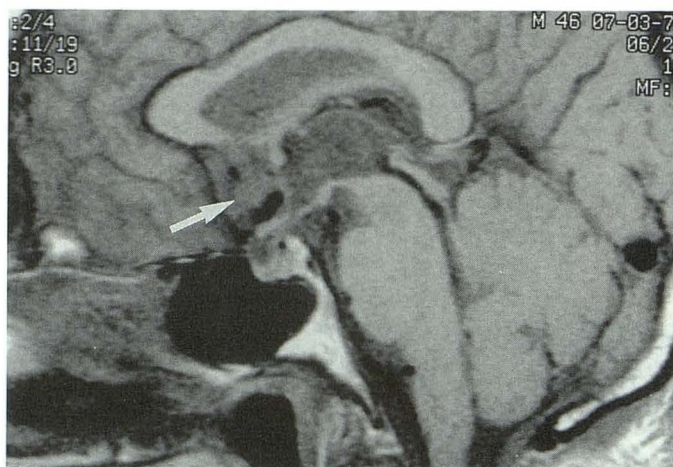
Fig. 4. T1-weighted sagittal MR image showing the position of the normal septal area consisting of the subcallosal area (thin arrow) and smaller paraterminal gyrus (thick arrow) under the corpus callosum and anterior to the third ventricle.

Fig. 5. T1-weighted sagittal MR image shows a large glioblastoma (arrows) distorting normal septal anatomy as well as the anterior corpus callosum.

Fig. 6. T1-weighted sagittal MR image demonstrates subtle distortion of the normal anatomy of the subcallosal area, paraterminal gyrus, and anterior and posterior parolfactory sulci by an extraaxial mass, a thrombosed aneurysm.



5



6

of limbic structures that extend from the temporal lobe around the corpus callosum to the septal area, and then to the inferior surface of the brain (3). In the inner curve, the indusium griseum extends around the outer surface of the corpus callosum to merge with the anterior aspect of the paraterminal gyrus called the *prehippocampal rudiment* (Fig 2) (4). The paraterminal gyrus, in turn, extends to the inferior surface of the brain joining with the diagonal band of Broca, which forms the obliquely oriented posterior-medial border of the anterior perforated substance (Fig 3). In the outer curve (Fig 2), the cingulate gyrus extends around the corpus callosum to merge with the superior aspect of the subcallosal area. The subcallosal area continues to the inferior surface of the hemisphere in contact with part of the medial olfactory stria (Fig 3). The medial, lateral, and intermediate olfactory stria arise from the posterior aspect of the olfactory tract and form the anterior margin of the anterior perforated substance.

In clinical MR images, the septal area is best demonstrated in sagittal sections (Fig 4). The paraterminal gyrus and subcallosal area are shown nearly perpendicular to the more anteriorly located suborbital sulci. MR also shows distortion of septal anatomy by extraaxial and intraaxial masses (Fig 5 and 6).

The next anatomic moment will describe the main limbic system pathways.

Suggested Reading

1. Naidich TP, Daniels DL, Haughton VM, et al. Hippocampal formation and related structures of the limbic lobe: anatomic-MR correlation. II. Sagittal sections. *Radiology* 1987;162:755-761
2. Carpenter MB, Sutin J. *Human neuroanatomy*. 8th ed. Baltimore: Williams & Wilkins, 1983:617-619
3. Mark LP, Daniels DL, Naidich TP, Borne JA. Limbic system anatomy: an overview. *AJNR Am J Neuroradiol* 1993;14:349-352
4. Williams PL, Warwick R, Dyson M, Bannister LH. *Anatomy of the human body*. 37th ed. London: Churchill Livingstone, 1989:1027-1035
5. Nieuwenhuys R, Voogd J, Van Huijzen C. *The human central nervous system: a synopsis and atlas*. 3rd revised ed. Berlin: Springer-Verlag, 1988.