



## Discover Generics

Cost-Effective CT & MRI Contrast Agents



WATCH VIDEO

# AJNR

## Prevalence and percutaneous drainage of cysts of the sacral nerve root sheath (Tarlov cysts).

R D Paulsen, G A Call and F R Murtagh

*AJNR Am J Neuroradiol* 1994, 15 (2) 293-297

<http://www.ajnr.org/content/15/2/293>

This information is current as  
of June 4, 2025.

# Prevalence and Percutaneous Drainage of Cysts of the Sacral Nerve Root Sheath (Tarlov Cysts)

Richard D. Paulsen, Glen A. Call, and F. Reed Murtagh

**PURPOSE:** To describe a percutaneous CT-guided method for drainage of perineurial (Tarlov) cysts, which are a cause of sciatica and low back pain, and to report the prevalence of these cysts within the population as detected by MR. **METHODS:** Five hundred sequential lumbosacral spine MRs were evaluated for the presence of a perineurial cyst. Using CT-guided percutaneous drainage techniques, seven cysts were drained in five symptomatic patients. **RESULTS:** Of the 500 sequential lumbosacral spine MRs, examinations from 23 patients showed perineurial cysts, a prevalence of 4.6%. Five patients (1%) were symptomatic from the cysts. After CT-guided percutaneous drainage, instant pain relief lasted from 3 weeks to 6 months without the risk or cost of spine surgery. **CONCLUSIONS:** Lumbosacral perineurial cysts are common lesions that are usually asymptomatic but may cause pressure symptoms. Cyst puncture can alleviate the pain. Although the cysts repressurized and the patients' symptoms returned in most cases, this technique seems to be a quick and simple way of at least attaining a pain-free interval and possibly a complete cure as occurred in one patient in this study.

**Index terms:** Subarachnoid space, cysts; Spinal cord, cysts; Spine, magnetic resonance; Spine, computed tomography; Spine, special procedures; Interventional neuroradiology; Nerves, sacral

*AJNR Am J Neuroradiol* 15:293-297, Feb 1994

A rare cause of sciatica is a sacral perineurial cyst, originally described by I. M. Tarlov in 1938 as an incidental finding at autopsy of 30 adults (1). In 1948, Tarlov proposed that these perineurial cysts could be symptomatic and recommended their surgical removal (2). Scattered case reports since then have postulated perineurial cysts as causes of backache, sciatica, and coccygodynia (3-5).

In an attempt to ascertain prevalence of perineurial cysts as well as association with symptoms, we evaluated 500 sequential lumbosacral spine magnetic resonance (MR) studies for evidence of cysts and correlated them with the patients' symptoms.

Current treatment requires extensive surgery with sacral laminectomy and cyst excision or shunting. Nerve fibers must often be sacrificed because they may be present in the cyst wall (6). With the advent of computed tomography (CT), percutaneous procedures have reduced the need for extensive invasive procedures for many different types of disease (7). We report on CT-guided percutaneous aspiration of these perineurial cysts for the relief of sciatica caused by compression from perineurial (Tarlov) cysts.

## Materials and Methods

Five hundred consecutive sequential MRs of the lumbosacral spine were evaluated using either Siemens (Iselin, NJ) or GE (Milwaukee, WI) 1.5-T or 1.0-T imaging systems. Of the 500 patients, 53% (265) were female and 47% (235) were male. The age range was 11 to 89 years. The scans were performed for positive workup for low back pain. Each exam was inspected for the presence of a perineurial cyst whether these were single or multiple. The findings were correlated with the patient's symptoms. Percentages for prevalence in the population studied, and rates of symptomaticity were then calculated.

Five patients who had symptoms possibly related to cysts of S1-S3 underwent percutaneous drainage. The

---

Received September 9, 1992; accepted pending revision December 3; revision received January 20, 1993.

From the Department of Radiology, University of South Florida College of Medicine, Tampa.

Address reprint requests to F. Reed Murtagh, MD, Department of Radiology, University of South Florida, College of Medicine, 12901 Bruce B. Downs Blvd, Box 17, Tampa, FL 33612.

*AJNR* 15:293-297, Feb 1994 0195-6108/94/1502-0293

© American Society of Neuroradiology

table summarizes the patients' symptoms and cyst size. Using thin-section (2-mm) high-resolution CT-guidance (Siemens Somatom DR-H, Iselin, NJ) percutaneous drainage was performed. The patient was placed in the scanner in a prone position. After making the site of the cyst to be drained on the skin, 1% lidocaine was injected to anesthetize the needle insertion site. With CT guidance, an 18- to 22-gauge spinal needle was placed through the appropriate sacral foramina or a small opening through the eroded dorsal elements into the cyst (Figs 1 and 2). In the case that neither could be found, a hole was created with the spinal needle. Each perineurial cyst was easily drained with no resultant persistent cerebrospinal fluid (CSF) leaks or nerve damage in this study. Each patient was followed for 6 to 9 months for return of symptoms.

## Results

Of 500 consecutive patients examined with MR, 23 (4.6%) had findings of perineurial cysts. Of the patients with cysts, five (1% of total, 22% of patients with cysts) had symptoms of local low back pain and radiculopathy along a distribution consistent with the location of the cyst.

The five patients with symptomatic cysts had percutaneous drainage of their perineurial cysts (Table 1). The first patient, a 37-year-old woman, was tapped twice; she received relief for 2 to 3 weeks each time. A 73-year-old woman was also tapped twice with about 4 months of relief each time. The other three patients all were tapped a single time. A 45-years-old woman had complete relief for 6 weeks at which time she died from her coexisting ovarian cancer.

TABLE 1: Summary of five female patients who underwent percutaneous drainage of perineurial cysts

Age	Symptoms	Findings	Results
37	S1 ipsilateral radiculopathy	Multiple cysts with largest measuring 2.5 cm	Tapped twice with relief of 2 to 3 weeks each time
45	Local sacral pain	Single 3.0-cm cyst	Tapped once with relief for 6 weeks
49	S1 and S2 ipsilateral radiculopathy	Multiple cysts with largest measuring 2.1 cm	Tapped once with relief for 3 weeks
60	S2 ipsilateral radiculopathy	Single 1.9-cm cyst	Tapped once with complete relief and no recurrence
73	Local sacral pain	Single 1.6-cm cyst	Tapped twice with 4 months of relief each time

A 49-year-old woman with multiple cysts had the largest one (measuring 2.1 cm) drained and had pain relief for 3 weeks before recurrence. The last patient is a 60-year-old woman who has had relief for 6 months with no pain recurrence. Of the five patients, two received relief for approximately 5 months and the other three for approximately 3 weeks. Of the five patients, two of them had multiple cysts. Interestingly, all of the patients were female.

## Discussion

Sacral perineurial cysts arise in the sacrococcygeal nerve roots, most commonly at the second and third sacral nerve root levels. The cyst wall is continuous with the arachnoid and dura of the posterior roots. The cyst cavity itself occupies the space between the perineurium (arachnoid covering the root) and the endoneurium (outer layer of the pia). Unlike meningeal cysts or diverticula, at least part of the lining of the perineurial cyst contains nerve fibers and, occasionally, ganglion cells, and the entire cyst may be surrounded by neural tissues (4). This places these cysts in Nabors's type II classification of spinal meningeal cysts (extradural meningeal cyst with spinal nerve root fibers) (6). The cysts arise most commonly at the junction of the posterior root and the dorsal ganglion. They often can be multiple (6). Although meningeal cysts, root pouch diverticula, and perineurial cysts differ pathologically, these conditions appear identical on myelographic and MR studies.

The pathogenesis of perineurial cysts is uncertain. Tarlov felt that hemorrhage into the subarachnoid space caused accumulations of red cells which impeded the drainage of the veins in the perineurium and epineurium, leading to rupture with subsequent cyst formation (8). Four out of the seven patients in Tarlov's 1970 article had a history of trauma (9). Schreiber and Haddad also supported this posttraumatic cause of cyst formation (10). Because many of the patients with perineurial cysts in his series did not have histories of trauma, Fortuna et al believed that the perineurial cysts were congenital, caused by arachnoidal proliferations within the root sleeve. These proliferations may lead to obstruction of normal CSF pathways (11).

The ultimate mechanism of cyst formation, regardless of the underlying cause, is stenosis of the ostium of the nerve root sheath. CSF is able to flow into the cyst with arterial pulsation, but

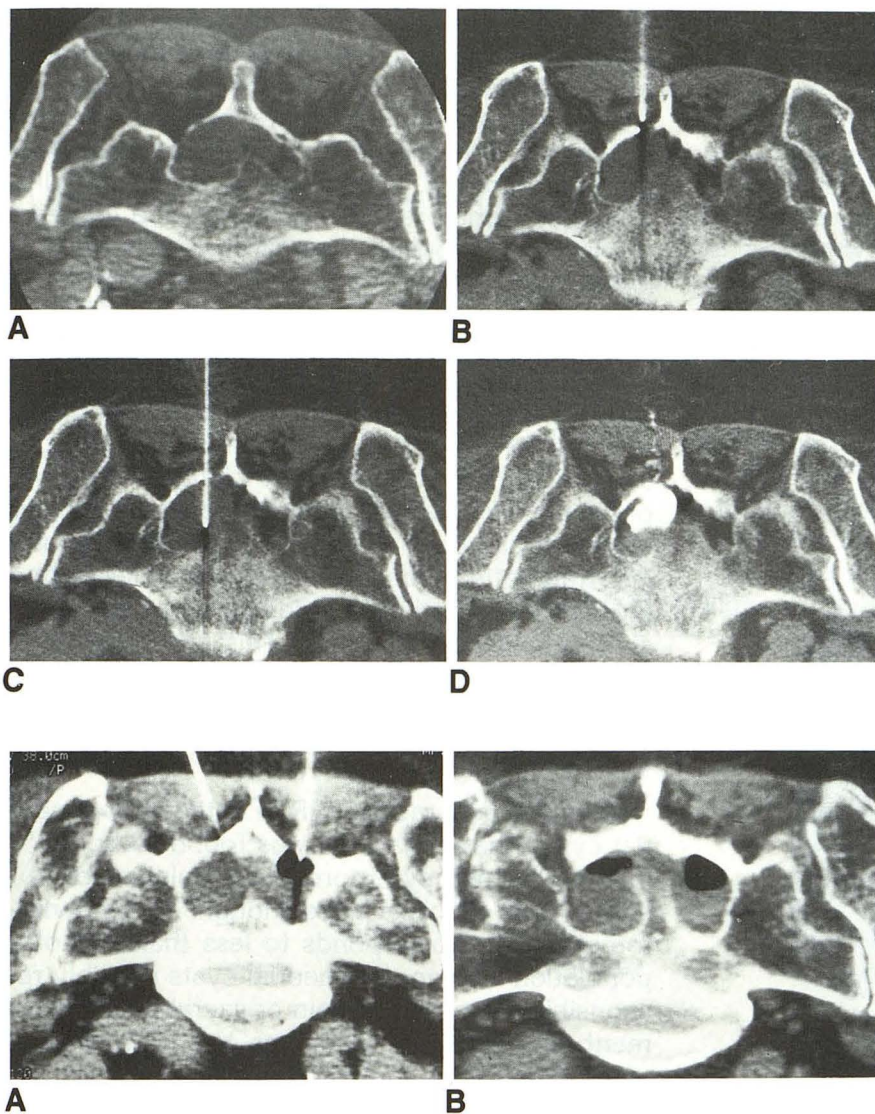


Fig. 1. A, Unenhanced axial CT image of the sacrum demonstrating a perineurial cyst eroding the bone and thinning the posterior lamina.

B, Twenty-gauge spinal needle in position to enter the cyst through a defect in the lamina.

C, Twenty-gauge spinal needle within the cyst.

D, Infusion of contrast to define the limits of the cyst cavity, which was then drained.

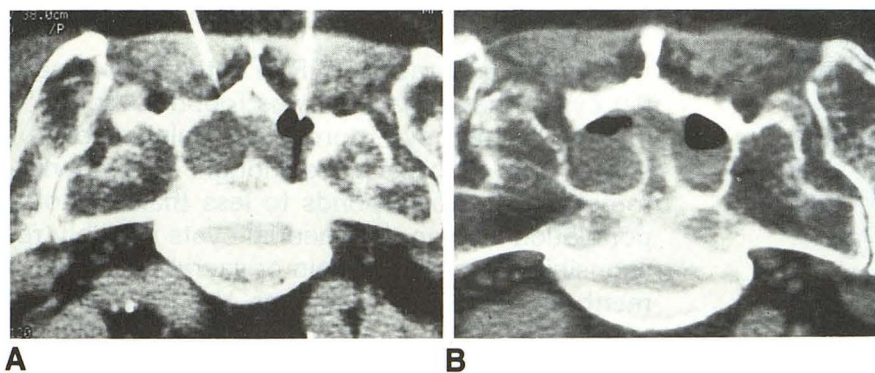


Fig. 2. A, A patient with multiple cysts being drained.

B, Postdrainage scan of the patient.

outflow is restricted because of a ball-valve phenomenon (12).

Diagnosis of perineurial cysts has been improved in recent years with the advent of CT and MR, but it is still impossible to tell how much neural tissue may be present in the cyst wall. Originally the diagnosis was made with plain film and myelography. Plain films may demonstrate characteristic bone erosion of the spinal canal or the anterior or posterior neural foramina. Myelography may demonstrate delayed filling of the cyst especially if using an oil-based contrast material, (such as iophendylate) because the communication between the subarachnoid and subperineurial spaces is not adequate to allow immediate visualization of the perineurial spaces. The pulsatile pressure of the CSF forces the contrast gradually into the perineurial space along the nerve roots and into the perineurial cysts (4). Using currently

available water-soluble contrast materials which have a lower viscosity than iophendylate, perineurial cysts may fill rapidly at myelography (6).

CT myelography and MR have improved the detection of perineurial cysts. CT without intrathecal contrast can demonstrate cystic masses isodense with CSF located at the foramina. Enlarged neural foramina may be secondary to remodeling from increased pressure in the cystic nerve root sheaths. Because of the presence of the cyst, there may be asymmetry of the epidural fat distribution and a capacious dural sac (13). With CT myelography only a small amount of contrast has to enter the cyst before it can be visualized. The advantages of MR over CT in the sacral region include better resolution of tissue density, absence of bone interference, and multiplanar capabilities. As a result, MR is the current imaging study of choice for perineurial cysts. MR

is also noninvasive, eliminating the need for a myelogram (14). The cysts demonstrate low signal on T1-weighted images and high signal on T2-weighted images, similar to CSF (Figs 3 and 4). Because the cysts have a one-way ball-valve mechanism, the CSF is static within the cysts, and flow-sensitive MR pulse sequences can be used to differentiate cysts from moving CSF in the subarachnoid space (13). Bone erosion also can be seen on MR, including canal widening, foraminal enlargement, or pedicle erosion.

Current treatment of symptomatic perineurial cysts involves surgical decompression with a sacral laminectomy and digital pressure to drain the cysts followed by gentle bipolar cautery to shrink the cysts (14). The risks associated with puncturing and draining perineurial cysts are infection, spinal headache, and CSF leak. Some cysts may

require complete removal, and adhering ganglia and nerve roots may be sacrificed, causing neurologic deficits such as urinary disturbances (8). When cysts are multiple, more extensive surgery is required with unroofing of the cysts and piecemeal excision of thin slices of the underlying tissue (8). Tarlov reported one case of a 49-year-old woman who had a sacral laminectomy followed by puncture drainage of a second sacral nerve root perineurial cyst instead of complete removal. She had total relief from her symptoms for 6 months (8). This study suggests that percutaneous drainage can give a reliable, minimally invasive form of relief to patients suffering from sciatica caused by nerve root compression from perineurial cysts and formed the basis for our clinical trials. Even if temporary, this quick and less traumatic procedure can supply relief during an interim until more extensive and permanent surgery can be performed. This procedure may even be curative in some patients.

### Conclusion

With the accuracy of MR in detecting perineurial cysts, the prevalence was found to be 4.6% in the clinically symptomatic population of our study; 22% of cysts were thought to be symptomatic. This corresponds to less than 1% of a population's having perineurial cysts possibly responsible for low back pain or sacral pain. Treatment for these abnormalities has consisted of extensive sacral laminectomies with cyst removal. This kind of treatment may be avoided or postponed by using percutaneous CT-guided

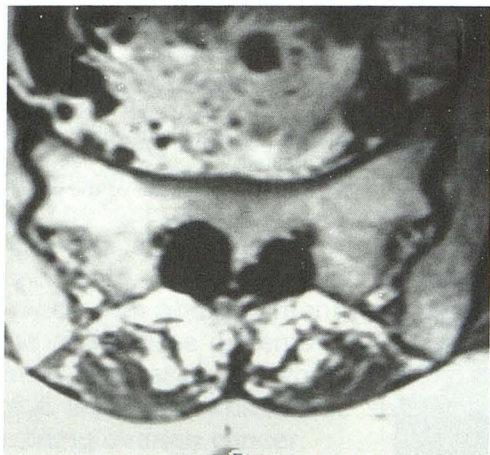


Fig. 3. T1-weighted axial MR image in patient with multiple cysts.

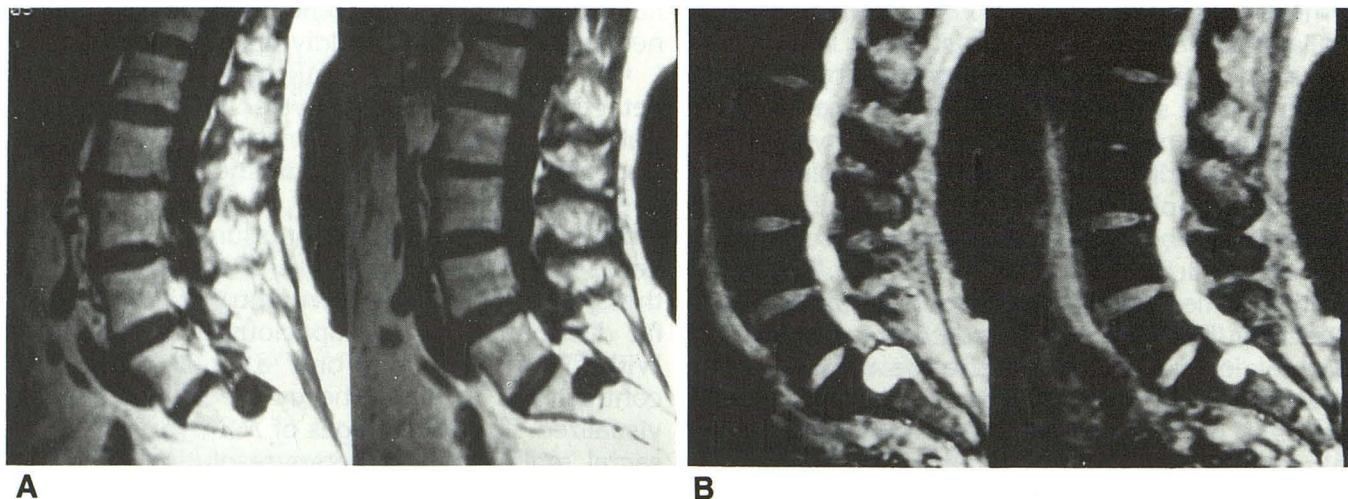


Fig. 4. A, T1-weighted sagittal MR image with multiple CSF line signal lesions within the sacral region representing perineurial cysts. B, T2-weighted sagittal MR image of the same patient.

drainage. Although in our experience most of the cysts eventually seem to repressurize, complete cure may be possible in some instances.

## References

1. Tarlov IM. Perineural cysts of the spinal nerve roots. *Arch Neurol Psychiatry* 1938;40:1067-1074
2. Tarlov IM. Cysts of the sacral roots. *JAMA* 1948;138:740-744
3. Davis DH, Wilkinson TJ, Teaford KA, Smigiel MR. Sciatica produced by a sacral perineurial cyst. *Tex Med* 1987;83:55-56
4. Nishiura I, Koyama T, Handa J. Intracanal perineurial cyst. *Surg Neurol* 1985;23:265-269
5. Ziegler DK, Batnitzky S. Coccygodynia caused by a perineurial cyst. *Neurology* 1984;34:829-830
6. Nabors MW, Pait TG, Byrd EB, et al. Updated assessment and current classification of spinal meningeal cysts. *J Neurosurg* 1988;68:366-377
7. Van Sonnenberg E, Agostino HB, Casola G, Halasz NA, Sanchez RB, Goodacre BW. Percutaneous abscess drainage. Current concepts. *Radiology* 1991;181:617-626
8. Tarlov IM. *Sacral nerve-root cysts. Another cause of the sciatic or cauda equina syndrome*. Springfield: Thomas, 1953:22-27
9. Tarlov IM. Spinal perineurial and meningeal cysts. *J Neurol Neurosurg Psychiatry* 1970;33:833-843
10. Schreiber F, Haddad B. Lumbar and sacral cysts causing pain. *J Neurosurg* 1951;8:504-509
11. Fortuna A, La Torre E, Ciappetta P. Arachnoid diverticula: a unitary approach to spinal cysts communicating with the subarachnoid space. *Acta Neurochir* 1977;39:259-268
12. Enzmann DR, DeLaPaz RL, Rubin JB. *Magnetic resonance of the spine*. St Louis: Mosby, 1990:225-231
13. Tabas J, Deeb Z. Diagnosis of sacral perineurial cysts by computed tomography. *J Comput Tomogr* 1986;10:255-259
14. Rodziewicz G, Kaufman B, Spetzler RF. Diagnosis of sacral perineurial cysts by nuclear magnetic resonance. *Surg Neurol* 1984;22:50-52

Please see the Commentary by Wilkins on page 298 in this issue.