



Discover Generics

Cost-Effective CT & MRI Contrast Agents



FRESENIUS
KABI

WATCH VIDEO

AJNR

Prevalence and Percutaneous Drainage of Cysts of the Sacral Nerve Root Sheath (Tarlov Cysts)

Robert H. Wilkins

AJNR Am J Neuroradiol 1994, 15 (2) 298-299

<http://www.ajnr.org/content/15/2/298.citation>

This information is current as
of June 4, 2025.

Prevalence and Percutaneous Drainage of Cysts of the Sacral Nerve Root Sheath (Tarlov Cysts)

Robert H. Wilkins, *Professor and Chief, Division of Neurosurgery, Duke University Medical Center, Durham, NC*

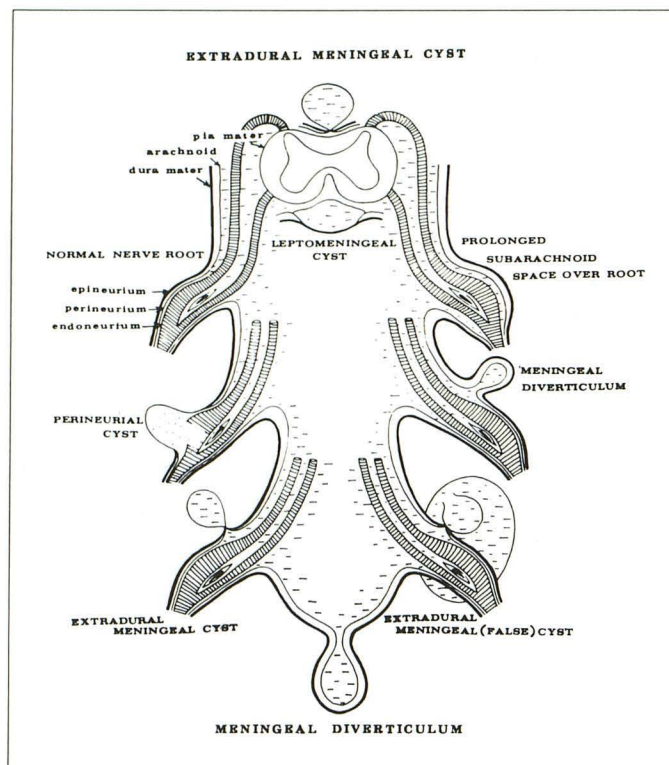


Fig. 1. A schematic illustration of some of the types of spinal extradural cysts, including the perineurial cyst. (from Tarlov [5]).

Paulsen et al in this issue provide the reader with a succinct review of Tarlov cysts, an estimate of their prevalence, and a new method of managing those that become symptomatic (1). Among 500 sequential magnetic resonance studies of the lumbosacral spine, the authors identified 23 patients with such cysts. Five of the patients were thought to be symptomatic from this condition and were treated by computed tomography-guided percutaneous cyst drainage.

In 1938, Dr Isadore M. Tarlov published an anatomic study of the structure of the filum terminale (2). During this investigation of approximately 30 human subjects at autopsy, Tarlov unexpectedly found cysts on the sacral or coccygeal posterior nerve roots of five subjects who

ranged in age from 49 to 63 years (3). In each of the involved nerves, the posterior root and/or ganglion was enlarged by a cyst that contained clear fluid that was colorless or faintly yellow. The larger cysts seemed to compress the corresponding anterior nerve root and the anterior and posterior roots of adjacent nerves.

According to Tarlov, "Microscopic study of these cysts showed that they arose between the arachnoid covering the nerve root (perineurium) and the outer layer of its pial cover (endoneurium) (Fig 1). They seemed to begin at one point in the circumference of the nerve root or ganglion, usually dorsally, and then to extend around its entire circumference, although occasionally the cyst dissected through the nerve root and was surrounded by nerve fibres or ganglion cells. Often much of the nerve root and ganglion was destroyed in the process. The outer wall of the cyst was found to be composed of vascular connective tissue (thinned dura mater, or epineurium) lined by flattened arachnoid. The inner wall of the cyst

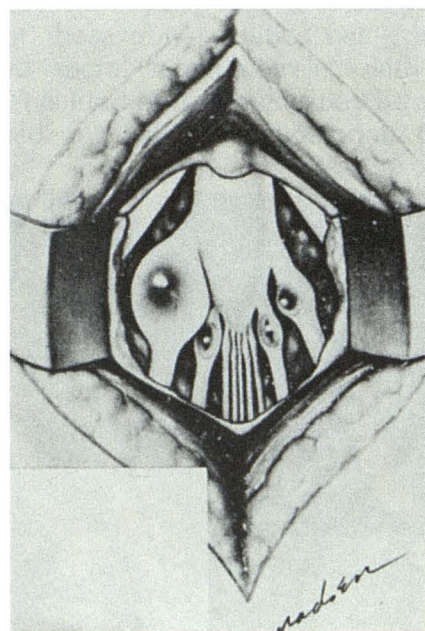


Fig. 2. A drawing of the multiple perineurial cysts of the sacral nerve roots as they were encountered at surgery (from Tarlov [7], copyright 1952, American Medical Association).

consisted of the flattened endothelium and reticulin of the pia mater" (4).

Although Tarlov thought initially that perineurial cysts did not communicate with the spinal subarachnoid space, he later showed that they would fill in delayed fashion after myelography using iophendylate (5). In the present era of water-soluble contrast agents, it is not uncommon to encounter incidental sacral perineurial cysts during myelography. These typically are multiple and bilateral, although one or two of the cysts may be much larger than the others.

Tarlov's experience with perineurial cysts spanned more than three decades (2, 3, 5-9). Although he recognized the incidental nature of most of these cysts, he thought that such cysts can at times be the cause of sciatica or a sacral nerve root dysfunction syndrome. Between 1948 and 1970, at least 59 cases of symptomatic spinal perineurial cysts were reported in the literature, and some were treated surgically (Fig 2) (4).

In general, treatment of symptomatic perineurial cysts has not been very satisfactory. Tarlov noted in 1953 that the results of simple aspiration were disappointing (9). Because a perineurial cyst ordinarily communicates with the spinal subarachnoid space, it is expected to refill after such treatment, with recurrence of the original symptoms. Forms of surgical treatment designed to preserve the nerve, such as reduction of the cyst wall or the insertion of fat into the cyst, also have

been followed by cyst reinflation. It seems now that the only way to avoid the problem of reinflation of the cyst is to excise the cyst, dividing the parent nerve in the process. Depending on the specific nerve, some form of neurologic deficit would be expected, such as loss of sensation in the autonomous zone of the divided nerve. Because of this, and the potential for impairment of bladder and bowel control, it would not be appropriate to treat multiple bilateral sacral cysts in this fashion.

References

1. Paulsen RD, Call GA, Murtagh FR. Prevalence and percutaneous drainage of cysts of the sacral nerve root sheath (Tarlov cysts). *AJNR Am J Neuroradiol* 1994;15:293-297
2. Tarlov IM. Structure of the filum terminale. *Arch Neurol Psychiatry* 1938;40:1-17
3. Tarlov IM. Perineurial cysts of the spinal nerve roots. *Arch Neurol Psychiatry* 1938;40:1067-1074
4. Wilkins RH, Odom GL. Spinal extradural cysts. In: Vinken PJ, Bruyn GW, eds. *Handbook of clinical neurology. vol 20. Tumors of the spine and spinal cord. part II*. Amsterdam: North-Holland, 1976:137-175
5. Tarlov IM. Spinal perineurial and meningeal cysts. *J Neurol Neurosurg Psychiatry* 1970;33:833-843
6. Tarlov IM. Cysts (perineurial) of the sacral roots. Another cause (removable) of sciatic pain. *JAMA* 1948;138:740-744
7. Tarlov IM. Cysts of the sacral nerve roots. Clinical significance and pathogenesis. *Arch Neurol Psychiatry* 1952;68:94-108
8. Tarlov IM. Sacral nerve-root cysts: pathogenesis and clinical significance. *J Nerv Ment Dis* 1953;117:156-157
9. Tarlov IM. *Sacral nerve-root cysts. Another cause of the sciatic or cauda equina syndrome*. Springfield: Thomas, 1953