



Discover Generics

Cost-Effective CT & MRI Contrast Agents



FRESENIUS
KABI

WATCH VIDEO

AJNR

MR of primary extraosseous Ewing sarcoma.

K Allam and G Sze

AJNR Am J Neuroradiol 1994, 15 (2) 305-307

<http://www.ajnr.org/content/15/2/305>

This information is current as
of June 4, 2025.

MR of Primary Extraosseous Ewing Sarcoma

Khalid Allam and Gordon Sze

Summary: We present MR imaging findings of a 15-year-old girl with a history of chronic back pain, proved by biopsy to be caused by primary extraosseous Ewing sarcoma, extending into the spinal epidural space. We also demonstrate the involvement of the adjacent structures and encroachment on the intervertebral foramina.

Index terms: Sarcoma; Spine, magnetic resonance; Spine, neoplasms; Pediatric neuroradiology

Ewing sarcoma, first described in 1921 (1), is primarily a childhood malignancy. It is the second most common primary malignant neoplasm of bone after osteosarcoma in the second decade of life (2). Histologically, Ewing sarcoma is characterized by a distinctive small round-cell infiltration. The tumor is seen frequently in the long bones (50%) and the flat bones (40%). The femur is most commonly affected (3).

Clinical Information

A 15-year-old girl with a history of chronic back pain presented with severe back pain radiating to the legs. There was no history of trauma and no history of numbness, weakness, or bladder or bowel changes. The patient did note a 7-pound weight loss over the previous few months. At physical examination a large tender mass was found in her back.

A bone scan showed foci of increased activity in the region of the right pedicle of L-1 of uncertain cause. Computed tomography revealed a large, heterogeneous, and only minimally enhancing paraspinal mass on the right with extension into the spinal canal as well as focal erosions of the posterior body of the L-1 vertebra. The epicenter appeared to lie in the right psoas muscle and posterior spinal muscles.

Magnetic resonance (MR) of the lower thoracic and lumbar spine (Fig 1) demonstrated a mass centered in the right psoas muscle extending from T-12 to approximately L-3. The mass extended to the erector spinae muscles and

entered the neural foramina at T-12-L-1, L1-2, and L2-3, invading the epidural space and causing mild cord compression. The right paraspinal portion seemed heterogeneous and enhanced, as did the erector spinae portion. Approximate tumor dimensions were 8.0 cm (superior-inferior) by 5.0 cm (transverse) by 9.0 cm (anterior-posterior).

Percutaneous biopsy disclosed primary extraosseous Ewing sarcoma. Sheets of oval-shaped tumor cells with high nuclear-to-cytoplasmic ratios and large areas of necrosis and small vessels were seen throughout the tumor.

Discussion

Extraskelatal Ewing sarcoma is a rare soft-tissue tumor that is histologically and ultrastructurally indistinguishable from the osseous form. Genetic predisposition is also similar, including the same translocations involving band q 12 of chromosome 22 (4).

Electron microscopic studies have failed to identify convincingly the cell of origin of this neoplasm, which is a primitive small round-cell tumor. Its morphologic appearance is strongly reminiscent of Ewing sarcoma. The site of origin is the main difference between these tumors and typical Ewing sarcoma, which is a tumor of bone; these variants (some authors have called them special undifferentiated types 1 and 2 rhabdomyosarcoma) (5) arise in extraskelatal soft tissue at various anatomic sites, particularly the paravertebral area and the lower extremity. The histologic similarity between these tumors is probably a reflection of the fact that they are all primitive mesenchymal neoplasms (5).

Extraosseous Ewing sarcoma has been noted to arise in different sites, including the scalp, the larynx, the nasal fossa, the neck, the chest wall, the lung, paravertebrally, the pelvis, the perineum, the arm, the finger, the leg, and the toe.

Received August 12, 1992; accepted pending revision November 11; revision received December 16.

From the Department of Diagnostic Radiology, Yale University School of Medicine, New Haven, Conn.

Address reprint requests to Gordon Sze, MD, Yale University School of Medicine, Department of Diagnostic Radiology, NF 2-123, 333 Cedar St, New Haven, CT 06510.

AJNR 15:305-307, Feb 1994 0195-6108/94/1502-0305 © American Society of Neuroradiology

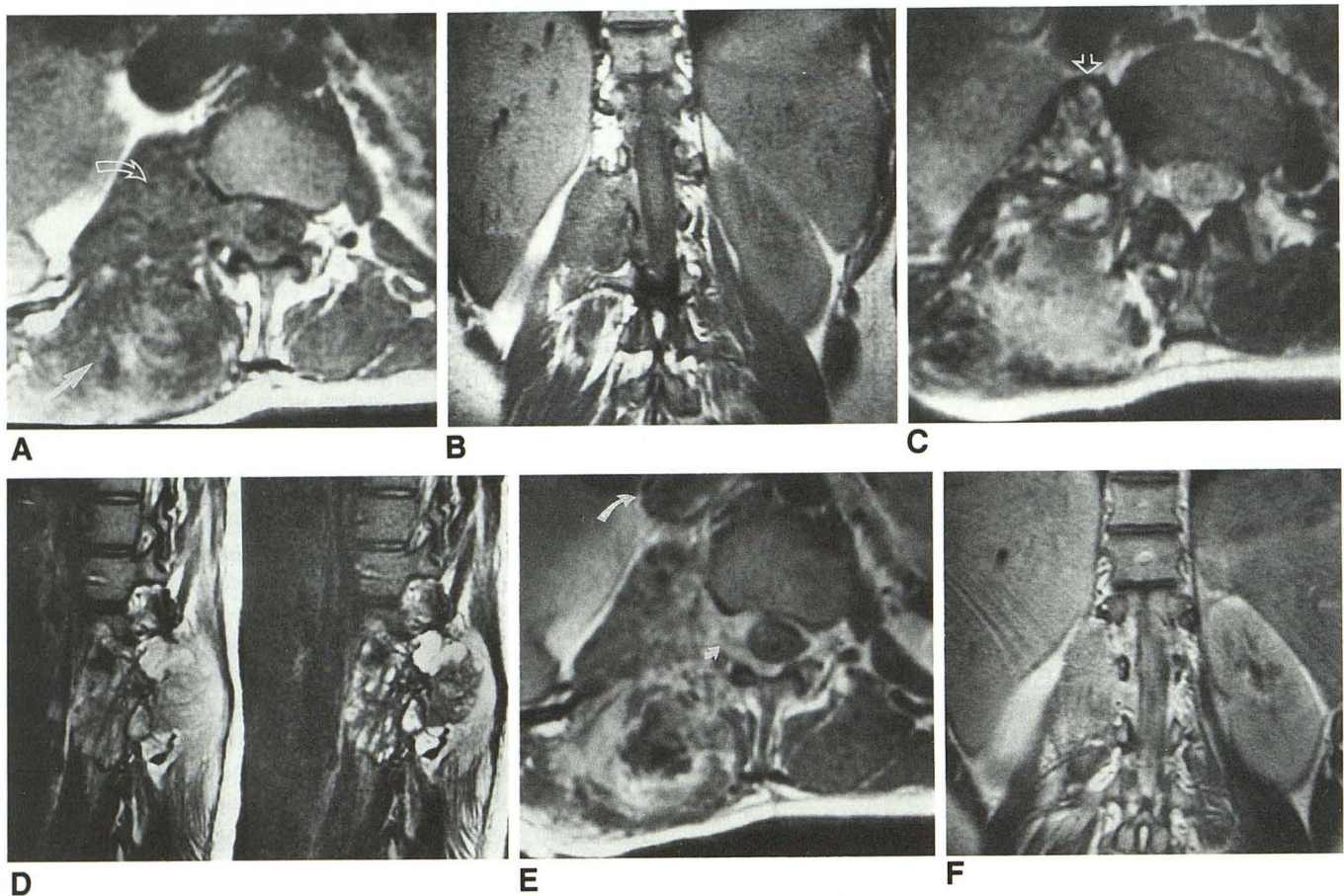


Fig. 1. Short-repetition-time axial (450/17/2 [repetition time/echo time/excitations]) (A) and coronal (700/11/2) (B) images demonstrate a right paravertebral mass with intermediate signal intensity extending into the intervertebral foramina of the upper lumbar vertebrae, disclosing the spinal cord. Long-repetition-time axial (2500/84/2) (C) and sagittal (3000/112/2) (D) images demonstrate a heterogeneous mottled appearance of the mass. Short-repetition-time axial (450/11/2) (E) and coronal (450/11/2) (F) postcontrast scans demonstrate heterogeneous enhancement. Extension to the erector spinae muscles (*long arrow*), retroperitoneum (*open curved arrow*), and crus of the diaphragm (*open arrow*), and widening the neural foramina and surrounding the spinal cord (*small curved arrow*). The *curved closed arrow* indicates the inferior vena cava.

Sixteen well-documented cases of extraskelatal Ewing sarcoma arising primarily in the spinal epidural space have been reported. The male-to-female ratio is about 1.5:1. Age incidence ranges from 4 to 47 years (6). Symptoms include back pain and/or radicular pain, paresis of one or both legs, sensory disturbances, and bladder and bowel dysfunction. Compression of the spinal cord and/or nerve roots may occur. The differential diagnosis includes intervertebral disk herniation, benign extradural and intradural tumors such as neurenteric cysts, lipoma, angioma, meningioma, fibroma, neurofibroma, dermoid cyst, abscess, and even extramedullary hematopoiesis. Malignancies other than extraskelatal Ewing sarcoma do occur in the spinal epidural space, either as primary or metastatic tumors. Leukemia, lymphoma, and other sarcomas are relatively fre-

quent in children. Spinal metastases from other primary tumors, such as Ewing sarcoma of bone, embryonal rhabdomyosarcoma, chondrosarcoma, synovial sarcoma neuroblastoma, and osteogenic sarcoma, have been reported (6). MR of skeletal Ewing sarcoma is able to show the extent of disease within the marrow cavity. Decreased signal intensity on T1-weighted images and increased signal intensity on T2-weighted images can differentiate tumor from surrounding normal marrow. The tumor can be inhomogeneous secondary to hemorrhage, calcification, or necrosis. Gadolinium enhancement has been observed (7).

In conclusion, we have presented an unusual case of extraskelatal Ewing sarcoma. Although the MR findings were nonspecific MR was valuable in defining the soft-tissue extent of the tumor

and involvement of the adjacent muscles, neurovascular bundle, and bony structures.

References

1. Ewing J. Diffuse endothelioma of bone. *Proc NY Pathol Soc* 1921;21:17-24
2. Kozłowski K, Beluffi G, Masel J, et al. Primary vertebral tumors in children. Report of 20 cases with brief review of the literature. *Pediatr Radiol* 1984;14:129-139
3. Wilner D. Ewing's Sarcoma. In: Wilner D, ed. *Radiology of tumors and allied disorders*. Philadelphia: Saunders, 1982:2096-2031
4. Angervall L, Enzinger FM. Extra skeletal neoplasm resembling Ewing's sarcoma. *Cancer* 1975;36:240-251
5. Altman AJ, Schwartz AD. *Malignant diseases of infancy, childhood, and adolescence*. 2nd ed. Philadelphia: Saunders, 1983:428
6. Kaspers JL, Kamhorst W, Graaff M, Alphen AM, Veerman AP. Primary spinal epidural extraosseous ewing's sarcoma. *Cancer* 1991;68:648-654
7. Twohig M, Sze G. Spinal tumors. In: Cohen MD, Edward MK, eds. *Magnetic resonance imaging of children*. Philadelphia: Decker, 1990:463-498