



Discover Generics

Cost-Effective CT & MRI Contrast Agents



FRESENIUS
KABI

WATCH VIDEO

AJNR

Diagnosing intracranial vasculitis: the roles of MR and angiography.

K G Harris, D D Tran, W J Sickels, S H Cornell and W T Yuh

AJNR Am J Neuroradiol 1994, 15 (2) 317-330

<http://www.ajnr.org/content/15/2/317>

This information is current as
of June 6, 2025.

Diagnosing Intracranial Vasculitis: The Roles of MR and Angiography

Kurt G. Harris, Duc D. Tran, William J. Sickels, Steven H. Cornell, and William T. C. Yuh

PURPOSE: To describe our experience with MR and angiography in diagnosing intracranial vasculitis and to test the hypothesis that MR can be used to screen for patients unlikely to have vasculitis. **METHODS:** Ninety-two patients who had angiography with "exclude vasculitis" as the indication or who had angiography and a clinical diagnosis of vasculitis were identified. Angiograms of all 92 patients and the MRs of the 70 patients who had both studies were reviewed. **RESULTS:** Eleven patients had intracranial vasculitis. Angiography showed characteristic changes in 8. MR, performed in 9 of 11 vasculitis cases, was significantly abnormal in all 9. Among 70 patients who had both studies, 19 had MR that was completely normal or showed only incidental findings. None of these 19 was diagnosed with vasculitis. The diagnostic yield of angiography performed to exclude vasculitis was only 6%. **CONCLUSIONS:** Evaluation for intracranial vasculitis should include MR. A negative MR excludes intracranial vasculitis more definitively than does a negative angiogram and makes the likelihood of finding vasculitis with angiography negligible.

Index terms: Vasculitis; Angiography, comparative studies; Magnetic resonance, indications

AJNR Am J Neuroradiol 15:317-330, Feb 1994

Intracranial vasculitis is a group of disorders resulting in intracranial vascular inflammation. Most of these are thought to be immune-mediated, either by immune complex deposition or cellular mechanisms (1-3). Diagnosis is difficult, yet critical, particularly for primary angiitis of the central nervous system (PACNS), which has non-specific and protean manifestations and a poor prognosis if left untreated (4). Angiography and brain biopsy have been the mainstays of diagnosis, but both have limitations. Angiography may have a false-negative rate of 20% to 30% because vessels of a size beyond its limit of resolution may be involved (4). In addition, several entities can mimic the appearance of vasculitis on angiography, particularly intracranial atherosclerosis and vasospasm (5, 6). Brain and leptomeningeal biopsy may be diagnostic in only 50% to 72% of PACNS cases because of segmental involvement by the disease and conse-

quent sampling error (4, 7). Furthermore, the risk of serious morbidity from brain biopsy has been estimated at 0.5% to 2% (8). The morbidity associated with biopsy and the limitations, risk, and expense of angiography would make a screening diagnostic examination highly desirable. If such a test were of sufficient sensitivity, regardless of specificity, patients with symptoms and signs suggestive of vasculitis but without the disease could be separated from those needing further evaluation.

The complications of vasculitis consist of ischemia caused by luminal compromise and hemorrhage caused by vessel rupture. Although ischemia and hemorrhage are not specific for vasculitis, in our limited experience, magnetic resonance imaging (MR) has proved sensitive to the presence of these parenchymal effects regardless of the size of vessels involved by the vasculitic process. Also, in a recent report, all seven of a group of patients with PACNS and angiograms positive for vasculitis also had positive MR findings (9). Based on these observations, we hypothesized that patients lacking significant findings on MR are unlikely to manifest changes of vasculitis on angiography and that these patients are unlikely to have intracranial vasculitis.

Received October 19, 1992; revision requested December 18; revision received and accepted March 17, 1993.

From the Department of Radiology, University of Iowa College of Medicine, Iowa City.

Address correspondence to Kurt G. Harris, MD, Assistant Professor, Department of Radiology, University of Iowa College of Medicine, 200 Hawkins Drive, Iowa City, IA 52242-1077.

AJNR 15:317-330, Feb 1994 0195-6108/94/1502-0317

© American Society of Neuroradiology

Materials and Methods

Review of consecutive angiographic records from a 77-month period was undertaken to identify patients who had undergone cerebral angiography to evaluate for intracranial vasculitis. Eighty-three patients were identified who had "exclude vasculitis" as the indication listed on the angiography requisition. The majority (70%) of these 83 were patients referred from the neurology service who had symptoms or signs of cerebral ischemia, and in whom the etiology was not clear. Approximately 20% had only nonspecific neurologic symptoms such as headache or mental changes, and approximately 10% had new-onset seizures. An additional 9 patients who had angiograms for another indication (most commonly to "exclude vascular malformation" in the setting of intraparenchymal hemorrhage) but with angiographic findings of vasculitis or a known clinical diagnosis of vasculitis were also included in the analysis, for a total of 92 patients.

Seventy of 92 patients had MR of the brain in the course of their evaluation. MR was performed on either a 1.5-T or a 0.5-T superconducting magnet. MR included parasagittal T1- and axial T2-weighted spin-echo images in all cases. Images obtained with the 1.5-T machine included axial proton-density (long repetition time, short echo time) spin-echo images as well. In addition, either coronal T2-weighted or pre- and postgadolinium chelate (gadopentetate dimeglumine) T1-weighted images in the axial and coronal planes were obtained for each patient, depending upon the indication.

Angiograms of all patients and MR images of the 70 patients with both studies were retrospectively evaluated independently by two neuroradiologists blinded to the original interpretations, clinical histories (except age), and findings on other imaging studies. Reviewers were asked to categorize each study according to the scheme outlined in Table 1 into normal, incidental, and

abnormal categories. For MR, nonspecific hyperintense foci were within the subcortical or periventricular white matter or the deep gray matter on T2-weighted images. To err on the side of increased sensitivity, and because larger nonspecific hyperintense foci are more likely to represent frank small vessel infarction (10), nonspecific hyperintense foci were considered incidental only if less than 3 mm in size in a patient age 55 years or older. Similarly, mild diffuse brain atrophy was considered incidental in patients over 55 years of age. Any other intracranial abnormality was considered "abnormal." Abnormal findings included, but were not limited to, hyperintense white matter foci 3 mm or larger, parenchymal changes consistent with ischemia or infarction, intracranial hemorrhage, and if paramagnetic contrast was administered, any abnormal vascular, parenchymal, or meningeal enhancement.

For angiography, the classic vasculitis pattern was defined as long segmental or multiple focal areas of significant narrowing in at least two separate vascular distributions (eg, middle, posterior, and anterior cerebral artery) (Figs 1 to 4). Avascular mass, vascular occlusion, aneurysm, or extracranial atherosclerotic occlusions or stenoses greater than 50% in diameter were considered abnormal. Discordance between reviewers or between the original interpretations and the two reviewers was resolved by consensus with a third neuroradiologist.

Clinical records of all 92 patients were reviewed to correlate treatments and outcomes with the imaging studies and to identify patients with a clinical diagnosis (opinion documented in writing by a nonradiologist) of intracranial vasculitis. To make the analysis more meaningful, patients with clinical diagnoses of vasculitis were then further categorized according to a scheme modified from a system of classification described by Fauci et al (3) (Table 2). This scheme was constructed from the viewpoint of a neuroimaging specialist,

TABLE 1: MR-angiography classification

Classification	Angiogram	MR
Normal		
Incidental	<50% stenosis of ICA or one intracranial artery	NHF (less than 3 mm) age >55 Atrophy age >55 Extracranial abnormality
Abnormal	Classic vasculitis Stenosis >50% Avascular mass Thrombosis or occlusion Anything not normal or incidental	Ischemia/infarct Hemorrhage White matter abnormality Abnormal enhancement Anything not normal or incidental

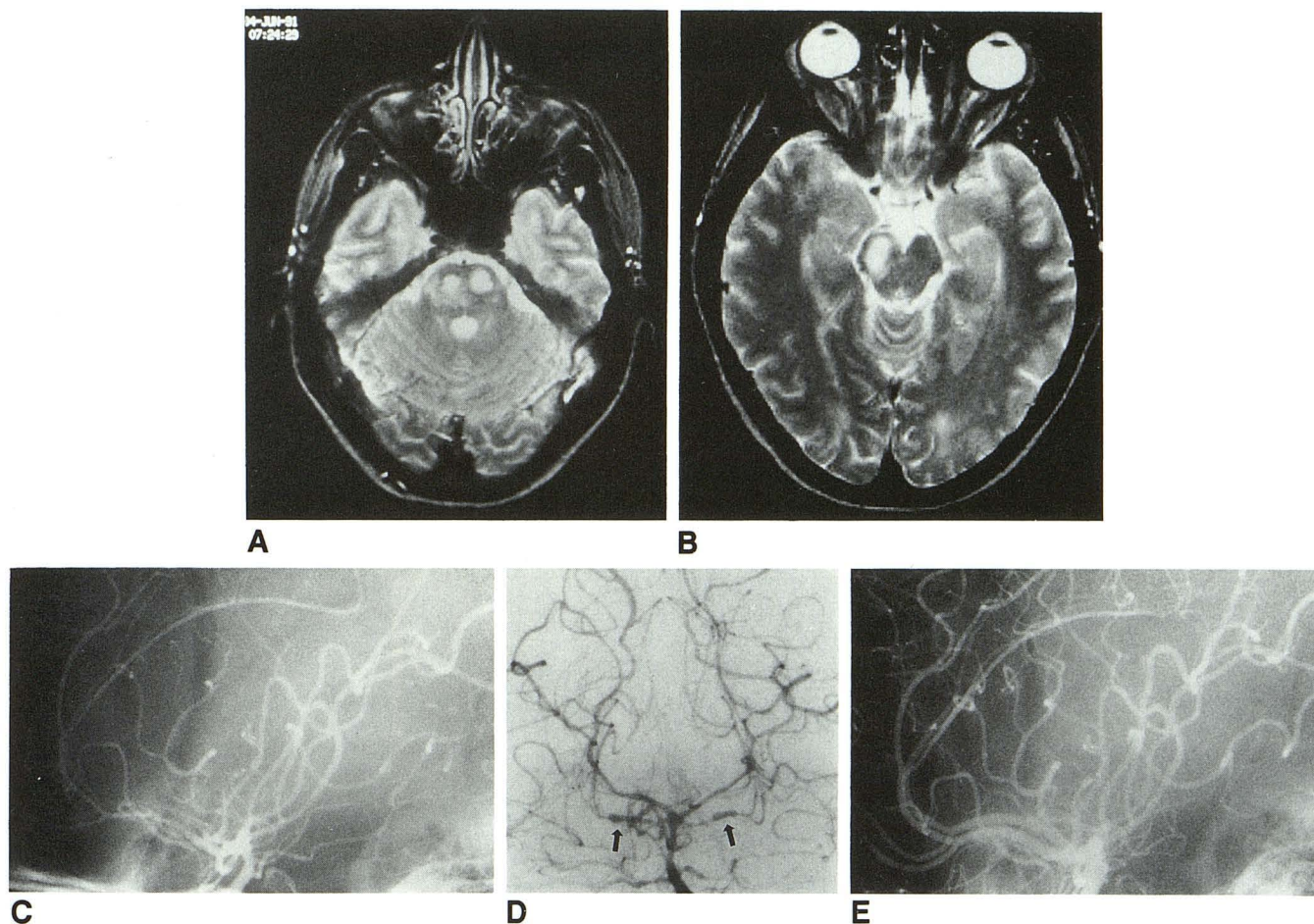


Fig. 1. Patient 3: PACNS. This 28-year-old woman who was several weeks postpartum presented with headache and left hemiparesis. A and B, Axial T2-weighted MR images show hyperintensity within basis pontis, extending into right cerebral peduncle. There was intense enhancement in the pons with intravenous gadopentetate dimeglumine enhancement (not shown).

C, Lateral projection from left carotid arteriogram shows diffuse narrowing of left anterior cerebral artery. Note cross-filling into right anterior cerebral artery, which is also narrowed.

D, Anteroposterior projection from right vertebral arteriogram shows diffuse narrowing of both posterior cerebral arteries and the basilar artery. There is severe segmental narrowing alternating with focal areas of dilation in the superior cerebellar arteries (arrows).

E, Lateral projection from left carotid arteriogram obtained after 1 year of therapy shows resolution of abnormalities.

yet incorporates clinical differences based on pathogenesis and treatment response. The categories are ranked 1 through 4 in descending order of a priori likelihood and significance to neurodiagnosis. PACNS is most likely simply because by definition it is confined to the central nervous system (CNS). Even though systemic angiitis with CNS involvement might be more common pathologically, it should be less common in the neurodiagnostic setting because systemic vasculitides involve other organ systems (category 2). This would tend to obviate the necessity for neuroradiologic evaluation. Similarly, angiitis of the CNS secondary to primary CNS disease (category 4) is less likely than PACNS to occur in the context of "exclude vasculitis" because the primary process (eg, meningitis) is usually of most

concern and is usually manifest apart from any secondary vasculitic involvement. The same is true of category 3, which would include entities described by Fauci et al (3) as hypersensitivity vasculitis (eg, vasculitis associated with collagen vascular disease). An indeterminate vasculopathy category (category 5) was included so that entities that have not been proved to be true inflammatory vasculitis (eg, illicit drug-induced vasculopathy [11]) yet that might warrant angiographic evaluation would not be missed if a negative MR was accepted as evidence of absence of disease.

For the purpose of describing MR and angiographic findings in vasculitis, patients in categories 1 to 4 were considered to have "true" vasculitis. This required a final clinical diagnosis of vasculitis as well as at least one of the follow-

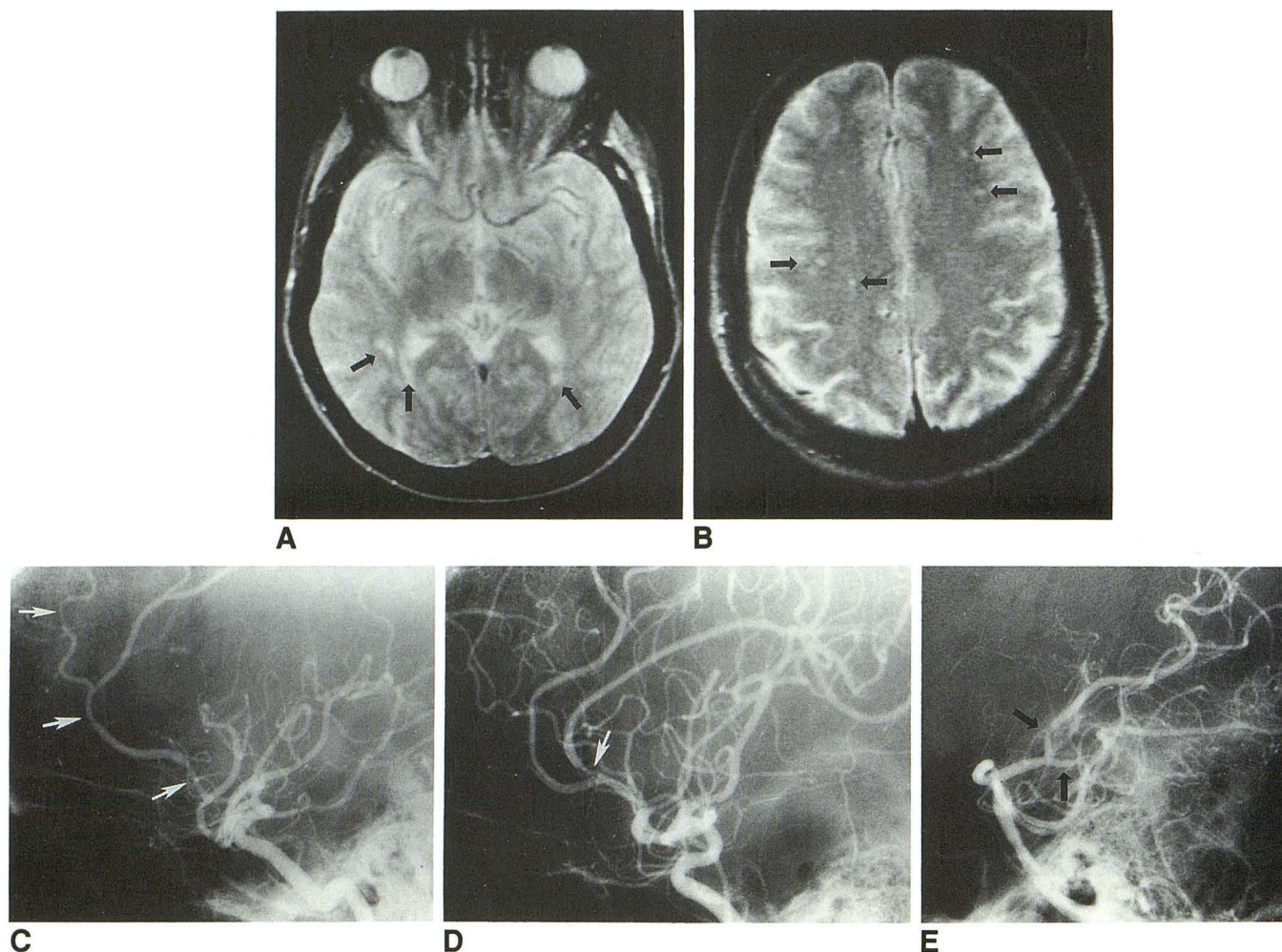


Fig. 2. Patient 1: PACNS. Patient was a 49-year-old man with headache, nausea, and extremity numbness.

A,B, Axial T2-weighted MR images show multiple foci of hyperintensity in the periventricular and deep white matter and at the corticomedullary junction (arrows).

Lateral projections from right and left internal carotid (C, D) and left vertebral (E) arteriograms show multiple focal areas of arterial narrowing (arrows).

ing: 1) pathologic evidence, 2) classic vasculitis pattern on angiogram, or 3) clinical course (such as the progression from headache to encephalopathy to focal neurologic deficits common with PACNS) and response to therapy consistent with vasculitis (1). Patients who were clinically diagnosed as having vasculitis without belonging to categories 1 to 4 or who met none of the three supporting criteria were deemed to have "indeterminate vasculopathy" (category 5).

To test our hypothesis about screening with MR, all 5 categories were used to be as inclusive as possible regarding the definition of intracranial vasculitis. Therefore, our hypothesis was not limited to testing whether a negative MR excludes PACNS but rather any type of intracranial vasculitis, whether confirmed or only putative.

Results

MR-Angiography Correlation

The median interval between MR and angiography was 4 days (range, 0 to 31 days). MR was performed before the angiogram in 84% of cases. In reviewing the MRs, there were minor differences between the two reviewers in total lesions detected and so forth, but there was no discordance between reviewers regarding the major category into which each study result was placed (Table 1). Similarly, there was no discordance between the reviewers and the original MR interpretations.

There were four angiograms in which the reading by both reviewers differed from the original interpretation, but the reviewers were concordant

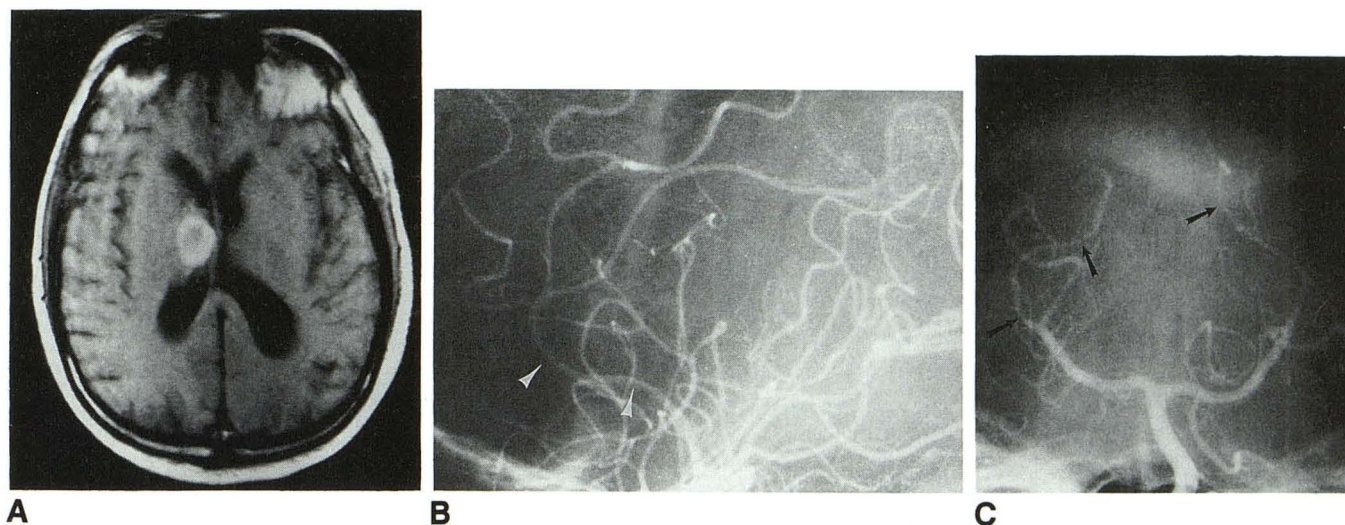


Fig. 3. Patient 8: Systemic vasculitis. This 68-year-old man had headache, myalgia, and gait disturbance. A, Axial T1-weighted MR image shows hyperintense right thalamic hemorrhage. B, Lateral projection from right internal carotid arteriogram shows narrowing of anterior cerebral artery (arrows). C, Anteroposterior projection from left vertebral arteriogram shows narrowing and attenuation of both posterior cerebral arteries (arrows).

with each other. Three patients were originally interpreted as "consistent with vasculitis," but not by the two reviewers. Two of these showed apparent smooth vascular narrowing in a single vessel on a single projection, interpreted as flow artifact by the reviewers. One had occlusive changes in a middle cerebral artery branch.

One patient with CNS lupus and progressive neurologic symptoms had a study originally read as abnormal but the diagnosis of vasculitis was not suggested. Upon review this was believed to show findings of vasculitis. This was the only patient with discordant readings who had a clinical course consistent with vasculitis (see Table 3, patient 10).

Fifty-one patients had abnormal MRs. Nineteen patients had MRs categorized as normal or incidental. Fourteen of these were completely normal. Five were patients placed in the incidental category. These included 2 over age 55 with nonspecific hyperintense foci, 1 with a pineal cyst, 1 with an intradiploic lesion, and 1 with mild diffuse atrophy. None of these 19 patients had abnormal angiograms (Table 4).

Thirty-three of the 70 patients with MR had T1-weighted images after enhancement with paramagnetic contrast. Nine of these 33 had abnormal enhancement. Four of the nine had clinical diagnoses of vasculitis and their findings are summarized in the text below and in Table 3. The remainder consisted of 2 patients with meningeal enhancement who were ultimately diagnosed

with meningitis, 2 patients with parenchymal enhancement consistent with subacute infarction, and 1 with multiple focal areas of enhancement which proved to be brain metastases.

Clinical Outcome: 19 Patients With Normal or Incidental MR

The clinical records of all patients were reviewed. Among the 19 patients with normal or incidental MR, records of clinical follow-up were available ranging from 2 days to 65 months from the date of the MR, with a median interval of 4 months. None of the 19 patients with normal or incidental MR had findings of vasculitis or any significant abnormality on angiography. Eight had no subsequent change in neurologic status and 9 either improved or had resolution of their neurologic symptoms. One patient deteriorated because of AIDS-related lymphoma. Another patient with encephalopathy of indeterminate cause died as a complication of brain and leptomeningeal biopsy to rule out vasculitis (with negative MR, angiogram, biopsy, and autopsy results). None of these patients was ultimately diagnosed with intracranial vasculitis of any type, including the indeterminate vasculopathy category. Table 5 summarizes the ultimate diagnoses, as best as could be determined, for these 19 patients.

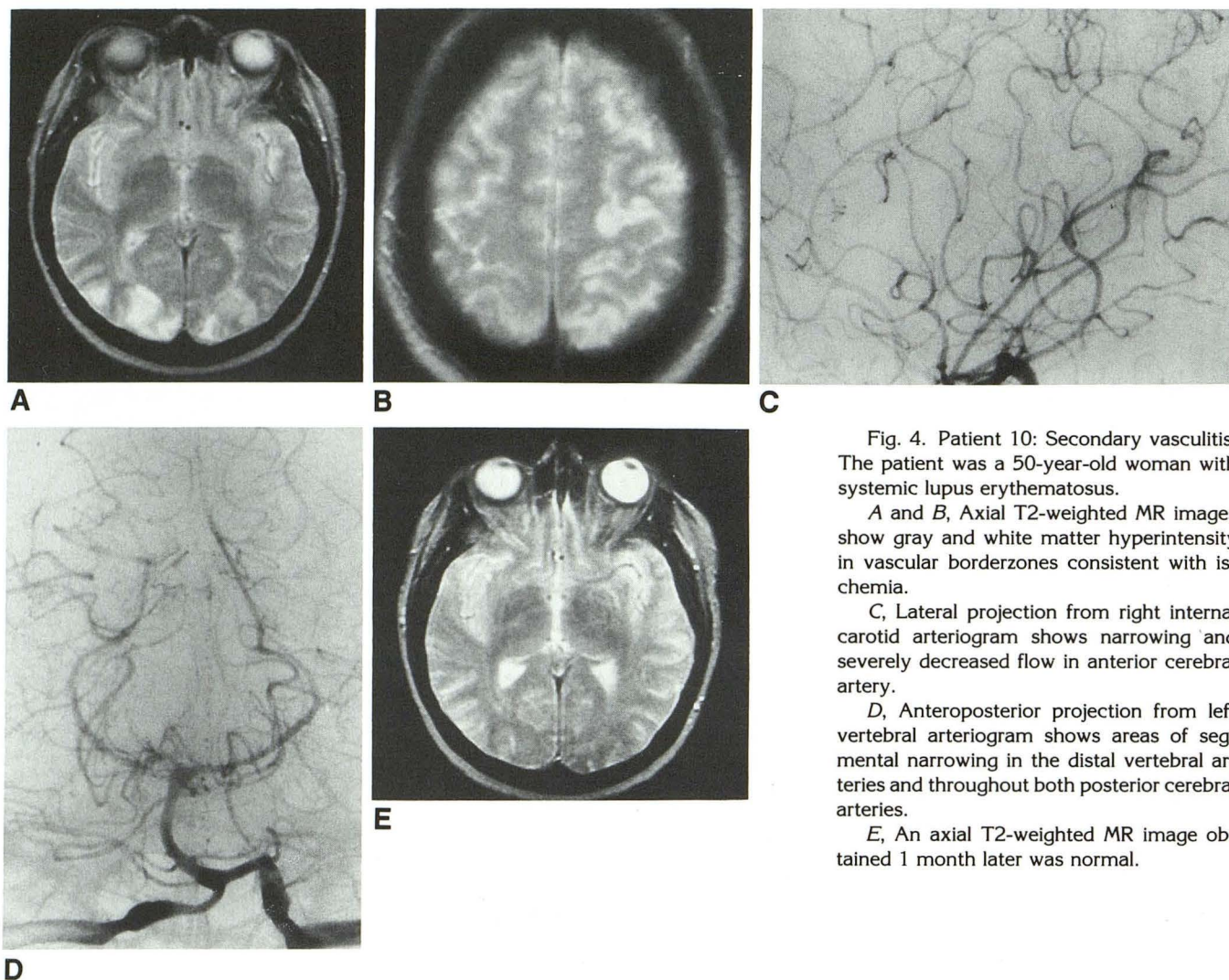


Fig. 4. Patient 10: Secondary vasculitis. The patient was a 50-year-old woman with systemic lupus erythematosus.

A and B, Axial T2-weighted MR images show gray and white matter hyperintensity in vascular borderzones consistent with ischemia.

C, Lateral projection from right internal carotid arteriogram shows narrowing and severely decreased flow in anterior cerebral artery.

D, Anteroposterior projection from left vertebral arteriogram shows areas of segmental narrowing in the distal vertebral arteries and throughout both posterior cerebral arteries.

E, An axial T2-weighted MR image obtained 1 month later was normal.

TABLE 2: Classification of vasculitis

1. PACNS—primary angiitis of the central nervous system (CNS)
2. Primary systemic angiitis with CNS involvement (eg, polyarteritis nodosa, giant cell)
3. Angiitis of CNS secondary to systemic disease (eg, collagen vascular disease)
4. Angiitis of CNS secondary to primary CNS disease (eg, meningitis)
5. Indeterminate vasculopathy

Patients with Vasculitis

Nineteen patients had a clinical diagnosis of some type of vasculitis. Patient information is summarized in Table 3. Eleven patients met the stricter criteria for true vasculitis (categories 1 to 4, Table 2). Five of these 11 had pathologic evidence of vasculitis. There were 7 cases of PACNS and 2 cases of a primary systemic angiitis involving the CNS (one possibly temporal arteritis). There were 2 cases of CNS angiitis secondary

to systemic disease (category 3). One of these was a patient with systemic lupus erythematosus who had an angiographic pattern of vasculitis and whose CNS symptoms improved dramatically with an increase in her steroid dosage (patient 10, Fig 4). The second patient (patient 11) had evidence of connective tissue disease on a skin biopsy and an appearance of classic vasculitis in both carotid distributions. Her symptoms improved dramatically with administration of steroids and cyclophosphamide.

There were no patients with vasculitis secondary to a primary CNS disease (CNS infection, granulomatous disease, etc).

Eight patients had a clinical diagnosis of some type of vasculitis but met none of the three supportive criteria. Three of these were considered "drug-induced" vasculitis. Only one patient in the indeterminate category (patient 19) had a

TABLE 3: Summary of patients with intracranial vasculitis (clinical diagnosis)

Patient	Age, Sex	Clinical Presentation	MR Findings	G	Angiogram Indic	Study	Angiogram Findings	Final Diagnosis	Pathology	Biopsy Site	Treatment	Outcome
I. PACNS												
1	49, M	Headache, vertigo, nausea, vomiting, extremity numbness	CMJ and deep white matter hyperintensity on T2WI	nl	Rule out stenosis	3V	Classic vasculitis bilaterally	PACNS	NA	NA	s,c	Resolved
2	52, F	Headache	Right frontal parenchymal hematoma, leptomeningeal enhancement in right middle cerebral artery territory	ab	Rule out vasc	3V	Classic vasculitis anterior circ. bilaterally. Improved at 6 wk	PACNS	NA	NA	s,c	Improved
3	28, F	Headache, left hemiparesis, postpartum	Large enhancing lesion in pons hyperintense on T2WI	ab	Rule out tumor	3V	Classic vasculitis. Resolved at 1 yr	PACNS	NA	NA	s,c	Improved
4	35, F	Headache, right hemiparesis, expressive aphasia	Left frontal 5 cm parenchymal hemorrhage.	nl	Rule out VM	3V	Classic vasculitis bilaterally. Slight improvement at 3 mo	PACNS	Infarct with glial reaction	Left frontal brain	s,c	Improved
5	50, F	Headache, nausea, vomiting	NA (CT showed infarct with hemorrhagic transformation)	NA	Rule out vasc	3V	Classic vasculitis bilaterally. Resolved at 6 mo	PACNS	Normal	Right frontal brain, meninges	s,c	Improved
6	58, F	Right hemiparesis and myalgia	Parenchymal hemorrhage in left frontal and left temporal regions	nl	Rule out VM	Left internal carotid artery, VA	Mass effect from hemorrhage, no vasculitis	PACNS	Acute lymphocytic vasculitis	Left temporal brain	s,c	IF
7	70, F	Headache, malaise, mental status changes, gait disturbance	Confluent periventricular white matter hyperintensities on T2WI, hypointense on T1WI profound diffuse meningeal enhancement with Gd	ab	Rule out VM, aneurysm	3V	Normal	PACNS	Invasion of meningeal arterioles and venules by histiocytes	Brain, meninges	s,c	Improved
II. Primary systemic vasculitis with CNS involvement												
8	68, M	Headache, mental status change, myalgia, unsteady gait	Right thalamic hemorrhage	nl	Rule out vasc	3V	Classic vasculitis bilaterally	Systemic vasculitis	Necrotizing vasculitis	Left temporal artery	s,c	Resolved

TABLE 3: Continued

Patient	Age, Sex	Clinical Presentation	MR Findings	G	Angiogram Indic	Study	Angiogram Findings	Final Diagnosis	Pathology	Biopsy Site	Treat-ment	Outcome
9	78, M	Headache, diplopia	Focal CMJ and central white matter hyperintensities on T2WI white matter and pons. T1WI normal	nl	Rule out vasc	Bil carotid	Normal	Systemic necrotizing vasculitis	Necrotizing vasculitis	Left gastrocnemius muscle	s,c	Improved
III. Secondary vasculitis												
10	50, F	Headache, arthralgia, fever, and seizure	Cortical and CMJ ischemia in right parietal and both occipital lobes on T2WI; resolved at 1 month	NA	Rule out vasc	3V	Classic vasculitis bilaterally	Systemic lupus erythematosus with CNS lupus	NA	NA	s	Improved
11	58, F	Right hemiparesis, expressive aphasia	NA (CT showed left frontal MCA/ACA borderzone infarct)	NA	Rule out vasc	Bil carotid	Classic vasculitis bilaterally. Slight improvement at 6 mo	Connective tissue disease, not otherwise specified	IgM and C3 deposition	Skin	s,c	Improved
IV. Indeterminate vasculopathy												
12	31, M	Mental status change, seizure, and left homonymous hemianopsia	Acute ischemia in right occipital lobe and old cerebellar infarcts	nl	Rule out vasc	3V	Right parietal capillary blush	Drug-induced vasculitis	NA	NA	s	Same
13	18, F	Headache	NA	NA	Rule out VM	Left carotid	Normal	Left temporal hematoma. Unknown vasculitis	NA	NA	s	Same
14	20, M	Seizure	NA	NA	Rule out vasc	3V	Irregular narrowing in left middle meningeal artery	Drug-induced vasculitis	Clot and reactive changes	Right temporal lobe	NA	Resolved
15	59, F	Headache, vomiting, homonymous hemianopsia	NA	NA	Rule out VM	3V	Smooth narrowing in both pericallosal artery	Vasospasm vs PACNS	Normal	Temporal artery	NA	Improved
16	14, F	Headache, left hemiplegia	Acute ischemia in right basal ganglia	nl	Stroke	3V	? thrombosis in right middle cerebral artery	? localized CNS vasculitis	NA	NA	asa	Improved

TABLE 3: Continued

Patient	Age, Sex	Clinical Presentation	MR Findings	G	Angiogram Indic	Study	Angiogram Findings	Final Diagnosis	Pathology	Biopsy Site	Treat-ment	Outcome
17	31, F	Left-sided numbness	Demyelination pattern	nl	Rule out vasc	3V	Normal	? drug-induced vasculitis	NA	NA	s	Same
18	39, M	Left hemiparesis	Confluent white matter hyperintensity on T2WI	nl	Rule out vasc	3V	Normal	Demyelination vs vasculitis	NA	NA	s	Same
19	64, M	7 month history of left-sided sensory changes, spells, elevated cerebrospinal fluid protein	Subacute right parietal hemorrhagic stroke with parenchymal enhancement. Focal hyperintensities on T2WI in brainstem, periventricular white matter and cerebellum also hypointense on T1WI	ab	Rule out stenosis	3V	Classic vs very severe intracranial atherosclerosis	Vasculitis? (only 9 days followup)	NA	NA	asa	Slight improvement, IF

Note—G indicates additional findings on gadolinium-enhanced images; ab, additional abnormality revealed on enhanced images; nl, no additional abnormality on enhanced images; T2WI, T2-weighted images; T1WI, T1-weighted images; CMJ, corticomedullary junction; Angiogram Indic, stated indication for angiogram; VM, vascular malformation; vasc, vasculitis; Study, number of vessels injected (eg, vertebral, right and left internal carotid artery); MCA, middle cerebral artery; ACA, anterior cerebral artery; V, vessel; VA, vertebral artery; s, steroids; c, cyclophosphamide; asa, aspirin; NA, not applicable or not performed; and IF, inadequate followup.

TABLE 4: MR-angiogram correlation (number of patients)

	Normal or Incidental MR	Abnormal MR
Normal or Incidental Angiogram	19	36
Abnormal Angiogram	0	15

TABLE 5: Clinical diagnoses of 19 patients with normal or incidental MR

Cerebrovascular accident or transitory ischemic attack	5
Seizure disorder	4
Encephalopathy of unclear cause	4
Rheumatoid arthritis, hypothyroidism	1
Systemic lupus erythematosus	1
AIDS-related lymphoma	1
Migraine	1
Lymphocytosis of unclear cause	1
Felty syndrome	1

classic vasculitis pattern angiographically. This patient may well have had PACNS but was lost to follow-up without being treated for vasculitis. In addition, there was some possibility that the angiographic changes represented severe intracranial atherosclerosis, and the clinical diagnosis was equivocal.

True Vasculitis: Angiography

Five of seven patients (71%) with PACNS had classic changes of vasculitis on angiography (Fig. 1 and 2). Both PACNS patients who lacked the classic vasculitis pattern were biopsy proved (Fig 5). Overall, 8 of 11 (72%) true vasculitis patients had classic changes of vasculitis. All but one patient with the classic vasculitis pattern had involvement in at least four vascular distributions (major intracranial vessels or their territories; middle, posterior, or anterior cerebral artery; or superior cerebellar). Of the 8 patients with classic vasculitis, 7 had three vessel angiography performed, with 6 of these showing findings of vasculitis on injection of all three vessels (right and left internal carotid arteries plus left or right vertebral). One patient (patient 2) showed vasculitis in both anterior circulations but none in the posterior circulation on three vessel angiography. One patient with classic vasculitis (patient 11) had both internal carotid arteries injected and had abnormality bilaterally. In all, 22 of the 23 injections performed in patients *with classic vasculitis* showed findings of vasculitis.

True Vasculitis: MR

Nine of the 11 true vasculitis patients had MR performed with abnormality in every case (Table 3). The two patients without MR had brain computed tomography (CT) scans showing significant abnormality (stroke) which could reasonably be presumed detectable with MR had it been obtained (patients 5 and 11). Four had parenchymal hemorrhage (patients 2, 4, 6, and 8) (Fig 3). Three patients (patients 1, 9, and 10) had abnormal hyperintense foci at the corticomedullary junction on T2-weighted images (Fig 2). Three patients (patients 1, 7, and 9) had either focal or confluent hyperintensities on T2-weighted images within the central white matter (Figs 2 and 5). One patient (patient 10) had border zone ischemic changes on T2-weighted images that were documented to have resolved with her clinical improvement 1 month later (Fig 4). One patient (patient 3) had unusual lesions in the basis pontis and cerebral peduncle that were hyperintense on T2-weighted images and enhanced with contrast (Fig 1).

Eight of nine patients who underwent MR had T1-weighted sequences after administration of gadopentetate dimeglumine paramagnetic contrast agent. Three of these eight (patients 2, 7, and 3) had abnormal patterns of enhancement, two of which were leptomeningeal enhancement (Fig 5). There were no cases in which contrast-enhanced sequences revealed abnormality in the face of a normal T2-weighted sequence.

In summary, there was no characteristic pattern of vasculitis on MR. Parenchymal hemorrhage, hyperintense foci in the white matter and at the corticomedullary junction, strokes of various size, leptomeningeal enhancement, brainstem lesions, and cortical ischemic areas all were seen.

Yield of Angiography

Eighty-three of the patients in this study had an angiogram performed to "exclude vasculitis." Five of these angiograms showed findings consistent with vasculitis (classic pattern) and helped establish the diagnosis, for a diagnostic yield of 6%.

Of the 11 patients defined by us as having true vasculitis, 5 of 11 (45%) were suspected before angiography and then diagnosed angiographically. Conversely, 5 of 11 (45%) were not suspected before angiography but rather were discovered incidentally at angiography (3 patients),

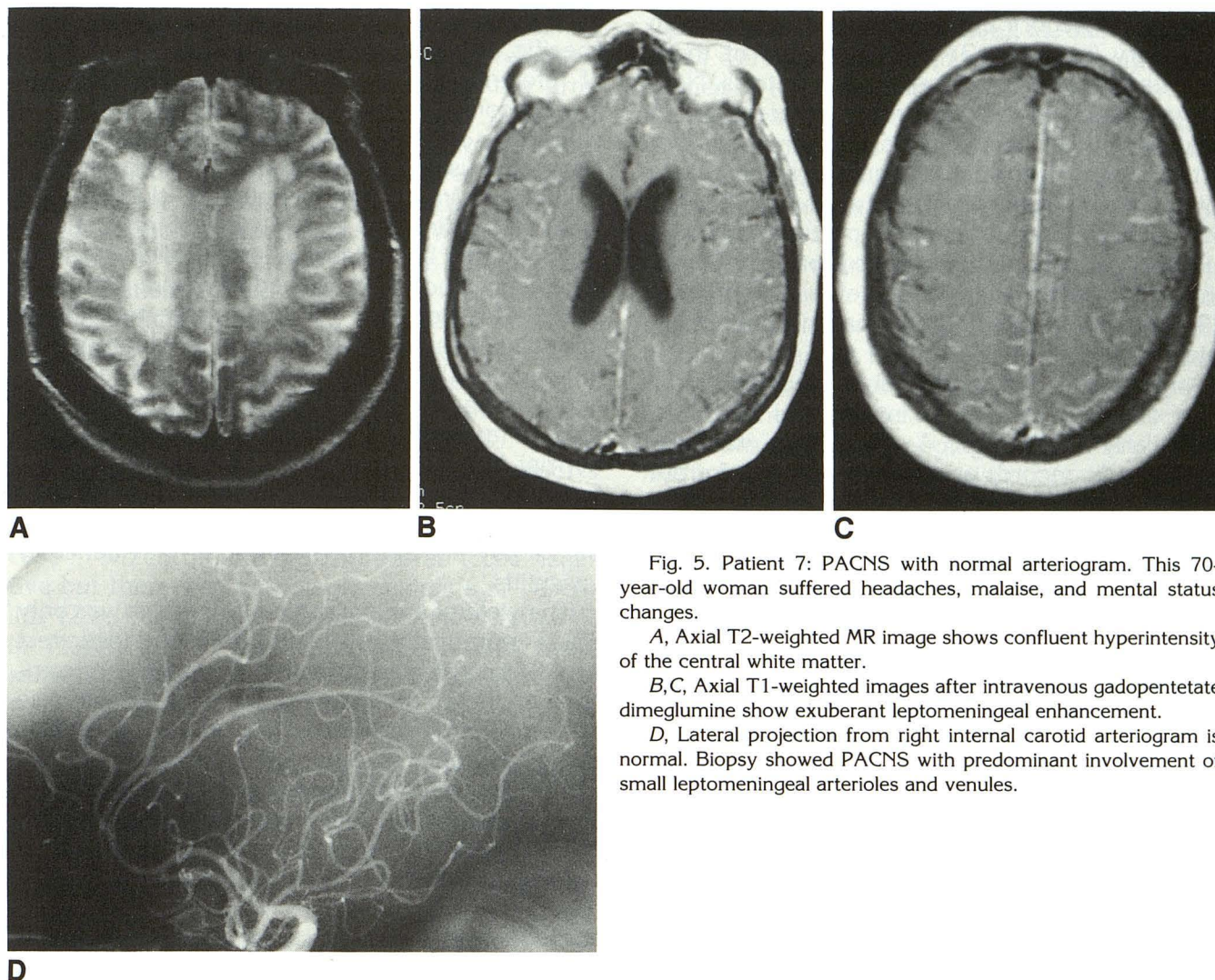


Fig. 5. Patient 7: PACNS with normal arteriogram. This 70-year-old woman suffered headaches, malaise, and mental status changes.

A, Axial T2-weighted MR image shows confluent hyperintensity of the central white matter.

B,C, Axial T1-weighted images after intravenous gadopentetate dimeglumine show exuberant leptomeningeal enhancement.

D, Lateral projection from right internal carotid arteriogram is normal. Biopsy showed PACNS with predominant involvement of small leptomeningeal arterioles and venules.

or were ultimately diagnosed pathologically despite a negative angiographic study (2 patients). One of the 11 (9%) was suspected to have vasculitis before angiography but had a negative angiogram, with the diagnosis supported by pathology. In the subset of PACNS patients, only 2 of 7 were suspected before angiography and then diagnosed angiographically.

Discussion

PACNS has been the subject of numerous case reports and series since its original description as a clinical entity in 1959 by Cravioto and Feigin (12). PACNS is an angiitis isolated to the CNS that tends to affect small to medium sized vessels of the brain parenchyma and meninges but can affect vessels of any size (4). PACNS has also been referred to as isolated or granulomatous

angiitis of the CNS (13–15). Although characteristic, the presence of granulomas is not essential to the diagnosis, but rather probably represents a particular stage of evolution of the disease (13). Although PACNS is the best described form of intracranial vasculitis, many authors stress the number of diverse entities that can cause intracranial vasculitis, in addition to the nonvasculitic entities that can cause a similar angiographic appearance (3–6, 16). The purpose of our study was to provide a description of the expected frequencies of the various causes of intracranial vasculitis from an imaging perspective, and to evaluate the role of imaging modalities in making the diagnosis.

The types of vasculitis we encountered were consistent with the hierarchy of our classification scheme. Most of our patients had PACNS (seven). There were 2 patients each with primary systemic

vasculitis (category 2) affecting the CNS and with secondary (category 3) vasculitis. One of these patients had systemic lupus erythematosus. Neuropsychiatric symptoms are very common in patients with systemic lupus erythematosus but in the majority of such patients symptoms are not caused by true intracranial vasculitis (17, 18). Nevertheless, there are case reports of true vasculitis in patients with systemic lupus erythematosus, rheumatoid arthritis, and even scleroderma (19–21). Not surprisingly, we had no patients in category 4.

Angiography has been considered the initial study of choice to exclude intracranial vasculitis, particularly PACNS (1, 4, 13). Thus, we used angiographic records as the starting point for our review. The number of patients evaluated for vasculitis actually may have been underestimated by our study because the criterion for entry (retrospectively) was an angiographic requisition listing vasculitis as the primary indication or a clinical diagnosis of vasculitis and history of an angiogram. We cannot exclude the possibility that vasculitis was considered but not indicated on the requisition, to say nothing of patients who may have had vasculitis but in whom the diagnosis was not considered. We make no claim to have detected all cases of intracranial vasculitis; indeed, this would be very difficult because autopsy may be the only way to diagnose some cases.

It has been stated that the angiographic vasculitis pattern is often mimicked by intracranial atherosclerosis (5, 6, 22). This may depend upon how strict the definition of an angiographic vasculitis pattern is. In this study there were 3 patients identified by both the original readers and the reviewers as having multiple foci of intracranial atherosclerosis, and none of the 3 had a course consistent with vasculitis. There were no patients with the classic vasculitis pattern that did not have supporting evidence of intracranial vasculitis. However, it should be noted that patient 19 may have had severe intracranial atherosclerosis, and we have encountered several patients over this time frame (not part of this study) who were not being evaluated for intracranial vasculitis yet showed incidental severe intracranial atherosclerosis that would be difficult to distinguish from vasculitis. The specificity of angiography should be enhanced by consideration of the patient's age and clinical presentation and whether there is other evidence of atherosclerosis.

Angiography, although useful and often very specific, should not be thought of as the standard of reference in diagnosis. The sensitivity is too low to conclude that a negative angiogram excludes the disease. Our estimate of angiographic sensitivity using our definition of the classic vasculitis pattern is 70%, a figure in close accord with that estimated in a review of 48 patients with PACNS by Calabrese and Mallek (4). Our experience and the published literature both suggest that a negative MR does more to exclude vasculitis than does a negative angiogram. No patients in this study suffered morbidity from angiograms. However, there was one patient who died as a result of brain biopsy, despite three normal MRs and a negative angiogram. The autopsy showed massive intracranial hemorrhage at the biopsy site as the cause of death. Neither the biopsy nor autopsy showed any evidence of vasculitis.

The yield of angiography in this series was only 6%. Theoretically, low yield with a diagnostic test could be explained by either poor test performance or the effect of low prevalence. In the case of angiography to rule out vasculitis, low yield is not attributable to poor test performance. This can be illustrated by assuming that the sensitivity of angiography is 100%, rather than our estimate of 70%. If this were the case, only one additional patient would have been detected (patient 9) because only 6 of the 11 vasculitis cases were suspected before angiography. It is the low prevalence of intracranial vasculitis that assures a low yield with any diagnostic test and guarantees that the vast majority of angiograms performed in search of vasculitis will not diagnose vasculitis.

Although all 7 of their patients had abnormal MRs, Greenan and colleagues (9) hypothesized that it was possible to have a negative MR in a patient with a positive angiogram. They based this on the fact that MR abnormality was not evident in every vascular distribution showing angiographic involvement. Theirs is an interesting observation and we do not take issue with it as a theoretical possibility. However, we think it is more relevant to consider MR or angiographic findings for the whole brain as either negative or positive when comparing test results. All 9 of our patients with true vasculitis who had both MR and angiography had a significantly abnormal MR, even the 3 without the classic vasculitis pattern. In addition, the 2 patients without MR had evidence of acute stroke on CT. This relationship between abnormal MR findings and ulti-

mate diagnoses of vasculitis held despite intervals of up to 1 month between MR and evaluation with angiography, which was usually the time that there was first documentation of a clinical suspicion of vasculitis. Intuitively, it would seem that the more recently an MR has been obtained, the better it should predict whether there is enough organ disturbance to warrant further consideration of vasculitis. We think it is very unlikely that a patient would manifest symptoms and signs significant enough to bring the patient to evaluation yet lack any parenchymal findings of vascular compromise on MR. There are many reports in the literature of patients with intracranial vasculitis (PACNS) with negative CT of the brain (4, 13, 14). However, among the few reports in the literature in which MR findings were described, we were able to identify only a single case in which the MR was purported to be negative but there was pathologic evidence of vasculitis (23). In this case the patient underwent MR in March 1985. The field strength and pulse sequences were not described in this report, nor were the images reproduced. In addition, the angiogram was negative and the description of the MR is suspect in that a head CT was reported to have shown "generalized brain swelling" only 2 days earlier. At the very least, it is fair to assume that the advantage of MR over CT in tissue contrast is significantly higher today than it was in 1985.

Although there were no cases in which contrast enhancement demonstrated the sole abnormality, the finding of leptomeningeal enhancement in two patients as well as the known predilection of PACNS for leptomeningeal vessels (16) suggest that paramagnetic contrast-enhanced images might be useful if vasculitis is suspected.

In summary, MR appears to be very sensitive and would have served as a useful screen in our series to exclude patients from further evaluation with angiography or biopsy (Table 4). Nineteen of the 70 patients who had both MR and angiography had normal or incidental MRs. None of these 19 was among the 11 patients with true vasculitis or among the 8 with indeterminate vasculopathy. The low yield of angiography performed to exclude vasculitis (6%) further supports the rationale for using MR as a screening tool, especially because MR has usually been obtained somewhere in the diagnostic workup, and consideration of the findings on a test already performed makes a particularly cost-effective screen. Both imaging specialists and clinicians

should note that most (55%) of our vasculitis cases were not diagnosed on an angiogram performed to exclude vasculitis but were discovered on angiograms performed for other indications or were diagnosed only at biopsy. This proportion was even higher for cases of PACNS (5 of 7), which is usually what the radiologist is asked to exclude.

We believe that the evaluation of patients with suspected intracranial vasculitis should include initial evaluation with MR. If high-quality MR can be obtained and is normal or shows only incidental findings, we believe that this does more to exclude the possibility of intracranial vasculitis than does a negative angiogram, and makes the likelihood of an ultimate diagnosis of vasculitis negligible. If the MR is abnormal and the cause is still unclear, one can proceed to angiography. If angiography is then normal or equivocal, this does not exclude vasculitis, and brain and leptomeningeal biopsy may be required.

Acknowledgments

We gratefully acknowledge the advice and criticism offered by Jon Lemke, PhD, and Paul Chang, MD.

References

1. Kissel JT. Neurologic manifestations of vasculitis. *Neurol Clin* 1989;7:655-673
2. Savage COS, Ng YC. The aetiology and pathogenesis of major systemic vasculitides. *Postgrad Med J* 1986;62:627
3. Fauci AS, Haynes BF, Katz P. The spectrum of vasculitis: clinical, pathologic, immunologic, and therapeutic considerations. *Ann Intern Med* 1978;89:660-676
4. Calabrese LH, Mallek JA. Primary angitis of the central nervous system: report of 8 new cases, review of the literature and proposal for diagnostic criteria. *Medicine* 1987;67:20-39
5. Ferris EJ, Levine HL. Cerebral arteritis: classification. *Radiology* 1973;109:327-341
6. Osborn AG. *Introduction to cerebral angiography*. Philadelphia: Harper and Row, 1980:286
7. Stubgen P, Lotz BP. Isolated angitis of the central nervous system: involvement of penetrating vessels at the base of the brain. *J Neurol* 1991;238:235-238
8. Barza M, Pauker S. The decision to biopsy, treat or wait in suspected herpes encephalitis. *Ann Intern Med* 1980;92:641-649
9. Greenan TJ, Grossman RI, Goldberg HI. Cerebral vasculitis: MR imaging and angiographic correlation. *Radiology* 1992;182:65-72
10. Braffman BH, Zimmerman RA, Trojanowski JQ, Gonatas NK, Hickey WF, Schlaepfer WW. Brain MR: pathologic correlation with gross and histopathology. 1. Lacunar infarction and Virchow-Robin spaces. *AJNR Am J Neuroradiol* 1988;9:621-628
11. Landi JL, Spickler EM. Imaging of intracranial hemorrhage associated with drug abuse. In *Neuroimaging Clin North Am* 1992;2:187-194
12. Cravioto H, Feigin I. Noninfectious granulomatous arteritis with a predilection for the nervous system. *Neurology* 1959;9:599-609
13. Cupps TR, Moore PM, Fauci AS. Isolated angitis of the central

- nervous system: Prospective diagnostic and therapeutic experience. *Am J Med* 1983;74:97-105
14. Moore PM. Diagnosis and management of isolated angiitis of the central nervous system. *Neurology* 1989;39:167-173
 15. Younger DS, Hays AP, Brust JC, Rowland LP. Granulomatous angiitis of the brain: an inflammatory reaction of diverse etiology. *Arch Neurol* 1988;45:514-518
 16. Moore PM, Cupps TR. Neurological complications of vasculitis. *Ann Neurol* 1983;14:155-167
 17. Devinsky O, Petito CK, Alonso DR. Clinical and neuropathologic findings in systemic lupus erythematosus: the role of vasculitis, heart emboli, and thrombotic thrombocytopenic purpura. *Ann Neurol* 1988;23:380-384
 18. Ellis SG, Verity MA. Central nervous system involvement in systemic lupus erythematosus: a review of neuropathologic findings in 57 cases, 1955-1977. *Semin Arthritis Rheumatism* 1979;8:212-221
 19. Weiner DK, Allen NB. Large vessel vasculitis of the central nervous system in systemic lupus erythematosus: report and review of the literature. *J Rheumatology* 1991;18:748-751
 20. Sigal LH. The neurologic presentation of vasculitic and rheumatologic syndromes. *Medicine* 1987;66:157-180
 21. Estey E, Lieberman A, Pinto R, Meltzer M, Ransohoff J. Cerebral arteritis in scleroderma. *Stroke* 1979;10:595-597
 22. Donnan GA, Baker HL, Siekert RG. Arteriographically diagnosed cerebral arteritis: clinical spectrum and outcome (abstr). *Ann Neurol* 1982;12:83-84
 23. Vanderzant C, Bromberg M, MacGuire A, McCune WJ. Isolated small vessel angiitis of the central nervous system. *Arch Neurol* 1988;45:683-687