

Generic Contrast Agents

Our portfolio is growing to serve you better. Now you have a *choice*.



[VIEW CATALOG](#)

AJNR

Transient severe brain stem depression during intraarterial papaverine infusion for cerebral vasospasm.

J D Barr, J M Mathis and J A Horton

AJNR Am J Neuroradiol 1994, 15 (4) 719-723

<http://www.ajnr.org/content/15/4/719>

This information is current as
of May 29, 2025.

Transient Severe Brain Stem Depression during Intraarterial Papaverine Infusion for Cerebral Vasospasm

John D. Barr, John M. Mathis, and Joseph A. Horton

Summary: A 63-year-old woman had severe, symptomatic cerebral vasospasm secondary to subarachnoid hemorrhage. We initiated simultaneous infusions of papaverine into her left vertebral and left internal carotid arteries. Twenty-five minutes after the infusions had begun, the patient had a transient reaction of respiratory arrest followed by rapid, progressive loss of brain stem function.

Index terms: Vasospasm; Drugs, reaction; Interventional neuroradiology, complications of; Iatrogenic disease or disorder

Symptomatic cerebral vasospasm after subarachnoid hemorrhage may be refractory to conventional therapy. Intraarterial papaverine infusion has been used rarely to treat cerebral vasospasm. While infusing papaverine into the anterior cerebral and vertebral arteries, we observed a reaction of severe transient brain stem depression with respiratory arrest.

Case Report

A 63-year-old woman presented to another institution with headache, nausea, and emesis. Subarachnoid hemorrhage from an anterior communicating artery aneurysm was diagnosed. The patient was neurologically intact when transferred to our institution on day 8 and rebled on day 9. Surgery was performed on day 10. It was not possible to clip the aneurysm because it had a very broad base, but a clip was placed across the left side of the anterior communicating artery to occlude the dominant arterial inflow.

The next day (postoperative day 1) the patient was lethargic with minimal response to verbal commands. She had no right lower extremity movement. A xenon computed tomographic cerebral blood flow examination showed regional cerebral blood flow to be less than 15 mL/100 g per minute in the right frontal and both occipital lobes. The left frontal lobe could not be evaluated because of motion artifact. Middle cerebral artery distribution flows were approximately 25 mL/100g per minute bilaterally. Bilateral internal carotid and left vertebral artery arterio-

grams were performed. The right internal carotid artery injection revealed a 5-mm-diameter aneurysm remnant and minimal anterior cerebral artery distribution vasospasm (Fig 1A). The left internal carotid artery injection showed severe anterior cerebral artery and minimal middle cerebral artery distribution vasospasm (Fig 1B). The left vertebral artery injection showed moderate vertebrobasilar vasospasm (Fig 1C).

Because the right lower extremity paresis was the main clinical concern, we were asked to restrict infusion of papaverine to the left internal carotid artery. We placed a Tracker 18 catheter (Target Therapeutics, Fremont, Calif) just distal to the posterior communicating artery origin and infused papaverine (300 mg in 100 mL normal saline) at 3 mL/min. An immediate follow-up arteriogram showed decreased, but still severe, anterior cerebral artery vasospasm (Fig 1D). A repeat xenon computed tomographic cerebral blood flow study was again difficult to interpret because of patient motion, but there were no definite changes. The patient's neurologic status remained unchanged.

On the next day (postoperative day 2), the patient was more lethargic, responding only to pain. She had minimal spontaneous movement and was ventilator dependent but spontaneously initiated respiration. Bilateral internal carotid artery and left vertebral artery arteriograms were repeated. The right internal carotid artery injection showed no change. The left internal carotid artery injection showed recurrent anterior cerebral artery vasospasm almost as severe as the prepapaverine arteriogram from the previous day (Fig 1E). The left vertebral artery injection showed slightly decreased vertebrobasilar vasospasm with more reflux into the right vertebral artery (Fig 1F).

This time, we planned to infuse papaverine into both the left internal carotid artery and the vertebrobasilar system. We placed a second 5-F sheath into the other common femoral artery and a 5-F base catheter within the left internal carotid artery. We then positioned a Tracker 18 catheter into the proximal left A-1 segment, attempting to improve selective perfusion of the anterior cerebral artery distribution. We placed a second Tracker 18 catheter into the left vertebral artery at the C-2 level, with the base catheter positioned within the subclavian artery. The left vertebral artery origin was tortuous, and infusion through

Received December 22, 1992; accepted pending revision March 21, 1993; revision received May 25.

From the Department of Radiology, University of Pittsburgh.

Address reprint requests to John D. Barr, MD, Departments of Radiology and Surgery, Penn State University, Hershey, PA 17033.

AJNR 15:719-723, Apr 1994 0195-6108/94/1504-0719 © American Society of Neuroradiology

the base catheter itself was not feasible. The spaces between the base and microcatheters were perfused with heparinized saline (6000 U/L). Systemic heparinization was not used. We began to infuse papaverine (300 mg in 100 mL normal saline) into the left vertebral artery. We started the left A-1 infusion (150 mg in 50 mL normal saline) approximately 5 minutes later, with both infusions at 3 mL/min.

Approximately 25 minutes after the left vertebral artery infusion had begun, the patient's oxygen saturation fell rapidly. We found that the patient had stopped initiating

respiration and that she had no spontaneous movement. The mean systemic blood pressure fell approximately 20 to 30 mm Hg during this time. The patient had rapid, progressive loss of brain stem function during the next 10 minutes, with fixed, dilated pupils, absent corneal reflexes, and no doll's-eye response. The left vertebral artery infusion was stopped (245 mg papaverine had been infused), and both Tracker catheters were withdrawn. The left A-1 infusion had been completed just before her event.

After the patient was stabilized, we obtained left internal carotid artery and left vertebral artery arteriograms, which

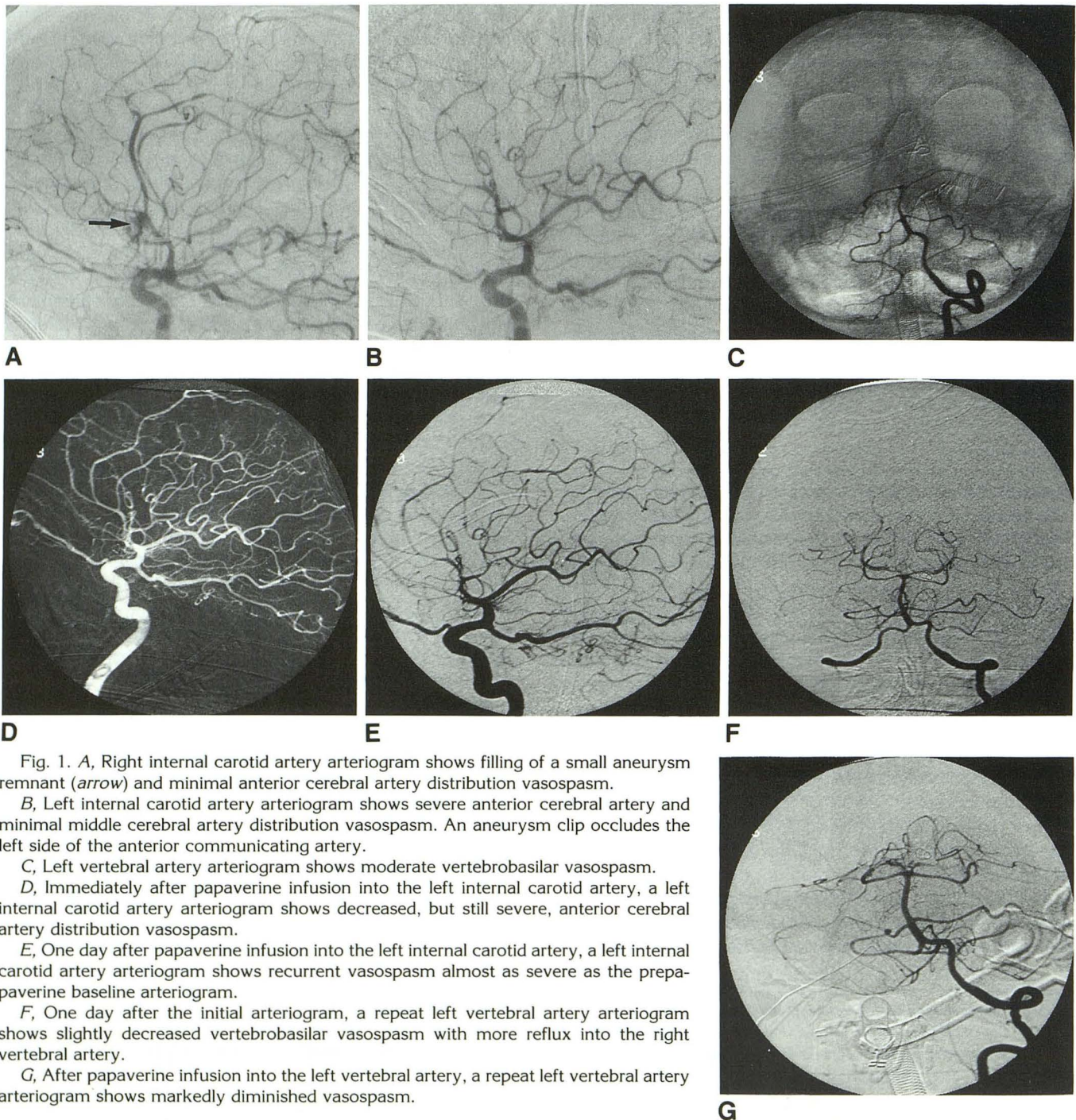


Fig. 1. A, Right internal carotid artery arteriogram shows filling of a small aneurysm remnant (arrow) and minimal anterior cerebral artery distribution vasospasm.

B, Left internal carotid artery arteriogram shows severe anterior cerebral artery and minimal middle cerebral artery distribution vasospasm. An aneurysm clip occludes the left side of the anterior communicating artery.

C, Left vertebral artery arteriogram shows moderate vertebrobasilar vasospasm.

D, Immediately after papaverine infusion into the left internal carotid artery, a left internal carotid artery arteriogram shows decreased, but still severe, anterior cerebral artery distribution vasospasm.

E, One day after papaverine infusion into the left internal carotid artery, a left internal carotid artery arteriogram shows recurrent vasospasm almost as severe as the prepapaverine baseline arteriogram.

F, One day after the initial arteriogram, a repeat left vertebral artery arteriogram shows slightly decreased vertebrobasilar vasospasm with more reflux into the right vertebral artery.

G, After papaverine infusion into the left vertebral artery, a repeat left vertebral artery arteriogram shows markedly diminished vasospasm.

showed markedly decreased vertebrobasilar vasospasm (Fig 1G). The left anterior cerebral artery was unchanged. A computed tomographic scan showed no evidence of hemorrhage or other significant change. The patient's neurologic status returned to her preinfusion baseline within 3 hours. She was discharged on postoperative day 26 with intermittent eye opening to verbal or painful stimuli and moving all four extremities on painful stimulation. Her corneal and gag reflexes were intact. She was no longer ventilator dependent.

Discussion

Vasospasm remains a significant cause of morbidity and mortality after subarachnoid hemorrhage. Although angiographic vasospasm is seen in 40% to 70% of patients, only 20% to 30% have neurologic deficits; approximately 14% of patients develop permanent or fatal deficits (1). Prophylaxis with nimodipine (2) and treatment with hypertensive hypervolemic therapy (3) have improved the outcome of patients with subarachnoid hemorrhage but have not completely eliminated the effects of vasospasm. Balloon angioplasty has proved effective in some cases (4–7), but it is not without risk (8, 9) and has limited availability because of the required expertise. It is also not possible to treat the distal arteries with angioplasty.

Although the mechanism of vasospasm remains poorly understood, there does seem to be an early period during which pharmacologic reversal is possible (10–14). Pharmacologic reversal of vasospasm has been described in humans, in animals, and in vitro (10–13, 15–17). The use of oral papaverine has been described for treatment of chronic cerebrovascular ischemia (18), and the effects of oral and intravenous papaverine on cerebral blood flow in healthy persons have been reported (19). Intraarterial papaverine has shown some promise as a potential treatment for vasospasm (16, 20–22).

Two complications were described during intraarterial papaverine infusion for treatment of cerebral vasospasm in 12 patients (20). In one patient, transient hemiparesis occurred during the infusion. The transient hemiparesis was temporally related to distal migration of the microcatheter into a middle cerebral artery branch and may not have been related to the papaverine itself (conversation with C. D. Phillips, October 1992). Ipsilateral pupil dilatation was noted in a second patient during infusion of the supraclinoid internal carotid artery; this resolved within 15 minutes after the infusion was stopped. No complication

was reported from use of papaverine to free a microcatheter lodged in the pericallosal artery because of iatrogenic vasospasm (16). In a series of 10 patients treated with superselective intraarterial papaverine infusion, no serious side effects were observed (21).

The mechanism of transient brain stem depression in our patient is unknown. Possible causes include an effect of the papaverine itself or brain stem ischemia caused by catheter-induced vasospasm, mechanical flow restriction, or emboli. Our patient had been premedicated with topical nitropaste, which reliably prevents catheter-induced vasospasm (23); angiography revealed only intracranial vasospasm attributed to subarachnoid hemorrhage. Only the Tracker 18 microcatheter was placed into the left vertebral artery because of its tortuous origin; this should not have produced any significant flow reduction, because the extracranial vertebral artery was much larger than the microcatheter. There was no evidence of an embolus on the follow-up arteriograms obtained approximately 30 minutes after the onset of neurologic changes. We cannot exclude the possibility that an embolus occurred during the infusion and resolved before the arteriogram, but the patient's clinical course was not consistent with this. Given the angiographic and clinical findings, we may reasonably exclude all but two causes: transient occlusion of angiographically invisible perforators by microemboli, and an effect of the papaverine itself.

Microemboli could have formed from precipitation of the papaverine solution or interaction with the patient's blood. Precipitation is observed when papaverine is mixed with heparinized saline (6000 U/L) but is not visually apparent when nonheparinized saline is used. The papaverine solution infused into this patient was prepared with nonheparinized saline. Microscopic examination of an identically prepared solution revealed no evidence of precipitation. In vitro evaluation of blood mixed with the papaverine solution was not feasible because clotting could not be prevented. Although we cannot entirely exclude in vivo embolus formation, the small amount of heparinized saline perfusing the spaces between the base and microcatheters should not have caused such precipitation, particularly because one base catheter was in the subclavian artery quite proximal to the tip of the microcatheter in the vertebral artery.

A direct effect of the papaverine itself may have produced the observed neurologic changes.

Central nervous system depression is described with "very large" doses of papaverine, but the dose and mechanism are not documented (24). Unlike the observed loss of ventilatory drive, respiratory stimulation has been reported, but the mechanism is unknown (24). There is a case report of transient coma after intramuscular injection of papaverine; 2 hours after injection of 80 mg of papaverine, the patient lapsed into a coma which resolved 3 hours later (25). Transient respiratory arrest during vertebral artery infusion of papaverine proximal to posterior inferior cerebellar artery has occurred in another patient, but we were unable to obtain a detailed description of this procedure. One patient in the previously described series did have vertebral artery infusion proximal to posterior inferior cerebellar artery without apparent complication (18).

We found no description of the dose-response characteristics of papaverine infused into the cerebral arteries, but we may reasonably assume that a lower dose of papaverine would be required to produce central nervous system depression when infused directly into the cerebral vasculature than when administered systemically. In addition, this patient's baseline status was lethargy and her arterial supply impaired by vasospasm; both factors might further lower the threshold dose to produce central nervous system depression. We have not infused two arteries simultaneously before or after this procedure, and this technique has not, to our knowledge, been used by anyone else. This technique increased the rate of systemic papaverine infusion but did not change the total dose administered and had minimal effect on the local concentration of papaverine within the perfused territories.

When infused intraarterially, the local dose of papaverine seems to be more important than the total systemic dose. We have treated patients with doses up to 450 mg and have observed significant blood pressure changes in only one patient, suggesting the blood pressure changes in this patient were secondary to brain stem depression rather than systemic vasodilatation. Large oral doses of papaverine (600 mg) given to healthy volunteers produced no central nervous system depression (19). Papaverine has hepatic metabolism with a half-life of 0.5 to 2.0 hours (26, 27). A prolonged half-life has been reported after cardiopulmonary bypass, apparently secondary to decreased hepatic perfusion (28).

We have subsequently observed mild, transient sedation in a 77-year-old woman during infusion

of papaverine into the right internal carotid artery. We infused 300 mg of papaverine into the right internal carotid artery over 30 minutes. Approximately 10 minutes after beginning the infusion, her level of consciousness decreased slightly and then returned to baseline within 10 minutes after the infusion had been completed. Because a follow-up angiogram showed only partial relief of vasospasm, we elected to infuse an additional 150 mg of papaverine over 15 minutes. We again noted transient sedation, which resolved shortly after the infusion was completed. No significant blood pressure changes were observed during the procedure. The findings in this patient support direct central nervous system depression caused by the papaverine. The significantly shorter duration of sedation in this patient may represent differences in regional blood flow or sensitivity of different central nervous system structures.

Intraarterial papaverine infusion, particularly in the posterior circulation, should be performed with caution and careful patient monitoring. Placement of the infusion catheter beyond the posterior inferior cerebellar artery origin may be beneficial. If the patient is not already intubated, appropriate personnel and equipment should be on hand, should the need arise. Intermittent contrast injection to demonstrate relief of vasospasm may be useful to keep the dose of papaverine to the minimum required. Although these reactions are alarming, they are outweighed by the benefits of relieving vasospasm.

References

1. Kassell NF, Sasaki T, Colohan ART, Nazar G. Cerebral vasospasm following aneurysmal subarachnoid hemorrhage. *Stroke* 1985; 16:562-572
2. Petruk KC, West M, Mohr G, et al. Nimodipine treatment in poor grade aneurysm patients. *J Neurosurg* 1988;68:505-517
3. Awad IA, Carter P, Spetzler RF, Medina M, Williams FW. Clinical vasospasm after subarachnoid hemorrhage: response to hypervolemic hemodilution and arterial hypertension. *Stroke* 1987;18:365-372
4. Dion JE, Duckwiler GR, Vinuela F, Martin N, Bentson J. Pre-operative micro-angioplasty of refractory vasospasm secondary to subarachnoid hemorrhage. *Neuroradiology* 1990;32:232-236
5. Higashida RT, Halback VV, Dormandy B, Bell J, Brant-Zawadzki M, Hieshima G. New microballoon device for transluminal angioplasty of intracranial arterial vasospasm. *AJNR Am J Neuroradiol* 1990;11:233-238
6. Brothens MF, Holgate RC. Intracranial angioplasty for treatment of vasospasm after subarachnoid hemorrhage: technique and modification to improve branch access. *AJNR Am J Neuroradiol* 1990;11:239-247
7. Newell DS, Eskridge JM, Mayberg MR, Grady MS, Winn RH. Angioplasty for the treatment of symptomatic vasospasm following subarachnoid hemorrhage. *J Neurosurg* 1989;71:654-660

8. Linskey ME, Horton JA, Rao GR, Yonas H. Fatal rupture of the intracranial carotid artery during transluminal angioplasty for vasospasm induced by subarachnoid hemorrhage. *J Neurosurg* 1991;74:985-990
9. Higashida RT, Halbach VV, Cahan LD, et al. Transluminal angioplasty for treatment of intracranial arterial vasospasm. *J Neurosurg* 1989;71:648-653
10. Nakagomi T, Kassell NR, Hongo K, Sasaki T. Pharmacological reversibility of experimental cerebral vasospasm. *Neurosurgery* 1990;27:582-586
11. Varsos VG, Theodore LM, Hee Han D, et al. Delayed cerebral vasospasm is not reversible by aminophylline, nifedipine, or papaverine in a "two-hemorrhage" canine model. *J Neurosurg* 1983;58:11-17
12. Hagai H, Noda S, Mabe H. Experimental cerebral vasospasm. Part 2: effects of vasoactive drugs and sympathectomy on early and late spasm. *J Neurosurg* 1975;420-428
13. Ogata M, Marshall BM, Loughheed WM. Observations on the effects of intrathecal papaverine in experimental vasospasm. *J Neurosurg* 1973;38:20-25
14. Fujiwara S, Kassell NF, Sasaki T, Nakagomi T, Lehman RM. Selective hemoglobin inhibition of endothelium-dependent vasodilation of rabbit basilar artery. *J Neurosurg* 1986;64:445-452
15. Vorkapic P, Bevan JA, Bevan RD. Longitudinal in vivo and in vitro time-course study of chronic cerebrovasospasm in the rabbit basilar artery. *Neurosurg Rev* 1991;14:215-219
16. Eckard DA, Purdy PD, Girson MS, Samson D, Kopitnik T, Hunt B. Intraarterial papaverine for relief of catheter induced intracranial vasospasm. *AJR Am J Roentgenol* 1992;158:883-884
17. Vorkapic P, Bevan RD, Bevan JA. Pharmacologic irreversible narrowing in chronic cerebrovasospasm in rabbits is associated with functional damage. *Stroke* 1990;21:1478-1484
18. Shaw TG, Meyer JS. Double-blind trial of oral papaverine in chronic cerebrovascular ischemia. *Angiology* 1978;29:839-851
19. McHenry LC, Stump DA, Howard G, Novack TT, Bivins DH, Nelson AO. Comparison of the effects of intravenous papaverine hydrochloride and oral pavabid HP capsules on regional cerebral blood flow in normal individuals. *J Cereb Blood Flow Metab* 1983;3:442-447
20. Kassell NF, Helm G, Simmons N, Phillips CD, Cail WS. Treatment of cerebral vasospasm with intra-arterial papaverine. *J Neurosurg* 1992;77:848-852
21. Kaku Y, Yonekawa Y, Tsukahara T, Kazekawa K. Superselective intra-arterial infusion of papaverine for the treatment of cerebral vasospasm after subarachnoid hemorrhage. *J Neurosurg* 1992;77:842-847
22. Livingston K, Hopkins LN. Intra-arterial papaverine as an adjunct to transluminal angioplasty for vasospasm induced by subarachnoid hemorrhage. *AJNR Am J Neuroradiol* 1993;14:346-347
23. Erba M, Jungreis CA, Horton JA. Nitro paste for prevention and relief of vascular spasm. *AJNR Am J Neuroradiol* 1989;10:155-156
24. *Physician's desk reference*. 46th ed. Montvale: Medical Economics Data, 1992:1290-1291
25. Ilan Y, Gerner O. Papaverine-induced coma. *Eur J Clin Pharmacol* 1988;33:651
26. Arnold JD, Baldrige J, Riley B, et al. Papaverine hydrochloride: the evaluation of two new dosage forms. *Int J Clin Pharmacol Biopharmacol* 1977;15:230-233
27. Koch-Weser J, Cook P, James I. Cerebral vasodilators. *N Engl J Med* 1981;305:1508-1513
28. Kramer WG, Romagnoli A. Papaverine disposition in cardiac surgery patients and the effect of pulmonary bypass. *Eur J Clin Pharmacol* 1984;27:127-130