

# Generic Contrast Agents

Our portfolio is growing to serve you better. Now you have a *choice*.



FRESENIUS  
KABI

[VIEW CATALOG](#)

# AJNR

This information is current as  
of May 25, 2025.

**[15O]H<sub>2</sub>O positron emission tomography  
determination of cerebral blood flow during  
balloon test occlusion of the internal carotid  
artery.**

J A Brunberg, K A Frey, J A Horton, J P Deveikis, D A Ross and  
R A Koeppel

*AJNR Am J Neuroradiol* 1994, 15 (4) 725-732  
<http://www.ajnr.org/content/15/4/725>

# **[<sup>15</sup>O]H<sub>2</sub>O Positron Emission Tomography Determination of Cerebral Blood Flow during Balloon Test Occlusion of the Internal Carotid Artery**

James A. Brunberg, Kirk A. Frey, Joseph A. Horton, John P. Deveikis, Donald A. Ross, and Robert A. Koeppe

**PURPOSE:** To determine the utility of [<sup>15</sup>O]H<sub>2</sub>O positron emission tomography (PET) for the quantitative determination of cerebral blood flow in patients undergoing balloon test occlusion of the internal carotid artery. **METHODS:** Twenty-two [<sup>15</sup>O]H<sub>2</sub>O PET cerebral blood flow studies were completed on 20 patients for whom temporary or permanent occlusion of the internal carotid artery was being considered because of skull base tumor or internal carotid artery aneurysm. In each study, cerebral blood flow was determined during temporary balloon internal carotid artery occlusion, and again after deflation and removal of the balloon from the internal carotid artery. **RESULTS:** Patients were divided into three groups based on clinical and cerebral blood flow response to balloon test occlusion. Studies were classified as group I when associated with no clinical symptomatology and with a cerebral blood flow decrease of less than 10 mL/100 g per minute (16 of 22 patients); as group II when there was no clinical symptomatology and cerebral blood flow fell to 25 to 35 mL/100 g per minute on the occluded side (5 of 22); and as group III when the patient was clinically unable to tolerate test occlusion and had a cerebral blood flow of less than 20 mL/100 g per minute on the occluded side (1 of 22). Neurologic sequelae developed in none of the eight group I patients later undergoing permanent internal carotid artery occlusion. Cerebral infarction developed subsequently in the one group II patient who underwent internal carotid artery occlusion. **CONCLUSION:** During internal carotid artery balloon test occlusion, [<sup>15</sup>O]H<sub>2</sub>O PET determination of cerebral blood flow allows rapid quantitative determination of cerebral blood flow throughout the entire brain, predicting the adequacy of collateral flow after permanent occlusion. All patients were able to tolerate the [<sup>15</sup>O]H<sub>2</sub>O PET cerebral blood flow determination, and there were no complications of the procedure.

**Index terms:** Positron emission tomography (PET); Cerebral blood flow; Interventional neuroradiology, provocative testing; Catheters and catheterization, balloons; Arteries, carotid (internal)

*AJNR Am J Neuroradiol* 15:725-732, Apr 1994

Elective temporary or permanent occlusion of the internal carotid artery in its cervical portion or at the skull base is increasingly used in the treatment of traumatic arterial lesions, for the

management of inoperable internal carotid artery aneurysms or pseudoaneurysms (1, 2), and during the surgical management of skull base or cervical tumors (3). Such temporary or permanent occlusion can be accomplished by surgical ligation or with endovascular inflatable detachable silicone or latex balloons (1-3). Because of an immediate and long-term risk for subsequent cerebral infarction, which may approach 30% after permanent occlusion of a single internal carotid artery (4-6), several techniques for internal carotid artery test occlusion have been developed to allow prediction of the adequacy of collateral flow. Initial methods included the application of percutaneous digital carotid pressure with clinical observation of the patient's neurologic examination as described by Matas (7) and

---

Received January 7, 1993; accepted pending revision March 15; revision received June 9.

Presented in part at the 30th Annual Meeting of the American Society of Neuroradiology, St. Louis, June 1992.

From the Departments of Radiology (J.A.B., J.A.H., J.P.D.), Surgery (Section of Neurosurgery) (J.A.B., D.A.R.), Neurology (J.A.B., K.A.F.), and Internal Medicine (K.A.F., R.A.K.), The University of Michigan Hospitals, Ann Arbor.

Address reprint requests to James A. Brunberg, MD, Department of Radiology, The University of Michigan Hospitals, 1500 E. Medical Center Dr, Ann Arbor, MI 48109-0030.

*AJNR* 15:725-732, Apr 1994 0195-6108/94/1504-0725

© American Society of Neuroradiology



the angiographic assessment of collateral flow at the circle of Willis. Neither has proved adequate for the accurate prediction of morbidity after permanent occlusion. Other methods have included intraoperative test occlusion with electroencephalographic monitoring and preoperative intraarterial balloon test occlusion of the internal carotid artery for up to 30 minutes with a combination of neurologic and neuropsychological testing, electroencephalographic monitoring, internal carotid artery stump pressure measurement, and/or the incorporation of induced hypotension.

A major advance in prediction of the safety of internal carotid artery occlusion was the incorporation during balloon test occlusion of cold xenon computed tomographic (CT) techniques for the quantitative determination of cerebral blood flow (8). Current xenon CT methods are, however, generally limited to two 10-mm-thick sections through the cranial vault. They are also limited by degradation of cerebral blood flow data from movement because of the anesthetic effect of xenon, by a failure rate up to 20% because of patient motion (see 10, 12, 13), by activation of cerebral blood flow from the effect of inhaled xenon itself (9–13), and by obscuration of posterior fossa detail by artifact related to regional bone density. For these reasons we have developed a [ $^{15}\text{O}$ ]H $_2\text{O}$  positron emission tomography (PET) technique for rapid quantitative determination of cerebral blood flow throughout the entire brain during brief internal carotid artery balloon test occlusion. The purpose of this report is to describe our initial experience with this method and to describe its role in the prediction of the adequacy of collateral circulation after permanent internal carotid artery occlusion.

## Methods

Twenty patients with skull-base tumors or aneurysms of the internal carotid artery underwent 22 angiographic evaluations and clinical internal carotid artery balloon test occlusions (Table 1). The 20 patients then underwent 22 [ $^{15}\text{O}$ ]H $_2\text{O}$  PET cerebral blood flow studies, each of which included cerebral blood flow determinations obtained without and with balloon test occlusion of the internal carotid artery. One patient underwent three clinical balloon test occlusions and three [ $^{15}\text{O}$ ]H $_2\text{O}$  cerebral blood flow procedures (Fig 1). Studies were done when there was a potential for temporary or permanent ligation of the internal carotid artery during skull base surgery or when internal carotid artery occlusion was planned as management of aneurysm or pseudoaneurysm. Informed consent was obtained from all patients, and the project was approved by our institutional review board.

The internal carotid artery balloon test occlusion procedure was initiated with baseline neurologic and neuropsychologic testing of the patient in the angiographic suite. A double lumen 5-F Swan-Ganz catheter was steam formed to approximate the shape of a JB-2 catheter. The balloon was test filled with Omnipaque 150 with elimination of air from the system. The catheter was inserted through a 5.5-F sheath placed in the right femoral artery, and its tip was advanced to the origin of the selected common carotid artery. With fluoroscopic guidance the tip was floated into the internal carotid artery by partially inflating the balloon. It was then advanced to the C2–3 level. Heparin was given (8000 U intravenously), and the volume of contrast necessary to fill the balloon just to the point of contour alteration and vessel occlusion was carefully determined. Occlusion was confirmed by contrast injection through the central lumen of the catheter, after which the balloon was immediately deflated to wash contrast from the endothelial surface. Under fluoroscopic control, the balloon was then reinflated to the predetermined occlusive volume, with neurologic and neuropsychologic testing to determine whether the patient was able to tolerate the 60 to 70 seconds of internal carotid artery occlusion necessary to complete the PET cerebral blood flow determination. The balloon was then deflated and left in place. The catheter position was marked by an adhesive strip at the location

TABLE 1: Outcome after balloon test occlusion in 20 patients: permanent internal carotid artery occlusion versus no occlusion

Grade	Total	Permanent Internal Carotid Artery Occlusion Not Done		Permanent Internal Carotid Artery Occlusion		Neurologic Deficit after Internal Carotid Artery Occlusion
		Tumor	Aneurysm	Tumor	Aneurysm	
I	16	7	1	2	6	0/8 (0%)
II	5	2	2	0	1	1/1 (100%)
III	1	0	1	0	0	0
Total procedures	22	9	4	2	7	1



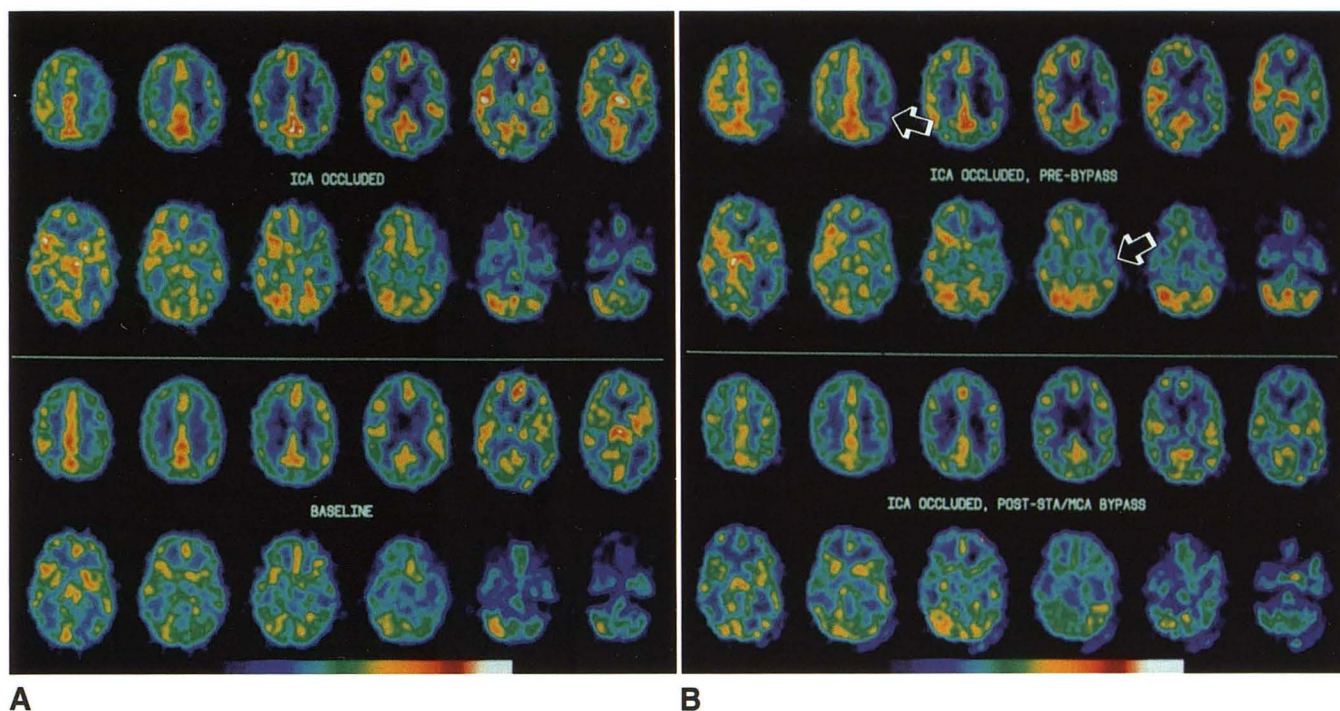


Fig. 1. Posttraumatic pseudoaneurysm of the left petrous internal carotid artery.

A, Selected images from a [ $^{15}\text{O}$ ]H $_2$ O PET cerebral blood flow study with and without internal carotid artery balloon test occlusion demonstrate no alteration in cerebral blood flow during balloon test occlusion (group I). Color scale range 10 to 110 mL/100 g per minute. After placement of two detachable silicone balloons within the aneurysm there was preservation of the internal carotid artery lumen. After doing well for several weeks the patient heard a "pop" in his left ear. A left internal carotid artery angiogram demonstrated recurrent filling of the lumen with contrast caused by rupture of the occluding balloons. Within the angular branch of the left middle cerebral artery there was a filling defect consistent with a balloon fragment. There was no clinical neurologic deficit.

B, A repeat [ $^{15}\text{O}$ ]H $_2$ O PET cerebral blood flow study with left internal carotid artery balloon test occlusion (*top*) was done before planned permanent occlusion of the left internal carotid artery. The study demonstrated regions of diminished cerebral blood flow in the left frontal, temporal and parietal lobes consistent with impaired collateral circulation in the distribution of several middle cerebral artery branches (group II). Color scale 7 to 90 mL/100 g per minute. After anastomosis of the superficial temporal artery to the partially occluded middle cerebral artery branch, just distal to the site of partial occlusion, an external carotid angiogram demonstrated excellent flow. Repeat [ $^{15}\text{O}$ ]H $_2$ O PET cerebral blood flow determination during balloon test occlusion, immediately after the superficial temporal artery/middle cerebral artery bypass, with the patient recovering from anesthesia (*bottom*), demonstrated cerebral blood flow to be symmetric and greater than 30 mL/100 g per minute throughout both hemispheres (group I). Subsequent permanent occlusion of the left internal carotid artery was completed without the development of neurologic sequela.

of catheter entrance into the sheath so that it could later be inflated for PET scanning without fluoroscopic control. The patient was then passively moved from the angiographic table and placed on a cart for transport to the PET suite.

PET cerebral blood flow studies were completed on a Siemens (Iselin, NJ) 931/08-12 tomograph. After transmission scanning for attenuation correction, an intravenous bolus of 3330 to 3700 MBq of [ $^{15}\text{O}$ ]H $_2$ O was administered. The brain tracer time-activity curve was determined between 15 and 75 seconds after bolus arrival in the scanner field of view using the positron tomograph. Arterial blood samples were used to calculate the arterial tracer time-activity curve and to measure carbon dioxide tension. Cerebral blood flow determination, done first with the vessel occluded, required balloon inflation for approximately 70 seconds. The balloon was then deflated and the catheter removed. Cerebral blood flow determination was then repeated after 8 minutes with the vessel not occluded. Fifteen

contiguous 6.75-mm-thick parametric images of cerebral blood flow were constructed through the cranial vault for each determination. Data, available within 10 minutes, were analyzed using region-of-interest determinations which were anatomically configured and placed over the frontal, temporal, parietal, and occipital cortex, as well as over the cerebellar hemispheres. Cerebral blood flow was corrected for change in carbon dioxide tension on the basis of a 3% decrease in cerebral blood flow for each mm Hg decrease in measured arterial carbon dioxide tension. Heparin was reversed with protamine. Total time for the study was 50 to 70 minutes. Clinical follow-up evaluation was available on all patients.

## Results

The results of 22 clinical balloon test occlusion studies and 22 [ $^{15}\text{O}$ ]H $_2$ O PET determinations of



cerebral blood flow, done both without and with internal carotid artery balloon test occlusion, were available from 20 subjects. No studies were incomplete or unsuccessful. Test results were divided into three groups based on clinical response to balloon test occlusion and on [ $^{15}\text{O}$ ]H $_2\text{O}$  cerebral blood flow response to balloon test occlusion. Group I included 16 studies on 14 patients who clinically tolerated balloon test occlusion and had either no change in cerebral blood flow with internal carotid artery balloon test occlusion or had a decrease in cerebral blood flow of less than 3 to 10 mL/100 g per minute in comparison with values obtained without occlusion (Fig 2). In all group I patients, cerebral blood flow remained above 35 mL/100 g per minute throughout the cortex of both hemispheres. Group II included five studies on five patients who clinically tolerated balloon test occlusion but had a regional decrease of cerebral blood flow to 25 to 35 mL/100 g per minute on the occluded side (Fig 2).

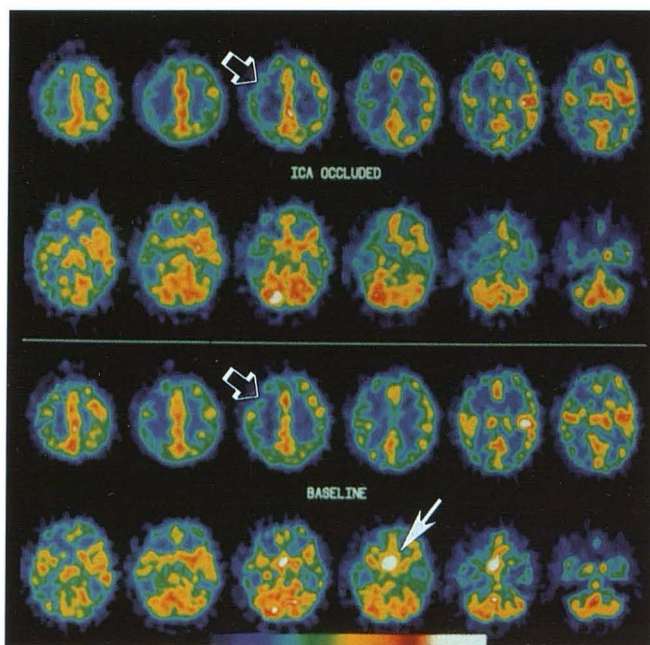


Fig. 2. Giant right internal carotid artery aneurysm distal to the ophthalmic artery in patient with right optic neuropathy. [ $^{15}\text{O}$ ]H $_2\text{O}$  PET cerebral blood flow study before and during internal carotid artery balloon test occlusion demonstrated no alteration in cerebral blood flow during balloon test occlusion (group I). A fixed perfusion deficit is demonstrated in the right frontal region at the site of a small chronic subdural hematoma (*open arrows*). Rapid flow is seen in the aneurysm during the unoccluded baseline study (*arrow*). Color scale range 0 to 140 mL/100 g per minute. Magnetic resonance 4 weeks after internal carotid artery occlusion with detachable silicone balloons demonstrated occlusion of the right internal carotid artery and thrombus filling the aneurysm. There were no neurologic sequelae, and vision gradually improved.

Group III included one patient who was clinically unable to tolerate test occlusion and had a cerebral blood flow of less than 10 mL/100 g per minute on the occluded side. One aneurysm patient appears twice in group I and once in group II (Fig 1).

After clinical and [ $^{15}\text{O}$ ]H $_2\text{O}$  cerebral blood flow balloon test occlusion procedures, nine patients underwent permanent occlusion of the tested internal carotid artery; in the remaining 13 situations permanent occlusion was not undertaken (Table 1). In the eight group I patients who underwent permanent occlusion, no temporary or permanent neurologic sequelae developed (Fig 2). The seven group I patients who did not undergo permanent occlusion were found not to require internal carotid artery occlusion either at the time of skull base surgery (seven cases) or at the time of management of a pseudoaneurysm of the internal carotid artery (one case) (Fig 1). Of the five patients in group II, four did not undergo internal carotid artery occlusion because of lack of need for occlusion at the time of skull base surgery and/or because of the perceived risk of occlusion in the presence of diminished cerebral blood flow reserve. One patient in group II developed uncontrollable but minor bleeding from the aneurysm wall during attempted aneurysm exposure and required intraoperative internal carotid artery ligation (Fig 3). Systolic blood pressure never fell below 145 mmHg during the operative procedure. A mild hemiparesis subsequently developed in this patient, and has persisted. The one patient in group III did not undergo carotid occlusion. Cerebral blood flow in this patient during balloon test occlusion decreased to 10 mL/100 g per minute in the distribution of the right anterior and middle cerebral arteries. Cerebral blood flow in the cortex of the left cerebellar hemisphere decreased to 45 mL/100 g per minute in comparison with normal right cerebellar cerebral blood flow of 71 mL/100 g per minute as a manifestation of crossed cerebellar diaschisis. Fifteen minutes after the balloon test occlusion procedure, a repeat PET study demonstrated normal cerebral and cerebellar blood flow. Data regarding this patient have been published elsewhere (14).

## Discussion

Internal carotid artery occlusion is increasingly used during the surgical approach to skull-base tumors and for management of inoperable inter-



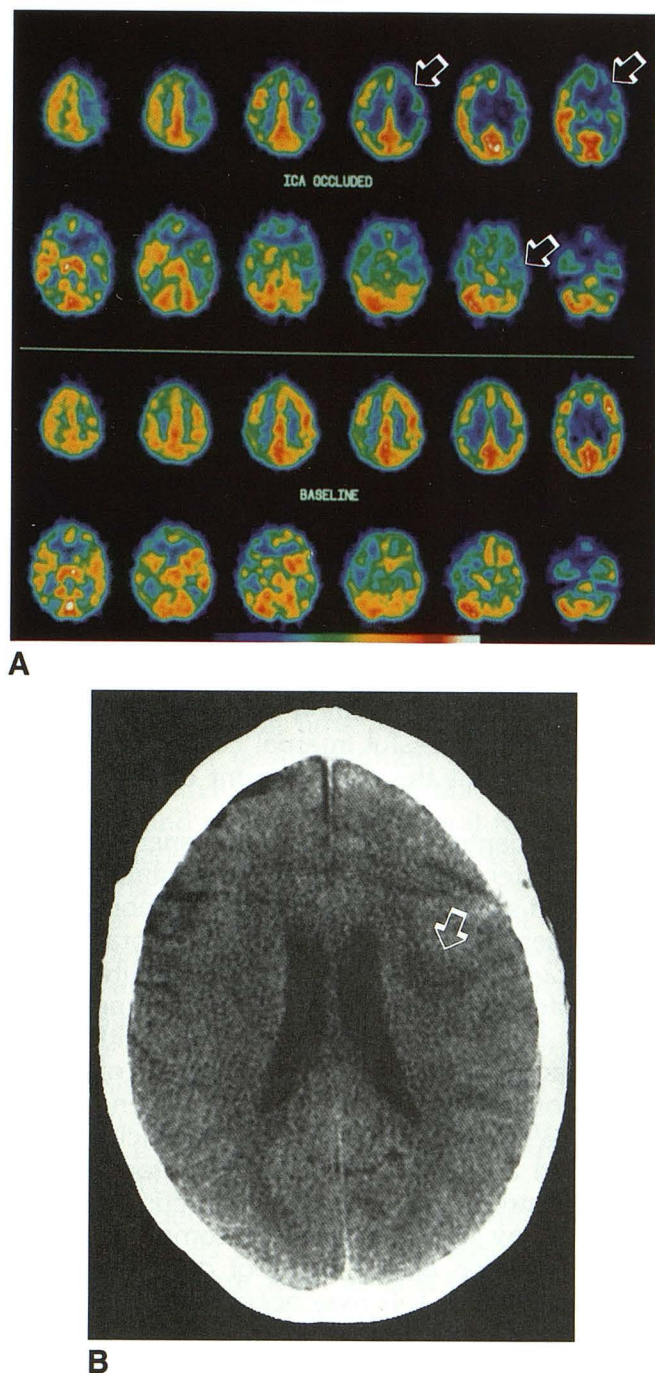


Fig. 3. Bilateral supraclinoid internal carotid artery aneurysms with previous successful clipping of the aneurysm on the right.

A, Balloon test occlusion of the left internal carotid artery was clinically normal. Selected images from a [ $^{15}\text{O}$ ]H $_2\text{O}$  PET cerebral blood flow study demonstrate a focal region of decreased flow to less than 25 mL/100 g per minute in the left posterior frontal and temporal region (arrows) during temporary internal carotid artery occlusion (group II). Color scale range 4 to 55 cc mL/100 g per minute. During a subsequent surgical approach to the aneurysm it became necessary to clamp the left internal carotid artery permanently. Two weeks after surgery a right hemiparesis developed; it has only partially resolved.

nal carotid artery aneurysms. Although embolization can occur from the distal internal carotid artery stump after occlusion, the risk of neurologic dysfunction after occlusion relates primarily to the adequacy of regional collateral flow in the distribution of the occluded vessel. This collateral flow is critical not only at the time of initial occlusion, but also during episodes of systemic hypotension, diminished cardiac output, or severe anemia, which may occur at a later date. The performance of a balloon test occlusion procedure with quantitative assessment of residual cerebral blood flow is thus helpful for determining the adequacy of collateral flow, for determining cerebral blood flow reserve capacity, and for predicting the potential for long-term maintenance of neurologic function after permanent vascular occlusion.

In human subjects, normal cerebral blood flow determined by [ $^{15}\text{O}$ ] PET techniques varies with patient age, physiologic activation of the region being studied, methodology, tracer kinetics, signal-to-noise ratio, image resolution, and size of the structure being imaged (15). With PET techniques, cerebral blood flow in cortical gray matter is generally 55 to 65 mL/100 g per minute and in white matter is 18 to 22 mL/100 g per minute (15). In primates and humans, it has been demonstrated with varying flow measurement techniques that a sustained fall of cortical blood flow to less than 18 to 23 mL/100 g per minute will result in reversible neuronal dysfunction, and that sustained flows of less than 8 to 12 mL/100 g per minute results in clinical and pathologic changes of infarction (16–19). Electroencephalographic changes characterized by excessive slow-wave activity occur when cortical blood flow falls to 16 to 22 mL/100 g per minute, and electroencephalographic flattening is demonstrated at cortical flows of less than 15 mL/100 g per minute (20, 21). Falls in blood flow that do not reach these levels, despite the percentage decline from antecedent normal values, do not result in clinical alteration. The magnitude of change in cerebral blood flow may indicate the hemodynamic significance of the occlusion, but it does not seem to predict the likelihood of ischemic complications. The percentage of fall of cerebral blood flow in response to balloon test occlusion

B, A CT study without contrast demonstrates a left posterior frontal infarction which predominantly involves subcortical and deep white matter.



was therefore not used in assigning patients to groups I to III.

During balloon test occlusion or after permanent vessel occlusion, a sustained fall of cortical blood flow to less than 18 to 20 mL/100 g per minute will result in prompt neuronal dysfunction, symptoms of which may be demonstrable if they occur in regions of eloquent cortex. Patients in group III are characterized by such a fall in cerebral blood flow during balloon test occlusion. They will predictably not tolerate permanent internal carotid artery occlusion. Although the development of clinical symptomatology during the balloon test occlusion (group III) obviates the need for quantitative cerebral blood flow assessment, it is possible for cerebral blood flow in clinically silent cortical areas to fall to levels sufficient to produce infarction without evoking evidence of clinical or electroencephalographic alteration. The quantitative evaluation of cerebral blood flow is therefore necessary in all patients who are clinically asymptomatic and have no electroencephalographic alteration during balloon test occlusion.

During balloon test occlusion, patients in group II are characterized by the lack of clinical change and by cortical regions with cerebral blood flow values ranging from 20 to 35 mL/100 g per minute. These areas have compromised collateral supply, although flow remains above ischemic thresholds. Xenon CT studies have demonstrated that patients with cerebral blood flow values of less than 300 mL/100 g per minute are at high risk for the development of cerebral infarction after permanent internal carotid artery occlusion (1, 8, 22). Patients in group II cannot be distinguished by clinical or by electroencephalographic criteria from patients in group I. Additionally, the measurement of carotid artery stump pressure during balloon test occlusion does not predict the adequacy of cerebral blood flow during balloon test occlusion (23). Because of compromised collateral flow, patients in group II are at risk for the development of stroke after permanent internal carotid artery occlusion.

Regions of impaired collateral flow detected during balloon test occlusion must be distinguished from regions with a fixed flow deficit which may have arisen from prior infarction, trauma, or surgery. This is accomplished by comparing blood flow data obtained without and with balloon test occlusion during each study. Because autoregulation maintains blood flow independent of perfusion pressure at pressures between 50

and 130 mmHg, the absence of matched flow defects on the unoccluded and balloon test occlusion studies indicates that there is insufficient collateral supply and vasodilation capacity during balloon test occlusion and that any further decline in perfusion pressure may be accompanied by an additional fall in cerebral blood flow. The inadequacy of perfusion reserves in such regions places the group II patient at risk for temporary or permanent neurologic dysfunction, even at times remote from initial testing or permanent occlusion, should there be a fall in perfusion pressure or oxygen-carrying capacity. In the current study, cerebral infarction developed in the distribution of the occluded vessel in the one patient of five in group II who underwent carotid ligation. A second group II patient underwent flow augmentation with a superficial temporal to middle cerebral artery bypass. A repeat balloon test occlusion cerebral blood flow study demonstrated that the patient had no region of diminished flow and allowed his reclassification as group I. He then underwent successful internal carotid artery occlusion without the development of subsequent infarction.

For patients in group II, permanent internal carotid artery occlusion risks the establishment of a fixed syndrome of diminished cerebral blood flow reserve capacity of "misery cerebral perfusion," (24) in which there will potentially be inadequate circulatory reserves to supply metabolic needs. These metabolic needs vary with functional activity and with concentration of metabolic components in the blood (oxygen or glucose). When reserve capacity is sufficiently diminished and maximal potential autoregulation has occurred, an increasing extraction ratio of oxygen may be insufficient to accommodate metabolic function during times of diminished perfusion pressure. This may occur with episodes of hypotension or arrhythmia, with severe anemia, or during vasospasm associated with subarachnoid hemorrhage. Patients with diminished cerebral blood flow reserve capacity may experience recurrent symptoms of cerebral dysfunction, not related to embolic phenomenon, but caused by relative oxygen insufficiency. Infarction will occur if the insufficiency is severe enough or is prolonged. The cerebral blood flow value of 20 to 35 mL/100 g per minute has been chosen to characterize the group II patients at risk on the basis of experience gained with xenon CT (1, 8, 22).

In group II patients the administration of intravenous acetazolamide in association with cerebral



blood flow determination may be useful for the quantification of cerebrovascular reserve capacity (12, 25, 26) and the more precise prediction of the success of permanent internal carotid artery occlusion. Cerebrovascular reserve capacity can be expressed as the difference between resting cerebral blood flow and cerebral blood flow after acetazolamide. Patients who fail to demonstrate an increase in cerebral blood flow after administration of acetazolamide can be assumed to be in maximal vasodilation with minimal flow reserve at a given perfusion pressure. Persisting though diminished reserve capacity may indicate the ability of regional cerebral parenchyma to tolerate permanent internal carotid artery occlusion despite significant compromise in collateral flow. As an alternative to the use of acetazolamide, hypotension or hypercardia also may be useful in determining cerebrovascular reserve capacity.

Regions of diminished cerebral blood flow during balloon test occlusion may relate not only to inadequate collateral flow but also to diaschisis associated with deafferentation and diminished metabolic activity (14). The distinction between diaschisis and diminished collateral flow usually can be made on the basis of known anatomic relationships, such as the occurrence of crossed cerebellar diaschisis with contralateral cerebral hemispheric ischemia. The use of intravenous acetazolamide may assist in this distinction by demonstrating increased flow because of persisting flow reserves in regions of diaschisis (27). Diaschisis during balloon test occlusion may in itself be a sufficient indicator of compromised neuronal function to preclude permanent vessel occlusion (14).

In our group of patients studied with [ $^{15}\text{O}$ ]H $_2$ O PET techniques there were no failed diagnostic studies, and there was no alteration of patient consciousness related to the agent used to determine blood flow. The limited time (8 minutes) required between sequential [ $^{15}\text{O}$ ]H $_2$ O PET studies promoted patient compliance with the procedure and allowed accurate coregistration of the sequential data obtained without and with arterial occlusion.

Advantages of the [ $^{15}\text{O}$ ]H $_2$ O PET cerebral blood flow technique have included the limited necessary duration of arterial balloon occlusion (60 to 70 seconds) for the determination of cerebral blood flow. Recognized complications of clinical internal carotid artery balloon test occlusion have been the occurrence of postocclusion emboliza-

tion, carotid dissection, and the development of aneurysm at the site of balloon inflation (Tarr RW, Pentheny JS, Horton JA, Complications of Preoperative Balloon Test Occlusion of the Internal Carotid Arteries: Experience in 300 Cases, presented at the Annual Meeting of the ASNR, Washington, DC, June 1991). These complications may relate in part to intimal injury or injury to the vasa vasorum from prolonged surface pressure by the inflated balloon. The limited duration of balloon inflation may minimize damage to the vascular wall. No complications have been encountered in our limited series of patients. With PET techniques, cerebral blood flow data through the posterior fossa are not obscured by artifact related to regional bone density. Dosimetry calculations indicate that for the 3700-MBq dosage of [ $^{15}\text{O}$ ]H $_2$ O used for a PET cerebral blood flow study, total body and brain radiation dose is 0.16 mGy.

The use of technetium-99m hexamethyl-propyleneamine oxide single photon emission CT imaging for the demonstration of symmetry of cerebral blood flow during balloon test occlusion has recently been reported (28–30). The technique has the advantage of using imaging equipment that is more widely available than PET or xenon CT. With Tc-99m hexamethyl-propyleneamine oxide single-photon emission CT, abnormal blood flow response to balloon test occlusion is characterized as focal areas of low flow or as hemispheric flow asymmetry. Results, however, are qualitative rather than quantitative, leading to potential confusion of patients in groups I and II of the present classification scheme. In a series of patients evaluated with xenon CT during balloon test occlusion, Yonas et al noted that among patients developing flow asymmetry, only 12% actually had blood flow levels less than 30 mL/100 g per minute on the side with lower flow (31). The use of qualitative Tc-99m hexamethyl-propyleneamine oxide single-photon emission CT asymmetries in cerebral blood flow during balloon test occlusion as an indication of inadequate collateral reserves may exclude a significant number of patients from undergoing successful therapeutic internal carotid artery occlusion or may result in unnecessary extracranial-to-intracranial bypass procedures. Tc-99m hexamethyl-propyleneamine oxide single-photon emission CT imaging for the quantitative determination of cerebral blood flow has been proposed but has not been validated (30).



When elective temporary or permanent occlusion of the internal carotid artery is planned, the performance of an internal carotid artery balloon test occlusion procedure is necessary to assure adequacy of collateral flow. If no clinical deficit develops, a quantitative assessment of cerebral blood flow is necessary to avoid placing the patient at risk for the development of cerebral infarction because of inadequate collateral flow and cerebrovascular reserve capacity. The use of PET with the intravenous administration of [ $^{15}\text{O}$ ]- $\text{H}_2\text{O}$  permits rapid quantitative determination of cerebral blood flow throughout the entire brain without alteration in patient responsiveness and without alteration of cerebral blood flow by the imaging agent. Potential injury to the vessel wall is minimized because of the brief duration (60 to 70 seconds) of vessel occlusion necessary for the procedure.

## References

1. Linskey ME, Sekhar LN, Horton JA, Hirsch WL, Yonas H. Aneurysms of the intracavernous carotid artery: a multidisciplinary approach to treatment. *J Neurosurg* 1991;75:525-534
2. Higashida RT, Halbach VV, Dowd C, et al. Endovascular detachable balloon embolization therapy of cavernous carotid artery aneurysms: results in 87 cases. *J Neurosurg* 1990;72:857-863
3. Gonzalez CF, Moret J. Balloon occlusion of the carotid artery prior to surgery for neck tumors. *AJNR Am J Neuroradiol* 1990;11:649-652
4. Razack MS, Sako K. Carotid artery hemorrhage and ligation in head and neck cancer. *J Surg Oncol* 1982;19:189-192
5. Nishioka H. Report on the cooperative study of intracranial aneurysms and subarachnoid hemorrhage. Section VIII, Part I: results of the treatment of intracranial aneurysms by occlusion of the carotid artery in the neck. *J Neurosurg* 1966;24:779-780
6. Roski RA, Spetzler RF, Nulsen FE. Late complications of carotid ligation in the treatment of intracranial aneurysms. *J Neurosurg* 1981;54:583-587
7. Matas R. Tests to determine the efficiency of the collateral circulation before attempting the permanent occlusion of the great surgical arteries. *Trans Am Surg Assoc* 1910;50:126-130
8. Erba SM, Horton JA, Latchaw RE, et al. Balloon test occlusion of the internal carotid artery with stable xenon/CT cerebral blood flow imaging. *AJNR Am J Neuroradiol* 1988;9:533-538
9. Witt JP, Holl K, Heissler HE, Dietz H. Stable xenon CT CBF: effects of blood flow alterations on CBF calculations during inhalation of 33% stable xenon. *AJNR Am J Neuroradiol* 1991;12:973-975
10. Latchaw RE, Yonas H, Penhney SL, Gur D. Adverse reactions to xenon-enhanced CT cerebral blood flow determination. *Radiology* 1987;163:251-254
11. Giller CA, Purdy P, Lindstrom WW. Effects of inhaled stable xenon on cerebral blood flow velocity. *AJNR Am J Neuroradiol* 1990;11:177-182
12. Tarr RW, Johnson DW, Horton JA, et al. Impaired cerebral vasoreactivity after embolization of arteriovenous malformations: assessment with serial acetazolamide challenge xenon CT. *AJNR Am J Neuroradiol* 1991;12:417-423
13. Purdy PD. Imaging cerebral blood flow in interventional neuroradiology: choice of technique and indications. *AJNR Am J Neuroradiol* 1991;12:424-427
14. Brunberg JA, Frey KA, Horton JA, Kuhl DE. Crossed cerebellar diaschisis: occurrence and resolution demonstrated with PET during carotid temporary balloon occlusion. *AJNR Am J Neuroradiol* 1992;13:58-61
15. Mazziotta JC, Phelps ME. Positron emission tomography studies of the brain. In: Phelps M, Mazziotta J, Schelbert H, eds. *Positron emission tomography and autoradiography: principles and applications for the brain and heart*. New York: Raven, 1986:493-579
16. Dettmers C, Broich K, Hartmann A, Solymosi L, Jacobs A, Kalender W. Estimated values in normal subjects. In: Yonas H, ed. *Cerebral blood flow measurement with stable xenon-enhanced computed tomography*. New York: Raven, 1992:81-83
17. Yonas H, Gur D, Claassen D, Wolfson SK Jr, Moossy J. Stable xenon-enhanced CT measurement of cerebral blood flow in reversible focal ischemia in baboons. *J Neurosurg* 1990;73:266-273
18. Jones TH, Morawetz RB, Crowell RM, et al. Thresholds of focal cerebral ischemia in awake monkeys. *J Neurosurg* 1981;54:773-782
19. Powers WJ, Grubb RL Jr, Baker RP, Mintun MA, Raichle ME. Regional cerebral blood flow and metabolism in reversible ischemia due to vasospasm. *J Neurosurg* 1985;62:539-546
20. Boysen G, Engell HC, Pistolesse GR, Fiorani P, Agnoli A, Lassen NA. On the critical lower level of cerebral blood flow in man with particular reference to carotid surgery. *Circulation* 1974;XLIX:1023-1025
21. Trojaborg W, Boysen G. Relation between EEG, regional cerebral blood flow and internal carotid artery pressure during carotid endarterectomy. *Electroencephalogr Clin Neurophysiol* 1973;34:61-69
22. de Vries EJ, Sekhar LN, Horton JA, et al. A new method to predict safe resection of the internal carotid artery. *Laryngoscope* 1990;100:85-88
23. Steed DL, Webster MW, DeVries EJ, et al. Clinical observations on the effect of carotid artery occlusion on cerebral blood flow mapped by xenon computed tomography and its correlation with carotid artery back pressure. *J Vasc Surg* 1990;11:38-44
24. Baron JC, Boussier MG, Rey A, Guillard A, Comar D, Castaigne P. Reversal of focal "misery-perfusion syndrome," by extra-intracranial arterial bypass in hemodynamic cerebral ischemia: a case study with  $^{15}\text{O}$  positron emission tomography. *Stroke* 1981;12:454-455
25. Tarr RW, Johnson DW, Rutigliano M, et al. Use of acetazolamide-challenge xenon CT in the assessment of cerebral blood flow dynamics in patients with arteriovenous malformations. *AJNR Am J Neuroradiol* 1990;11:441-448
26. Rogg J, Rutigliano M, Yonas H, Johnson DW, Penhney S, Latchaw RE. The acetazolamide challenge: imaging techniques designed to evaluate cerebral blood flow reserve. *AJNR Am J Neuroradiol* 1989;10:803-810.
27. Boggsrud TV, Rootwelt K, Russell D, Nyberg-Hansen R. Acetazolamide effect on cerebellar blood flow in crossed cerebral-cerebellar diaschisis. *Stroke* 1990;21:52-55
28. Moody EB, Dawson RC III, Sandler MP. Tc-HMPAO SPECT imaging in interventional neuroradiology: validation of balloon test occlusion. *AJNR Am J Neuroradiol* 1991;12:1043-1044
29. Peterman SB, Taylor A Jr, Hoffman JC Jr. Improved detection of cerebral hypoperfusion with internal carotid balloon test occlusion and  $^{99\text{m}}\text{Tc}$ -HMPAO cerebral perfusion SPECT imaging. *AJNR Am J Neuroradiol* 1991;12:1035-1041
30. Monsein LH, Jeffery PJ, van Heerden BB, et al. Assessing adequacy of collateral circulation during balloon test occlusion of the internal carotid artery with  $^{99\text{m}}\text{Tc}$ -HMPAO SPECT. *AJNR Am J Neuroradiol* 1991;12:1045-1051
31. Yonas H, Linskey M, Johnson DW, et al. Internal carotid balloon test occlusion does require quantitative CBF. *AJNR Am J Neuroradiol* 1992;13:1147-1148