

Generic Contrast Agents

Our portfolio is growing to serve you better. Now you have a *choice*.



FRESENIUS
KABI

[VIEW CATALOG](#)

AJNR

Orbital and optic pathway sarcoidosis: MR findings.

R F Carmody, M F Mafee, J A Goodwin, K Small and C Haery

AJNR Am J Neuroradiol 1994, 15 (4) 775-783

<http://www.ajnr.org/content/15/4/775>

This information is current as
of May 25, 2025.

Orbital and Optic Pathway Sarcoidosis: MR Findings

R. F. Carmody, M. F. Mafee, J. A. Goodwin, K. Small, and C. Haery

PURPOSE: To identify and characterize the MR findings of sarcoidosis when it involves the orbit and visual pathways. **METHODS:** The MR scans of 15 patients, 3 with presumed and 12 with proved orbital or optic pathway sarcoidosis were retrospectively reviewed. **RESULTS:** Eight patients had MR evidence of optic nerve involvement by sarcoid granuloma. Perineural enhancement was seen in four cases, optic atrophy in one. Three who had had unenhanced scans showed optic nerve enlargement. Nine patients had optic chiasmal involvement. One patient had increased T2 signal in the optic radiations. Three patients had orbital masses that had MR signal characteristics similar to pseudotumor. Five patients had periventricular white matter abnormalities closely resembling multiple sclerosis. **CONCLUSIONS:** Sarcoidosis should be considered in the differential diagnosis of optic nerve or nerve sheath enhancement on MR. Orbital sarcoidosis has MR characteristics very similar to pseudotumor.

Index terms: Sarcoidosis; Orbits, magnetic resonance; Orbits, disease; Optic tract

AJNR Am J Neuroradiol 15:775-783, Apr 1994

Approximately 25% of patients with sarcoidosis have ophthalmic involvement, most frequently uveitis (1, 2). Visual system abnormalities are the most common extrathoracic manifestations of this disease (3). In addition to the globe, the conjunctiva, extraocular muscles, retrobulbar fatty reticulum, lacrimal gland, optic nerve, chiasm, and optic radiations (meningovascular infiltration) may be affected. These patients may present with confusing clinical and radiologic findings, especially if ophthalmic involvement precedes systemic symptoms. In one series, ocular disease was the first manifestation of sarcoidosis in 19% of cases (4).

Several investigators have characterized the magnetic resonance (MR) findings in neurosarcoidosis (5-13), and some of these reports include descriptions of visual pathway involvement. In this article we describe the MR findings in 15 patients with orbital or optic pathway sarcoidosis

in order to show the spectrum of this disorder as it affects the visual apparatus. Three of these patients have presumed but not proved sarcoidosis; they are included because their cases are thought to have instructional value.

Materials and Methods

Fifteen patients, age range 17 to 52 years, with known or suspected orbital or optic pathway involvement by sarcoidosis were examined by MR. Thirteen were black and two were white; nine were female and six were male. The scans were performed from 1988 to 1992 and were reviewed retrospectively by two neuroradiologists. Most were done on a 1.5-T Signa unit (General Electric, Milwaukee, Wis), using the quadrature head coil and a variety of MR protocols. Orbits were examined in the axial plane with both T1- and T2-weighted spin-echo images, in the coronal plane with T1-weighted spin-echo images (3- to 5-mm sections), and in the sagittal plane with T1-weighted images (3-, 5-, or 7-mm section thickness). Twelve of the 15 patients had at least one gadopentetate dimeglumine-enhanced sequence (0.1 mm/kg intravenous administration) on their initial scan. T1-weighted postgadolinium fat-suppressed images were available in two cases. Eight of the patients were neuroophthalmologic referrals; the remaining seven came from a variety of other sources. The diagnosis of sarcoidosis was established by biopsy in eight cases, or by the presence of associated systemic disease (eg, pulmonary sarcoid) in four cases.

Three other patients had strong clinical and radiologic evidence indicative of neurosarcoidosis. The first of these

Received March 19, 1993; accepted pending revision May 28; revision received June 22.

From the University of Arizona Medical Center (R.F.C.), Tucson; and University of Illinois, Eye and Ear Infirmary (M.F.M., J.A.G., K.S., C.H.), Chicago.

Address reprint requests to R. F. Carmody, MD, University of Arizona Medical Center, Tucson, AZ 85724.

AJNR 15:775-783, Apr 94 0195-6108/94/1504-0775

© American Society of Neuroradiology

TABLE 1: MR findings in 15 cases of orbital and optic pathway sarcoidosis

Case	Age/Race/Sex	Symptoms	Basis of Diagnosis	Optic Nerves	Chiasm	Optic Tracts and Radiations	Other Intracranial	Lacrimal Glands	Extraocular Muscles/Orbital Apex	Basal Cisterns	Other	Gadopentetate Dimeglumine Given?
1	17/B/F (Presumed sarcoid)	Vision loss, OS ocular pain	(Presumed sarcoid)	Thickened, OS	Thickened		Two small periventricular ↑T2 areas pituitary enlarged				Parotid uptake on gallium scan	No
2	32/B/M	Vision loss, OD	Bronchial biopsy	Thickened, irregular margins, OU				Bilateral enlargement	Bilateral enlargement			No
3	30/B/F	Blurred vision narcolepsy	Bronchial biopsy		Slight thickening					Slight pituitary stalk enlargement		Yes
4	18/B/M (Presumed sarcoid)	Vision loss, OD	(Presumed sarcoid)		Thickening and enhancement		Periventricular lesions (↑T2) which enhanced			Enhancement near left cavernous sinus	Parotid enlargement, positive gallium scan, parotids	Yes
5	26/B/F (Presumed sarcoid)	Vision loss, OD	(Presumed sarcoid)	Diffuse enhancement on right side	Enhancement on right side					Sylvian fissure enhancement		Yes
6	47/W/M	Vision loss, pain OS, papillo- edema on exam	Optic nerve biopsy	Diffuse enhancement on right side perineural and nerve enhancement OS								Yes
7	52/B/F	Tolosa-Hunt syndrome OS	Orbital mass biopsy				Extensive white matter disease (↓T1, ↑T2)		Left orbital apex mass	Enhancement sylvian fissure		Yes
8	40/B/M	Vision loss OD	Biopsy (site not recorded)	Enlarged, OD	Enlarged							No
9	26/B/M	Headache	Pulmonary biopsy	Bilateral intracranial ON sheath enhancement	Diffuse perichiasmal enhancement		Hydrocephalus			Diffuse enhancement		Yes
10	51/W/F	Painful proptosis, chemo- sistis OS	Lacrimal gland biopsy					Enlarged, infiltrated OS	Enhancing retrobulbar mass			Yes
11	50/B/F	Left face and hand numbness, slurred speech	Systemic disease	Perineural enhancement, intracranial ONs	Enhancement		Extensive patchy leptomeningeal enhancement			Diffuse enhancement		Yes
12	41/B/F	Blurred vision, headache, facial pain, right ptosis	Intracranial mass biopsy	Slight compression on right by extraaxial mass	Slight enlargement and enhancement		Right fifth nerve involvement in pontine cistern			Large enhancing clival and right paracavernous enhancing mass, ↓T2 signal	Parotid enlargement	Yes

13	44/B/M	Blurred vision, Systemic (history of optic neuritis OS, 1984)	↑T2 signal in chiasm	↑proton-density and ↑T2 signal, optic radiations, left occipital lobe	Periventricular lesions (↓T1, ↑T2) with enhancement	Yes
14	40/B/F	10-year history of progressive visual loss to complete blindness, sensorineural hearing loss	Thin, atrophic, with ↑T2 signal	Atrophic optic tracts	Extensive periventricular lesions (↑T2)	Yes
15	38/B/F	Vision loss OS, Systemic lacrimal gland enlargement on exam				Yes

Note: B indicates black; W, white; OD, right eye; ON, optic nerve; OS, left eye; OU, both eyes.

(case 1) was diagnosed as having sarcoid optic neuropathy based on the MR findings, parotid and lacrimal gland uptake on gallium scan, clinical examination, and response to steroid therapy. The second patient (case 4), who also presented with unilateral optic neuropathy, had MR evidence of intracranial neurosarcoidosis, parotid uptake on gallium scan, and a negative workup for multiple sclerosis (negative visual evoked response, normal cerebrospinal fluid). The third patient (case 5) was presumed to have sarcoid based on ophthalmoscopic findings, MR evidence of meningeal involvement, and characteristic response to steroids. Her workup for multiple sclerosis was also negative.

Results

Clinical symptoms and MR findings are summarized in Table 1.

Optic Nerve, Chiasm, and Optic Tract Involvement

Eight patients had abnormalities of the optic nerve by MR (Table 1). In four cases some combination of neural or perineural enhancement was seen after gadolinium administration. One of these four (case 5, presumed sarcoid) also had uniform enhancement of the intraorbital portion of the optic nerve and nerve head (Fig 1). In this case follow-up MR after a course of steroid therapy revealed marked resolution of prior MR findings (Figs 1F and 1G). In another patient (case 6) the perineural enhancement pattern and clinical presentation suggested optic nerve sheath meningioma, and a biopsy was done (Fig 2). In cases 5 and 6, which had neural as well as perineural enhancement, both patients had profound visual loss. Conversely, in cases 9 and 11, in which only perineural enhancement was found, vision was normal.

Three patients were scanned before the availability of gadopentetate dimeglumine; all had optic nerve enlargement. One of these (case 1, presumed sarcoid) had resolution of her left eye symptoms after steroid therapy but developed a recurrence on the right after tapering off her medication.

One woman with a long-standing history of bilateral sarcoid optic neuropathy, now totally blind, showed advanced optic nerve, chiasm and optic tract atrophy (Fig 3). She also had an empty sella and diabetes insipidus, which has been described with sarcoid infiltration of the pituitary-hypothalamic axis (11, 14).

Nine patients had chiasmal enlargement and/or enhancement, usually associated with pitui-

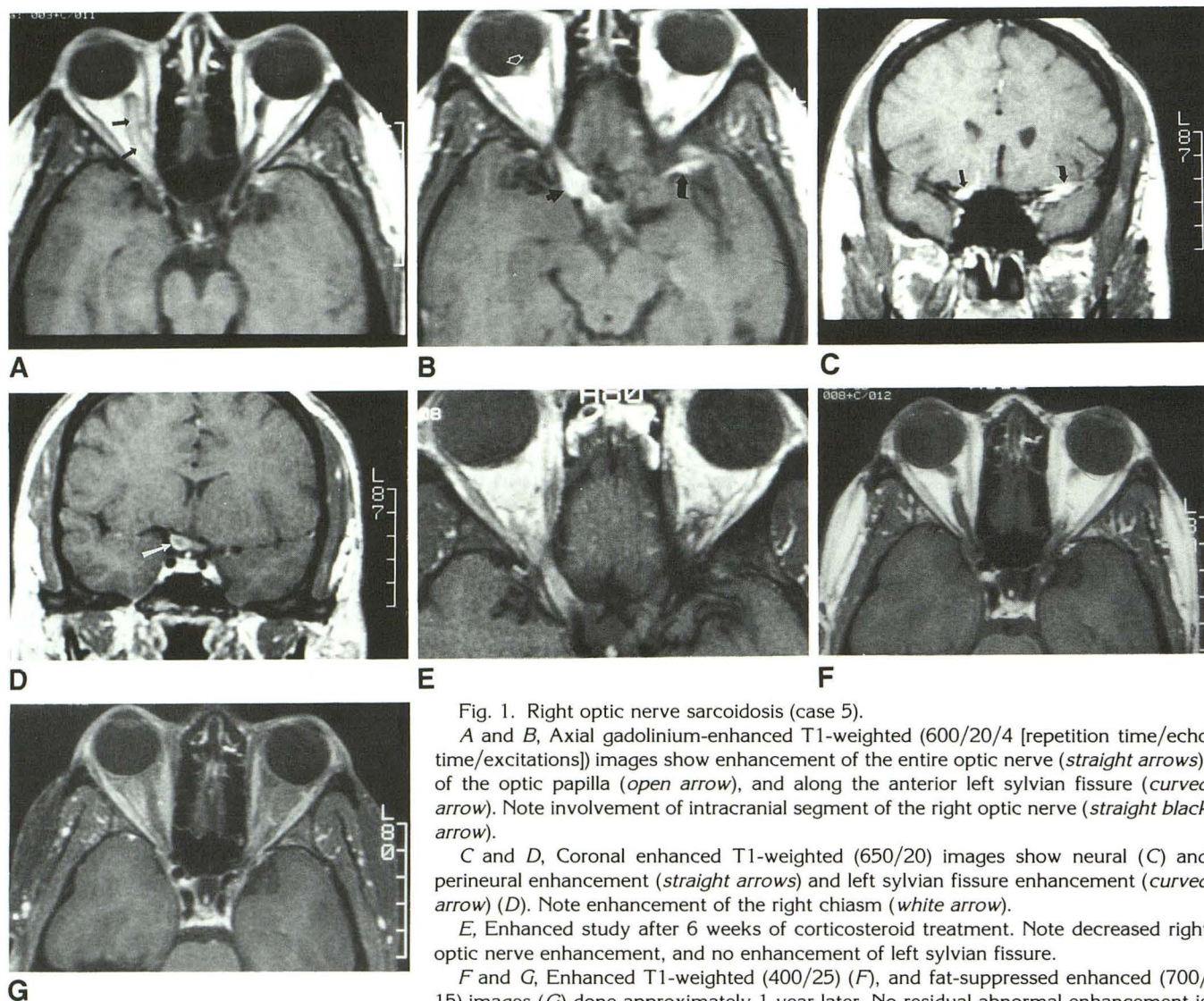


Fig. 1. Right optic nerve sarcoidosis (case 5).

A and B, Axial gadolinium-enhanced T1-weighted (600/20/4 [repetition time/echo time/excitations]) images show enhancement of the entire optic nerve (*straight arrows*), of the optic papilla (*open arrow*), and along the anterior left sylvian fissure (*curved arrow*). Note involvement of intracranial segment of the right optic nerve (*straight black arrow*).

C and D, Coronal enhanced T1-weighted (650/20) images show neural (C) and perineural enhancement (*straight arrows*) and left sylvian fissure enhancement (*curved arrow*) (D). Note enhancement of the right chiasm (*white arrow*).

E, Enhanced study after 6 weeks of corticosteroid treatment. Note decreased right optic nerve enhancement, and no enhancement of left sylvian fissure.

F and G, Enhanced T1-weighted (400/25) (F), and fat-suppressed enhanced (700/15) images (G) done approximately 1 year later. No residual abnormal enhancement is seen.

tary-infundibular and adjacent basal cisternal involvement (Fig 4).

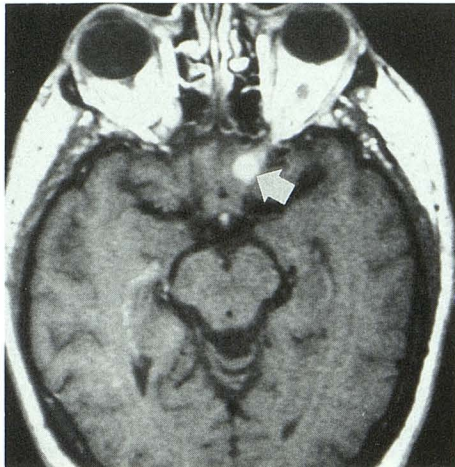
One man (case 13) with an 8-year history of pulmonary sarcoidosis and a previous episode of optic neuritis had an area of increased T2 signal intensity in the optic radiations of the left occipital lobe. His MR findings closely resembled those of multiple sclerosis.

Lacrimal Gland and Posterior Orbital Involvement

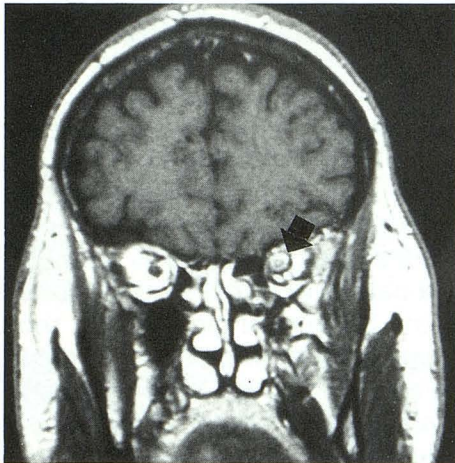
Three patients had MR evidence of lacrimal gland sarcoidosis. One showed mild, bilateral gland enlargement with diffuse, homogeneous enhancement (case 15). Her lacrimal glands were also enlarged on physical examination. The second patient (case 10) had an infiltrating mass

involving the left lacrimal gland and adjacent structures (Fig 5). The mass was isointense to muscle on T1-weighted images, became progressively more hypointense on intermediate and T2-weighted images, and enhanced uniformly. The third patient (case 2) had bilateral lacrimal gland and extraocular muscle infiltration, which was markedly hypointense on T2-weighted images (gadolinium not available).

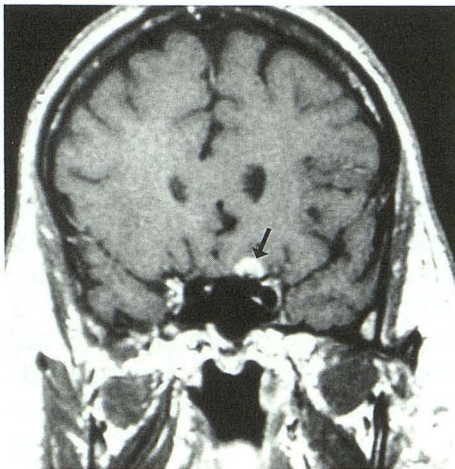
One patient (case 7) presented clinically with Tolosa-Hunt syndrome (painful ophthalmoplegia caused by cavernous sinus or superior orbital fissure "inflammation" [15, 16]). MR showed an infiltrating orbital apex mass which was isointense to gray matter on T1- and T2-weighted images and enhanced homogeneously (Fig 6). Biopsy showed noncaseating granuloma. She also had



A



B



C

Fig. 2. Left optic nerve sarcoidosis (case 6).

A, Axial postcontrast T1-weighted (500/25) image.

B and C, Coronal enhanced T1-weighted (600/25) images. Arrows indicate marked enhancement of intraorbital and intracranial portions of left optic nerve, mainly perineural (arrows), but with some involvement of nerve itself.

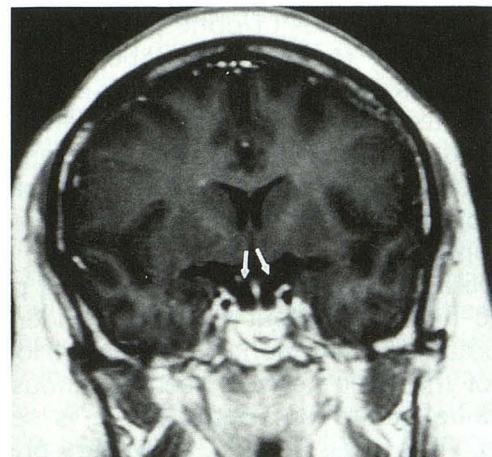
extensive white matter changes resembling multiple sclerosis.

Basal Cisternal Involvement

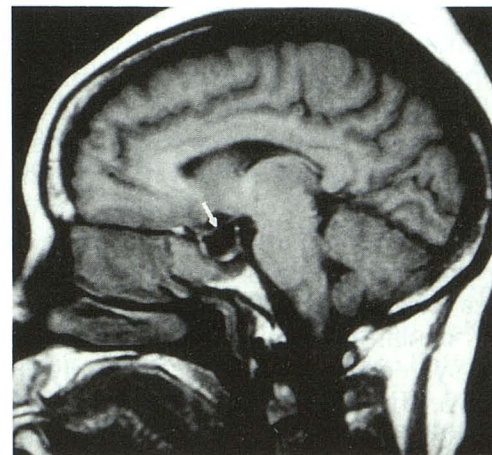
Seven of the 12 patients who received gadolinium had abnormal enhancement in the basal cisterns, most commonly in the parasellar region. In the most dramatic of those (case 12), an enhancing mass was seen in the right cavernous sinus region extending posteriorly onto the clivus (Fig 7). Although the preoperative diagnosis was en plaque meningioma, biopsy showed granulomatous inflammation compatible with sarcoidosis.

Discussion

Sarcoidosis, a granulomatous disease of unknown cause, involves the central nervous sys-



A



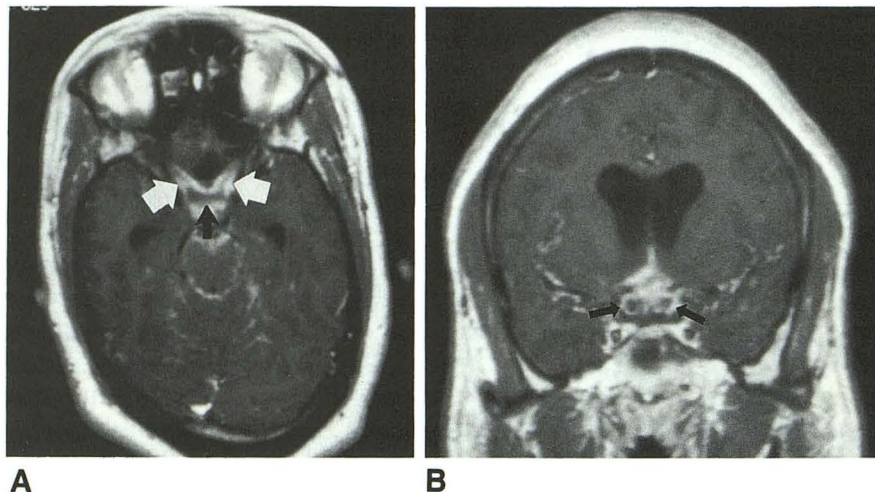
B

Fig. 3. Advanced optic atrophy caused by long-standing neurosarcoidosis (case 14). Coronal enhanced (A) and sagittal T1-weighted (450/20) (B) images show severe thinning of optic nerves, chiasm, and optic tracts (arrows). Also note empty sella.

Fig. 4. Chiasmal sarcoidosis with hydrocephalus in a 26-year-old man (case 9).

A, Axial enhanced T1-weighted (400/11) image shows encasement of intracranial optic nerves (white arrows) and chiasm (black arrow) by enhancing sarcoid tissue.

B, Coronal enhanced T1-weighted (600/11) image shows perineural enhancement surrounding intracranial optic nerves (arrows) and mild ventricular enlargement. Note also basal cisternal enhancement.



tem clinically in 5% of cases (17, 18) but is found in 16% of autopsy cases (19). The optic nerves are occasionally affected; Beardsley et al, in a cooperative retrospective study from 1974 to 1982, found 11 cases of optic nerve sarcoidosis (20). According to this paper, the optic nerve may be affected by several mechanisms: 1) optic disk papillitis caused by intraocular inflammation; 2) papilledema secondary to increased intracranial pressure; 3) retrobulbar neuritis; 4) primary infiltration of the optic nerves and nerve sheaths; and 5) optic atrophy (20, 21).

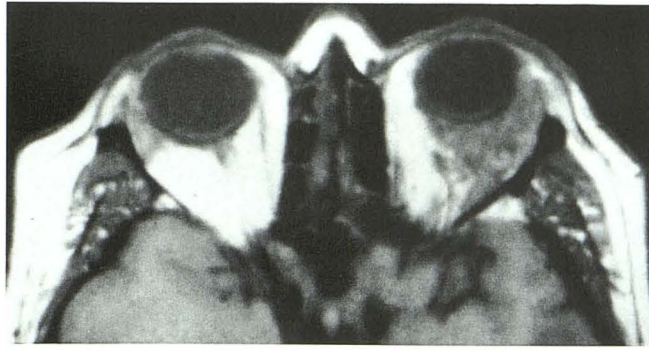
Retrobulbar neuritis refers to a clinical picture of optic neuritis without objective evidence of granulomatous infiltration of the nerve. No granuloma of the optic nerve is seen at funduscopy. No definite infiltration of the nerve is seen at imaging. This classification, however, predates the use of gadolinium-enhanced MR, and there may be overlap between retrobulbar neuritis and primary infiltration of the optic nerve.

Four patients in our series had prominent gadolinium enhancement of the optic nerve or nerve sheath similar to that seen with leptomeningeal spread of tumor, nerve sheath meningioma, orbital pseudotumor, or optic neuritis from other causes. The first of those (case 5), a young woman with presumed sarcoid optic neuropathy, illustrates the difficulty in establishing the diagnosis of ocular or orbital sarcoidosis when it precedes systemic disease. Her MR study showed optic nerve, chiasm, and sylvian fissure enhancement. Workup for tuberculous, fungal and bacterial meningitis was negative. No systemic disease was found. In this type of situation the clinician has to choose between optic nerve biopsy, craniotomy with biopsy, or empirical treatment with corticosteroids. This patient received

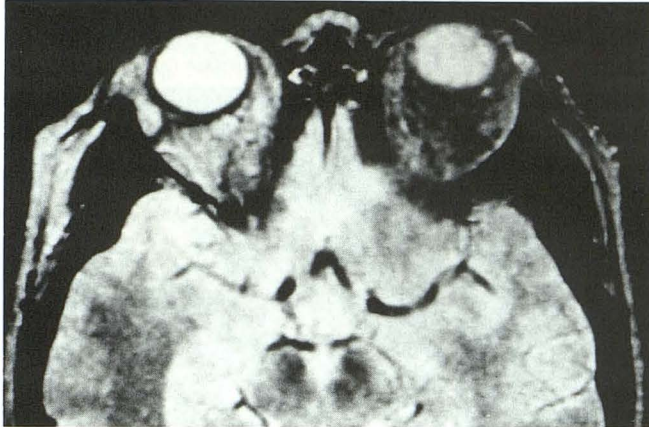
a course of prednisone and improved clinically and radiologically.

Moreover, an optic nerve biopsy that shows noncaseating granuloma does not unequivocally establish the diagnosis of sarcoidosis, which by definition is a multisystem disease (22). In the absence of systemic disease, some have referred to this isolated form of sarcoid as "granulomatous optic neuropathy" (23), or "sarcoid-like disorder" (24). Patient 6, who originally was thought to have had an optic nerve sheath meningioma, had optic nerve biopsy which showed noncaseating granuloma. Unfortunately, after the biopsy he had no light perception in the affected eye and did not recover vision despite intensive steroid treatment. Had sarcoid been considered in the initial differential diagnosis and had he received empirical steroid treatment with follow-up MRs, his outcome might have been better. Beardsley et al also described a patient who had an optic nerve biopsy for suspected meningioma which showed noncaseating granuloma (20). Their patient went from 20/30 vision before surgery to no light perception after surgery. These investigators suggest an empirical course of steroids as a noninvasive diagnostic test before biopsy of suspected nerve sheath meningioma. Gudeman et al also reported two cases of sarcoid optic neuropathy who were biopsied for suspected optic nerve sheath meningioma (25). Our experience, as well as that of several others (23, 25, 26), is that after steroid therapy granulomatous lesions of the optic nerve usually show a decrease in size and intensity of contrast enhancement, but meningiomas do not change.

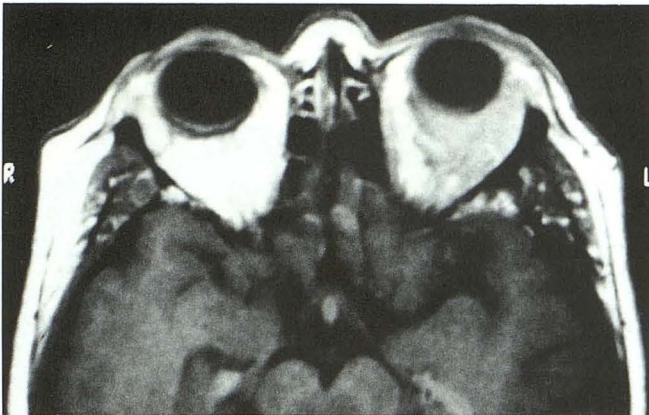
Three patients, one with presumed and two with definite sarcoid optic neuropathy, had their MR studies before the availability of gadopente-



A



B



C

Fig. 5. Orbital sarcoidosis involving left lacrimal gland and retrobulbar space (case 10).

A, Axial T1-weighted (600/23) image. The mass infiltrates the lacrimal gland, lateral rectus muscle, and retrobulbar fat.

B, T2-weighted (1500/80) image. The mass becomes hypointense to fat, simulating pseudotumor.

C, Axial enhanced T1-weighted (616/23) image shows moderate, homogeneous enhancement of the mass.

tate dimeglumine. Although some thickening and irregularity of the optic nerve could be seen, the lesions were much harder to see than those seen on patients with enhanced scans. We agree with Seltzer et al that contrast enhancement greatly increases the sensitivity of MR for central nervous

system sarcoidosis and should be used whenever this diagnosis is being considered (12).

Our three cases of orbital sarcoidosis presenting as retrobulbar infiltrating masses illustrate the difficulty in distinguishing this condition from idiopathic orbital inflammatory disease (pseudotumor), which has the same MR signal characteristics (27). One of these patients was originally thought to have lacrimal gland pseudotumor, but response to steroids was slow and incomplete. Biopsy was compatible with lacrimal gland sarcoidosis. We did not consider lymphoma or metastatic disease in this patient because these conditions are usually hyperintense on T2-weighted images.

Five of our patients also had periventricular white matter lesions of decreased T1 and increased T2 signal intensity. In most cases these lesions were indistinguishable from those seen with multiple sclerosis, and in the absence of other MR evidence of neurosarcoidosis this can be a diagnostic dilemma. For example, Smith et al (10) described five patients in whom the clinical and MR findings (ie, white matter lesions) made differentiation between these two diseases difficult or impossible. The presence of associated leptomeningeal enhancement, as was seen in three of our five patients with white matter lesions, supports a diagnosis of sarcoidosis rather than multiple sclerosis. One of our patients with periventricular lesions also had a peripheral seventh cranial nerve neuropathy—a common finding with neurosarcoidosis but not a feature of multiple sclerosis. Both multiple sclerosis and sarcoidosis may present with optic neuritis, but there are some clinical features that help in differentiating demyelinating optic neuritis from sarcoid optic neuropathy (28). Laboratory findings, such as cerebrospinal fluid values, may also overlap with neurosarcoidosis and multiple sclerosis (10). Moreover, it is certainly possible for the two diseases to coexist.

The sensitivity of MR for detecting optic neuritis (cause unspecified, but usually multiple sclerosis) seems to be about 50% (29, 30). The sensitivity of MR for demonstrating optic nerve sarcoidosis is, however, unknown. Patient 15 in this series was diagnosed clinically as having left optic neuritis caused by sarcoidosis, but this was not detected on her enhanced MR study. However, she had had 6 days of prednisone by the time she was imaged, which would tend to invalidate this case as a false negative. A prospective study to evaluate the sensitivity of MR for sarcoid

Fig. 6. Orbital apex sarcoidosis presenting as Tolosa-Hunt syndrome (case 7).

A, Axial T1-weighted (400/25) image shows a left orbital apex mass extending through the superior orbital fissure (*white arrow*).

B and C, Intermediate (3200/30) (B) and T2-weighted (3200/80) (C) images show the mass to be approximately isointense to gray matter.

D, T1-weighted (600/15) fat-suppressed enhanced image shows marked enhancement of the mass, which extends through superior orbital fissure into middle cranial fossa (*arrow*).

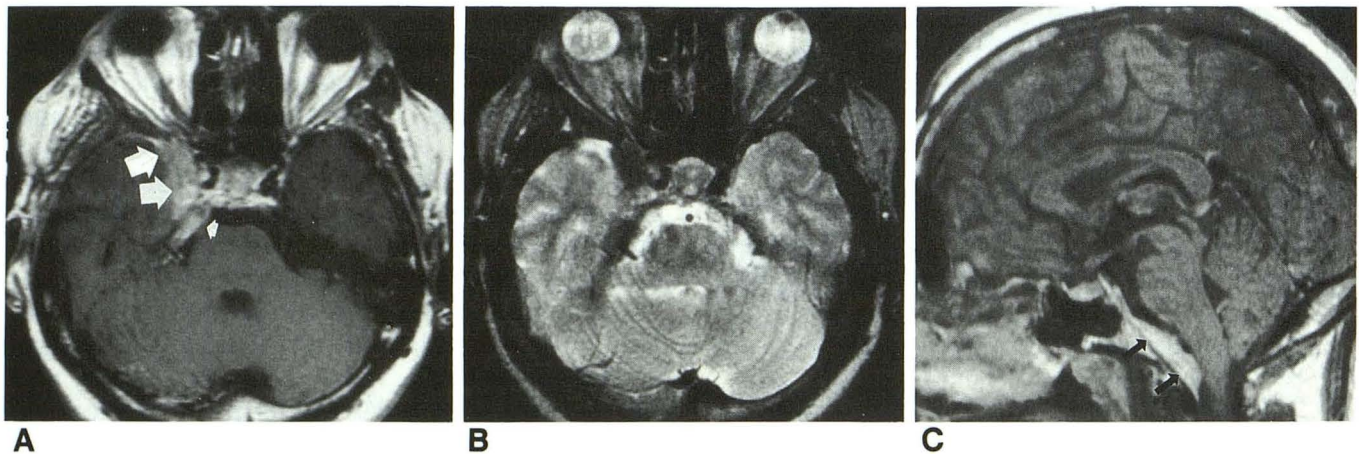
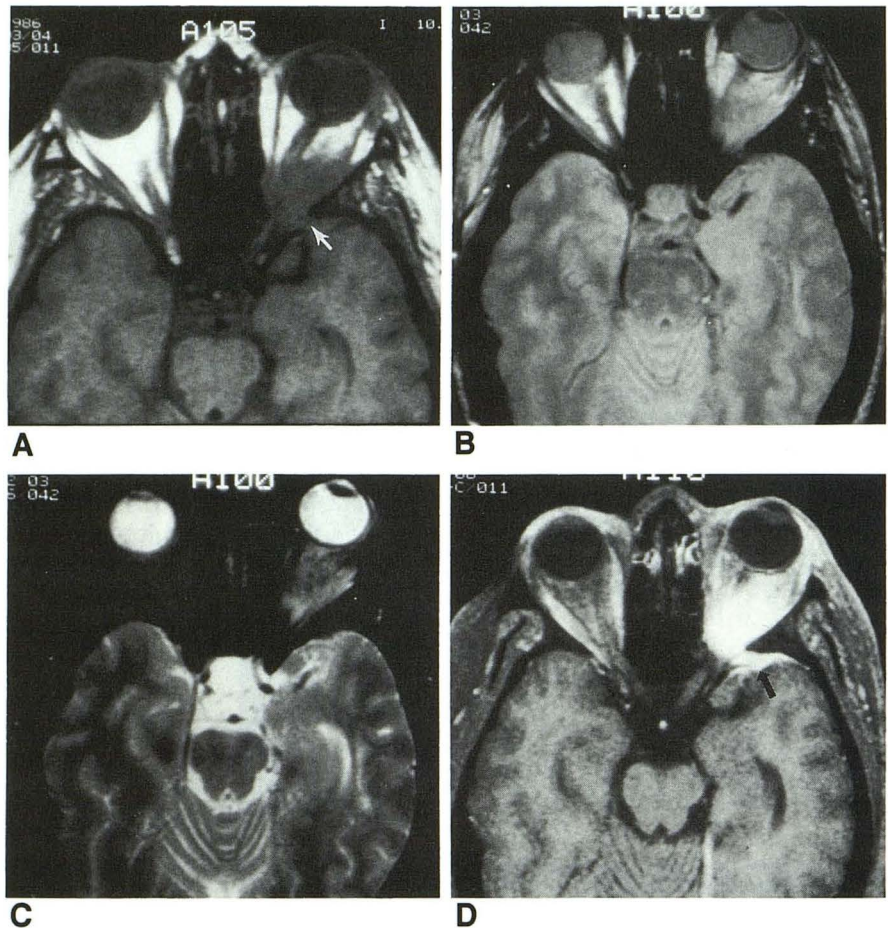


Fig. 7. Cavernous sinus and clival involvement.

A, T1-weighted (800/20) enhanced axial image shows an enhancing mass between right cavernous sinus and medial temporal lobe (*large arrows*). Also note compression of the right fifth nerve (*small arrow*) in the pontine cistern.

B, T2-weighted (2400/80) axial image shows the mass to be hypointense to brain.

C, T1-weighted (800/25) enhanced sagittal image shows an enhancing clival mass (*arrows*) resembling meningioma.

optic neuritis would be very helpful but difficult to accomplish because of the rarity of this condition.

In summary, the MR findings of orbital and optic pathway sarcoidosis may closely resemble

several other diseases, both in anatomic location and signal characteristics. Isolated optic nerve sarcoidosis is virtually impossible to diagnose without biopsy in the absence of systemic involvement. However, in certain clinical settings,

a trial of steroid therapy may be helpful in distinguishing between optic nerve sheath meningioma leptomeningeal enhancement is strong supportive evidence of sarcoidosis providing that tuberculosis, fungal disease, syphilis, and neoplasm can be ruled out by appropriate clinical and laboratory tests. A gadopentetate dimeglumine-enhanced study should be performed whenever orbital or neurosarcoidosis is suspected.

References

1. Jabs DA, Johns CJ. Ocular involvement in chronic sarcoidosis. *Am J Ophthalmol* 1986;102:297-301
2. James DG. Ocular sarcoidosis. *Ann NY Acad Sci* 1986;465:551-563
3. Jordan DR, Anderson RL, Nerad JA, Patrinely JR, Scraftford, DB. Optic nerve involvement as the initial manifestation of sarcoidosis. *Can J Ophthalmol* 1988;23:232-237
4. Obenaus CD, Shaw HE, Sydnor CF, Klitworth GK. Sarcoidosis and its ophthalmic manifestations. *Am J Ophthalmol* 1978;86:648-655
5. Ludmerer KM, Kissane JM. Visual impairment, pituitary dysfunction, and hilar adenopathy in a young man. *Am J Med* 1986;80:259-268
6. Ketonen L, Oksanen V, Kuuliala I, Somer H. Hypodense white matter lesions in computed tomography of neurosarcoidosis. *J Comput Assist Tomogr* 1986;10:181-183
7. Cooper SD, Brady MB, Williams JP, Pilgreen KL, Harp DL, Weissmann JR. Neurosarcoidosis: evaluation using computed tomography and magnetic resonance imaging. *J Comput Assist Tomogr* 1988;12:96-99
8. Hayes WS, Sherman JL, Stern BJ, Citrin CM, Pulaski PD. MR and CT evaluation of intracranial sarcoidosis. *AJNR Am J Neuroradiol* 1987;8:841-847
9. Miller DH, Kendall BE, Barter S, et al. Magnetic resonance imaging in central nervous system sarcoidosis. *Neurology* 1988;38:378-383
10. Smith AS, Meisler DM, Weinstein MA, et al. High-signal periventricular lesions in patients with sarcoidosis: neurosarcoidosis or multiple sclerosis? *AJR Am J Roentgenol* 1989;153:147-152
11. Walker FO, McLean WT, Elster A, Stanton C. Chiasmal sarcoidosis. *AJNR Am J Neuroradiol* 1990;11:1205-1207
12. Seltzer S, Mark AS, Atlas SW. CNS sarcoidosis: evaluation with contrast-enhanced MR imaging. *AJR Am J Roentgenol* 1992;158:391-397
13. Engelken JD, Yuh WTC, Carter KD, Nerad JA. Optic nerve sarcoidosis: MR findings. *AJNR Am J Neuroradiol* 1992;13:228-230
14. Tang RA, Grotta JC, Lee KF, Lee YE. Chiasmal syndrome in sarcoidosis. *Arch Ophthalmol* 1983;101:1069-1073
15. Yousem DM, Atlas SW, Grossman RI, Sergott RC, Savino PJ, Bosley TM. MR imaging of Tolosa-Hunt syndrome. *AJR Am J Roentgenol* 1990;154:167-170
16. Goto Y, Hosokawa S, Goto I, Hirakata R, Hasuo K. Abnormality in the cavernous sinus in three patients with Tolosa-Hunt syndrome: MRI and CT findings. *J Neurol Neurosurg Psychiatry* 1990;53:231-234
17. Delaney P. Neurologic manifestations in sarcoidosis. *Ann Intern Med* 1977;87:336-345
18. Stern BJ, Krumholz A, Johns C, Scott P, Nissim J. Sarcoidosis and its neurological manifestations. *Arch Neurol* 1985;42:909-917
19. Waxman JS, Sher JH. The spectrum of central nervous system sarcoidosis: a clinical and pathologic study. *Mt Sinai J Med* 1979;3:309-317
20. Beardsley TL, Brown SVL, Sydnor CF, Grimson BS, Klitworth GK. Eleven cases of sarcoidosis of the optic nerve. *Am J Ophthalmol* 1984;97:62-77
21. Ingestad R, Stigmar G. Sarcoidosis with ocular and hypothalamic-pituitary manifestations. *Acta Ophthalmol* 1971;49:1-10
22. James DG, Turiaf J, Hosoda Y, et al. Description of sarcoidosis: report on the subcommittee on classification and definition. *Ann NY Acad Sci* 1979;278:742
23. Krohel GB, Charles H, Smith RS. Granulomatous optic neuropathy. *Arch Ophthalmol* 1981;99:1053-1055
24. Frisen L, Lindgren S, MacGregor BJ, et al. Sarcoid-like disorder of the intracranial optic nerve. *J Neurol Neurosurg Psychiatry* 1977;40:702-707
25. Gudeman SK, Selhorst JB, Susac JO, Waybright EA. Sarcoid optic neuropathy. *Neurology* 1982;32:597-603
26. Brooks J, Strickland MC, Williams JP, Vulpe M, Fowler HL. Computed tomography changes in neurosarcoidosis clearing with steroid treatment. *J Comput Assist Tomogr* 1979;3:398-399
27. Atlas SW, Grossman RI, Savino PJ, et al. Surface-coil MR of orbital pseudotumor. *AJNR Am J Neuroradiol* 1987;8:141-146
28. Graham EM, Ellis CJK, Sanders MD, McDonald WI. Optic neuropathy in sarcoidosis. *J Neurol Neurosurg Psychiatry* 1986;49:756-763
29. Guy J, Mancuso A, Quisling RG, Beck R, Moster M. Gadolinium-DTPA-enhanced magnetic resonance imaging in optic neuropathies. *Ophthalmology* 1990;97:592-599
30. Merandi SF, Kudryk BT, Murtagh FR, Arrington JA. Contrast-enhanced MR imaging of optic nerve lesions in patients with acute optic neuritis. *AJNR Am J Neuroradiol* 1991;12:923-926