

Generic Contrast Agents

Our portfolio is growing to serve you better. Now you have a *choice*.



FRESENIUS
KABI

[VIEW CATALOG](#)

AJNR

MR imaging and MR angiography in the evaluation of pulsatile tinnitus.

R R Dietz, W L Davis, H R Harnsberger, J M Jacobs and D D Blatter

AJNR Am J Neuroradiol 1994, 15 (5) 879-889

<http://www.ajnr.org/content/15/5/879>

This information is current as of May 28, 2025.

MR Imaging and MR Angiography in the Evaluation of Pulsatile Tinnitus

R. Rex Dietz, Wayne L. Davis, H. Ric Harnsberger, John M. Jacobs, and Duane D. Blatter

PURPOSE: 1) To evaluate the scope of imaging findings seen with spin-echo MR and MR angiography (MRA) in patients with pulsatile tinnitus; 2) to determine whether MRA adds additional imaging information (to that provided by spin-echo MR) necessary for determining the cause of pulsatile tinnitus; and 3) to suggest MR and MRA imaging techniques for evaluation of patients with pulsatile tinnitus. **METHODS:** Forty-nine patients with pulsatile tinnitus were evaluated with MR and MRA. Seventeen of these patients had conventional angiography. **RESULTS:** Vascular lesions or paraganglioma were demonstrated in 28 patients. Of these 28 lesions, the majority were seen best (46%) or only (36%) on MRA. The spectrum of lesions detected included dural arteriovenous fistula (nine), extracranial arteriovenous fistula (three), paraganglioma (five), jugular bulb variants (three), aberrant internal carotid artery (one), internal carotid artery stenosis (one), tortuous internal carotid artery (one), carotid dissection with pseudoaneurysm (one), stenosis of the transverse sinus (two), and arteriovenous malformation (two). **CONCLUSIONS:** MRA, in conjunction with spin-echo imaging, markedly enhances the ability of MR to diagnose the lesions responsible for pulsatile tinnitus.

Index terms: Magnetic resonance angiography (MRA); Magnetic resonance, comparative studies; Hearing

AJNR Am J Neuroradiol 15:879-889, May 1994

The spectrum of lesions associated with pulsatile tinnitus makes imaging a challenge, because the differential diagnosis includes congenital and acquired vascular lesions and skull base tumors. In recent years high-resolution computed tomography (CT) with adjunctive angiography has served as the principal radiologic tool for evaluating patients presenting with pulsatile tinnitus (1-3). CT has been shown to be excellent for delineating the bony abnormalities that are associated with some of the vascular diseases and paragangliomas, but angiography is necessary to diagnose or exclude dural arteriovenous fistula (AVF) and intrinsic vascular abnormalities.

Conventional spin-echo magnetic resonance (MR) has been suggested to be of limited utility in this radiologic evaluation, because it shows poor resolution of both vascular and bony abnormalities (1, 2, 4).

Statistically the most common treatable causes of pulsatile tinnitus are paraganglioma (glomus tympanicum, jugulotympanicum, and jugulare) and dural AVF (1). Contrast-enhanced conventional spin-echo MR can diagnose paraganglioma readily (5). With the addition of MR angiography (MRA), MR can also suggest the diagnosis of dural AVF (6). It is possible then that MR with MRA will permit the screening of patients with pulsatile tinnitus with a single radiologic examination.

In this report we present our experience in MR and MRA imaging of 49 patients with pulsatile tinnitus. The goals of our study are to evaluate the scope of imaging findings seen with MR and MRA in patients with pulsatile tinnitus and to determine whether MRA adds additional imaging information (to that provided by conventional MR) necessary for determining the cause of pulsatile tinnitus. In addition, we will propose an

Received May 10, 1993; accepted pending revision August 14; revision received October 19.

From the Section of Neuroradiology, Department of Radiology, University of Utah Medical Center (R.R.D., W.L.D., H.R.H., J.M.J.), and the Department of Radiology, LDS Hospital (D.D.B.), Salt Lake City, Utah.

Address reprint requests to Wayne L. Davis, MD, Section of Neuroradiology, Department of Radiology, University of Utah Medical Center, 50 N Medical Dr, Salt Lake City, UT 84132.

AJNR 15:879-889, May 1994 0195-6108/94/1505-0879

© American Society of Neuroradiology

imaging protocol for screening patients presenting with pulsatile tinnitus.

Materials and Methods

Forty-nine patients referred with pulsatile tinnitus were evaluated with MR and MRA from February 1991 through December 1992. There were 31 female and 17 male subjects, with ages ranging from 12 to 80 years (mean 48 years) (Table 1).

All MR imaging was performed on a 1.5-T unit (Signa, General Electric, Milwaukee, Wis). A specific MR imaging protocol for pulsatile tinnitus (Table 2) was instituted in December 1991. Twenty-two patients were evaluated before the development of the protocol; 27 were imaged with the protocol.

Spin-echo MR and MRA was performed in all patients. The imaging parameters and the number of patients examined with each imaging sequence is given in Table 2. For the skull-base MRA acquisitions (7, 8), source images, maximum-intensity projection collapsed images of the complete data set, and volume of interest-restricted maximum-intensity projection images of the temporal bone regions were filmed and reviewed. Volume of interest-restricted maximum-intensity projection images (included carotid and vertebral arteries) were filmed and reviewed for cervical examinations. For two-dimensional phase-contrast exams, magnitude-corrected phase (flow directional) and angiographic speed images were filmed for interpretation (9, 10).

CT images were available for review in 10 patients. Seventeen patients had conventional angiography.

Data Analysis

Data collected included patient demographics, history, clinical findings (otoscopic findings, subjective versus objective tinnitus, cranial neuropathy, etc) and clinical diagnosis. All imaging studies were retrospectively reviewed by two of us. The examinations were scored according to the following criteria: 0, no lesion seen to explain the pulsatile tinnitus; 1, lesion seen only on spin echo MR images; 2, lesion best demonstrated on spin-echo images, but with abnormality on, or additional information provided by, the MRA images; 3, lesion best demonstrated on MRA images, but abnormality detected on, or additional information provided by, the spin-echo images; and 4, lesion detected only on the MRA images. The score for each case is given in Table 1.

Results

Spectrum of Lesions Detected

The results are summarized in Table 3. Twenty-one patients had no demonstrable cause for pulsatile tinnitus; all had subjective pulsatile tinnitus and a normal tympanic membrane. One (patient 44) had conventional angiography; none had available CT examinations. Six patients had vascular tympanic membranes; all had lesions

demonstrated. Five of these were paragangliomas; the other was caused by an aberrant internal carotid artery.

Arteriovenous Lesions

Dural AVF, the most commonly identified lesion, was seen in nine patients. Eight of the nine had conventional angiography and embolization; this was deferred in one patient because of complicating medical illness. All had objective pulsatile tinnitus. Findings on MR and MRA associated with dural AVF included: 1) increased number and size of extracranial vessels; 2) visualization of transosseous collaterals; 3) abnormal flow in the dural sinus or other venous channels; 4) stenosis or occlusion of the transverse sinus; and 5) abnormal signal from the calvarium overlying the site of the fistula (Fig 1). The transosseous channels and abnormal signal in the calvarium was best seen on the MRA source images.

Three patients had extracranial direct AVF; all underwent conventional angiography and embolization. These lesions were readily identified on MR and MRA because of the large vascular channels and high flow associated with them (Fig 2). A pial arteriovenous malformation (AVM) in the posterior temporal lobe was demonstrated on both spin-echo imaging and MRA, with MRA demonstrating supply from an enlarged posterior cerebral artery.

Tumors

MR and MRA examinations in five patients were interpreted as showing jugular foramen or middle ear masses consistent with paragangliomas (Fig 3). These cases demonstrated imaging findings consistent with those that have been previously described (5, 11). All have been surgically proved and were associated with vascular-appearing retrotypanic masses.

Arterial Lesions

An aberrant internal carotid artery was demonstrated in one patient with pulsatile tinnitus (patient 1). MRA reprojections show the characteristic figure-7 appearance (Fig 4); the MRA source images showing the posterior location of the ascending segment of the internal carotid artery. Spin-echo MR imaging did not contribute to MR in this diagnosis.

One patient had focal severe stenosis of the right internal carotid artery with an associated cervical bruit. The lesion was shown by both MRA and conventional angiography. Tortuosity

TABLE 1: Demographic information, history, and diagnoses in 49 patients with pulsatile tinnitus

Patient	Age	Sex	History	Objective/ Subjective	Vascular Tympanic Membrane?	Diagnosis	Score
1	12	F	Right pulsatile tinnitus, pulsating vascular mass behind right tympanic membrane	O	Y	Aberrant right internal carotid artery	4
2	68	F	Right-sided headache with right pulsatile tinnitus	S	N	Negative VBD with medullary compression	0
3	30	F	Bilateral pulsatile tinnitus	S	N	Negative	0
4	61	F	Left pulsatile tinnitus with tortuous internal carotid artery on Doppler	O	N	Tortuous internal carotid arteries bilateral, right > left, no significant stenosis	4
5	12	M	Left pulsatile tinnitus trauma 6 years prior	O	N	Left suboccipital vertebral to venous AVF, angio proved	3
6	17	F	Right pulsatile tinnitus	S	N	Negative	0
7	61	M	Right pulsatile tinnitus	O	N	Dural AVF, angio proved	4
8	26	M	Fullness left ear with pathologic diagnosis of glomus jugulare	S	Y	Glomus jugulotympanicum, surgically proved	2
9	77	M	Left pulsatile tinnitus	O	N	Dural AVF, angio proved	3
10	22	F	Left pulsatile tinnitus	S	N	Negative	0
11	61	F	Left pulsatile tinnitus	S	N	Left temporal lobe pial AVM	3
12	65	M	Right pulsatile tinnitus	O	N	Right occipital dural AVF, angio proved	4
13	78	F	Right pulsatile tinnitus	O	S	Right cervical internal carotid artery stenosis	4
14	43	F	Right pulsatile tinnitus	S	N	Occluded left transverse sinus, right transverse sinus with focal stenosis and poststenotic dilatation, angio proved	4
15	58	M	Left pulsatile tinnitus for 3-4 months	O	N	Dural AVF, angio proved	3
16	35	F	Right pulsatile tinnitus	S	N	Negative	0
17	69	F	Left pulsatile tinnitus, left C-7 paralysis	S	N	Negative	0
18	25	F	Rushing noise right ear	S	N	Negative	0
19	36	M	Bilateral bruit in the neck, pulsatile thrill over right occipital	O	N	Direct AVF, right vertebral artery to venous, angio proved	3
20	39	F	Right pulsatile tinnitus after resection of right paraganglioma 1 year prior to exam, now with recurrent right pulsatile tinnitus	S	Y	Glomus jugulotympanicum	1
21	50	F	Right pulsatile tinnitus pressure in right ear	S	N	Right maxillary sinus inflammation	0

TABLE 1: Continued

Patient	Age	Sex	History	Objective/ Subjective	Vascular Tympanic Membrane?	Diagnosis	Score
22	55	M	Left pulsatile tinnitus, pseudotumor cerebri after left occipital craniotomy for acoustic neuroma	O	N	Dural AVF, angiogram proved	3
23	68	F	Right pulsatile tinnitus for 2 years	S	N	Negative	0
24	23	M	Right pulsatile tinnitus and hearing loss	S	N	Absence of flow left transverse sinus with enlarged right transverse and sigmoid sinus, no evidence of mass, jugular megabulb without dehiscence	3
25	46	M	Left pulsatile tinnitus x 9 months	S	N	Negative	0
26	26	F	Left pulsatile tinnitus, vertigo for 2 months	S	N	Prominent left jugular bulb	0
27	66	F	Right pulsatile tinnitus for 2 years, palpable pulsating vascular structure right occipital	O	N	Right occipital AVF (no intracranial contribution), angiogram proved	3
28	58	M	Left pulsatile tinnitus, seizures, intermittent visual loss	O	N	Dural AVF, type III, angiogram proved	3
29	41	F	Right subjective pulsatile tinnitus, C-9 to C-12 dysfunction	S	Y	Right paraganglioma, surgically proved	2
30	38	F	Right pulsatile tinnitus	S	N	Negative	0
31	46	F	Left pulsatile tinnitus for 4 years, previous negative MR	S	N	Negative	0
32	32	M	Pulsatile tinnitus	S	N	Negative	0
33	12	M	Left pulsatile tinnitus for 3 months, constant, left eye proptosis, chemosis, past mastoiditis	O	N	Dural AVF, middle meningeal, ascending pharyngeal, and inferolateral trunk to cavernous sinus, angiogram proved	3
34	43	F	Bilateral pulsatile tinnitus x 2 years, right > left	S	N	Negative	0
35	36	F	Right pulsatile tinnitus x 4-5 months	S	N	Negative	0
36	74	F	Roaring in right ear, partial loss of hearing on right	S	N	Negative	0
37	80	F	Left pulsatile tinnitus	O	N	Left occipital dural AVF, angiogram deferred	3

of the cervical internal carotid artery without focal stenosis was demonstrated in two patients with cervical bruits.

Dissection of the cervical internal carotid artery with associated pseudoaneurysm was seen in one patient (patient 49). This patient had acute onset

TABLE 1: Continued

Patient	Age	Sex	History	Objective/ Subjective	Vascular Tympanic Membrane?	Diagnosis	Score
38	55	M	Left maxillary AVM, after partial maxillectomy and embolization x 2, now with pain left temporal region and left pulsatile tinnitus	S	N	Small residual maxillary AVM, proximally occluded left external carotid artery with multiple vertebral to external carotid artery collaterals, left face hypovascular on phase-contrast MRA, angio proved	4
39	71	F	Left pulsatile tinnitus for 2.5 months, left neck bruit	O	N	Negative	0
40	65	M	Right pulsatile tinnitus	S	N	High right jugular bulb	4
41	71	F	Right pulsatile tinnitus	S	N	Negative	0
42	33	F	Bilateral pulsatile tinnitus, left > right headaches	S	N	Maxillary sinus inflammation	0
43	75	F	Right pulsatile tinnitus	O	N	Large right dural AVF, angio proved	3
44	33	M	Right pulsatile tinnitus, past trauma	S	N	Right parietal encephalomalacia, negative angio	0
45	67	F	Left pulsatile tinnitus, hearing loss	S	Y	Enhancing lesion left middle ear consistent with glomus tympanicum (surgically proved)	1
46	39	F	Left pulsatile tinnitus, hearing loss	S	Y	Glomus jugulotympanicum with descending facial nerve involvement (surgically proved)	1
47	64	M	Left pulsatile tinnitus	S	N	Left jugular bulb diverticulum	3
48	45	F	Left pulsatile tinnitus	S	N	Jugular sinus stenosis	4
49	38	F	Right pulsatile tinnitus after chiropractic manipulation	S	N	Carotid dissection with pseudo aneurysm	4

Note.—The examinations were scored according to the following: 0, no lesion seen to explain the patient's pulsatile tinnitus; 1, lesion seen only on spin-echo MR images; 2, lesion best demonstrated on spin-echo images, but with abnormality on, or additional information provided by, MRA images; 3, lesion best demonstrated on MRA images, but abnormality detected on, or additional information provided by, spin-echo images; and 4, lesion detected only on the MRA images.

of pulsatile tinnitus after chiropractic manipulation.

Venous Lesions

Two patients (patients 24 and 40) had a high jugular bulb without dehiscence; neither had a vascular retrotympanic mass. Jugular bulb diverticulum was seen in one patient (patient 47). Focal stenosis of the transverse sinus was shown by both MRA and angiography (Fig 5) in one patient

(patient 14). A second (patient 48) with transverse sinus stenosis was seen on MRA only.

Spin-Echo versus MRA Imaging

Of the 28 patients with lesions detected on MR and MRA, in three (11%) the lesion was seen only on spin-echo images. In two other patients a lesion was best seen with spin-echo images, although abnormality was appreciated on MRA. Of these five patients (18% of lesions), all have

TABLE 2: MR and MRA imaging parameters for the evaluation of patients presenting with pulsatile tinnitus

Description	Plane	Repetition time/Echo time	Thickness/ Gap (mm)	Location	Gadolinium*	Number of Patients
Coronal T1-weighted image	Coronal	500/12	4/1	Whole brain	—	49
Axial T2-weighted image	Axial	3200/102 (effective)	5/2.5	Whole brain	—	49
MRA cervical vessels (2-D time-of-flight)	Axial	31/9	1/0	Bifurcation to skull base	—	31
MRA skull base	Axial	25/6.7	1.3/0	Foramen magnum up	—	47
Coronal T1-weighted image	Coronal	500/12	3/1	Centered at internal auditory canal	+	30
Axial T1-weighted image	Axial	500/12	3/1	Centered at internal auditory canal	+	30
2-D phase-contrast MRA ^b	Axial	33/8.4	20/0	Foramen magnum to torcular herophili	+/-	25

Note.—Examination should be tailored to the patient's clinical presentation. In patients with probable intrinsic vascular lesions (objective tinnitus, known AVF) and/or normal temporal bone/jugular foramen on T2-weighted images and clinical exam the postgadolinium sequences may be deferred. Cervical MRA may be deferred in patients with vascular tympanic membranes. If a significant cervical arterial lesion is seen, directed MRA with multiple overlapped thin-slab acquisition technique may be used for confirmation and improved spatial resolution.

* Gadolinium (0.1 mmol/kg) administered intravenously before acquisition.

^b A high velocity encoding (80 cm/sec) is used to avoid phase aliasing in directional flow imaging (9). If gadolinium is used, the 2-D phase-contrast sequence is obtained after contrast administration.

TABLE 3: Summary of findings in 49 patients with pulsatile tinnitus

Diagnosis	Number of Cases	Patient
No demonstrated cause for pulsatile tinnitus	21	2, 3, 6, 10, 16, 17, 18, 21, 23, 25, 26, 30, 31, 32, 34, 35, 36, 39, 41, 42, 44
Lesions causing pulsatile tinnitus		
Dural AVF	9	7, 9, 12, 15, 22, 28, 33, 37, 43
Paraganglioma	5	8, 20, 29, 45, 46
Extracranial AVF	3	5, 19, 27
High jugular bulb	2	24, 40
Jugular bulb diverticulum	1	47
Stenosis of transverse sinus	2	14, 48
Aberrant ICA	1	1
Pial AVM	1	11
Stenosis of ICA	1	13
Carotid dissection, pseudoaneurysm	1	49
Lesions associated with pulsatile tinnitus		
Tortuous ICA	1	4
Maxillary AVM	1	38
Total	49	

proved paragangliomas.

The majority of lesions detected (82%, $n = 23$) were best demonstrated or seen only with MRA. In 10 of these (36% of lesions) spin-echo MR failed to show an abnormality, and the lesion was demonstrated only on MRA. This group included carotid lesions ($n = 4$), dural AVF ($n = 2$), carotid

dissection and psuedoaneurysm ($n = 1$), high jugular bulb ($n = 1$), stenotic transverse sinus ($n = 2$), and a maxillary AVM ($n = 1$).

Thirteen patients (46%) had lesions best demonstrated on MRA, although an abnormality was present on spin-echo MR. Lesions in this group included dural AVF ($n = 7$), extracranial direct AVF ($n = 3$), high jugular bulb ($n = 1$), jugular bulb diverticulum ($n = 1$), and parenchymal AVM ($n = 1$).

Subjective versus Objective Pulsatile Tinnitus

A subgroup of 16 patients had objective tinnitus (cardiac synchronous sound detectable by the examining physician). All of these patients showed lesions on MR and MRA (Table 1). Dural AVF and extracranial AVF were associated with objective tinnitus in all cases, as was the aberrant internal carotid artery. Three patients with abnormalities of the cervical vessels had associated objective tinnitus or bruit.

Thirty-three patients in our series had subjective tinnitus (sound heard only by the patient). Thirteen of these patients (42%) had lesions demonstrated. These included paraganglioma, high jugular bulb, jugular bulb diverticulum, carotid dissection with psuedoaneurysm, pial AVM, maxillary AVM, and stenosis of the transverse sinus. All patients with no detectable cause for their pulsatile tinnitus had subjective tinnitus.

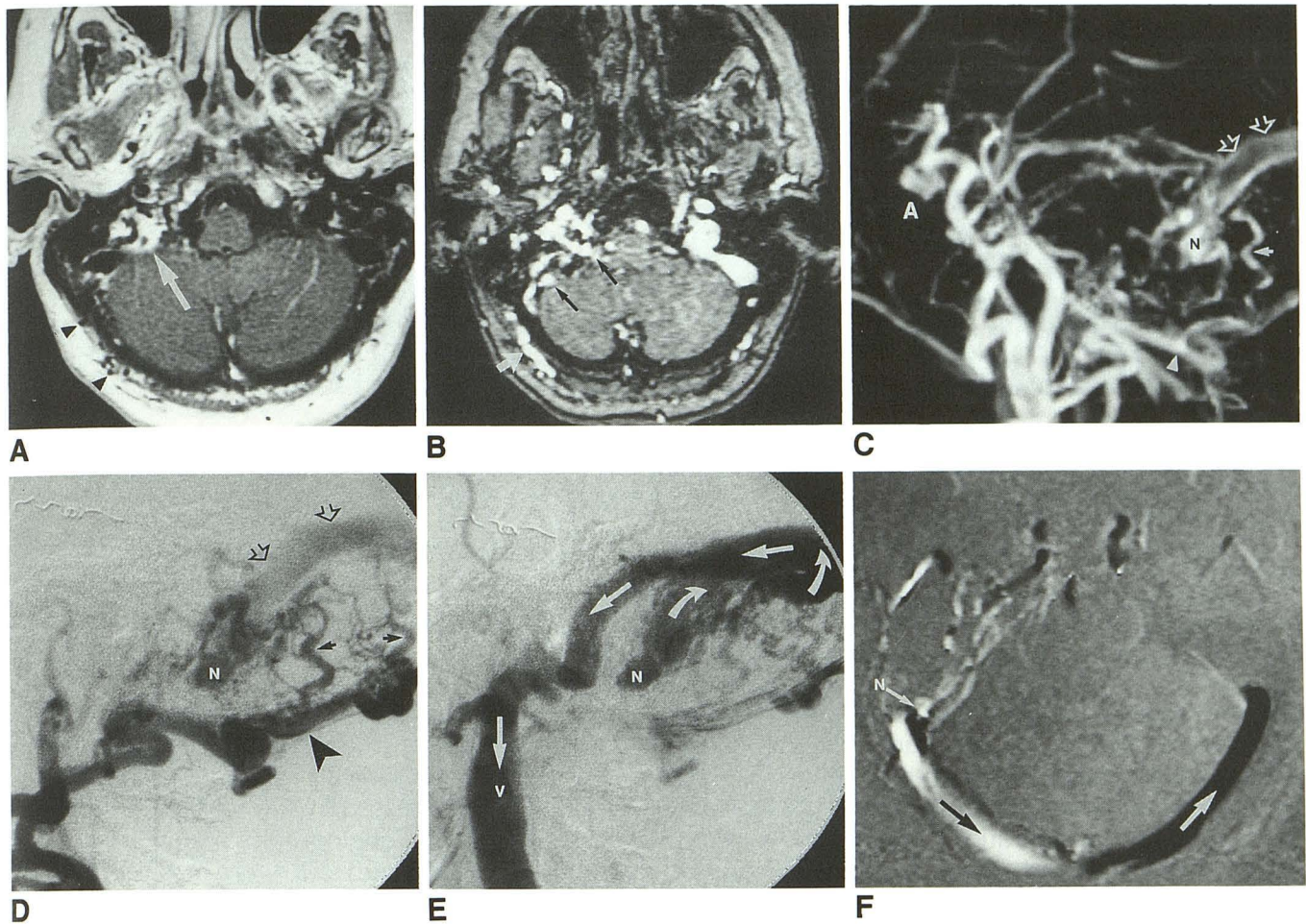


Fig. 1. Patient 43. Dural arteriovenous fistula.

A, Axial T1-weighted image with gadolinium shows abnormal enhancement within the right jugular foramen (arrow). This represents increased flow in the ipsilateral transverse sinus and foramen. Enlarged extracranial vessels are also seen (arrowheads).

B, Source image from multiple overlapped thin-slab acquisition MRA reveals prominent extracranial vessels (white arrow) and abnormal vascularity in the region of the sigmoid sinus and jugular foramen (arrows).

C, Volume of interest-limited lateral maximum-intensity projection reprojection shows a large occipital artery (arrowhead) which provides feeders (white arrow) to the nidus (N) of the AVF. The transverse sinus is shown by the open arrows. A indicates anterior.

D, Early phase of a right occipital artery (arrowhead) digital subtraction angiogram reveals similar features as C with feeders (black arrows), nidus (N), and transverse sinus (open arrows). Note the retrograde direction of sinus flow.

E, Later angiographic image from same study as D demonstrates retrograde venous flow (large arrows) from the nidus (N) to the contralateral internal jugular vein (V). No antegrade flow is seen in the ipsilateral sigmoid sinus.

F, Magnitude-corrected phase (flow-directional) image from axial 2-D phase-contrast MRA with anteroposterior directional flow encoding. Anterior-to-posterior flow is depicted in white (black arrow), and posterior-to-anterior flow is represented in black (white arrow). Image confirms the angiographic impression of venous flow to the contralateral side away from the AVF nidus (N).

Discussion

The complaint of pulsatile tinnitus is one of the more common reasons for imaging the area of the temporal bone. Statistically, the radiologist is in search of paraganglioma and dural AVF, although there are a number of other causes to be excluded, including nonsurgical normal vascular venous and arterial variants. The most recent imaging recommendations regarding modality of choice in this clinical setting include high-resolution CT with angiography serving an adjunctive

role unless objective tinnitus is present (1). MR was relegated to an ancillary position because of its historic inability to deal with the vascular causes of pulsatile tinnitus and its relative blindness in areas of high bone content such as the temporal bone.

In this report we attempt to evaluate the use of MR in evaluating patients with pulsatile tinnitus. Previous conclusions regarding the role of MR were based on standard spin-echo and gradient-echo MR imaging alone. MRA with its thin-

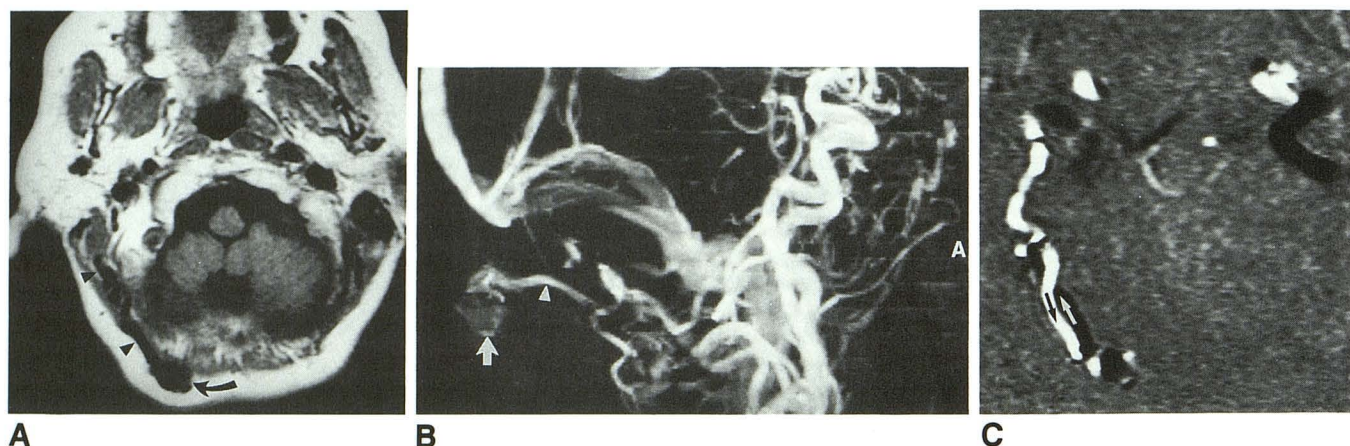

Fig. 2. Patient 27. Extracranial direct AVF with suboccipital varix.

A, T1-weighted axial image demonstrates flow void in the right suboccipital subcutaneous tissues (*curved arrow*). Enlarged vessels feeding and draining the lesion are also seen (*arrowheads*).

B, Maximum-intensity projection lateral reprojection better characterizes the varix location (*arrow*) and demonstrates arterial supply from the occipital artery (*arrowhead*). A indicates anterior.

C, Magnitude-corrected phase (flow-directional) image where anterior-to-posterior flow is seen in *white* and posterior-to-anterior flow is represented in *black*. In this case the white vessel (*black arrow*) is the feeding artery; the black vessel (*white arrow*) is the draining vein.

section source images and reprojected images was not available. Ideally, each patient in this study would have had high-resolution CT, MR with MRA, and cerebral angiography. Ethical and patient care considerations make this type of study design beyond reach. Our conclusions as they emerge in this discussion are necessarily drawn with care as a result.

Dural AVF and paraganglioma were the two most common lesions associated with pulsatile tinnitus identified in this study. Detection of dural AVF with MR is solely a function of MRA findings. Before MRA was available, the inability of MR to diagnose dural AVF excluded MR from use in patients with pulsatile tinnitus. MR findings associated with dural AVF included enlarged feeding and draining vessels found in conjunction with a vascular nidus and dural venous sinus abnormalities (Fig 1). The venous sinus abnormalities demonstrated are consistent with the theory that these lesions form as a sequel to trauma and/or thrombophlebitis of the venous sinus (12).

Prior studies have reported the visualization of dural AVF with MR and MRA (6, 13). The primary difficulty reported with MR evaluation of dural AVF is the detection of sinus occlusion. We found 2-D phase-contrast angiography helpful in defining abnormalities of the dural sinus. Directional flow images can demonstrate the presence of sinus occlusion and retrograde flow in the more proximal dural sinus (Fig 1). In this series we did not encounter a known situation in which a dural

AVF was diagnosed with angiography but not MRA. However, a small, strategically placed dural AVF could theoretically present with pulsatile tinnitus and be missed by MR with MRA. Because of this possibility, angiography should be pursued if results of MR with MRA are normal and the patient has either objective pulsatile tinnitus or a compelling clinical story with subjective pulsatile tinnitus.

Other arteriovenous lesions seen in this study included extracranial AVF and pial AVM. Extracranial AVF did not present a clinical or radiologic diagnostic problem. Enlarged arterial and venous structures were appreciated on MR and MRA in all patients. The site of fistula communication was visualized with MRA (Fig 2). Pial AVM, although an uncommon cause of pulsatile tinnitus, is readily identified on both MR and MRA (14). The vascular supply is better defined with MRA, however.

Paraganglioma, glomus jugulare, jugulotympanicum, or tympanicum was the second most common lesion identified in this study. Glomus jugulotympanicum and tympanicum present with both pulsatile tinnitus and a vascular-appearing retrotympanic mass. High-resolution CT has previously served as the test of choice in evaluating paraganglioma because of its ability to identify the soft-tissue mass and the bony changes in the temporal bone and jugular foramen region (5). Standard thin-section T1 postgadolinium axial and coronal MR images best delineated the size

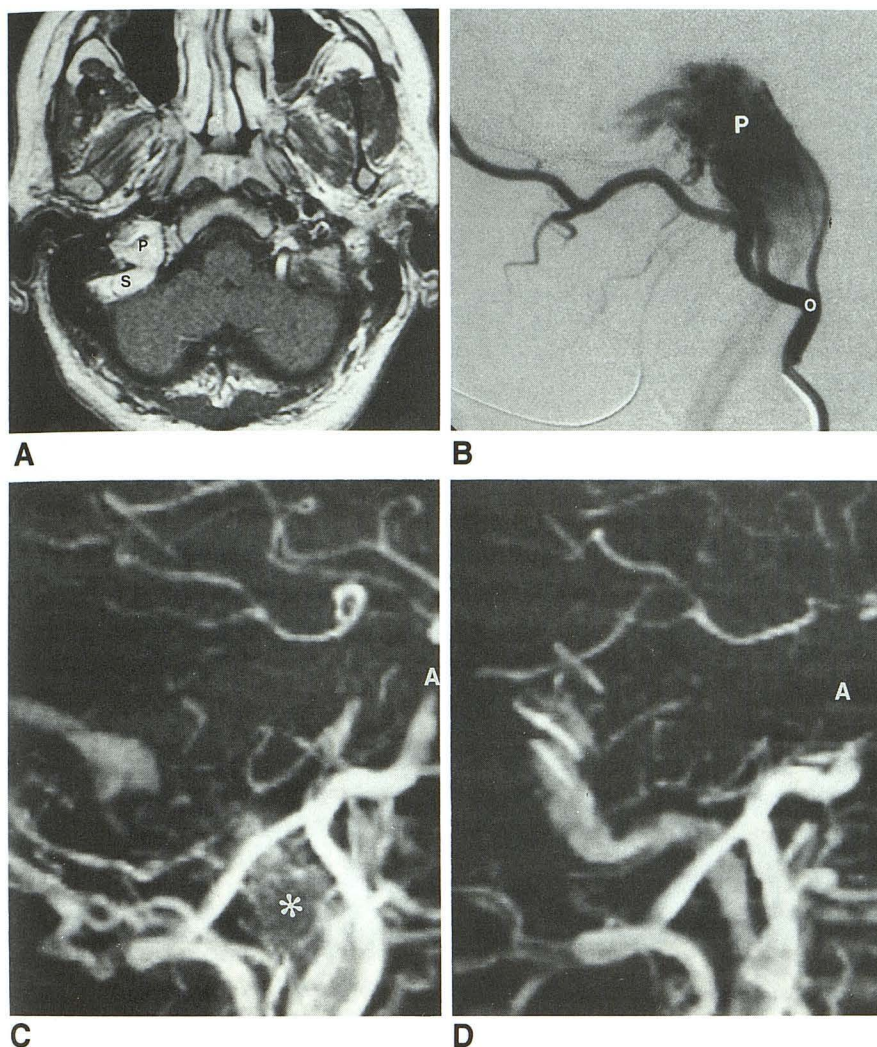


Fig. 3. Patient 29. Glomus jugulotympanicum.

A, Axial contrast-enhanced T1-weighted image shows an enhancing right jugular foramen mass (P). The sigmoid sinus (S) posteriorly abuts the mass.

B, Lateral projection digital subtraction angiogram of the right occipital artery (O) shows an enhancing mass in the jugular foramen consistent with paraganglioma (P).

C, Volume of interest-limited maximum-intensity projection reconstruction of the region of the right jugular foramen (lateral reprojection) shows abnormal signal from the region of the jugular bulb (*), thought to represent the vascular channels within this tumor. A indicates anterior.

D, Maximum-intensity projection reconstruction in lateral projection of the normal left jugular foramen is provided for comparison.

and extent of the paraganglioma. If the lesion extends into a region of adjacent marrow or soft fat, fat-saturation T1 techniques can be useful. MRA typically did not aid in the diagnosis, although a characteristic pattern of abnormal signal was appreciated in several cases (Fig. 3).

Arterial lesions associated with pulsatile tinnitus include internal carotid artery stenosis, ectasia, aberrant internal carotid artery, aneurysm of the petrous internal carotid artery, and fibromuscular dysplasia (3, 4). Pulsatile tinnitus related to this group of arterial lesions probably occurs as a result of marked turbulence and change in velocity of blood flow in the petrous internal carotid artery secondary to vessel caliber change near the skull base. In some patients, however, the vascular noise may be the result of increased blood flow in the ascending pharyngeal artery. Standard MR is unable to detect these lesions. Only MRA can indicate these diagnoses.

The lack of fibromuscular dysplasia cases in our series either means we are insensitive to this lesion or that our series is too small to have seen a case. Although others have reported identifying fibromuscular dysplasia with MR and MRA (15), the sensitivity of MRA to this lesion has yet to be determined. Subtle or strategically placed stenotic vascular lesions may represent another reason to pursue angiography in patients with pulsatile tinnitus and normal MR with MRA.

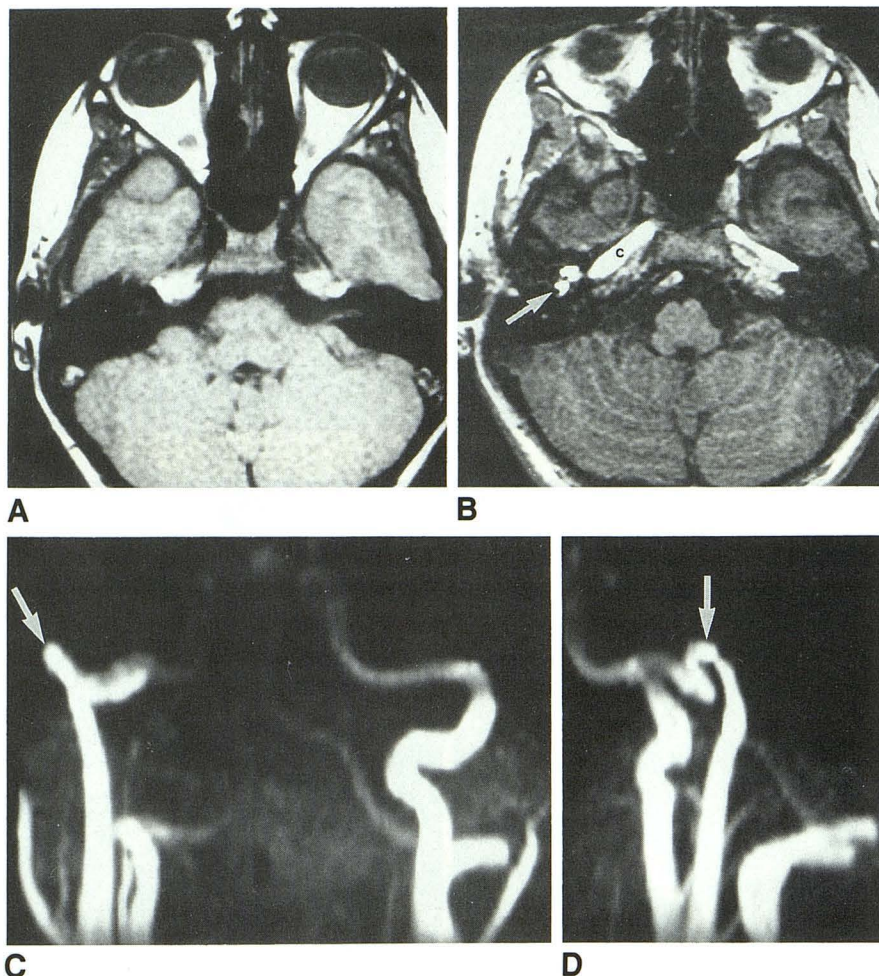
Aberrant internal carotid artery is an important lesion to recognize because of its clinical presentation as a vascular retrotympanic mass. If not recognized, biopsy can result in disastrous sequelae. There is a typical high and posterior course to the aberrant vessel (3), giving a figure-7 appearance on anteroposterior images. This is readily seen on MRA reprojections, and examination of the source images shows the typical course of the artery posterior to the middle ear at its entry

Fig. 4. Patient 1. Aberrant internal carotid artery.

A, Axial T1-weighted image through the midtemporal bone level reveals no evidence for the aberrant internal carotid artery because of the lack of signal seen with both bone and rapidly flowing blood on standard T1-weighted MR images (from Davis and Harnsberger [16]).

B, Source image from the MRA sequence shows high signal in the posterolateral aspect of the aberrant artery (arrow). C indicates flow in horizontal portion of the petrous internal carotid artery.

C and D, 3-D time-of-flight MRA demonstrates the characteristic angiographic appearance of an aberrant internal carotid artery on the right in anteroposterior (C) and lateral (D) projections (arrows).



to the skull base (Fig 4).

The venous variants associated with the jugular bulb (high jugular bulb, dehiscant jugular bulb, and jugular bulb diverticulum) may be associated with pulsatile tinnitus. The jugular bulb is defined as high when it extends above the level of the external auditory canal on axial imaging. It is considered dehiscant when the bony plate separating the bulb from the middle ear cavity is partially or totally absent (1). Although MR and MRA do not directly show the thin bony plate, dehiscence may be suggested from the configuration of the bulb. In addition, otoscopy should demonstrate a vascular-appearing retrotympenic mass. In theory, a dehiscant jugular bulb with turbulent flow could mimic a paraganglioma on MR. However, examination of the MRA source images in combination with the final reprojected images should allow discrimination between these lesions. Specifically, the flowing blood in the jugular bulb will give high signal on the MRA source images, whereas a paraganglioma will not.

Temporal bone CT may also serve a confirmatory role and should be used in difficult or confusing cases.

Stenosis of the transverse venous sinus was demonstrated as a cause of pulsatile tinnitus by both MRA and conventional angiography in one of our patients (Fig 5) and by MRA alone in another. Neither patient had debilitating pulsatile tinnitus requiring surgical or endovascular therapy, so it is not possible for us to assess the true relationship of these lesions to the patient's pulsatile sound.

Although this study was not specifically designed to evaluate an imaging protocol, there are a number of general suggestions that can be made. The imaging protocol used in an individual patient should be tailored to the patient's clinical presentation and prior radiologic findings. In patients with cervical bruit, attention to the cervical vessels is emphasized, whereas the presence of a vascular retrotympenic mass directs imaging to the temporal bone and may obviate the need for

cervical MRA. Gadolinium-enhanced spin-echo imaging is of little utility in a patient in whom a vascular lesion (ie, AVF or intrinsic arterial or venous disease) is found on MRA. Patients with subjective pulsatile tinnitus and a normal tympanic membrane usually require complete evaluation, however.

The addition of MRA to conventional MR greatly enhances the ability of this modality to show vascular lesions. The 18% of lesions that were best demonstrated on spin-echo MR is our cohort of paragangliomas, whereas vascular lesions of all types were better demonstrated with MRA. And in 37% of lesions, the lesion was demonstrated only on MRA. At the very least, MRA has made it possible to consider MR with MRA as an effective tool in the evaluation of patients with pulsatile tinnitus.

Summary

MR with MRA is able to detect the spectrum of lesions associated with pulsatile tinnitus. MRA adds considerable information to that provided by spin-echo MR and was necessary or helpful in determining the cause of pulsatile tinnitus in the majority of our patients. Based on our experience with 49 patients presenting with pulsatile tinnitus, we recommend MR with MRA be considered as the first radiologic test ordered in patients with pulsatile tinnitus. Although we feel that MR with MRA is all the imaging needed in most patients, angiography should still be used in patients with troublesome pulsatile tinnitus (either subjective or objective) and normal MR with MRA.

References

- Remley KB, Coit WE, Harnsberger HR, et al. Pulsatile tinnitus and the vascular tympanic membrane: CT, MR, and angiographic findings. *Radiology* 1990;174:383-389
- Remley KB, Harnsberger HR, Jacobs JM, Smoker WRK. The radiologic evaluation of pulsatile tinnitus and the vascular tympanic membrane. *Semin Ultrasound CT MR* 1989;10:236-250
- Lo, WM. Vascular tinnitus. In: Som PM, Bergeson RT, eds. *Head and neck imaging*. St Louis: Mosby-Year Book, 1991:1108-1115
- Swartz JD, Harnsberger HR. *Imaging of the temporal bone*. New York: Thieme, 1992:154-191
- Olsen WL, Dillon WP, Kelly WM, Norman D, Brant-Zawadski M, Newton TH. MR imaging of paragangliomas. *AJNR Am J Neuroradiol* 1986;7:1039-1042
- Chen JC, Tsuruda JS, Halbach VV. Suspected dural arteriovenous fistula: results with screening MR angiography in seven patients. *Radiology* 1992;183:265-271
- Blatter DD, Parker DL, Robinson RO. Cerebral MR angiography with multiple overlapping thin slab acquisition, I: quantitative analysis of vessel visibility. *Radiology* 1991;179:805-811

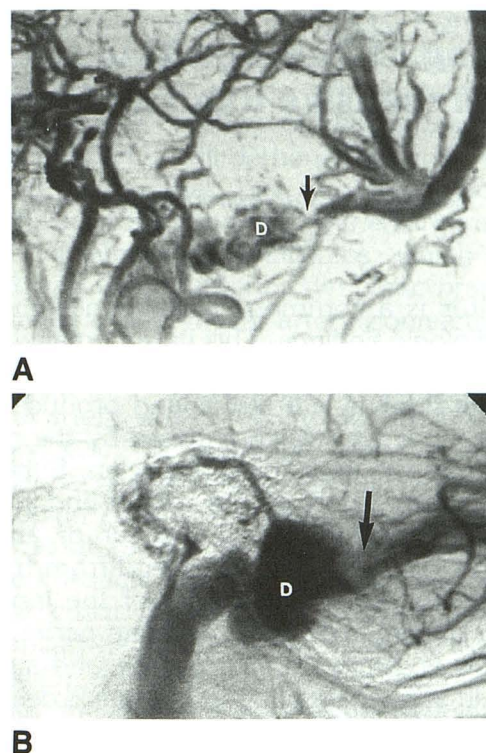


Fig. 5. Patient 14. Transverse sinus stenosis.

A, Volume of interest-limited maximum-intensity projection reconstruction from MRA (multiple overlapped thin-slab acquisition MRA) demonstrates focal narrowing of the right transverse sinus (arrow) with poststenotic dilatation (D) in this patient with right pulsatile tinnitus. There was no flow in the left transverse sinus.

B, Lateral projection from a digital angiogram shows identical findings in the venous phase.

- Parker DL, Yuan C, Blatter DD. MR angiography by multiple thin slab 3D acquisition. *Magn Reson Med* 1991;17:434-451
- Turski P, Korosec F, Turski D, Bernstein M, Weber D, Mistretta C. Phase contrast MRA directional flow imaging of the circle of Willis: normal and pathologic conditions (abstr). *Invest Radiol* 1991;26:1137
- Marks M, Pelc N, Ross M, Enzmann D. Determination of cerebral blood flow with a phase contrast cine MR technique: evaluation of normal subjects and patients with arteriovenous malformations. *Radiology* 1992;182:467-476
- Vogl T, Bruning R, Schedel H, et al. Paragangliomas of the jugular bulb and carotid body: MR imaging with short sequences and Gd-DTPA enhancement. *AJNR Am J Neuroradiol* 1989;10:823-827
- Pierot L, Chiras J, Meder J-M, Rose M, Rivierez M, Marsault C. Dural arteriovenous fistulas of the posterior fossa draining into subarachnoid veins. *AJNR Am J Neuroradiol* 1992;13:315-323
- De Marco JK, Dillon WP, Halbach VV, Tsuruda JS. Dural arteriovenous fistulas: evaluation with MR imaging. *Radiology* 1990;175:193-199
- Blatter DD, Parker DL, Ahn SS, et al. Cerebral MR angiography with multiple overlapping thin slab acquisition, II: early clinical experience. *Radiology* 1992;183:379-389
- Heiserman JE, Drayer BP, Fram EK, Keller PJ. MR angiography of cervical fibromuscular dysplasia. *AJNR Am J Neuroradiol* 1992;13:1454-1457
- Davis WL, Harnsberger HR. Magnetic resonance imaging of an aberrant internal carotid artery. *AJNR Am J Neuroradiol* 1991;12:1225