

Generic Contrast Agents

Our portfolio is growing to serve you better. Now you have a *choice*.



FRESENIUS
KABI

[VIEW CATALOG](#)

AJNR

Hyperperfusion of ictal seizure focus demonstrated by MR perfusion imaging.

S Warach, J M Levin, D L Schomer, B L Holman and R R
Edelman

AJNR Am J Neuroradiol 1994, 15 (5) 965-968

<http://www.ajnr.org/content/15/5/965>

This information is current as
of May 27, 2025.

Hyperperfusion of Ictal Seizure Focus Demonstrated by MR Perfusion Imaging

S. Warach, J. M. Levin, D. L. Schomer, B. L. Holman, and R. R. Edelman

Summary: MR using a susceptibility-weighted sequence and dynamic contrast enhancement with gadolinium demonstrated relative hyperperfusion of the right temporoparietal cortex in a patient in focal status epilepticus. A single-photon emission CT (SPECT) scan also demonstrated hyperperfusion of the right temporoparietal cortex. Perfusion MR, SPECT, and electroencephalogram normalized when the seizures ended.

Index terms: Seizures; Magnetic resonance, technique; Brain, magnetic resonance

Neuroimaging techniques are useful aids in the diagnosis of epilepsy. Positron emission tomography identifies seizure foci as ictal increases in glucose metabolism and cerebral blood flow and interictal decreases in these measures (1,2). Similar changes in cerebral blood flow are detectable by single-photon emission computed tomography (SPECT) (3,4). Because magnetic resonance (MR) is part of the standard diagnostic workup of patients with seizure disorders, it would be advantageous to have an MR method to identify seizure foci by alterations in cerebral function. We report such a method.

Materials and Methods

MR

Conventional spin-echo T1- and T2-weighted images in the axial plane were obtained. Cerebral blood volume imaging was performed on a 1.5-T whole-body clinical imager with standard hardware by a technique previously described (5). With T2* weighting obtained using a gradient-echo pulse sequence with a long echo time, one can measure the susceptibility effects of the passage of gadolinium on the brain (6). A spoiled fast low-angle shot sequence was used with parameters of 35/25/1 (repetition time/echo time/excitations), flip angle of 10 degrees, section thickness of 8 mm, acquisition matrix of 256×80

(interpolated to 256×256), and rectangular field of view of 30×22.5 cm. Scan time per image was 2.8 seconds, with no interscan delay; 25 images were acquired. After approximately four images were obtained, 20 cc of gadopentetate dimeglumine (469 mg/cc) were administered into an antecubital vein over approximately 5 seconds, followed by a saline flush.

Dynamic MR images were acquired at a single axial section location corresponding to the level of most prominent abnormality on the SPECT. The section orientation differed slightly between the studies, but the areas of temporoparietal cortex under study were comparable. For quantitative analysis, the target region for analysis was the gray matter region of greatest signal decrease on T2*-weighted images. A region of interest of 16 pixels was placed over the right parietal cortex on the localizing T1- and T2-weighted images to assure that placement of the region of interest avoided sulci, medium- to large-size blood vessels, and areas of abnormal signal on T2-weighted images. The region was then transferred onto the enhanced images.

$\Delta R2^*$ was computed as previously described (7). For each region of interest, relative blood volume was estimated by the area under the curve for the T2* rate change ($\int \Delta R2^* dt$), taken as the sum of the $\Delta R2^*$ values of the first pass of the gadolinium-DTPA over the first eight images after the appearance of contrast, approximately 22.5 seconds. Data analysis was limited to this time period to avoid the effect of recirculation or the second pass of contrast through the brain, which was determined by the signal intensity versus time and $\Delta R2^*$ versus time curves (*vertical line* in Fig 2A).

SPECT

SPECT imaging was obtained using an annular single-crystal brain camera and 20 mCi of the brain perfusion tracer technetium-99m-labeled hexamethyl-propyleneamine oxime (8). SPECT was performed in the ictal state and repeated 13 days later.

Received April 27, 1993; accepted pending revision June 28; revision received August 9.

From the Departments of Neurology (S.W., D.L.S.) and Radiology (S.W., R.R.E.), Harvard Medical School, Beth Israel Hospital, Boston, Mass; and the Department of Radiology, Harvard Medical School, Brigham and Women's Hospital (J.M.L., B.L.H.), Boston, Mass.

Address reprint requests to Steven Warach, MD, PhD, Department of Neurology, Harvard Medical School, Beth Israel Hospital, 330 Brookline Ave, Boston, MA 02215.

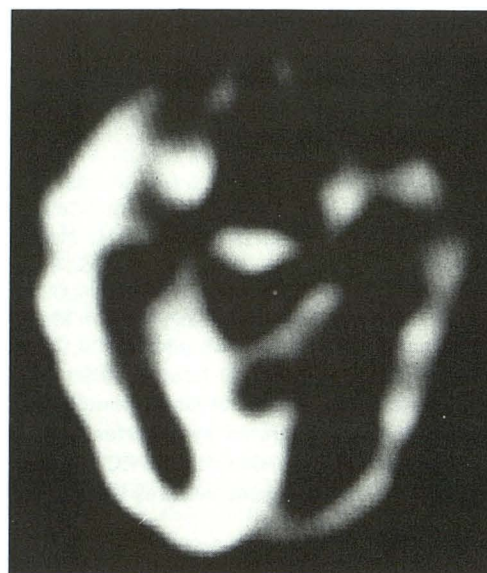AJNR 15:965-968, May 1994 0195-6108/94/1505-0965 © American Society of Neuroradiology

Results

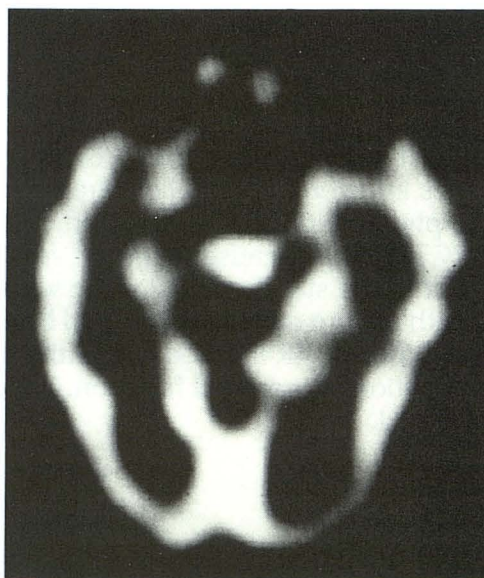The patient was a 41-year-old man who had had a partial resection of a medulloblastoma, followed by whole brain irradiation and chemotherapy. He presented with focal status epilepticus, characterized by left visual field hemianopsia and visual hallucinations with left body convulsions. He was studied with MR, SPECT, and electroencephalography during a 3-day period in which he exhibited continuous seizure activity and approximately 2 weeks later when clinical seizures had stopped. T1- and T2-weighted images showed mildly dilated ventricles; extensive, abnormally increased periventricular signal in T2-weighted images; and increased signal intensity in T2-weighted images in the right cerebellar hemisphere and pons.

The initial electroencephalogram showed rhythmic sharp activity consistent with epileptic discharge of the right central and posterior temporal regions. A brain SPECT scan performed at that time showed marked hyperperfusion of the right temporoparietooccipital area (Fig 1A). The number of counts over the right parietal cortex was 50.7% higher than that over the left. An electroencephalogram performed 16 days later showed focal slow-wave activity over the right hemisphere, suggesting a structural lesion, without evidence of ongoing epileptic activity; a follow-up SPECT scan showed resolution of the right hemispheric hyperperfusion (Fig 1B) with relatively symmetric perfusion (right counts 6.2% higher).

Blood volume imaging with MR while the patient exhibited seizure behavior (left visual field hallucinations) demonstrated markedly increased relative blood volume in the right temporoparietal region. Figure 2A illustrates the time curve of the signal change for a region of interest in the right and left parietal cortex. Note the greater decrease in signal intensity for each time point in the right versus the left hemisphere. The time to maximal signal drop is within the same 2.8-second time period. The $\int \Delta R2^* dt$ for the first 22.5 seconds after the appearance of contrast was 0.088 for the right parietal cortex and 0.046 for the left (91% higher on the right). Figure 2B shows increased blood volume in the right temporoparietal cortex similar to the initial SPECT hyperperfusion. After the hallucinations had stopped, the electroencephalogram showed no further seizure activity, and the SPECT had become symmetric, MR showed relatively symmetric blood volume



A



B

Fig. 1. Perfusion SPECT.

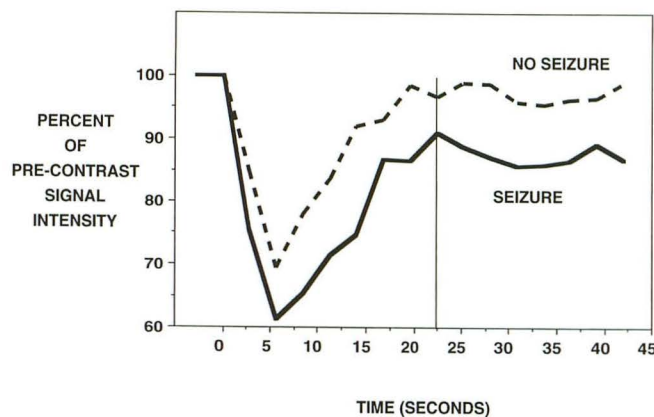
A, Ictal. Hyperperfusion throughout the right temporal, parietal, and occipital cortices.

B, Thirteen days later, perfusion is relatively symmetric.

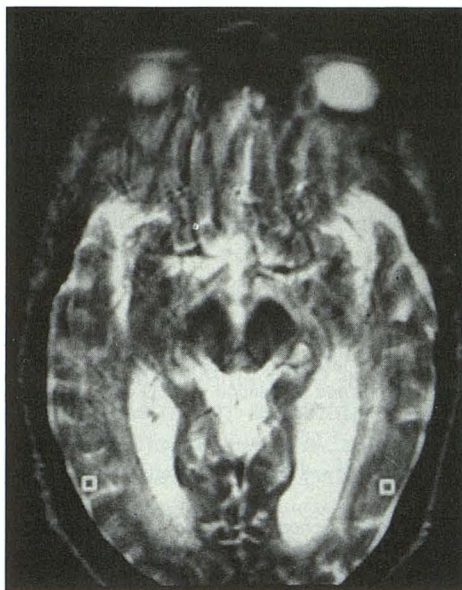(Fig 2C). The $\int \Delta R2^* dt$ for this study was 0.041 for the right parietal cortex and 0.036 for the left.

Discussion

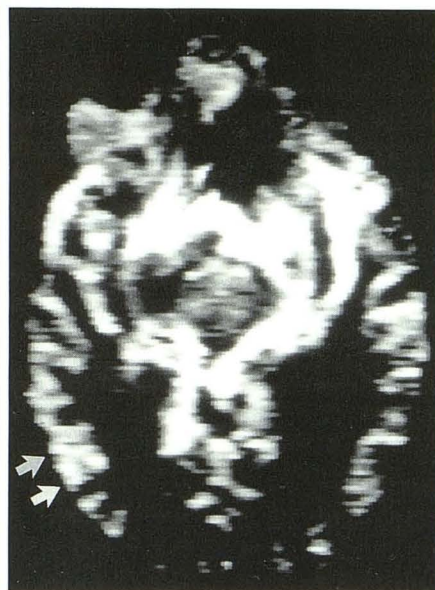We demonstrated that regional hyperperfusion during focal status epilepticus can be identified using a functional MR technique. The concordance of the MR results with electroencephalogram, SPECT, and neurologic signs during two different clinical states supports the conclusion. Furthermore, $\int \Delta R2^* dt$ for the hyperperfused



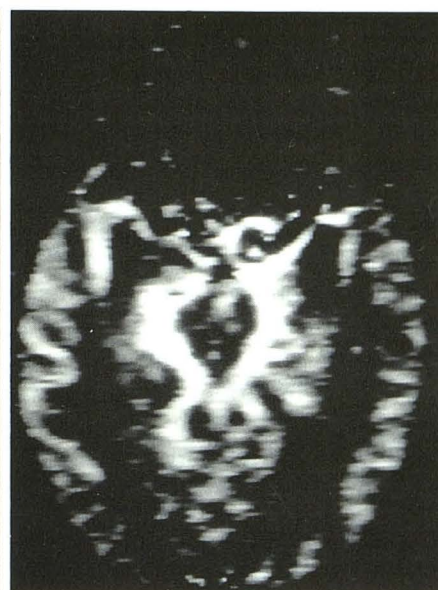A



B



C



D

Fig. 2. MR blood volume imaging.

A, Percentage of precontrast signal intensity versus time curve for ictal MR perfusion scan. Values are taken from a region of interest centered over the region of greatest signal change in the right parietal cortex (*solid line* labeled seizure) and over the comparable region of the left hemisphere (*dashed line* labeled no seizure). Greater relative blood volume at each time point for the right parietal cortex is evident from the greater signal change from baseline at each time point.

B, Quantitative analysis. Axial T2-weighted images through the level of perfusion study. Square regions of interest of 16 pixels overlaid areas measured from perfusion images, graphed in A.

C, Ictal perfusion MR, subtracting the image at peak enhancement from the image before enhancement. The signal is greatest in and around large blood vessels around basal cisterns, Sylvian fissures, and other large sulci. An apparent high signal change in the left anterior temporal cortex is attributable to signal from large vessels in sulci, not from parenchyma. The *arrow* points to the focus of greatest blood volume within the brain parenchyma. The $\int \Delta R2^* dt$ for this region over 22.5 seconds is 0.088; for the corresponding region of the left hemisphere, it is 0.041.

D, Sixteen days later, perfusion MR indicates symmetric blood volumes. The $\int \Delta R2^* dt$ for the right parietal cortex is 0.046; that for the left is 0.036.

right parietal cortex was 91% greater than that for the left, and $\int \Delta R2^* dt$ for the left parietal cortex during the seizure and that for both left and right cortices 13 days later were close to the mean values for normal cortex previously published using this technique (5,9).

Although cerebral blood flow is not measured with this method, information about relative cerebral blood flow can, under certain conditions, be inferred. MR signal intensity over time is used to calculate the parameter $\int \Delta R2^* dt$, which has been shown to be proportional to cerebral blood vol-

ume in healthy brain tissue (7). Because cerebral blood flow equals the ratio of cerebral blood volume to mean transit time for intravascular tracers, it may be deduced that cerebral blood flow was increased in the seizure focus, because the estimate of mean transit time (indirectly related to the time to maximum decrease in signal) was the same for both ictal and control regions. It must be emphasized that absolute cerebral blood flow cannot be computed with this technique, nor can an absolute determination of mean transit time, because these are not directly related to the concentration time curve of contrast, but also depend on the topology of the cortical vasculature, which is not known (10); however, relative differences in flow between comparable regions can be estimated. Using the same technique, the mean \pm standard deviation of $\int \Delta R2^* dt$ in cerebrocortical gray matter was 0.036 ± 0.016 for a sample of 10 patients with no brain lesion (5) and 0.041 ± 0.027 for control regions in 12 patients with acute infarcts (9). Thus, the ictal control region and both regions when this patient was not having a seizure had the $\int \Delta R2^* dt$ expected for normal brain perfusion.

This technique has no special hardware requirements and may be used with any standard 1.5-T clinical imaging system in the same imaging session as routine imaging, without moving the patient. Although imaging a patient during a seizure is rare and typically impractical, this unusual case illustrates that abnormal cerebral perfusion in epilepsy can be demonstrated by MR. Unpublished observations suggest that interictal focal hypoperfusion is also detectable with MR blood volume imaging. The technique has the advantage of permitting direct comparison to an anatomic image, making the location of perfusion abnormalities certain while avoiding cross-registration errors, assuming patient motion is eliminated or controlled. An improved signal-to-noise ratio would make the technique more sensitive to subtler changes in perfusion. Variability in results between measurements in a single subject may be expected based on variability in the manual injection or on patient motion. These shortcomings would not account for the regional differences found within the brain on a single study or for the change in regional differences between studies that has been observed here. As applied here, the technique was limited to a single imaging section. Newer techniques, such as echo-planar imaging, which at present require special hardware not yet widely available, should allow

multisection multiplanar perfusion imaging with temporal resolution of less than 1 second and greater signal change to noise, thus increasing the sensitivity of the technique to detect areas of abnormal perfusion. Newer MR techniques to observe regional perfusion differences based on endogenous susceptibility contrast (11) may also be sensitive to seizure-related changes and would permit serial studies over time.

The results in this case are consistent with the results of positron emission tomography and SPECT studies demonstrating ictal increases in cerebral blood flow. A recent report of induced seizures after electrical stimulation with depth electrodes found increases in local cerebral blood flow that returned to baseline after the electrical discharges, as measured with xenon computed tomography (12). A systematic comparison of MR perfusion techniques with results from other physiologic studies of seizure foci will be needed to define its possible future role in the diagnosis of epilepsy.

References

- Engel J, Kuhl DE, Phelps ME, Mazziotta JC. Interictal cerebral glucose metabolism in partial epilepsy and its relation to EEG changes. *Ann Neurol* 1982;12:510-517.
- Theodore WH, Katz D, Kufta C, et al. Pathology of temporal lobe foci: correlation with CT, MRI, and PET. *Neurology* 1990;40:797-803.
- Magistretti P, Uren P, Blume H, Schomer D, Royal H. Delineation of epileptic focus by single photon emission tomography. *Eur J Nucl Med* 1982;7:484-485.
- Marks DA, Katz A, Hoffer P, Spencer SS. Localization of extratemporal epileptic foci during ictal single photon emission computed tomography. *Ann Neurol* 1992;31:250-255.
- Edelman RR, Mattle HP, Atkinson DJ, et al. Cerebral blood flow: assessment with dynamic contrast-enhanced T2*-weighted MR imaging at 1.5T. *Radiology* 1990;176:211-220.
- Villringer A, Rosen BR, Belliveau JW, et al. Dynamic imaging with lanthanide chelates in normal brain: contrast due to magnetic susceptibility effects. *Magn Reson Med* 1988;6:164-174.
- Rosen BR, Belliveau JW, Chien D. Perfusion imaging by nuclear magnetic resonance. *Magn Reson Q* 1989;5:263-281.
- Holman BL, Carvalho PA, Zimmerman RE, et al. Brain perfusion SPECT using an annular single crystal camera: initial clinical experience. *J Nucl Med* 1990;31:1456-1561.
- Warach S, Li W, Ronthal M, Edelman RR. Evaluation of acute cerebral ischemia using dynamic contrast-enhanced MR and MR angiography. *Radiology* 1992;182:41-47.
- Weisskoff RM, Chesler D, Boxerman JL, Rosen BR. Pitfalls in MR measurement of tissue blood flow with intravascular tracers: which mean transit time? *Magn Reson Med* 1993;29:553-558.
- Kwong K, Belliveau JW, Chesler DA, et al. Dynamic magnetic resonance imaging of human brain activity during primary sensory stimulation. *Proc Natl Acad Sci USA* 1992;89:5675-5679.
- Johnson DW, Hogg JP, Dasheiff R, Yonas H, Pentheny S, Juma-as A. Xenon/CT cerebral blood flow studies during continuous depth electrode monitoring in epilepsy patients. *AJNR Am J Neuroradiol* 1993;14:245-252.