



## Discover Generics

Cost-Effective CT & MRI Contrast Agents

 FRESENIUS  
KABI

[WATCH VIDEO](#)

# AJNR

## **Paradoxical ventricular enlargement after successful shunting.**

C P Russo, L Hochhauser and J A Winfield

*AJNR Am J Neuroradiol* 1994, 15 (6) 1034-1036

<http://www.ajnr.org/content/15/6/1034>

This information is current as  
of June 1, 2025.

# Paradoxical Ventricular Enlargement after Successful Shunting

Craig P. Russo, Leo Hochhauser, and Jeffrey A. Winfield

**Summary:** We present two cases of ventricular obstruction in which shunting of intracranial cysts resulted in the unexpected finding of ventricular enlargement. By imaging criteria this suggested shunt malformation; however, the clinical presentation dramatically improved. The probable mechanism for this diagnostic pitfall is discussed.

**Index terms:** Brain, ventricles; Brain, cysts; Shunts, ventriculoperitoneal; Pediatric neuroradiology

Shunting procedures can alter the appearance of intracranial cysts, leading to confusion in diagnosis (1). Even with successful cyst decompression, cerebrospinal fluid (CSF) dynamics may not be readily predictable. We encountered the unexpected computed tomography (CT) appearance of ventricular enlargement after shunting.

## Case Reports

### Case 1

K.M., a preterm girl born at 29 weeks of gestation (weight 1250 g) had congenital cytomegalovirus infection and suffered a grade-IV intraventricular hemorrhage on day 2 of life, requiring ventriculoperitoneal shunt placement 2 weeks postpartum. She had shunt infection and meningitis at 14 months of age. CT scan showed an isolated fourth ventricle filling the posterior fossa (Fig 1A) with upward herniation through the tentorial notch (Fig 1B). Both lateral ventricles were almost completely collapsed, yet the shunt pumped and filled well and the anterior fontanel was soft. After antibiotic treatment for gram-negative shunt infection, a cyst-peritoneal shunt was placed to decompress the trapped fourth ventricle. CT showed a decrease in size of the isolated fourth ventricle yet enlargement of both lateral ventricles (Fig 1C). Her neurologic symptoms had improved with an increase in spontaneous activity, the CSF pressures in both shunts were low, and the child was discharged.

### Case 2

A.A. was a preterm girl born at 25 weeks of gestation by cesarean section for fetal distress. She had a grade-IV intraventricular hemorrhage and required a ventriculoperitoneal shunt at 3 months and a shunt revision at 7 months of age. She suffered a prolonged generalized seizure with respiratory distress at 32 months of age. At that time the ventriculoperitoneal shunt was functioning well, and there was no evidence of infection. She recovered without further complication. A magnetic resonance study revealed a Dandy-Walker malformation with a large posterior fossa cyst and hypoplastic cerebellar tissue. Also identified were multiple supratentorial intraventricular cysts suggesting a postinflammatory compartmentalization syndrome. A CT ventriculogram showed opacification of the frontal horns and the third ventricle (Fig 2A); there was no communication with the large cysts. During supratentorial cyst drainage several loculated fluid collections were partially removed. Lysis of the adhesions and membranes reestablished CSF communication. The postoperative CT study showed increase in transverse diameter of the third ventricle and expansion of both lateral ventricles (Fig 2, B and C).

## Discussion

Encystment of a portion of the ventricular system is a well-documented complication of intraventricular hemorrhage or infection (3). The accumulation of CSF in a sequestered portion of the ventricle may cause cystlike enlargement of this isolated space and result in blockage of the CSF drainage pathways (5). After decompression of the cysts either the brain or the subarachnoid spaces including the ventricles must resume a new configuration to compensate for the volume loss. Upward herniation of posterior fossa cysts is a well-recognized complication of selective shunting of the lateral ventricles for treatment of these cysts (2, 6–8) and commonly occurs in cases of acquired aqueductal stenosis.

Received March 30, 1992; accepted pending revision May 26; revision received January 5, 1993.

From the Department of Radiology, Section of Neuroradiology (C.P.R., L.H.), and Department of Neurosurgery (J.A.W.), State University of New York, Syracuse.

Address reprint requests to Craig P. Russo, MD, Department of Radiology, University Hospital, 750 E Adams St, Syracuse, NY 13210.

AJNR 15:1034-1036, Jun 1994 0195-6108/94/1506-1034 © American Society of Neuroradiology



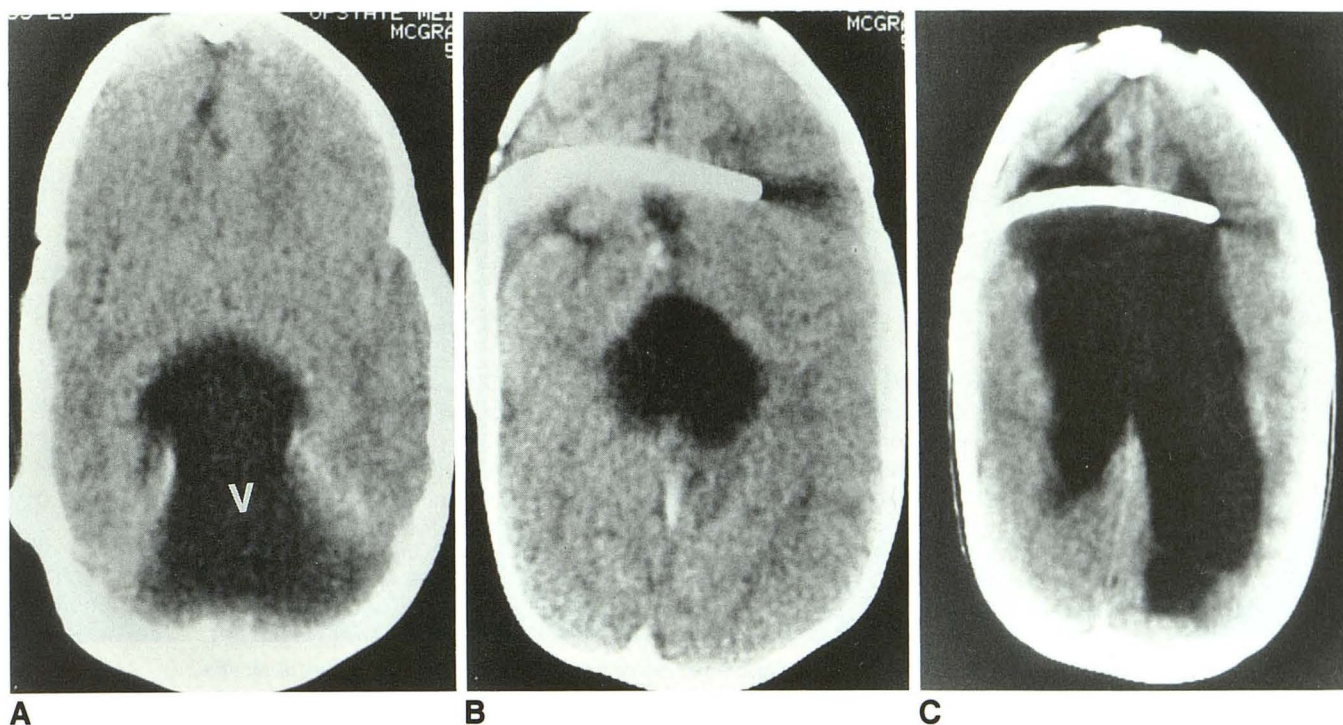


Fig. 1. Trapped fourth ventricle (case 1). CT scans show the keyhole appearance of an encysted fourth ventricle (v) which occupies the entire posterior fossa and protrudes superiorly through the tentorial notch (A). It compresses the lateral ventricles (B) causing the CSF in the compressed lateral ventricles to escape through a patent shunt, resulting in ventricular collapse or overshunting. After cyst-peritoneal shunting, the encysted fourth ventricle has been effectively decompressed. Once the pressure on the lateral ventricles was reduced, they had expanded beyond the expected size (C) erroneously suggesting shunt obstruction by CT criteria while clinically the patient was doing well.

In case 1, the preoperative CT scan shows collapsed lateral ventricles with a large posterior fossa cyst herniating superiorly through the tentorial hiatus (Fig 1, A and B). Excess drainage of CSF through the ventriculoperitoneal shunt may have allowed the lateral ventricles to collapse. The resulting decrease in supratentorial volume and pressure would then facilitate expansion and upward herniation of the posterior fossa cyst. Once the posterior fossa cyst was shunted and decreased in size, the pressure exerted on the supratentorial CSF compartment was relieved, and the lateral ventricles reexpanded (Fig 1C) to the baseline dilatation appropriate for this child with marked cerebral atrophy. It appears that the ventricular shunt was initially decompressing and compensating for the mass effect caused by the expanding posterior fossa volume. With a ventriculoperitoneal shunt tube in place, the lateral ventricles could readily accommodate the increased volume from the expanding cyst. When the mass effect by the posterior fossa cyst was relieved after cystoperitoneal shunting, the CSF pressures were found to be normal in both com-

partments, thus indicating that there was no shunt failure.

In case 2, the patient demonstrated features typical of Dandy-Walker malformation and developed several sequestered, fluid-filled loculations within the supratentorial ventricular system. The transtentorial upward herniation of the trapped fourth ventricle contributed to the excessive supratentorial pressure similar to case 1. As expected, shunting of the loculated lateral ventricles decreased the size of the previously sequestered CSF space. It was not expected, however, that the frontal horns of the lateral ventricles would appear larger after surgery. The most likely explanation for the enlargement after cyst shunting is that preexisting cerebral atrophy was unmasked with decompression of the supratentorial compartment.

These two cases show that volume which had been occupied by enlarged intracranial cysts was gained at the expense of volume normally occupied by the lateral ventricles. As the expanded cysts were decompressed and decreased in size, the lateral ventricles reexpanded to fill the volume previously occupied by the cyst, thus maintaining



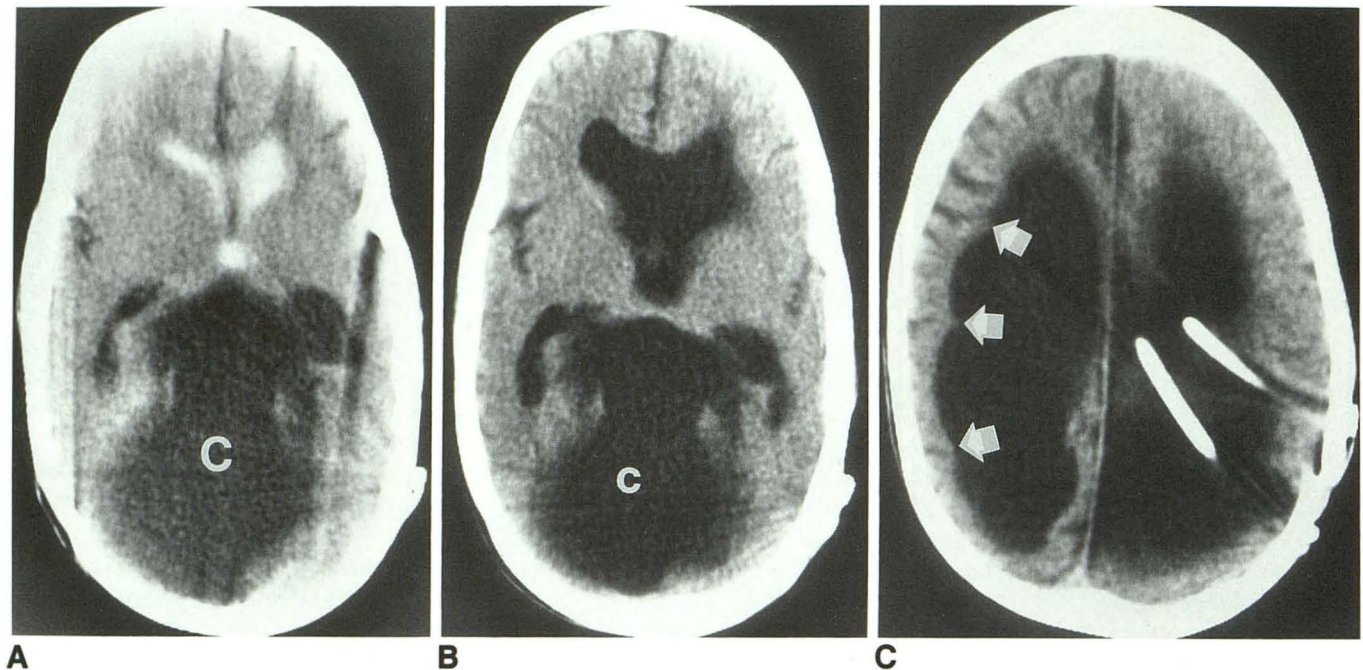


Fig. 2. Dandy-Walker cyst with postinflammatory compartmentalization of the lateral ventricles (case 2). The CT ventriculogram shows a CSF-containing space (c) completely occupying the posterior fossa and protruding through the hiatus into the supratentorial space (A). Only the frontal horns and the third ventricle are opacified; the remaining ventricular spaces do not communicate with the frontal horns. After surgery and lysis of adhesions the lateral ventricles are no longer compressed and have expanded (B and C). Note that the diminution of volume and pressure results on one hand in some retraction of the wall of the lateral ventricle with visualization of the cortical sulci (arrows); on the other hand the frontal horns have enlarged beyond their expected size (C).

a fixed intracranial volume. With confirmation of good shunt function it became clear that the postoperative CT appearance of enlarged lateral ventricles was actually the desired result of therapy and did not indicate shunt malfunction. Great care is therefore required when interpreting imaging studies of patients who harbor more than one independent fluid-filled compartment if each is shunted separately.

## References

1. Wolpert SM, Scott RM, Runge VM, Kwan ESK. Difficulties in diagnosing congenital posterior fossa fluid collections after shunting procedures. *AJNR Am J Neuroradiol* 1987;8:653-656
2. Foltz EL, Shurtleff DB. Conversion of communicating hydrocephalus to stenosis or occlusion of the aqueduct during ventricular shunting. *J Neurosurg* 1966;24:520-529
3. Harwood-Nash DC, Fitz CR. *Neuroradiology in infants and children*. Vol 1, St. Louis: Mosby, 1976:632-642
4. Scotti G, Musgrave MA, Fitz CR, Harwood-Nash DC. The isolated fourth ventricle in children: CT and clinical review of 16 cases. *AJNR Am J Neuroradiol* 1980;1:419-424
5. Hawkins JC, Hoffman HJ, Humphreys RP. Isolated fourth ventricle as a complication of ventricular shunting. Report of three cases. *J Neurosurg* 1978;49:910-913
6. Eller TW, Pasternak JF. Isolated ventricles following intraventricular hemorrhage. *J Neurosurg* 1985;62:357-362
7. Wolfson BJ, Faerber EN, Truex RC. The "keyhole": a sign of herniation of a trapped fourth ventricle and other posterior fossa cysts. *AJNR Am J Neuroradiol* 1987;8:473-477
8. Wang AN, Carson BS. Upward herniation of the posterior fossa cyst in the shunted child. *Surg Neurol* 1987;28:215-220