

Generic Contrast Agents

Our portfolio is growing to serve you better. Now you have a *choice*.



[VIEW CATALOG](#)

AJNR

Combined stent implantation and endosaccular coil placement for treatment of experimental wide-necked aneurysms: a feasibility study in swine.

F Turjman, T F Massoud, C Ji, G Guglielmi, F ViÖ±uela and J Robert

This information is current as of May 31, 2025.

AJNR Am J Neuroradiol 1994, 15 (6) 1087-1090
<http://www.ajnr.org/content/15/6/1087>

Combined Stent Implantation and Endosaccular Coil Placement for Treatment of Experimental Wide-Necked Aneurysms: A Feasibility Study in Swine

Francis Turjman, Tarik F. Massoud, Cheng Ji, Guido Guglielmi, Fernando Viñuela, and John Robert

PURPOSE: To assess the feasibility of combining stent implantation in the parent artery with endosaccular coil placement for the treatment of experimentally created wide-necked aneurysms. **METHODS:** Wide-necked aneurysms were surgically created on the common carotid artery in 12 swine. A metal stent was endovascularly implanted across each aneurysm neck and its effect documented angiographically. If the aneurysm remained patent, a microcatheter was introduced into the aneurysm through the stent mesh. Electrically detachable coils were delivered into the aneurysm sac to produce thrombosis. **RESULTS:** After stent implantation, one carotid artery thrombosed and two aneurysms spontaneously occluded. In the other 9 cases, coils were deposited through the stent to occlude the aneurysm. Complete aneurysm packing was possible in all 9 cases. The presence of the stent allowed placement of small coils near the aneurysm neck, thus contributing to the safe occlusion of small remnants in the final stages of aneurysm packing. **CONCLUSION:** The combination of stent implantation and coil placement is feasible in the treatment of experimental wide-necked saccular aneurysms. The stent maintains patency of the parent artery while allowing aneurysm occlusion by endosaccular coil placement through the stent's mesh. Occlusion of small aneurysm remnants is possible with no fear of coil hernation or migration into the parent artery. Long-term studies will be necessary before application to treatment of selected intracranial aneurysms.

Index terms: Aneurysm, intracranial; Aneurysm, therapeutic blockade; Interventional instrumentation, coils; Interventional instrumentation, stents; Interventional neuroradiology, experimental; Animal studies

AJNR Am J Neuroradiol 15:1087–1090, Jun 1994

Wide-necked saccular aneurysms are difficult to treat surgically or by endovascular therapy. Endovascular stent implantation has been proposed recently as a method for treatment of

saccular aneurysms. A major shortcoming of this technique, however, has been the occasional failure of aneurysm occlusion and late aneurysm recanalization, findings more frequent in aneurysms possessing wide necks. To combat this problem, we have developed a combination of stent implantation and electrically detachable coil placement for the treatment of experimental wide-necked aneurysms in swine.

Materials and Methods

All animal experiments were conducted in accordance with policies set by our university's Chancellor's Animal Research Committee and National Institutes of Health guidelines. Wide-necked aneurysms were surgically created under general anesthesia by grafting a vein pouch onto the common carotid arteries of 12 adult Red Duroc swine (1, 2). Within 4 days of surgery, under general anesthesia (1% to 2% halothane inhalation) and via the transfemoral route, orthogonal plane selective carotid arteriography was per-

Received April 1, 1993; accepted pending revision Jun 16; revision received July 6.

Dr F. Turjman is supported by a grant from the Ministère des Affaires Étrangères from France and by the Innovaylon prize from the City of Lyon (France). Dr T.F. Massoud is a 1992–1993 Kodak Scholar and 1993 William Cook Interventional Fellow of the Royal College of Radiologists, and recipient of a research fellowship from the Pathological Society of Great Britain and Ireland.

From the Endovascular Therapy Service and Leo G. Rigler Radiological Research Center, Department of Radiological Sciences, University of California Los Angeles Medical Center.

Address reprint requests to Dr F. Turjman, Endovascular Therapy Service, Department of Radiological Sciences, University of California Los Angeles Medical Center, Le Conte Avenue, Los Angeles, CA 90024.

AJNR 15:1087–1090, Jun 1994 0195-6108/94/1506-1087

© American Society of Neuroradiology

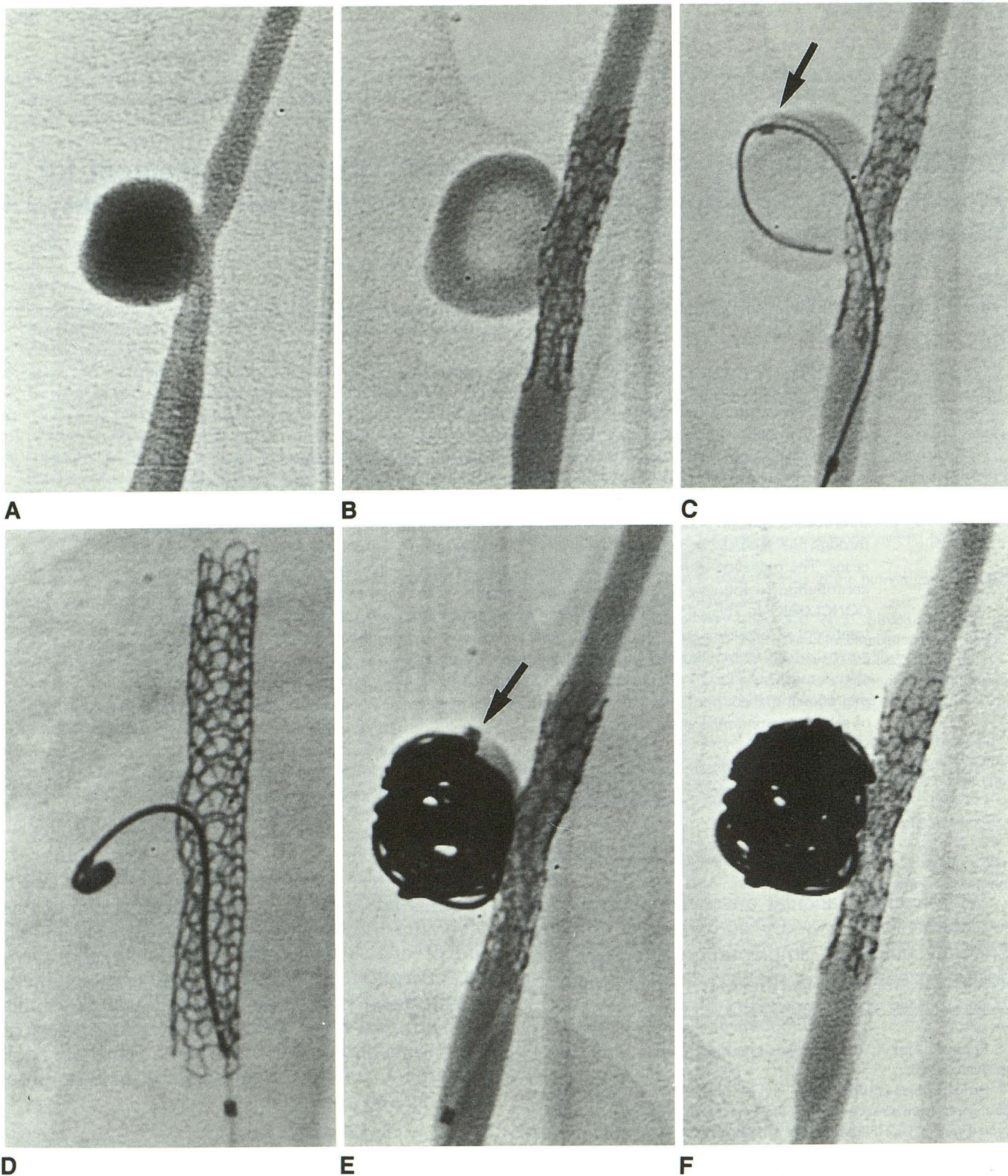


Fig. 1. A, Right carotid angiogram shows the aneurysm and its wide neck (8 mm in diameter).
 B, After stent implantation the aneurysm is still patent. The stent is placed in a correct position across the aneurysm neck. Different steps of the treatment follow.
 C, A microguidewire is first introduced into the aneurysm through the stent mesh. The microcatheter is then pushed into the aneurysm sac. The tip of the catheter appears as a black dot (arrow). Carotid opacification is performed through the guiding catheter.
 D, The first coil is placed in the aneurysm. Despite its small size (2 mm \times 4 cm), no migration occurs.
 E, The aneurysm is almost completely occluded. A small coil (2 mm \times 4 cm) is visible in the inflow zone of the aneurysm (arrow).
 F, Control angiogram shows complete occlusion of the aneurysm with five coils (total length 82 cm).

formed to demonstrate aneurysm patency (Fig 1A). Heparin (3000 U) was administered intraarterially. The angiographic catheter was exchanged for a 3.4- to 5.0-F catheter-mounted balloon-inflatable Strecker stent (Meditech, Watertown, Mass). Stents were 1.5 or 3.3 cm in length and 4.5 or 5.0 mm in diameter. The balloon was advanced to the level of the aneurysm neck and inflated for stent expansion and placement. Angiography was performed before and after stent implantation to assess the carotid artery and the aneurysm. At this stage the experiment was terminated if the aneurysm was spontaneously and completely occluded. If the aneurysm remained patent, the balloon catheter was exchanged for a 6-F guiding catheter, placed in the proximal carotid artery (Fig 1B). A preshaped 2.5-F Tracker 18 (or Tracker 10) microcatheter and Seeker 14 microguide wire (Target Therapeutics, San Jose, Calif) combination was advanced through the guiding catheter to the level of the aneurysm neck. Using fluoroscopy and "road mapping," the microguidewire followed by the microcatheter was advanced through the mesh of the stent and into the aneurysm sac (Fig 1C). The microguidewire was subsequently removed. Repeat angiography was performed through the microcatheter and the guiding catheter. Continuous flush with pressurized saline was delivered via side-arm adaptors. Guglielmi electrically detachable coils (Target Therapeutics) were delivered into the aneurysm via the microcatheter, according to the technique previously described by Guglielmi et al (3, 4). We chose a small first and/or last coil to be detached (2-mm coil diameter, 4-cm length) and placed it in or near the aneurysm neck to evaluate possible migration into the parent artery (Figs 1D and 1E). Complete packing of the aneurysm was done with several coils (Fig 1F).

Results

All swine tolerated the surgical and endovascular procedures, with no general or specific neurologic ill effects. All aneurysms were patent on the angiograms performed within 4 days of surgery. After stent implantation, one carotid artery thrombosed, and two aneurysms completely and spontaneously occluded. In the other nine swine, aneurysms remained patent despite the presence of the stent across the aneurysm neck. In these aneurysms, progressive and complete packing of the aneurysm sac was accomplished by using Guglielmi detachable coils placed via a microcatheter traversing the stent mesh. The passage of the microcatheter/microguide-wire combination through the stent mesh was always easy with either of the microcatheter sizes used. The exact number of coils detached varied with the size of each aneurysm. Small coils placed near the aneurysm neck in the initial stages of aneurysm packing or at the end of the occlusion process to fill small aneurysm remnants always stayed where they were deposited and did not herniate or migrate through the aneurysm neck into the parent artery. The stent mesh prevented

encroachment of the coils onto the carotid lumen. No thrombus or coil was seen to embolize into the downstream circulation. No aneurysm ruptured. No follow-up assessments were conducted in this preliminary feasibility study.

Discussion

The frequency of wide-necked aneurysms and their specific methods of treatment have been poorly addressed in the literature. Some insight into this particular type of lesion may be gained by the study of giant intracranial aneurysms, because they are likely to be associated with wide necks. Such aneurysms, especially in vertebro-basilar, carotid-ophthalmic, and carotid-cavernous locations, have been considered as lesions with great neurosurgical difficulties (5–8). These difficulties are usually related to the length of the neck and to the thickness of the neck wall. The challenges posed by the neurosurgical management of these lesions has resulted in a higher rate of referral for minimally invasive endovascular therapy. However, the complete occlusion of such lesions using endovascular therapy is not easy.

In the treatment of intracranial saccular aneurysms, complete aneurysm occlusion is necessary with both surgical and endovascular techniques. Regrowth and/or rebleeding from aneurysms incompletely treated by surgery is well documented in the literature (9–11). Similar consequences have been reported after incomplete endovascular occlusion of aneurysms with detachable balloons (12–15) and with coils. Casasco et al (16) have recently reported a series of 71 aneurysms treated with coils. They reported good results in 90% of small aneurysms and in 82% of large ones. In their series two aneurysm remains resulted in hemorrhage and death. The authors concluded that large and giant aneurysms, especially those having wide necks, pose a specific problem whatever the treatment undertaken. Guglielmi et al (3, 4) have developed a technique of aneurysm occlusion with electrically detachable coils. Guglielmi detachable coils, still in evaluation, possess three main advantages: they are softer and less traumatic than simple coils, they are detachable by application of electric current, which also induces thrombosis, and above all they are retrievable before detachment. This last characteristic is of paramount importance. It allows assessment of the accuracy of coil placement before its detachment, dramatically increasing the safety of the treatment. Unfortunately, the treatment of wide-necked aneurysms by this method presents its own difficulties.

Attempts to occlude the aneurysm neck carry the risk of coil herniation into the parent artery, with consequent vessel thrombosis or coil migration. Guglielmi et al (17) reported complete occlusion in 13 of 16 small-necked aneurysms versus complete occlusion in 4 of 16 wide-necked aneurysms, thus recognizing the latter as a distinct subset of saccular aneurysms requiring further technical innovations to improve their currently available therapeutic options.

A technique for occlusion of saccular aneurysms by stent implantation has been described previously, and its feasibility demonstrated in experimental in vivo settings (18) (Geremia GK, et al, Embolization of Experimentally Created Aneurysms with Intravascular Stent Devices, presented at the 30th Annual Meeting of the American Society of Neuroradiology, St. Louis, 1992; Wakhloo AK et al, Coated and Noncoated Stents in Treatment of Carotid AV-fistula and Aneurysms: An Experimental Study, presented at the 30th Annual Meeting of the American Society of Neuroradiology, St. Louis, 1992). Stent placement in the parent artery across the aneurysm neck leads to complete occlusion of experimental aneurysms in most instances. However, emerging from these previous preliminary studies was the recognition of certain limitations to this technique, including the occasional persistence of aneurysm patency and late aneurysm recanalization despite correct stent implantation. The overall appeal of stent implantation as an endovascular technique for treatment of saccular aneurysms thus necessitates further refinements that may help ensure aneurysm occlusion. This is particularly true for those aneurysms with wide necks, in which patency after stent placement across the neck is a more frequent finding. These considerations have led us to combine stent implantation with Guglielmi detachable coil embolization to achieve complete occlusion of wide-necked aneurysms. Our results have demonstrated that placement of these coils through stents was possible. Furthermore, the presence of the stent across the aneurysm neck acts as a physical barrier through which small-sized coils can be deposited near the neck without the risk of their migration into the parent artery. The combination of these two endovascular techniques, therefore, permits complete occlusion of wide-necked aneurysms without remnants, and results in a safe and dense packing of the aneurysm.

In conclusion, the combination of stent placement and Guglielmi coiling seems feasible for the treatment of wide-necked experimental aneurysms. The circular configuration of the released

coils, which is assumed because of their inherent memory, also acts as a safeguard to accidental migration into the parent artery. The technique may be applicable to the treatment of certain human intracranial aneurysms, such as carotid-ophthalmic and carotid-cavernous aneurysms. At present, the main limitation of stent use for these lesions is the inability of this device to reach the appropriate locations. Such positioning will require the future development of as flexible a device as possible, capable of traversing the petrous segment of the carotid artery and of being implanted in the carotid siphon. Furthermore, long-term controlled angiographic and histopathologic studies are necessary before application in human clinical settings.

Acknowledgments

We thank Randy Tuomisto and Marie-Annick Lebourg from Boston Scientific for their help and advice. We thank Christopher Carangi for his work in the laboratory.

References

1. German WJ, Black SPW. Experimental production of carotid aneurysms. *N Engl J Med* 1954;250:104-106
2. Kerber CW, Buschman RW. Experimental carotid aneurysms: I. Simple surgical production and radiographic evaluation. *Invest Radiol* 1977;12:154-157
3. Guglielmi G, Viñuela F, Sepetka I, et al. Electrothrombosis of saccular aneurysms via endovascular approach, I: electrochemical basis, technique and experimental results. *J Neurosurg* 1991;75:1-7
4. Guglielmi G, Viñuela F, Dion J, et al. Electrothrombosis of saccular aneurysms via endovascular approach, II: preliminary clinical experience. *J Neurosurg* 1991;75:8-14
5. Yasargil MG, Gasser JC, Hodosh RM, et al. Carotid ophthalmic aneurysms: direct microsurgical approach. *Surg Neurol* 1977;8:155-165
6. Drake CG. Giant intracranial aneurysms: experience with surgical treatment in 174 patients. *Clin Neurosurg* 1979;26:12-95
7. Sundt TMJ, Piepgras DG. Surgical approach to giant intracranial aneurysms: operative experience with 80 cases. *J Neurosurg* 1979;51:731-742
8. Keravel Y, Sindou M. *Giant intracranial aneurysms: Therapeutic approaches*. Berlin-Heidelberg: Springer Verlag, 1988:42-51
9. Lin T, Fox AJ, Drake CG. Regrowth of aneurysm sacs from residual neck following aneurysm clipping. *Neurosurgery* 1989;70:556-560
10. Ebina K, Suzuki M, Andoh A, et al. Recurrence of cerebral aneurysm after initial neck clipping. *Neurosurgery* 1982;11:764-768
11. Feuenberg I, Lindquist C, Lindquist M, et al. Natural history of postoperative aneurysms rests. *J Neurosurg* 1987;66:30-34
12. Kwan ESK, Heilman CB, Shucart WA, et al. Enlargement of basilar artery aneurysms following balloon occlusion "water-hammer effect:" report of two cases. *Neurosurgery* 1991;75:963-968
13. Heilman CB, Kwan ESK, Wu JK. Aneurysm recurrence following endovascular balloon occlusion. *J Neurosurg* 1992;77:260-261
14. Fox AJ, Drake CG. Aneurysm neck remnant following balloon embolization. *J Neurosurg* 1987;67:321-322
15. Hodes JE, Fox AJ, Pelz DM, et al. Rupture of aneurysms following balloon embolization. *J Neurosurg* 1990;72:567-571
16. Casasco et al. Selective endovascular treatment of 71 intracranial aneurysms with metal coils. *J Neurosurg* 1993;79:3-10
17. Guglielmi G, Viñuela F, Duckwiler G, et al. Endovascular treatment of posterior circulation aneurysms by electrothrombosis using electrically detachable coils. *J Neurosurg* 1992;77:515-524
18. Turjman F, Acevedo G, Moll T, et al. Treatment of experimental carotid aneurysms by endoprosthesis implantation: preliminary report. *Neurol Res* 1993;15:181-184