



Discover Generics

Cost-Effective CT & MRI Contrast Agents



WATCH VIDEO

AJNR

Intracranial vertebral artery dissection in Wallenberg syndrome.

T Hosoya, N Watanabe, K Yamaguchi, H Kubota and Y Onodera

AJNR Am J Neuroradiol 1994, 15 (6) 1161-1165

<http://www.ajnr.org/content/15/6/1161>

This information is current as
of June 4, 2025.

Intracranial Vertebral Artery Dissection in Wallenberg Syndrome

T. Hosoya, N. Watanabe, K. Yamaguchi, H. Kubota, and Y. Onodera

PURPOSE: To assess the prevalence of vertebral artery dissection in Wallenberg syndrome.

METHODS: Sixteen patients (12 men, 4 women; mean age at ictus, 51.6 years) with symptoms of Wallenberg syndrome and an infarction demonstrated in the lateral medulla on MR were reviewed retrospectively. The study items were as follows: (a) headache as clinical signs, in particular, occipitalgia and/or posterior neck pain at ictus; (b) MR findings, such as intramural hematoma on T1-weighted images, intimal flap on T2-weighted images, and double lumen on three-dimensional spoiled gradient-recalled acquisition in a steady state with gadopentetate dimeglumine; (c) direct angiographic findings of dissection, such as double lumen, intimal flap, and resolution of stenosis on follow-up angiography; and (d) indirect angiographic findings of dissection (such as string sign, pearl and string sign, tapered narrowing, etc). Patients were classified as definite dissection if they had reliable MR findings (ie, intramural hematoma, intimal flap, and enhancement of wall and septum) and/or direct angiographic findings; as probable dissection if they showed both headache and suspected findings (ie, double lumen on 3-D spoiled gradient-recalled acquisition in a steady state or indirect angiographic findings); and as suspected dissection in those with only headache or suspected findings. **RESULTS:** Seven of 16 patients were classified as definite dissection, 3 as probable dissection, and 3 as suspected dissection. Four patients were considered to have bilateral vertebral artery dissection on the basis of MR findings. **CONCLUSIONS:** Vertebral artery dissection is an important cause of Wallenberg syndrome.

Index terms: Arteries, dissection; Arteries, vertebral; Arteries, magnetic resonance; Brain, infarction; Cerebral angiography; Headache

AJNR Am J Neuroradiol 15:1161-1165, Jun 1994

It is well recognized that Wallenberg syndrome (lateral medullary syndrome) is caused by occlusion or stenosis of the vertebral artery, and its most important cause is arteriosclerosis. However, Wallenberg syndrome is more common in young men compared with other more usual types of strokes, and its onset is characterized clinically by headache. Because these clinical features are similar to those of vertebral artery dissection, which has become more evident with the development of imaging technology, vertebral artery dissection as a cause of Wallenberg syndrome has been observed recently (1-5). We

investigated the presence of headache and neuro-radiologic findings on MR and angiography to assess the prevalence of vertebral artery dissection in Wallenberg syndrome.

Materials and Methods

The present study was based on retrospective review of 16 patients (12 men and 4 women) aged 40 to 67 years (mean 51.6) presenting with clinical signs and symptoms of Wallenberg syndrome (such as loss of pain and temperature sensation in the unilateral face and contralateral body, ataxia, and dysphagia) who underwent MR from 1988 to 1992. In all an infarction was demonstrated in the lateral medulla on T2-weighted images. The study items were headache, in particular, occipitalgia and/or posterior neck pain at ictus, MR findings, and angiographic findings. Clinical information at ictus was obtained by records of the patients.

MR images were obtained with a 1.5-T system in 12 cases and a 0.5-T system in 4 cases. With the 1.5-T system, we used spin-echo sequences with 400/18/2 (repetition time/echo time/excitations) for T1-weighted images in 9 cases and spin-echo sequences with 2500/30,100/1 or fast

Received June 4, 1993; accepted pending revision August 30; revision received September 30.

From the Department of Radiology, Yamagata University School of Medicine, Japan.

Address reprint requests to Takaaki Hosoya, MD, Department of Radiology, Yamagata University School of Medicine, Iidanishi 2-2-2 Yamagata, Japan 990-23.

AJNR 15:1161-1165, Jun 1994 0195-6108/94/1506-1161

© American Society of Neuroradiology

Clinical, MR, and angiographic findings in 16 patients with Wallenberg syndrome

Case	Age/Sex	Headache	MR				Angiography		VA Dissection ^c
			Period ^a	T1-Weighted	T2-Weighted ^b	3-D SPGR	Period ^a	Findings	
1	40/M	+	9 y	...	Normal	Double intensity (right VA)	1 wk 5 wk	String sign (right VA) Resolution of stenosis	Definite
2	41/M	+	7 y	Normal	Normal	Double lumen (left VA)	2 wk	String sign (left VA)	Probable
3	41/M	+	1 wk	Normal	Normal	...	6 mo	String sign (left VA)	Probable
4	42/M	+	1 wk	Normal	Normal	Normal	1 mo	Wall irregularity (right PICA)	Suspected
5	45/M	?	2 y	High lesion (Bil VA-BA)	Flow void (-) (right VA)	Enhancement of wall and septum (right VA) Double lumen (left VA)	Definite
6	46/F	+	3 y	Normal	Flow void (-) (left VA)	...	3 wk	Tapering stenosis and occlusion (left VA)	Probable
7	49/F	+	5 y	High lesion (left VA)	Normal	Double lumen (left VA) Double intensity (left VA)	0 d	String sign (left VA)	Definite
8	49/M	+	4 mo	High lesion (left VA)	Flow void (-)	...	3 mo	Tapering stenosis and occlusion (left VA)	Definite
9	50/M	+	3 y	Normal	Flow void (-) (left VA)	...	5 wk	Occlusion (left VA)	Suspected
10	52/M	+	1 y	High lesion (Bil VA)	Intimal flap (right VA)	...	6 mo	Focal stenosis (right VA) Double lumen (pooling) and pearl and string sign (right VA) Smooth stenosis (left VA)	Definite
11	58/M	+	3 wk	...	Intimal flap (left VA)	Enhancement of wall and septum (left VA) Double lumen (right VA)	Definite
12	58/M	+	8 y	Normal	Normal	Enhancement of wall and septum (Bil VA)	Definite
13	60/F	-	7 y	...	Normal	...	2 y	Occlusion (left VA)	No
14	64/M	?	4 mo	Normal	Normal	Double lumen (left VA)	4 mo	Occlusion (left VA)	Suspected
15	64/M	-	4 y	Normal	Normal	No
16	67/F	-	2 mo	Normal	Normal	Normal	2 mo	Wall irregularity (left PICA)	No

^a Period from ictus to examination.^b All showed high-signal lesions at lateral medulla on T2-weighted images.^c See text for classification of vertebral artery dissection.

Note.—Bil indicates bilateral; VA, vertebral artery; and PICA, posterior inferior cerebellar artery.

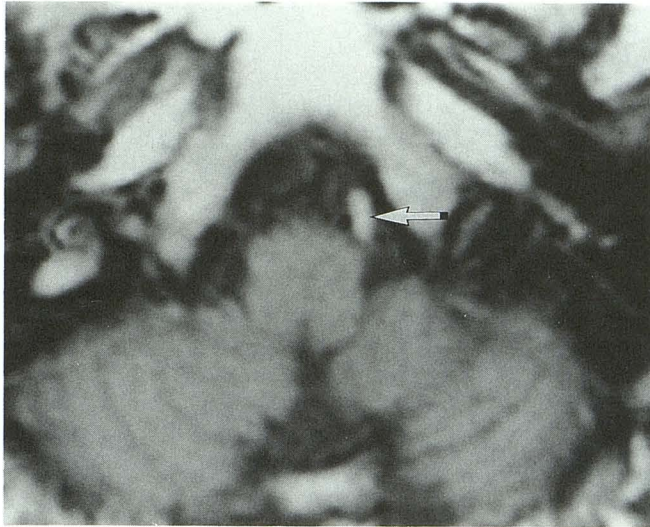


Fig. 1. Case 8. Third axial T1-weighted image in the multi-image sequence shows a high-intensity lesion (arrow) and narrowing of the residual signal void of the left vertebral artery.

spin-echo sequences with 3200/19,95/1 for proton density-weighted images and T2-weighted images in all cases. Five-millimeter-thick sections with 2.5-mm spacing between adjacent sections were obtained routinely in an axial plane. Furthermore, in 9 cases three-dimensional imaging using spoiled gradient-recalled acquisition in the steady state (SPGR) sequences with 26/4.5/2, 35° flip angle, 16- to 18-cm of field of view, 1.0 mm section thickness, 0 mm space, 256/192/64 (matrices) was performed after injection of 0.1 to 0.15 mmol/kg (up to 20 ml) of gadopentetate dimeglumine (6). With the 0.5-T system we used spin-echo sequences with 500/30 and 2000/100 for T1- and T2-weighted images with 10-mm-thick sections without spacing. In this study, we set the most inferior section of all MR examinations at the junction of C-1 and C-2 to avoid inflow artifacts at the level of interest. MR findings relating to vertebral artery dissection such as intramural hematoma (7, 8) on T1-weighted images, intimal flap (9) on T2-weighted images, and enhancement of wall and septum on contrast-enhanced 3-D SPGR were taken as a reliable MR finding. We considered double lumen on 3-D SPGR to be a suspected MR finding even through the possibility of flow artifacts could not be denied completely because this finding had not been detected in any patient without stroke.

Vertebral angiography by selective catheterization using biplane stereo magnification radiography and/or a digital subtraction angiography system was performed in 12 cases (bilateral in 7 cases). Angiographic findings were grouped into direct findings and indirect findings. The former included double lumen or intimal flap (5, 10–12), indicating the presence of a false lumen and resolution of stenosis on follow-up exam (2, 4, 13), considered as a direct angiographic sign of vertebral artery dissection. The latter included pearl and string sign (11, 13), tapered narrowing (11, 14), total occlusion with proximal distension (11), and

retention of contrast medium (1, 12), which were considered specific for vertebral artery dissection but not as a pathognomonic sign.

The patients were classified as definite dissection, probable dissection, suspected dissection, or no dissection, after review of the presence of characteristic headache at ictus, MR findings, and angiographic findings. The criteria of the classification were as follows: definite dissection in patients with reliable MR findings and/or direct angiographic findings; probable dissection in those with both headache and suspected findings (suspected MR findings or indirect angiographic findings); suspected dissection in those with only with headache or suspected findings; and no dissection in those with no headache or abnormal finding.

Results

The clinical, MR, and angiographic findings of 16 patients with Wallenberg syndrome are summarized in the Table.

Headache

Eleven of 16 patients presented with sudden onset occipitalgia and/or posterior neck pain preceding or simultaneous with the symptoms of Wallenberg syndrome. In 5 of 11 patients the headache was unilateral. Three had no headache, and 2 had vague headache.

MR

Intramural hematoma (Fig 1) of the intracranial vertebral artery on T1-weighted images was shown in 4 of 13 patients. Intimal flap was seen in 2 of 16 on T2-weighted images (Fig 2A), and enhancement of wall and septum in 3 of 9 on contrast-enhanced 3-D SPGR images (Figs 2C and 2D). Contrast-enhanced 3-D SPGR also revealed a double lumen (Figs 2B and 2D) in 5 patients. MR findings suggested bilateral vertebral artery dissection in 4 patients.

Angiography

Two of 12 patients showed direct angiographic findings of double lumen and resolution of stenosis. Indirect findings were detected in 6 patients, all of whom presented with headache at ictus.

Vertebral Artery Dissection in Wallenberg Syndrome

Seven (44%) of 16 patients were classified as definite dissection, 3 as probable dissection, and

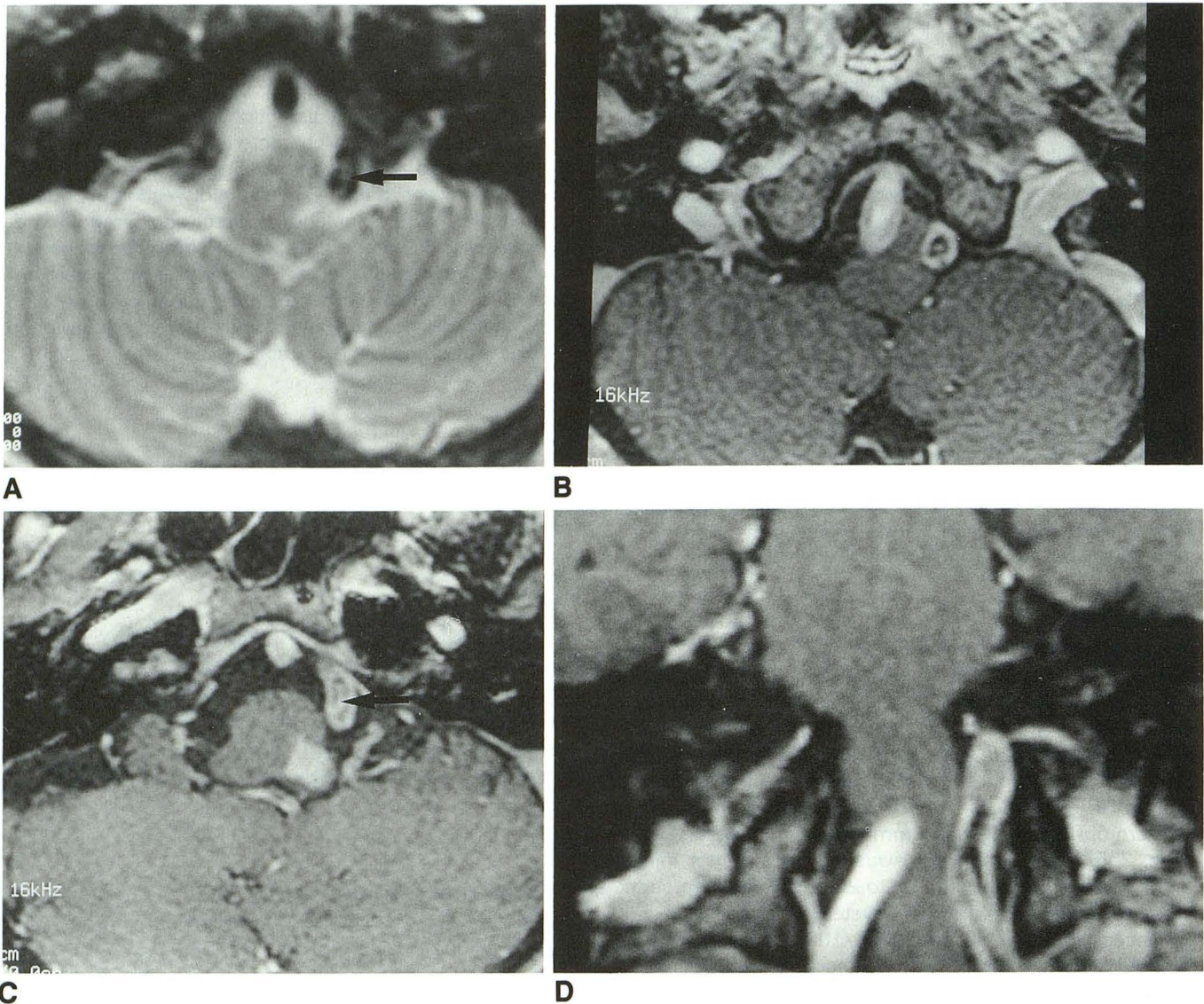


Fig. 2. Case 11. MR images obtained in a patient with left Wallenberg syndrome at 24 days after ictus.

A, Axial T2-weighted image shows a curvilinear high-signal structure (arrow) in the left vertebral artery.

B and C, Contrast-enhanced 3-D SPGR reveals an enhanced intimal flap (arrow) in the left vertebral artery and a double lumen of the right vertebral artery.

D, Reformatted image of the contrast-enhanced 3-D SPGR.

3 as suspected dissection. Only 3 were classified as no dissection. The frequency of definite and probable dissection, which comprised 8 men and 2 women (mean age 47.9), in Wallenberg syndrome was 63%.

Discussion

Wallenberg syndrome is characterized by onset with headache, and its clinical features are very similar to those of vertebral artery dissection. Recently, patients with Wallenberg syndrome caused by vertebral artery dissection have been reported (1-5). Vertebral artery dissection is con-

sidered an important cause of Wallenberg syndrome.

To assess the prevalence of vertebral artery dissection in Wallenberg syndrome, we investigated the presence of headache at ictus in addition to MR and angiographic findings, because unilateral occipital headache has been emphasized as one of the most important clinical symptoms of the spontaneous vertebral artery dissection (1-5, 11).

Vertebral angiography had previously been the only method of preoperative diagnosis of vertebral artery dissection before the development of

MR. Of the angiographic findings described by many authors, reliable findings of arterial dissection are considered to be the presence of a false lumen (double lumen or intimal flap) (5, 10, 11) and resolution of stenosis (2, 4, 13). These findings, however, have been confirmed in only a few cases, and it is known clinically that some patients with vertebral artery dissection have been diagnosed as having fusiform aneurysm (1, 3, 11) or occlusion of vertebral artery (2, 3, 8) by angiography. In our study, there were only two patients with reliable angiographic findings.

On the other hand, MR can reveal an intramural hematoma directly as a semilunar hyperintensity causing narrowing of the residual eccentric signal void of the lumen (7, 8), and an intimal flap as a linear structure in the artery (9). These are considered reliable findings of arterial dissection and were actually observed together with direct or indirect angiographic findings in all three cases in which angiography was performed.

Contrast-enhanced 3-D SPGR has been used for imaging of cranial nerves and intracranial vessels (6). This has offered high-quality images as MR angiotomography with good spatial resolution. It seems that this sequence, which is almost the same as 3-D time-of-flight MR angiography, is appropriate to demonstrate true and false lumens with different flow velocities. Of the various abnormalities, two are considered to be abnormal findings suggesting vertebral artery dissection. One is enhancement of the wall and septum, shown as a linear enhanced structure in the lumen with enhancement of the wall of the artery. This must be a reliable finding of dissection of the occluded artery, because in other patients with such findings vertebral angiogram shows occlusion of the vertebral artery. And the other is double lumen, appearing as a semilunar hyperintensity circumscribing an eccentric greater hyperintensity with a low-intensity border. We considered this finding on 3-D SPGR as a suspected MR finding, even though the possibility of the flow artifacts could not be denied completely because it had not been detected in any patient without stroke. Five arteries out of seven with these findings had other abnormalities suggesting arterial dissection. Sometimes double intensity (different intensity in the lumen without low-intensity border) was shown. This may indicate arterial dissection but may be caused by different flow velocities.

It is believed that vertebral artery dissection is dangerous because it causes subarachnoid hemorrhage resulting in death (1, 5, 11, 13). Our finding that vertebral artery dissection was the most frequent cause of Wallenberg syndrome suggests that vertebral artery dissection is a frequent cause of vertebrobasilar ischemic strokes and may not be so dangerous. It also has been reported that bilateral vertebral artery dissection is not rare (2, 3), and our observation on the basis of MR findings is in agreement.

In conclusion, our results indicate a probable association between vertebral artery dissection and Wallenberg syndrome and that the incidence may be higher than previously suspected. Thus, clinical examination should be performed to detect not only infarction of the lateral medulla, but also vertebral artery dissection, in cases of Wallenberg syndrome.

References

1. Shimoji T, Bando K, Nakajima K, Ito K. Dissecting aneurysm of the vertebral artery. Report of seven cases and angiographic findings. *Neurosurgery* 1984;61:1038-1046
2. Chiras J, Marciano S, Molina JV, et al. Spontaneous dissecting aneurysm of the extracranial vertebral artery (20 cases). *Neuroradiology* 1985;27:327-333
3. Mokri B, Houser OW, Sandok BA, Piepgras DG. Spontaneous dissections of the vertebral arteries. *Neurology* 1988;38:880-885
4. Rodacki MA, Mello LR. Bilateral dissecting aneurysms of the extracranial vertebral arteries associated with cervical carotid artery aneurysm. *AJNR Am J Neuroradiol* 1990;11:1147-1149
5. Yamaura A, Watanabe Y, Saeki N. Dissecting aneurysms of the intracranial vertebral artery. *J Neurosurg* 1990;72:183-188
6. Hosoya T, Sato N, Yamaguchi K, Sugai Y, Ogushi M, Kubota H. MR imaging of the cranial nerves and the intracranial vessels using 3D-SPGR. *J Magn Reson* 1992;12:245-252
7. Quint DJ, Spickler EM. Magnetic resonance demonstration vertebral artery dissection: report of two cases. *J Neurosurg* 1990;72:964-967
8. Gelbert F, Assouline E, Hodes JE, et al. MRI in spontaneous dissection of vertebral and carotid arteries: 15 case studies at 0.5 tesla. *Neuroradiology* 1991;33:111-113
9. Iwama T, Andoh T, Sakai N, Iwata T, Hirata T, Yamada H. Dissecting and fusiform aneurysms of vertebro-basilar systems: MR imaging. *Neuroradiology* 1990;32:272-279
10. Kunze ST, Schiefer W. Angiographic demonstration of a dissecting aneurysm of the middle cerebral artery. *Neuroradiology* 1971;2:201-206
11. Yonas H, Agamanolis D, Takaoka Y, White RJ. Dissecting intracranial aneurysms. *Surg Neurol* 1977;8:407-415
12. Pozzati E, Padovani R, Fabrizi A, Sabantini L, Gaist GJ. Benign arterial dissection of the posterior circulation. *Neurosurgery* 1991;75:69-72
13. Ojemann RG, Fisher CM, Rich JC. Spontaneous dissecting aneurysm of internal carotid artery. *Stroke* 1972;3:434-440
14. Miyazaki S, Yamaura A, Kamata K, Fukushima H. A dissecting aneurysm of the vertebral artery. *Surg Neurol* 1984;21:171-174