



Discover Generics

Cost-Effective CT & MRI Contrast Agents



WATCH VIDEO

AJNR

Value of interuncal distance measure in diagnosis of Alzheimer disease questioned.

K Ishii

AJNR Am J Neuroradiol 1994, 15 (7) 1286

<http://www.ajnr.org/content/15/7/1286.citation>

This information is current as
of June 1, 2025.

FORUM

Editor's note: The following letter was received from Dr Ishii. The reply from Dr Howieson follows. Because of the interest in this measurement, the letter was sent to Dr de Leon and his colleagues for comment, and the replies are presented as a neuroradiologic forum.

Value of Interuncal Distance Measure in Diagnosis of Alzheimer Disease Questioned

I have read with interest the article by Howieson et al (1), which appeared in the May 1993 *AJNR*. I agree with their conclusion that the interuncal distance is not a useful screening measure for Alzheimer disease. However, I have two questions.

According to the result in their Table 2, the controls' values for interuncal distance decreased (from 28.4 ± 5.6 to 26.8 ± 3.1) during 1 year. Does this mean that the controls' hippocampi became larger during that time?

Second, they mention that correlation of interuncal distance with the Mini-Mental State Examination and Clinical Dementia Scale was significant. I cannot believe that result. In my institute I examined the correlation of interuncal distance with the Mini-Mental State Examination but found that there was none. Early et al (2) also reported that the Mini-Mental State Examination scores of the group of patients with Alzheimer disease did not correlate with the interuncal distance. I would be interested to know the scores of interuncal distances and Mini-Mental State Examinations of their subjects.

Kazunari Ishii
Department of Radiology
Hyogo Institute for Aging Brain and
Cognitive Disorders
Hyogo, Japan

References

1. Howieson J, Kaye JA, Holm L, Howieson D. Interuncal distance: marker of aging and Alzheimer disease. *AJNR Am J Neuroradiol* 1993;14:647-650
2. Early B, Escalona PR, Boyko OB, et al. Interuncal distance measurements in healthy volunteers and in patients with Alzheimer disease. *AJNR Am J Neuroradiol* 1993;14:907-910

Reply

Dr Ishii's first question is why a variation of 1.6 mm occurs between group measurements in which the standard deviations are ± 5.6 mm and ± 3.1 mm. This variation is, of course, well within what might be expected for the small groups used for this study. It may be of interest to Dr Ishii that of the 10 controls, 5 of the measurements increased, 4 decreased, and 1 remained the same. This further demonstrates that there was no significant change.

The second question is combined with a statement that Dr Ishii cannot believe our results. We have rechecked our statistics and do not think that we have made an error.

John Howieson
Department of Diagnostic Radiology
Oregon Health Sciences University
School of Medicine
Portland

Comment

The Case for the Interuncal Distance

Development of a specific diagnostic radiologic test for Alzheimer disease that is also sensitive in the early stages of the disease is a laudable objective. Regrettably, this goal has not yet been reached (1). Since 1986, five papers have been published describing the diagnostic utility for Alzheimer disease of a linearly determined interuncal distance. The reported outcomes range from perfect sensitivity and specificity to no group difference between patients with Alzheimer disease and control subjects. We have reviewed the four magnetic resonance (MR) papers published in this journal and one computed tomography paper published elsewhere. After briefly highlighting salient aspects of these studies and examining our own data, we will offer an assessment regarding the interuncal distance measure.

LeMay et al in 1986 (2), using axial plane computed tomography, first described an interuncal distance-type measurement at the level of the suprasellar cistern connecting the two most medial aspects of the curved uncus. Their results indicated that, compared with many other measures of atrophy, the interuncal distance measurement had the most consistent results in discriminating healthy elderly subjects from patients with Alzheimer disease. Nevertheless, it was not considered of diagnostic importance because of the large overlap between healthy elderly subjects and patients with Alzheimer disease. However, Lemay et al did report that statistical combinations of diverse atrophy measures, which included the interuncal distance measure, achieved highly accurate diagnostic discriminations.

Dahlbeck et al in 1991 (3) reported that an axial MR interuncal distance measurement gave excellent statistical separation between 10 healthy subjects and 10 patients with Alzheimer disease. The means and standard deviations for the groups were 22 ± 4 mm and 37 ± 3 mm, respectively. Most important, the individual scores did not overlap between groups. The largest distance determined in a control subject was 25.6 mm, and the smallest distance found in a patient with Alzheimer disease was 34.0 mm.

Doraiswamy et al in 1993 (4) following up on the Dahlbeck et al study, reported in a normative study of 75

subjects 21 to 82 years of age that the axial MR interuncal distance measurement significantly increased with age and was greater in men (presumably because of head size differences). Although they did not study a group of patients with Alzheimer disease, Doraiswamy et al commented that the range of normal interuncal distance sizes they observed did have potential clinical importance. Specifically they found that healthy control subjects, regardless of gender and age, had interuncal distance values less than 30 mm. Therefore, by extrapolation, any value greater than 30 mm could be considered abnormal, and therefore Doraiswamy et al suggested that their results supported the finding of Dahlbeck et al. Thus, these three papers with this measurement seem to support the potential use of interuncal distance as a radiologic test for the detection of Alzheimer disease.

In an important MR validation study in 1993, Early et al (5) compared the linearly measured axial interuncal distance with the volume of the imaged amygdala-hippocam-

pal complex. The study was conducted on 17 healthy subjects ranging in age from 26 to 78 years. Because the previous MR papers referred to the interuncal distance as an index of hippocampal atrophy, it was surprising that no relationship between the interuncal distance and the volume was found. However, the interuncal distance measure was again found to be associated positively with age. Early et al also examined the diagnostic value of the interuncal distance in a sample of 12 patients with Alzheimer disease. Equally surprising, even when corrected for head size, the interuncal distance measure was not found to be significantly larger in the Alzheimer disease than in the control group, nor was it associated with the magnitude of the cognitive impairment in the Alzheimer disease group. This study was clearly the first negative diagnostic report for interuncal distance.

In 1993 Howieson et al (6) added two important aspects to the evaluation of the axial MR interuncal distance in Alzheimer disease. First, they provided a 1-year longitu-

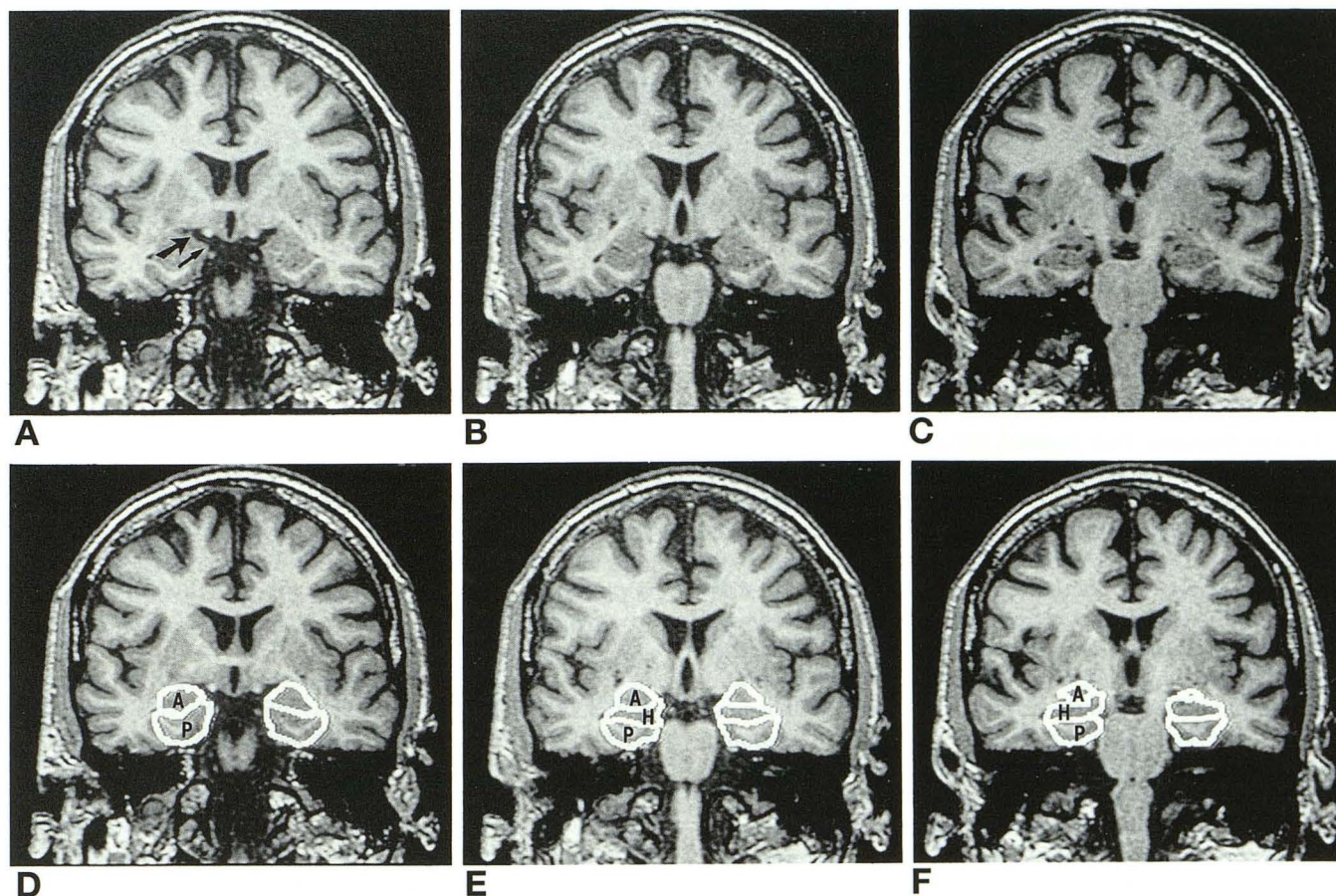


Fig 1. MR scans (*top row*) were obtained on a General Electric (Milwaukee, Wis) Advantage 1.5-T imager using a spoiled gradient-echo sequence of 35/9/1 (repetition time/echo time/excitations), a 60° flip angle, an 18-cm field of view, and a 256 × 128 acquisition matrix. We obtained 124 contiguous coronal images perpendicular to the plane of the hippocampus with a section thickness of 1.3 mm. On 12 contiguous images through the uncus, we drew the outlines of the hippocampus (H), parahippocampal gyrus (P), and the amygdala (A) using a twofold image magnification (pixel size, 0.35 mm). The three coronal images depicted (A–C) and the corresponding drawn regions (D–F) were selected to highlight the variations in the uncus anatomy. The images are separated by 2.6 mm, and the most anterior coronal section depicted (part A) is at the level of the smallest coronal interuncal distance. The gyrus ambiens (*thin arrow*) was drawn as part of the parahippocampal gyrus and the semilunar gyrus (*heavy arrow*) as part of the amygdala (part A).

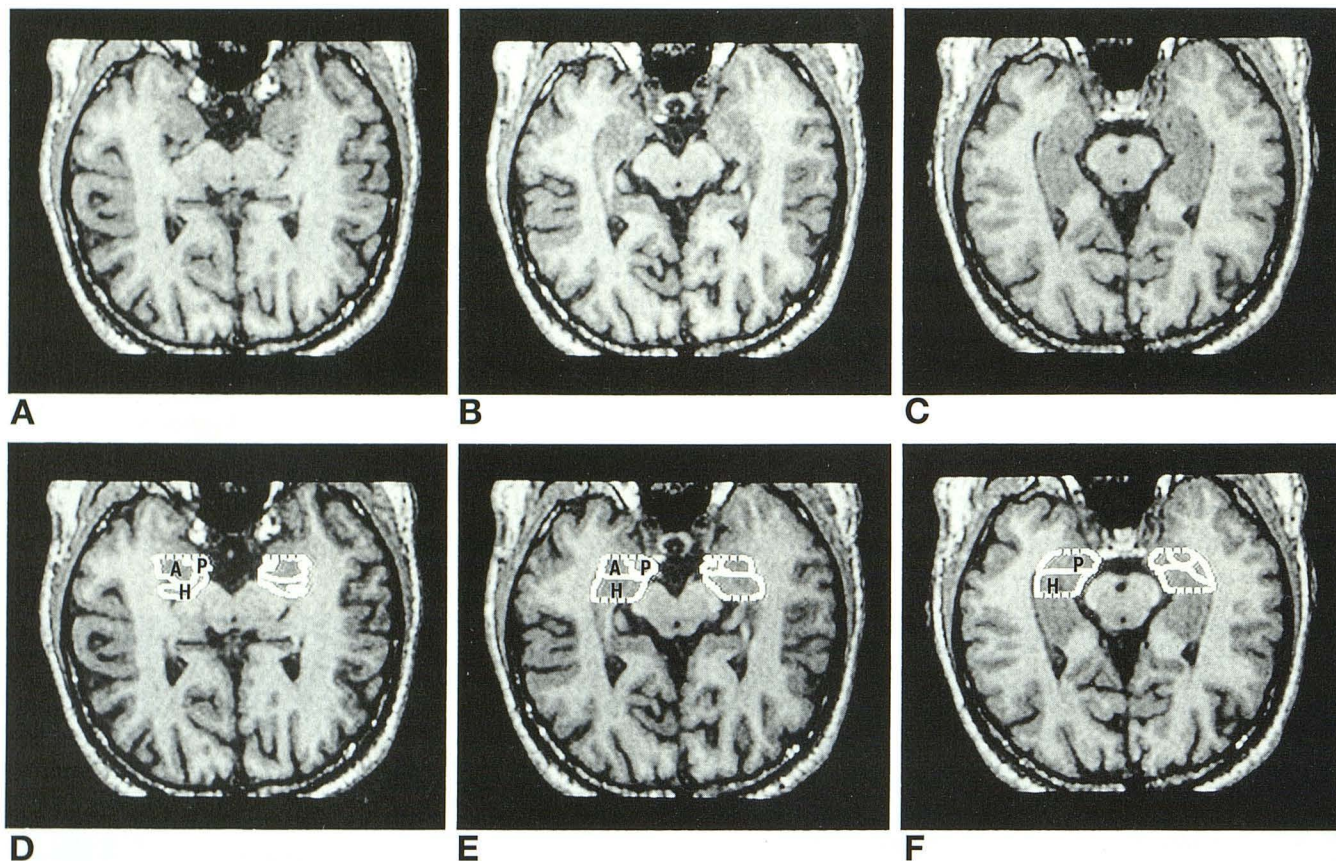


Fig 2. Axial images were obtained by reformatting by 90° the set of coronal images after the outlined regions were drawn. The axial images were constructed to have 3-mm section thicknesses. The reformatted axial images show the outlines of the three regions originally drawn on the coronal scan. The *interrupted lines* represent the anterior and posterior boundaries of the coronal levels selected.

dinal study of 10 control subjects and 10 patients with Alzheimer disease, and, second, they compared the interuncal distance measurement in an axial plane versus a coronal plane. Examination of the baseline axial interuncal distance data, with and without the head size correction, revealed no differences between the two groups, thus replicating the negative result of Early et al. Only at the follow-up did the group differences reach significance. One intuitively would conclude that deterioration in the Alzheimer disease group was responsible for the significance of the differentiation at follow-up. However, this was not the case. The values of the Alzheimer disease group were unchanged. Rather, as acknowledged by the authors, the different outcomes for the baseline and the follow-up comparisons were probably caused by errors of measurement on the baseline axial scans of the control group. In support of the possibility of a measurement error, it was reported that the control axial baseline study was associated with greater variability and a paradoxically larger mean than the axial follow-up measurement. The coronal interuncal distance data set significantly differentiated the groups on both observation periods. Nevertheless, even using the coronal interuncal distance, the authors comment that there was considerable overlap between healthy subjects and patients with Alzheimer disease. Howieson et

al concluded that the axial interuncal distance is prone to greater errors of measurement than the coronal interuncal distance, and overall the measurement is not suitable as a screening test for Alzheimer disease.

In summary, we tally the score for interuncal distance studies of Alzheimer disease as one positive report, one negative report, and two reports showing group statistical significance but, because of overlapping cases, no clinical significance.

Several methodological and anatomic issues have attracted our attention and cause us to reflect on the significance and meaning of the interuncal distance measurement. A growing body of literature identifies hippocampal and anterior parahippocampal (entorhinal cortex) neuropathologic alterations as early and consistent sites of Alzheimer disease (7–10). Even though it is surprising that the uncus anatomy has never been examined in an MR volume study of Alzheimer disease, there is a reasoned rationale for the measurement. In vivo detection of the gross anatomic correlates of the pathologic hippocampal changes have led to an accurate prediction of future Alzheimer disease in patients at risk (11, 12), improved computed tomographic diagnostic accuracies (13), and MR parenchymal volume studies that reported significant

volume losses in the hippocampi (14–17) and the amygdalas (18) of patients with Alzheimer disease. As in any new research area, the first in vivo imaging studies of the medial temporal lobe have relied on small samples of patients and have not consistently addressed issues of disease specificity, anatomic specificity, severity of dementia, gender differences, and the normal aging of the anatomy. Consequently, we and others do not (yet) have confidence in any clinical radiologic medial temporal lobe test for brain Alzheimer disease (1). Most specifically, the epidemiologic and anatomic uncertainties associated with the above medial temporal lobe studies, as well as the lack of direct studies of the uncus, impact negatively on our ability to interpret the highly variable outcomes of the interuncal distance studies. For example, are the between-study differences caused by selection characteristics of the patients with Alzheimer disease or by issues of anatomic sampling? Clearly, more clinical and anatomic-pathologic research is needed, as well as more comprehensive patient data in the published reports.

The anatomy and shape of the uncus is complex (19). The posterior portion of the uncus includes only the head of the hippocampus. It does not include the parahippocampal gyrus from which it is separated by the uncus sulcus (detectable on MR). The anterior uncus (anterior to the hippocampus) is formed by the upward and posterior folding of the parahippocampal gyrus. In the anterior uncus, the parahippocampal gyrus extends to the semilunar gyrus and to the most medial prominence, the gyrus ambiens. The later two gyri border the amygdala, and all are partially visible on coronal MR. This complex ovoid shape of the uncus (Figs 1 and 2) makes it difficult to identify a single uniform point from which to make linear interuncal distance-type measurements. The uncus and, secondarily, the interuncal distance measurement may be influenced by volume losses in the hippocampus, parahippocampus, and amygdala. Each of these regions potentially has a different extent of involvement according to the stage of Alzheimer disease. Therefore, it is unclear what a change in the interuncal distance measurement reflects anatomically. The interuncal distance is unlikely to show a simple linear relationship to any particular volume change.

There is considerable error of measurement on the axial interuncal distance. We reviewed 21 axial MR studies from 13 patients with Alzheimer disease and 8 healthy subjects. We found it difficult on the 5-mm-thick axial image to identify a standard section when anatomy external to the uncus (suprasellar cistern) was used to define the section to be selected. Figure 2 highlights the anatomic complexity of identifying the optimal point of measurement on the axial plane. The transitions between anatomic areas are not well appreciated, and this is especially true when there is variability in the section angulation and when thick sections are used. Atrophic brains and patients with small heads often did not have two sections to select from. Our data indicate that interuncal distance measurement differences of up to 25% can result from measurements taken from two adjoining 5-mm axial sections.

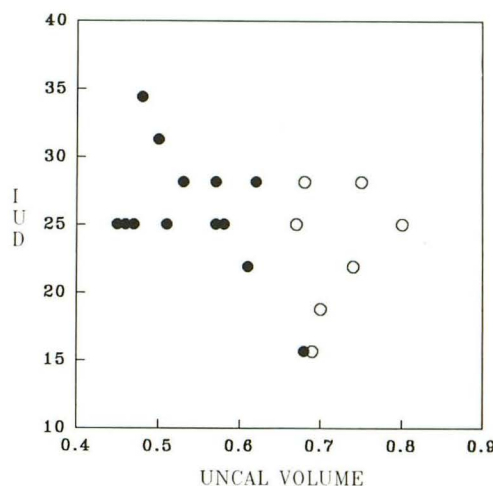


Fig 3. Plots of the average per-section uncus volume in cubic centimeters (x-axis) against interuncal distance (IUD) values in millimeters (y-axis) for patients with Alzheimer disease (solid circles) and control subjects (open circles). All measurements have been adjusted to real brain size. MR scans were obtained with a Phillips (Mahwah, NJ) Gyroscan 1.5-T imager using a T1-weighted spin-echo sequence (630/20/1). Coronal images used for volume determinations were oriented perpendicular to the long axis of the hippocampus, and the axials used to measure the interuncal distance were parallel to the long axis. The coronal and axial measurements were derived from 4-mm-thick sections with 10% gaps.

Given the absence of published data on the uncus in Alzheimer disease, we examined a subset of patients and control subjects in our previous Alzheimer disease volume study (17). We determined the uncus volumes on 5-mm T1-weighted coronal sections and the interuncal distance measurements on 5-mm T1-weighted axial sections. The uncus volume procedures we used were similar to those used by Early et al, and the axial interuncal distance measurements were obtained using the common procedure described in the above-mentioned papers. The results indicated that the uncus volume significantly differentiated 8 healthy subjects from 13 patients with Alzheimer disease when controlling for age and gender ($F[1,19] = 37.1; P < .0001$). The uncus volume measurements showed Alzheimer disease-related volume losses of 24% and evidence for an excellent overall diagnostic classification accuracy (greater than 95%). In Figure 3 we plot the association of our "uncus" volume and interuncal distance measurements for these subjects. As with previous studies, our control subjects all had interuncal distance values greater than 30 mm. Like the study by Early et al, we found no relationship ($P > .05$) between the volume and the interuncal distance in the healthy subjects. Moreover, we found no significant relationship after including the Alzheimer disease group in the correlation (see Fig 3). In our study, as in the study by Early et al, we did not find any statistical evidence that the interuncal distance measurement was useful for separating the Alzheimer disease and the control groups ($P > .05$).

In summary, we feel that the interuncal distance, as currently defined, is not a useful diagnostic tool for Alzheimer disease. Considerable work needs to be done on the anatomic validation of the interuncal distance measurement to reduce changes in the complex shape of the uncus to a simple measurement. We believe that continued in vivo study of the medial temporal lobe is of potential value in the diagnosis of Alzheimer disease, and additional clinical and anatomic studies of this brain region should be encouraged.

M. J. de Leon
A. Convit
S. DeSanti
C. Tarshish
S. H. Ferris

Department of Psychiatry
New York University Medical Center

A. E. George
H. Rusinek
L. Arena

Department of Radiology
New York University Medical Center

J. Golomb
M. Bobinski

Department of Neurology
New York University Medical Center
New York, NY
and
Institute for Basic Research
Staten Island, NY

References

- de Leon MJ, Golomb J, Convit A, DeSanti S, McRae TD, George AE. Measurement of medial temporal lobe atrophy in diagnosis of Alzheimer's disease. *Lancet* 1993;341:125-126
- LeMay M, Stafford JL, Sandor T, Albert M, Haykal B, Zamani A. Statistical assessment of perceptual CT scan ratings in patients with Alzheimer type dementia. *J Comput Assist Tomogr* 1986;10:802-809
- Dahlbeck SW, McCluney KW, Yeakley JW, et al. The interuncal distance: a new MR measurement for the hippocampal atrophy of Alzheimer disease. *AJNR Am J Neuroradiol* 1991;12:931-932
- Doraiswamy PM, McDonald WM, Patterson L, et al. Interuncal distance as a measure of hippocampal atrophy: normative data on axial MR. *AJNR Am J Neuroradiol* 1993;14:141-143
- Early B, Escalona PR, Boyko OB, et al. Interuncal distance measurements in healthy volunteers and in patients with Alzheimer disease. *AJNR Am J Neuroradiol* 1993;14:907-910
- Howieson J, Kaye JA, Holm L, Howieson D. Interuncal distance: marker of aging and Alzheimer disease. *AJNR Am J Neuroradiol* 1993;14:647-650
- de la Monte SM. Quantitation of cerebral atrophy in preclinical and end-stage Alzheimer's disease. *Ann Neurol* 1989;25:450-459
- Morris JC, McKeel DW, Storandt M, et al. Very mild Alzheimer's disease: informant-based clinical, psychometric, and pathological distinction from normal aging. *Neurology* 1991;41:469-478
- Price JL, Davis PB, Morris JC, White DL. The distribution of tangles, plaques and related immunohistochemical markers in healthy aging and Alzheimer's disease. *Neurobiol Aging* 1991;12:295-312
- Arriagada PV, Marzloff K, Hyman BT. Distribution of Alzheimer-type pathologic changes in nondemented elderly individuals matches the pattern in Alzheimer's disease. *Neurology* 1992;42:1681-1688
- de Leon MJ, George AE, Stylopoulos LA, Smith G, Miller DC. Early marker for Alzheimer's disease: the atrophic hippocampus. *Lancet* 1989;672-673
- de Leon MJ, Golomb J, George AE, et al. The radiologic prediction of Alzheimer's disease: the atrophic hippocampal formation. *AJNR Am J Neuroradiol* 1993;14:897-906
- George AE, de Leon MJ, Stylopoulos LA, et al. CT diagnostic features of Alzheimer disease: importance of the choroidal/hippocampal fissure complex. *AJNR Am J Neuroradiol* 1990;11:101-107
- Seab JP, Jagust WS, Wong SFS, Roos MS, Reed BR, Budinger TF. Quantitative NMR measurements of hippocampal atrophy in Alzheimer's disease. *Magn Reson Med* 1988;8:200-208
- Kesslak JP, Nalcioglu O, Cotman CW. Quantification of magnetic resonance scans for hippocampal and parahippocampal atrophy in Alzheimer's disease. *Neurology* 1991;41:51-54
- Jack CR Jr, Petersen RC, O'Brien PC, Tangalos EG. MR-based hippocampal volumetry in the diagnosis of Alzheimer's disease. *Neurology* 1992;42:183-188
- Convit A, de Leon MJ, Golomb J, et al. Hippocampal atrophy in early Alzheimer's disease: anatomic specificity and validation. *Psychiatr Q* 1993;64:371-387
- Scott S, DeKosky S, Scheff S. Volumetric atrophy of the amygdala in Alzheimer's disease: quantitative serial reconstruction. *Neurology* 1991;41:351-356
- Duvernoy HM. *The Human Hippocampus: An Atlas of Applied Anatomy*. Munich: JF Bergmann Verlag, 1988