

Generic Contrast Agents

Our portfolio is growing to serve you better. Now you have a *choice*.



FRESENIUS
KABI

[VIEW CATALOG](#)

AJNR

Occipital condyle fractures: clinical presentation and radiologic detection.

D A Clayman, C H Sykes and F S Vines

AJNR Am J Neuroradiol 1994, 15 (7) 1309-1315

<http://www.ajnr.org/content/15/7/1309>

This information is current as
of May 31, 2025.

Occipital Condyle Fractures: Clinical Presentation and Radiologic Detection

David A. Clayman, Charles H. Sykes, and Frederick S. Vines

PURPOSE: To describe the CT findings in occipital condyle fractures in patients suffering craniocervical trauma. **METHODS:** Six occipital condyle fractures in five patients were analyzed. Because of clinical or plain-film findings, the craniocervical junction in each patient was imaged using thin-section, high-resolution CT. Axial data were reformatted in the coronal plane or in both coronal and sagittal planes. Clinical and radiologic findings associated with occipital condyle fractures reported in the English medical literature were correlated with our cases to determine conclusive predictive features indicating condylar injury. **RESULTS:** Two avulsion (type III) fractures in two patients, two compression (type I) fractures in one patient, and two compression fractures in two patients were diagnosed by CT. Specific predictive features indicating occipital condyle fracture could not be confirmed. **CONCLUSIONS:** CT greatly facilitates diagnosing and typing of occipital condyle fractures. Nonspecific parameters prompting CT after trauma are unexplained persistent upper-neck pain with normal plain-film findings, lower cranial nerve palsies, spasmodic torticollis, retropharyngeal or prevertebral soft-tissue swelling, and fractures of the atlas or axis.

Index terms: Atlantooccipital joint; Occipital bone; Skull, fractures; Skull, computed tomography; Spine, computed tomography

AJNR Am J Neuroradiol 15:1309–1315, Aug 1994

In the spectrum of craniocervical injuries, occipital condyle fractures have been considered rare. After Bell's first report in 1817, only 17 cases were described through 1983 (1). Since 1983 the number of published cases in the world literature has more than doubled, with most having been published after 1988 (1).

We evaluated five patients with six occipital condyle fractures during a 4-year period. Only one patient had plain-film findings remotely suggesting a condyle injury. None of the clinical symptoms or signs suggesting cervical injury raised suspicion of a condylar fracture. The unexpected frequency of condylar fractures, the lack of specific predictive features for these

fractures, and the inherent difficulty in imaging the craniocervical junction prompted further investigation.

Our purpose is to increase awareness of and raise suspicion for occipital condyle fractures in patients suffering craniocervical trauma. We suggest criteria to prompt computed tomography (CT) of the craniocervical junction.

Patients and Methods

Four patients involved in severe motor vehicle accidents and one patient who was shot in the neck were evaluated. In each case, clinical or radiologic findings prompted thin-section, high-resolution CT study of the craniocervical junction. Two- to 3-mm-thick axial scans from the skull base above the level of the foramen magnum and through the C-2/C-3 intervertebral disk were acquired. The data were reformatted in either the coronal plane or in both coronal and sagittal planes.

The English medical literature was reviewed to investigate the frequency of reported occipital condyle fractures, to determine whether specific predictive clinical or radiologic features of condylar injury could be identified, and to define the optimal imaging modality for fracture diagnosis.

Received June 2, 1993; accepted pending revision August 5; revision received October 12.

From the Department of Radiology, University of Florida Health Science Center/Jacksonville.

Address reprint requests to David A. Clayman, MD, Department of Radiology, University of Florida Health Science Center/Jacksonville, 655 W Eighth St, Jacksonville, FL 32209.

AJNR 15:1309–1315, Aug 1994 0195-6108/94/1507-1309

© American Society of Neuroradiology

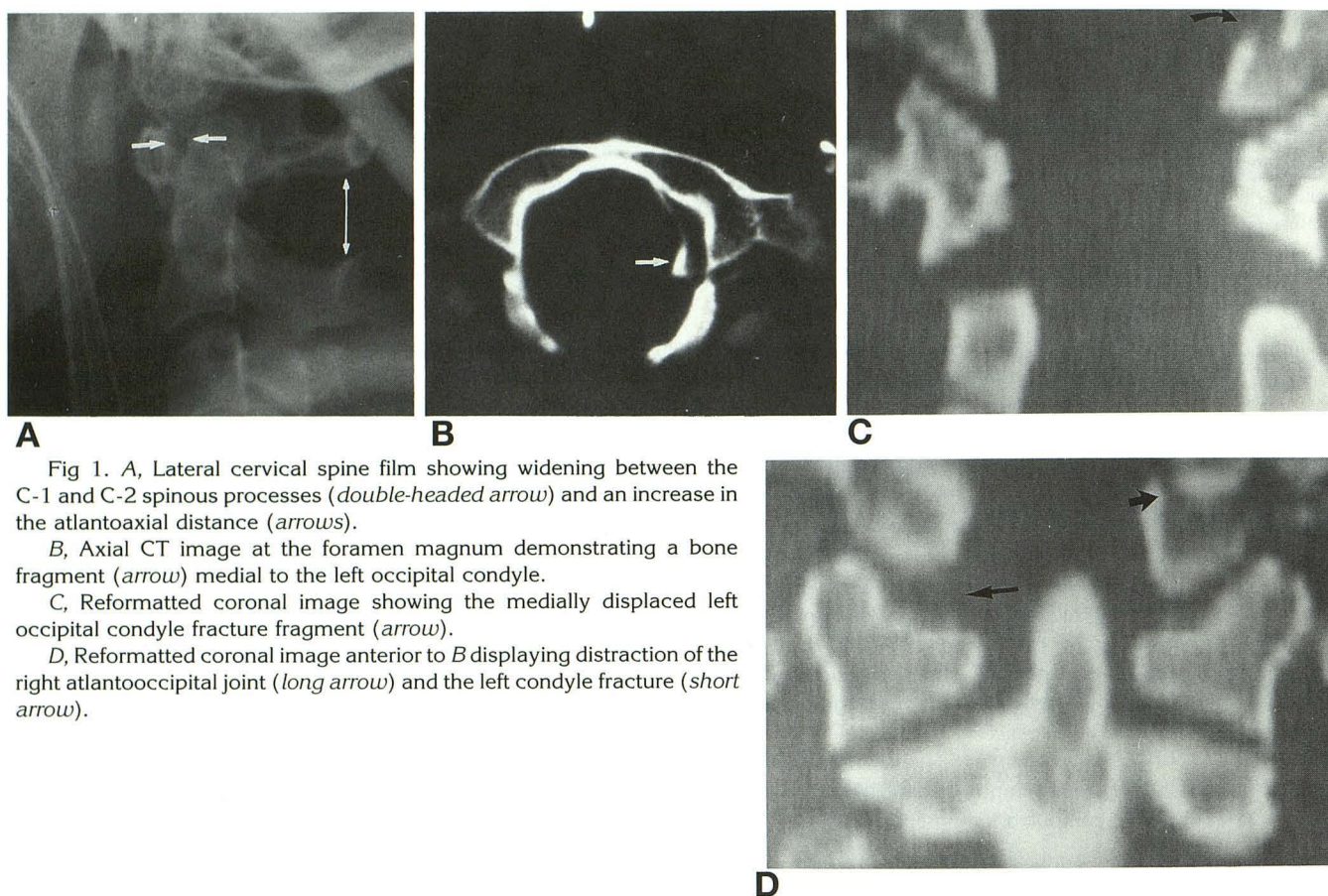


Fig 1. A, Lateral cervical spine film showing widening between the C-1 and C-2 spinous processes (double-headed arrow) and an increase in the atlantoaxial distance (arrows).

B, Axial CT image at the foramen magnum demonstrating a bone fragment (arrow) medial to the left occipital condyle.

C, Reformatted coronal image showing the medially displaced left occipital condyle fracture fragment (arrow).

D, Reformatted coronal image anterior to B displaying distraction of the right atlantooccipital joint (long arrow) and the left condyle fracture (short arrow).

Results

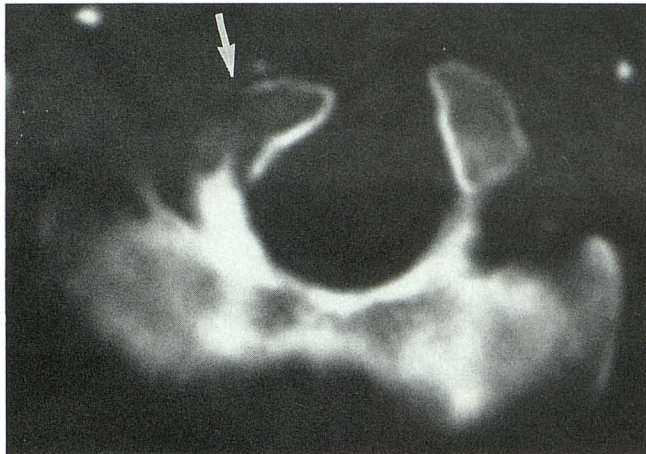
Clinically, two patients were neurologically intact at presentation. One patient with bilateral lower-extremity pareses had neck pain. One patient was unresponsive with decerebrate posturing. One patient presented with bilateral upper-extremity pareses compatible with central cord syndrome. The mechanism of injury was a motor vehicle accident in all cases except one. None had cranial nerve deficit. All but one had conservative treatment.

CT of the craniocervical junction was prompted by abnormal findings on cervical spine plain films in three cases. These findings were increased interspinous distance between C-1 and C-2, craniocervical dislocation, and traumatic spondylolisthesis of C-2. In another case, a CT scan of the head fortuitously included the occipital condyles and revealed a mildly displaced occipital condyle fracture. A gunshot wound to the upper neck generated the need for CT at the level of the craniocervical junction.

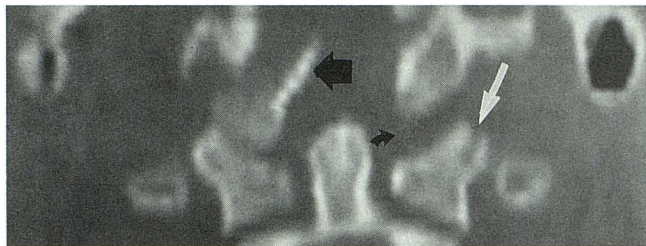
The diagnosis of occipital condyle fracture in all cases was made with CT. In two cases an occipital condyle fracture with medial displacement of the fracture fragment (Figs 1B, 1C, 2A, and 2B) and craniocaudal separation of the contralateral atlantooccipital joint (Figs 1D and 2B) were defined. In the remaining three cases four condylar fractures with little or no fragment displacement were identified (Figs 3B, 4A, and 5A). Atlantooccipital subluxation was not seen in these cases. Fractures in the first two cases were classified as type III avulsion injuries (see "Discussion"). The four fractures in the latter three cases were classified as type I compression injuries.

Discussion

Craniocervical junction injury is a common occurrence in motor vehicle accidents and diving injuries. Occipital condyle fractures are part of the spectrum of injury and can contribute significant morbidity, yet these fractures are rarely discussed.



A



B

Fig 2. A, 2-mm-thick axial CT image of skull base showing the right occipital condyle fracture rotated and medially displaced (arrow).

B, Reformatted coronal image demonstrating the medial tilt of the right condyle fracture fragment (straight black arrow) and distraction of the left atlantooccipital joint (curved arrow). Avulsed fracture from the superior lateral margin of the left lateral mass of C-1 (white arrow) is also shown.

Bucholz et al's postmortem study of 100 consecutive motor vehicle fatalities identified 24 patients with cervical spine injuries. Twenty of these injuries were localized between the occiput and C-2; only 12 of the 20 were clinically suspected before postmortem search. Two patients were found to have occipital condyle fractures (2). These findings indicate a greater than 8% incidence of occipital condyle fracture in cervical injury patients dying in motor vehicle accidents. The incidence of this injury in surviving patients remains unknown.

Our search of the medical literature reveals a significant increase in the reporting of occipital condyle fractures since 1988. From 1817 until 1974, before clinically available CT, we found 11 cases reported (1). Nine clinical cases and 2 autopsy cases are reported between 1978 and 1986 (1, 2). Since 1988, we find 18 new cases of which 14 are diagnosed by CT, 2 by CT plus polytomography, and 2 by polytomography (1,

3-10). The increase in diagnosis probably reflects improvements in CT technology and better trauma care, resulting in improved patient survival.

Diagnosis of an occipital condyle fracture, particularly the avulsed condyle (Figs 1B, 1C, 2A, and 2B), can be critical. Displacement and migration of the fractured condylar fragment can impinge and compress the brain stem and the lower cranial nerves (1, 11, 12). Delayed onset of lower cranial nerve function is reported (6, 7, 12) and may result from unrecognized instability at the craniocervical junction or late migration of an occipital condyle fracture fragment. Despite the potential for serious neurologic deficit or death, the mainstay of therapy remains conservative treatment, with immobilization the most common practice (1, 8, 10).

Wessels (10) and Bolender et al (12) describe five cases of occipital condyle fracture resulting in lower cranial nerve palsies. The hypoglossal canal is located at the base of the occipital condyle, and the jugular foramen is in close proximity lateral to the condyle. Cranial nerves IX, X, and XI passing through the jugular foramen and cranial nerve XII passing through the hypoglossal canal are susceptible to injury in the event of occipital condyle fracture. Palsies of the cranial nerves may result (10, 12). Cranial nerve palsy may not be present immediately after a traumatic event. Orbay describes a case of hypoglossal palsy which developed 3 months after the original trauma. It is postulated that callus formation or fracture mobility may have resulted in the late onset of nerve compression (6).

From our review of the literature, we could determine no conclusive predictive features leading to the specific diagnosis of occipital condyle fracture. Various clinical and radiologic findings reported are persistent neck pain and normal cervical spine films (1, 3), skull-base fracture (1), prevertebral soft-tissue swelling on plain film (8, 9), torticollis with only minor subluxation (7, 10), atlantooccipital distraction (4), brain-stem injury (1), and lower cranial nerve palsies (6, 10-13). Some previous reports have asserted a predictive value to lower cranial nerve palsy for occipital condyle fracture (3, 7, 8, 10, 11). Our own cases were the result of violent automobile accidents and one missile injury. Patient presentation was varied, but no lower cranial nerve palsies were detected.

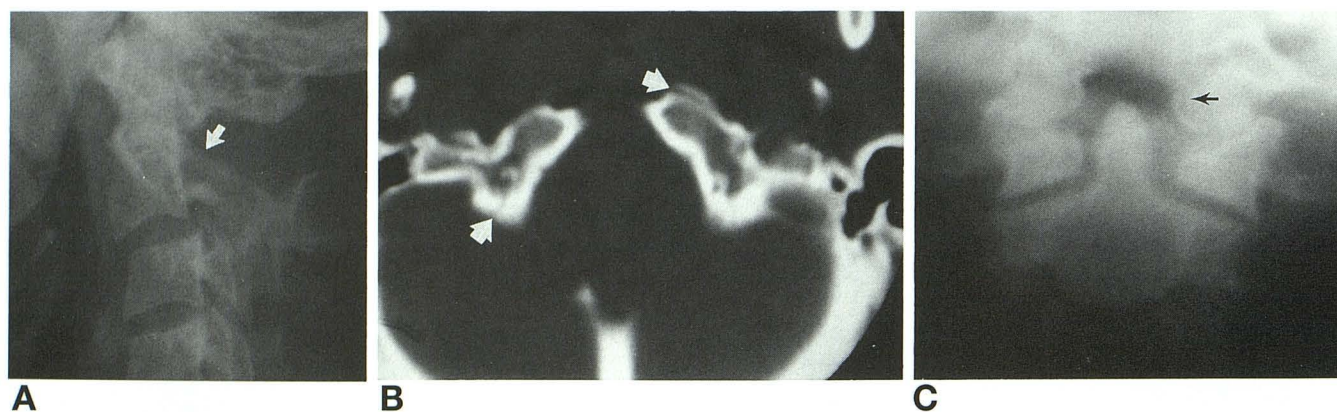
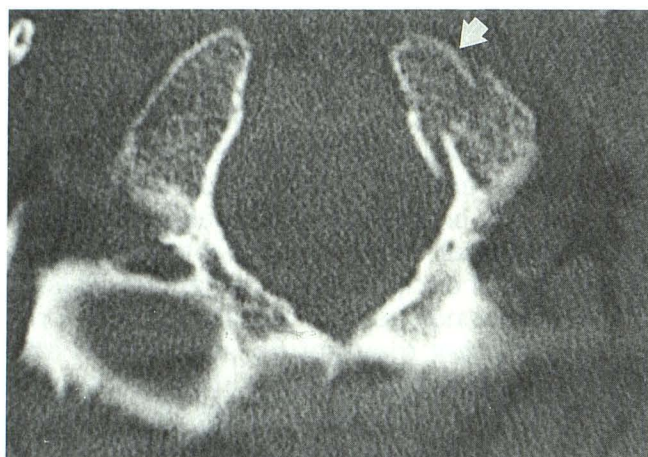


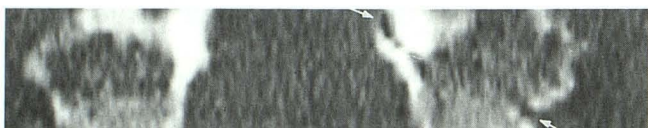
Fig 3. A, Lateral cervical spine film showing acute posterior angulation at the C-2/C-3 disk level, mild forward subluxation of C-2 on C-3, and C-2 lamina fractures (*arrow*), which are obscured by the overlying contralateral lamina.

B, Thin-section axial CT scan through the occipital condyles demonstrating a nondisplaced fracture through the right condyle and a minimally displaced left condyle fracture fragment (*arrows*).

C, Two-month follow-up coronal polytomogram showing a minimally displaced left occipital condyle fracture with the fracture line still visible (*arrow*).



A



B

Fig 4. A, Thin-section high-resolution axial CT image through the occipital condyles demonstrating a minimal medially displaced left occipital condyle fracture fragment (*arrow*).

B, Reformatted coronal image showing the oblique course of the fracture through the left occipital condyle (*arrows*).

Other previous case reports also describe no lower cranial nerve injury (1, 3, 5, 7–9, 11).

Despite the lack of specific predictors of the occipital condyle injury, our review reveals several parameters that, when present, should prompt further imaging of the craniocervical junction with high-resolution CT. These parameters are unexplained persistent posttraumatic

upper-neck pain with normal plain films, palsies of cranial nerves IX, X, XI, or XII, posttraumatic spasmodic torticollis, posttraumatic retropharyngeal or prevertebral soft-tissue swelling, upper cervical spine fracture/dislocation of the axis or atlas, or fracture of the occipital skull base. From our cases, one patient had prevertebral swelling and a questioned odontoid fracture (Fig 1A); one patient had atlantooccipital subluxation; and a third patient had bilateral C-2 lamina fractures (Fig 3A).

The occipital condyles form the superior portion of the craniocervical junction, which functionally consists of the occipital condyles, the atlas, and the axis. These structures are considered together because of their profound interrelationship with regard to the mechanics of the upper cervical spine. The articulation of convex occipital condyles on concave atlantosuperior facets is a configuration that allows good flexion-extension and lateral bending but limited axial rotation. The atlas-axis articulation provides liberal axial rotation; however, less flexion-extension and little lateral bending is permitted (14–16).

Ligamentous attachments to the occipital condyles are important for craniocervical stability. Arising from the superolateral surface of the dens, the alar ligaments connect the dens of the axis to the medial surfaces of the occipital condyles and to the lateral masses of the atlas (Fig 6B). The purpose of the alar ligaments is to restrain rotation of the upper cervical spine. The cruciform ligament is composed of the trans-

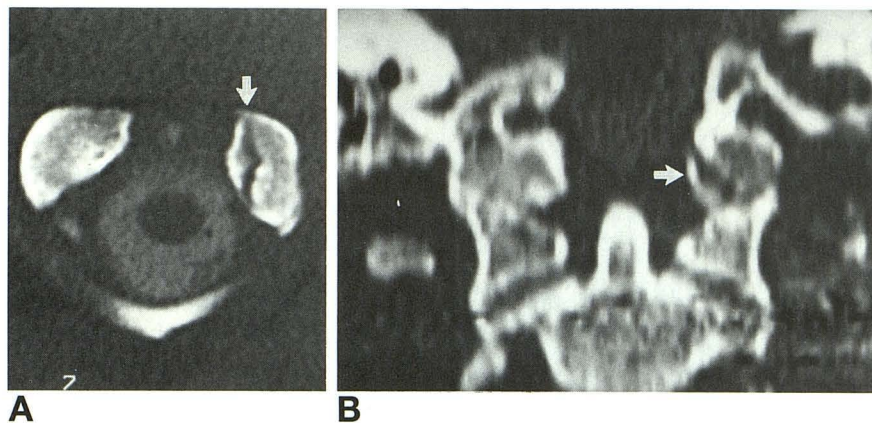


Fig 5. A, Axial CT image through the upper craniocervical junction demonstrating a fracture (arrow) on the left.

B, Reformatted coronal CT image clearly showing the fracture to arise from the medial margin of the left occipital condyle (arrow).

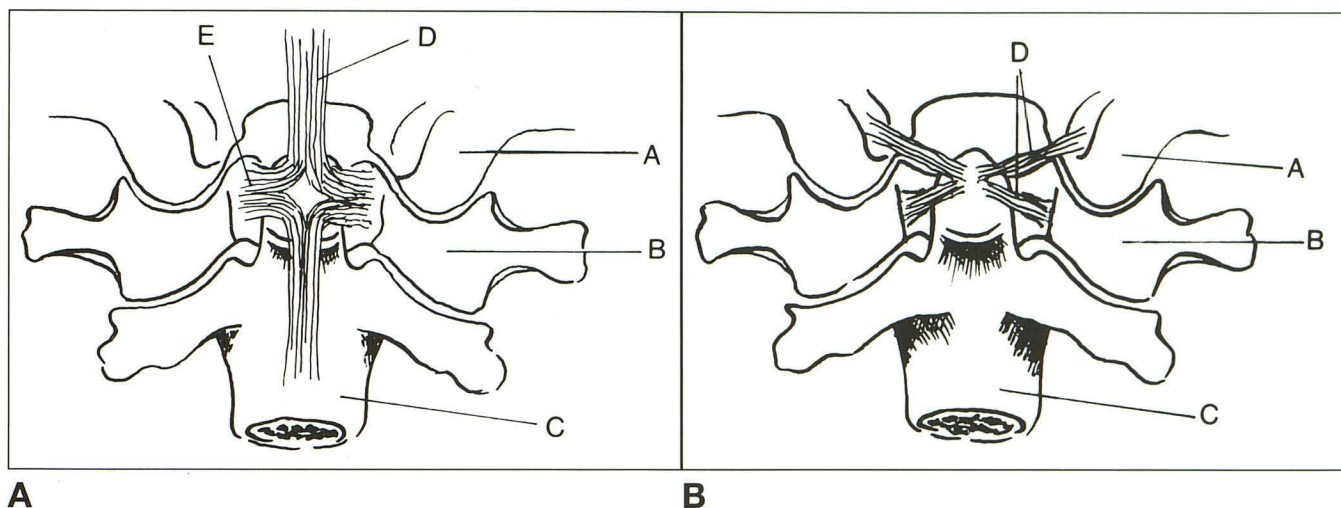


Fig 6. A, Posterior view of the craniocervical junction with the lamina and spinous processes of C-1 and C-2 removed; A indicates occipital condyle; B, lateral mass of C-1; C, body of C-2; D, superior longitudinal band; and E, transverse portion of the cruciform ligament.

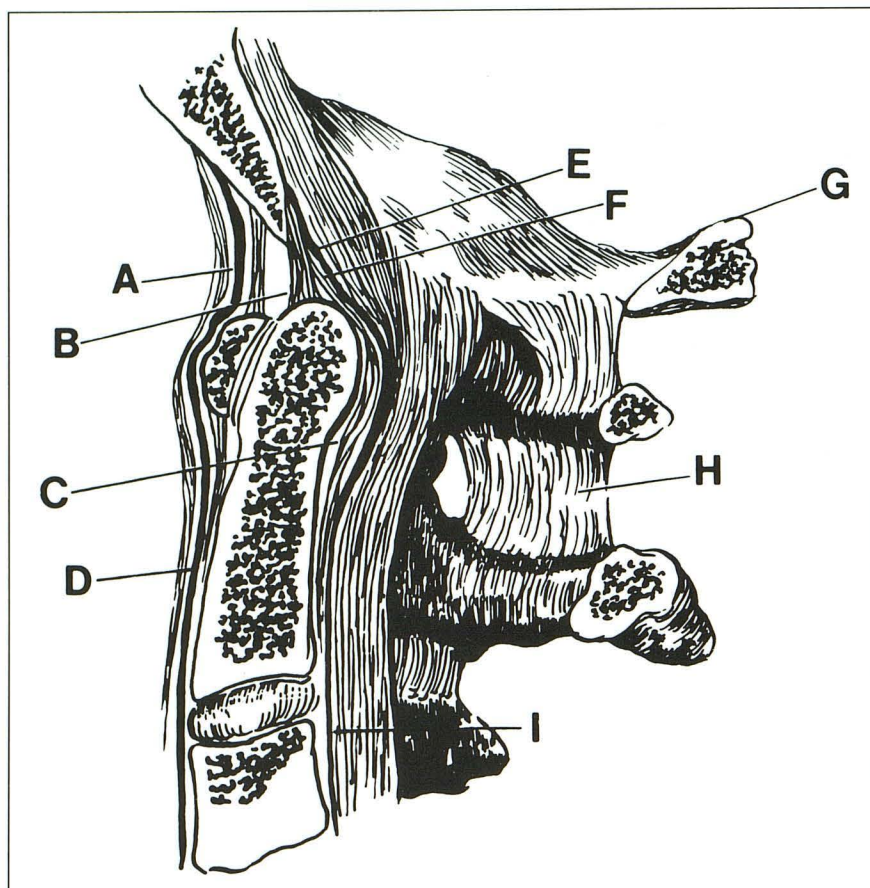
B, Same view as A, but with the cruciform ligament removed; A, B, and C are as in A; D, alar ligaments.

verse ligament of the atlas and the vertical longitudinal fasciculi (Fig 6A). The transverse ligament passes posterior to the dens, linking the lateral masses of the atlas. The vertical longitudinal fasciculi, also referred to as the superior and inferior longitudinal bands, are the weak and inconsistently present vertical components of the cruciform ligament. The superior longitudinal band blends with the atlantooccipital membrane (see below), joining the dorsal surface of the body and dens of the axis to the dorsal surface of the clivus. Together with the transverse ligament, these ligaments restrict both flexion at the craniocervical junction and anterior displacement of the atlas. Arising from the apex of the dens, the apical ligament secures the dens to the tip of the clivus. The anterior atlantooccipital membrane, the superior extension of the anterior longitudinal ligament,

and the tectorial membrane, the superior extension of the posterior longitudinal ligament, both attach to the anterior margin of the foramen magnum to provide further anterior support. The apical interspinous ligaments, ligamentum nuchae, and fibrous capsules of the atlantooccipital joints provide posterior support for the craniovertebral junction (Fig 7).

Three types of occipital condyle fractures have been described. The type I injury (Figs 3–5) is an impaction fracture occurring as a result of axial loading. Although the ipsilateral alar ligament may be functionally impaired, the intact tectorial membrane and contralateral alar ligament preserve spinal stability (1). Diving accidents and motor vehicle accidents are common causes of axial loading-type injuries to the occipitoatlantoaxial complex (17). The type II injury is a basilar occipital fracture that includes

Fig 7. Parasagittal view of craniocervical junction; A indicates anterior atlantooccipital membrane; B, apical ligament of the dens; C, transverse ligament; D, anterior longitudinal ligament; E, tectorial membrane; F, superior longitudinal band; G, occipital bone; H, interspinous ligament; and I, posterior longitudinal ligament.



or exits through one or both occipital condyles and results from direct trauma to the skull. Intact tectorial membrane and alar ligaments maintain stability. The type III injury (Figs 1 and 2) is an avulsion fracture of the occipital condyle and partial or complete tearing of the contralateral alar ligament and the tectorial membrane. The mechanism of injury is forced rotation, usually combined with lateral bending at the craniocervical junction. The condylar avulsion, combined with loading and injury to the contralateral alar ligament and tectorial membrane, makes the type III injury potentially unstable (1).

When imaging the upper cervical spine for trauma, it is imperative that one include the occipital condyles and lower occipital skull. High-resolution 2- to 3-mm-thick axial CT is the method of choice in examining the skull base (1, 7) and craniocervical junction for fracture. Hematoma and other soft-tissue injury also may be identified. Coronal and sagittal reconstructions may be extremely helpful to assess fracture displacement with particular reference to the spinal canal and spinal cord. Care must be

taken to ensure that off-midline sagittal images include the entire occipital condyle. If clinical conditions and time permit, 1.5-mm axial images could be acquired to allow for higher-quality coronal and sagittal reconstructions. Spiral or helical CT scanning enables reconstruction of axial images at 1-mm increments; overlapped stacking of the spiral axial images yields high-quality coronal and sagittal reformations. Plain-film examination to detect injury at the craniocervical junction is limited by complex overlying radiodensities. Normal variants of the occipital condyles further complicate radiographic evaluation (18). Assessment by magnetic resonance may be limited by the metal contents of some cervical halo braces and collars (19). Decreased cortical bone detail further limits magnetic resonance. Severity of clinical condition and remote access prevented timely magnetic resonance study of our patients. Conventional CT remains useful, primarily in the follow-up setting.

We and others (3, 4) believe occipital condyle fractures may be present more frequently than generally accepted, possibly as much as

8% of craniocervical junction injuries. There are no specific predictors of occipital condyle fracture; however, using parameters defined above to increased awareness and prompt CT examination, the true incidence of occipital condyle fractures eventually may be determined. CT with sagittal and coronal reconstructions is the modality of choice for evaluating craniocervical junction trauma. Imaging the craniocervical junction must include the lower occipital skull and condyles as well as the atlas and axis of the upper cervical spine. Diagnosis of the unstable type III avulsion fracture of the occipital condyle is important because of the potential for serious delayed neurologic injury. Treatment, however, remains conservative.

Acknowledgments

We thank Carole Welsh and Dorothy Shumate for their excellent manuscript preparation.

References

1. Anderson P, Montesano P. Morphology and treatment of occipital condyle fractures. *Spine* 1988;13:731-736
2. Bucholz RW, Burkhead WZ, Graham W, Petty C. Occult cervical spine injuries in fatal traffic accidents. *J Trauma* 1979;19:768-771
3. Sanjay SD, Coumas JM, Danylevich A, Hayes E, Dunn EJ. Fracture of the occipital condyle: case report and review of the literature. *J Trauma* 1990;30:240-241
4. Jones DN, Knox AM, Sage MR. Traumatic avulsion fracture of the occipital condyles and clivus with associated unilateral atlanto-occipital distraction. *AJNR Am J Neuroradiol* 1990;11:1181-1183
5. Curri D, Cervellini P, Zanusso M, Benedetti A. Isolated fracture of the occipital condyle: case report. *J Neurosurg Sci* 1988;32:157-159
6. Orbay T, Aykol S, Seckin Z, Ergun R. Late hypoglossal nerve palsy following fracture of the occipital condyle. *Surg Neurol* 1989;31:402-404
7. Salvoline ER, Ebraheim NA, Jackson WT, Rusin JJ. Three dimensional computed tomography in evaluation of occipital condyle fracture. *J Orthop Trauma* 1989;3:71-75
8. Valaskatzis EP, Hammer AJ. Fracture of the occipital condyle. *S Afr Med J* 1990;77:47-48
9. Mariani P. Occipital condyle fracture presenting as retropharyngeal hematoma. *Ann Emerg Med* 1990;19:1447-1449
10. Wessels LS. Fracture of the occipital condyle. *S Afr J Surg* 1990;28:155-156
11. Spencer J, Yeakley J, Kaufman H. Fracture of the occipital condyle. *Neurosurg* 1984;15:101-103
12. Bolender N, Cromwell LD, Wendling L. Fracture of the occipital condyle. *AJR Am J Roentgenol* 1978;131:729-731
13. Jacoby CG. Fracture of the occipital condyle. *AJR Am J Roentgenol* 1979;132:500
14. Goel VK, Clark CR, Gallaes K, Liv YK. Moment-rotation relationships of the ligamentous occipito-atlanto-axial complex. *J Biomech* 1988;21:673-680
15. Levine AM, Edwards CC. Traumatic lesions of the occipito-atlanto-axial complex. *Clin Orthop* 1989;5:3-68
16. Dvorak J, Schneider E, Saldinger P, Rahn B. Biomechanics of the craniocervical region: the alar and transverse ligaments. *J Orthop Res* 1988;6:452-461
17. Shkrum MJ, Green RN, Nowak ES. Upper cervical spine trauma in motor vehicle collisions. *J Forensic Sci* 1989 Mar;34:381-390
18. Keats TE. *Atlas of Normal Roentgen Variants That May Simulate Disease*. St. Louis: Mosby Yearbook, 1992:147-149
19. Clayman DA, Murakami ME, Vines FS. Compatibility of cervical spine braces with MR imaging: a study of nine nonferrous devices. *AJNR Am J Neuroradiol* 1990;11:385-390