



Discover Generics

Cost-Effective CT & MRI Contrast Agents



FRESENIUS
KABI

WATCH VIDEO

AJNR

Fast spin-echo imaging of the neck: comparison with conventional spin-echo, utility of fat suppression, and evaluation of tissue contrast characteristics.

J S Lewin, H D Curtin, J S Ross, J L Weissman, N A Obuchowski and J A Tkach

This information is current as of June 1, 2025.

AJNR Am J Neuroradiol 1994, 15 (7) 1351-1357
<http://www.ajnr.org/content/15/7/1351>

Fast Spin-Echo Imaging of the Neck: Comparison with Conventional Spin-Echo, Utility of Fat Suppression, and Evaluation of Tissue Contrast Characteristics

Jonathan S. Lewin, Hugh D. Curtin, Jeffrey S. Ross, Jane L. Weissman, Nancy A. Obuchowski, and Jean A. Tkach

PURPOSE: To determine whether fast spin-echo sequences could replace conventional spin-echo methods in the evaluation of head and neck neoplasms and associated adenopathy and to evaluate differences in tissue contrast characteristics between conventional spin-echo and fast spin-echo examinations of head and neck disease. **METHODS:** Twenty-seven patients with squamous cell carcinoma were imaged on a 1.5-T imager with both conventional spin-echo and fast spin-echo sequences with identical section thickness and position. Twenty-one of the 27 fast spin-echo studies were performed with frequency-selective fat suppression. Three radiologists independently evaluated the images using a five-point scale to compare primary lesion margin definition and conspicuity, lymph node margin definition and conspicuity, gross motion artifact, and flow artifact. Quantitative percent contrast and contrast-to-noise ratios were calculated and compared in 7 cases with fat-suppressed fast spin-echo. **RESULTS:** Fast spin-echo was preferred by all three readers for lesion margin conspicuity and lymph node conspicuity. Gross motion and flow artifact demonstrated trends toward reader preference for fast spin-echo. Quantitative contrast values for fast spin-echo were significantly greater than those for conventional spin-echo. **CONCLUSIONS:** Fast spin-echo with fat suppression can replace conventional spin-echo at a time savings of more than 50% and improves tissue contrast and the conspicuity and definition of margins for primary lesions and lymph nodes. Fat-suppression heterogeneity remains the major limitation of this technique. Thus, careful attention to fat-suppression failure and unwanted water saturation is essential.

Index terms: Magnetic resonance, comparative studies; Magnetic resonance, fat suppression; Magnetic resonance, tissue characterization; Neck, magnetic resonance; Neck, neoplasms

AJNR Am J Neuroradiol 15:1351-1357, Aug 1994

Spin-echo T2-weighted images have been fundamental in the magnetic resonance (MR) detection and characterization of head and neck tumor and lymphadenopathy. Unfortunately, the large anatomic area of interest and spatial

resolution requirements necessary for the evaluation of many head and neck abnormalities typically result in long imaging times, which may increase motion artifact.

Recently, refined fast spin-echo techniques, based on the rapid acquisition relaxation enhanced method first described by Hennig et al (1), produce high-quality images with spin-echo contrast in a greatly reduced imaging time. The purpose of this investigation was to determine whether fast spin-echo sequences could replace conventional spin-echo methods in the evaluation of head and neck neoplasms and associated adenopathy in terms of image quality and lesion conspicuity and to evaluate differences in tissue contrast characteristics between conventional spin-echo and fast spin-echo examinations in the evaluation of head and neck disease.

Received July 21, 1993; accepted after revision February 22, 1994.

Presented at the 31st Annual Meeting of the American Society of Neuroradiology, Vancouver, British Columbia, Canada, May 16-19, 1993.

Supported in part by National Institutes of Health Grant 1RO1CA54016-03.

From the Cleveland Clinic Foundation, Department of Radiology (J.S.L., J.S.R., N.A.O., J.A.T.); and the Pittsburgh Eye and Ear Hospital, Department of Radiology, University of Pittsburgh.

Address reprint requests to Jonathan S. Lewin, MD, Department of Radiology, Case Western Reserve University, University Hospitals of Cleveland, 11100 Euclid Ave, Cleveland, OH 44106.

AJNR 15:1351-1357, Aug 1994 0195-6108/94/1507-1351

© American Society of Neuroradiology

Subjects and Methods

Twenty-seven patients with newly diagnosed squamous cell carcinoma of the oral cavity/oropharynx ($n = 12$) or hypopharynx/larynx ($n = 15$) were imaged on a standard clinical 1.5-T imager. All patients presenting for MR of the neck with newly diagnosed lesions were included in the study if their clinical condition and the imaging schedule permitted. Axial conventional spin-echo was performed in all cases, with imaging parameters of 2566 to 3216/30, 80 (repetition time/echo time) and matrix/excitations of $256 \times 128/2$ ($n = 18$), $256 \times 192/1$ ($n = 7$), $256 \times 192/2$ ($n = 1$), or $256 \times 256/1$ ($n = 1$). The conventional spin-echo study was a double-echo sequence with only the second echo evaluated in this investigation. Flow compensation and superior and inferior saturation pulses were applied. Imaging time averaged 13 minutes 12 seconds, with a range of 10 minutes to 22 minutes 30 seconds. A single effective-echo axial fast spin-echo study was performed after the conventional spin-echo examination, with parameters 3000–4600/84–102, echo train length of 8, 16- to 21-millisecond interecho spacing, and matrix/excitations of $256 \times 192/2$ ($n = 22$), $256 \times 192/1$ ($n = 2$), $256 \times 192/4$ ($n = 1$), $256 \times 128/4$ ($n = 1$), or $256 \times 256/4$ ($n = 1$).

Frequency-selective fat suppression was applied in 21 patients, with no fat suppression in the remaining 6 patients. Superior and inferior presaturation pulses were applied in all 6 patients without fat suppression and in 14 of the 21 patients imaged with fat-suppression techniques. The imaging time averaged 5 minutes 20 seconds, with a range of 2 minutes 36 seconds to 11 minutes 34 seconds. Flow compensation techniques were not used with the fast spin-echo examinations.

Axial 5-mm sections were obtained with a 1-mm inter-section gap from the level of the occlusal plane to the thoracic inlet in identical positions for fast spin-echo and conventional spin-echo examinations. The scans were continued to the skull base in selected cases in which superior extension of disease was suspected. A 16-kHz bandwidth was used for both fast spin-echo and conventional spin-echo examinations.

During the examination, all patients underwent spin-echo T1-weighted acquisitions in the axial, coronal, or sagittal planes, with or without gadopentatate dimeglumine contrast administration. These were used for diagnosis but were not included in this analysis.

Comparative Data Analysis

The conventional spin-echo and fast spin-echo images were compared by three experienced radiologists independently and rated on a five-point scale, with 1 indicating conventional spin-echo significantly better than fast spin-echo; 2, conventional spin-echo somewhat better than fast spin-echo; 3, conventional spin-echo equivalent to fast spin-echo; 4, fast spin-echo somewhat better than conventional spin-echo; and 5, fast spin-echo significantly better than conventional spin-echo. Using this scale, the

readers assessed the variables gross motion artifact, flow artifact, lesion conspicuity and margin definition, and lymph node conspicuity and definition. Significant differences in findings between the studies were noted. In addition, each reader ranked fat-suppression homogeneity on a four-point scale, from poor to excellent. All evaluations were performed on equivalently positioned images.

Quantitative Contrast Evaluation

Percent contrast and contrast-to-noise ratios were calculated in seven patients in whom fast spin-echo with fat suppression was performed, through manual placement of a region of interest over the maximal area of the tissue of interest for measurement of mean absolute signal intensity, comparing lymph node versus muscle, lymph node versus fat, lesion versus muscle, and lesion versus fat. The regions of interest were compared only for adjacent tissues to reduce the effects of receiver and fat-suppression heterogeneity and were of identical size and position for the conventional spin-echo and fast spin-echo examinations. Percent contrast was then calculated using the equation $\%contrast = (S_l - S_b)/S_b$, with S_l representing mean signal intensity within the region of interest for the lymph node or lesion and S_b the mean signal intensity for the muscle or fat background tissue (2). Contrast-to-noise ratios were calculated using two different methods, one using a region of interest over air to measure electronic noise (CNR_a) and the other using the standard deviation of the background tissue to approximate tissue noise in combination with electronic noise (CNR_b) (2). These were calculated with the following equations: $CNR_a = (S_l - S_b)/(S_{air}/\sqrt{\pi})$, and $CNR_b = (S_l - S_b)/SD_b$, where S_{air} represents the mean signal intensity from a region of interest in air outside the neck, and SD_b represents the standard deviation of the background tissue (2).

Statistical Analysis

For the reader image comparison, the hypothesis that conventional spin-echo was equivalent to fast spin-echo was tested for each variable in each reader using the Wilcoxon Signed Rank Test. The results of percent contrast, CNR_a , and CNR_b were compared testing the hypothesis that conventional spin-echo and fast spin-echo were equal. The paired t test was used when the values were normally distributed; the Wilcoxon Signed Rank Test was applied for nonnormal distributions.

Results

Direct Comparison

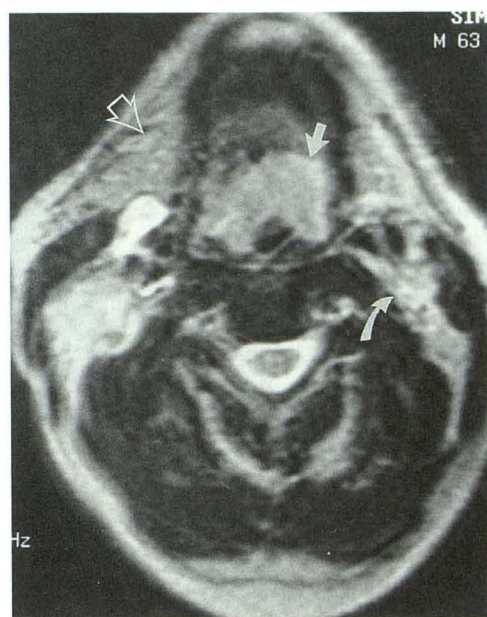
Lesion margin conspicuity was worse on fast spin-echo than conventional spin-echo in only 2 of 80 reader comparisons, equivalent in 17, somewhat better on fast spin-echo in 40, and significantly better on fast spin-echo in 21

TABLE 1: Results of Wilcoxon Signed Rank Tests

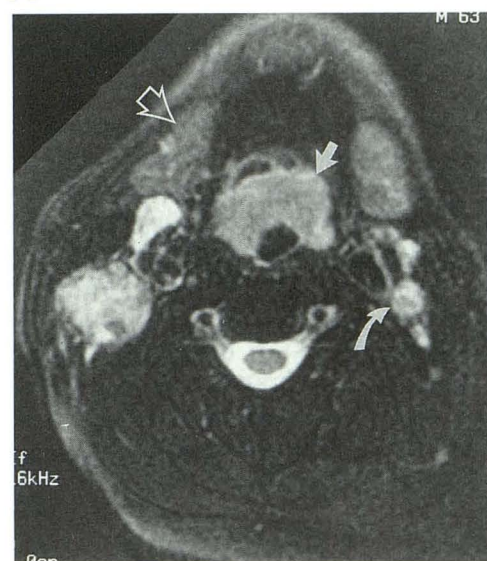
	Two-Tailed P Values		
	Reader 1	Reader 2	Reader 3
Lesion margin conspicuity	<.01	<.01	<.01
Lymph node conspicuity	<.01	<.01	<.01
Gross motion artifact	.16	.09	<.01
Flow artifact	.34	<.01	.09

reader comparisons. When analyzed alone, fast spin-echo with fat suppression was judged equivalent to or better than conventional spin-echo in all 63 reader comparisons. Lymph node conspicuity was better on conventional spin-echo than fast spin-echo in 4 of 81 reader comparisons and better on fast spin-echo in 64 reader comparisons. For gross motion artifact, conventional spin-echo was better than fast spin-echo in 6, equivalent in 45, and better on fast spin-echo in the remaining 30 reader comparisons. Flow artifact was better on conventional spin-echo than fast spin-echo in 8 reader comparisons, equivalent in 33, and better on fast spin-echo in the remaining 40 reader comparisons. The results of statistical analysis of the comparative rating for each of the variables for each reader are presented in Table 1. Of note, *P* values less than .01 for the variables lesion margin conspicuity and lymph node conspicuity demonstrate that conventional spin-echo and fast spin-echo are not equivalent, with fast spin-echo preferred by all three readers (Figs 1 and 2). In 5 of 6 interpretations in which conventional spin-echo was preferred over fast spin-echo for lesion or node conspicuity, fast spin-echo was performed without fat suppression. For gross motion artifact, reader 3 clearly preferred fast spin-echo, reader 1 had no preference, and reader 2 tended to show greater preference for fast spin-echo, particularly after eliminating cases with poor fat-saturation homogeneity. For flow artifact, reader 2 preferred fast spin-echo, and readers 1 and 3 showed no significant preference.

Although there was an observable difference in lesion conspicuity, a significant difference in lesion detection was not observed. No significant discrepancies occurred between the results of MR evaluation and findings on surgical resection.



A



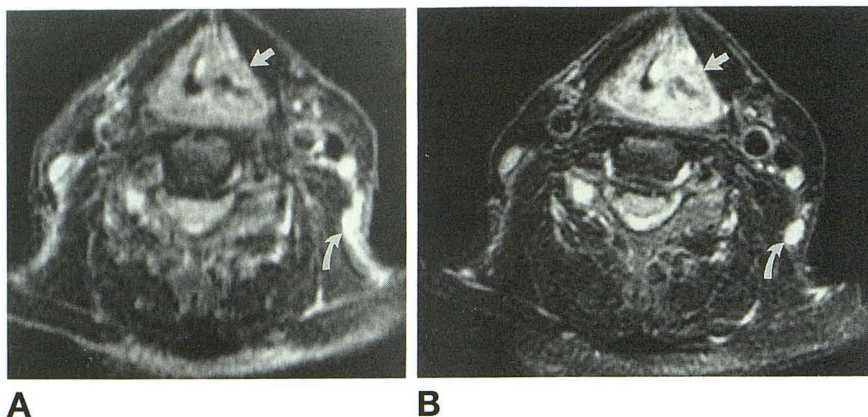
B

Fig 1. Supraglottic carcinoma.

A, Conventional spin-echo (3000/80, 256 × 128 matrix) and B, fast spin-echo with fat suppression (2500/102, 256 × 192 matrix). Margins of supraglottic carcinoma are better defined on the fast spin-echo image, and contrast between the tumor and surrounding tissues is much greater on the fast spin-echo study (straight arrow). Spinal accessory chain lymph nodes are more conspicuous on the fast spin-echo examination than the conventional spin-echo study because of the decreased signal intensity of adjacent fat (curved arrow). Note appearance of the submandibular glands on the fast spin-echo examination compared with the conventional spin-echo study (open arrow).

Fig 2. Transglottic carcinoma.

A, Conventional spin-echo (2750/80, 256 × 128 matrix) and B, fast spin-echo with fat suppression (3000/102, 256 × 192 matrix). Primary carcinoma is well visualized on both examinations, with slightly better margin definition on the fast spin-echo examination (*straight arrow*). Spinal accessory chain lymph nodes are again better visualized on the fast spin-echo study because of decreased signal from surrounding fat with the fat-suppression technique (*curved arrow*).



Technical Quality

Averaged among the three readers, fat-suppression homogeneity was considered poor in 17%, fair in 31%, good in 46%, and excellent in 6%.

Tissue Contrast Characteristics and Contrast-to-Noise Ratio Evaluation

Table 2 outlines percent contrast, CNR_a , and CNR_b calculations for conventional spin-echo and fast spin-echo examinations, along with the P values from testing the hypothesis that contrast values for fast spin-echo and conventional spin-echo are equal. Contrast values for fast spin-echo are greater than those for conventional spin-echo, with statistical significance at the .05 level reached for all comparisons except the node/muscle measurement by the CNR_a method and lesion/muscle by the CNR_b method.

Discussion

Fast spin-echo techniques are based on the rapid acquisition relaxation enhanced method

first described by Hennig et al (1). Multiple echoes are collected after each section excitation, with each echo separately phase encoded to fill a distinct spatial frequency line in k-space (1, 3, 4). This basic modification of the Carr-Purcell-Meiboom-Gill pulse sequence results in spin-echo contrast in a greatly reduced imaging time.

The degree of T2 weighting in fast spin-echo is determined by the effective echo time, which is defined by the choice of echo assigned to the central or low spatial frequency segment of k-space (ie, that which includes the zero order phase-encoding line) (3–5). In this investigation, later echoes were used to fill the lower spatial frequency portions of k-space, with the higher spatial frequency data acquired at earlier echoes. This phase-reordering scheme results in a filtering effect, which may yield a slight edge or small object enhancement compared with conventional spin-echo techniques (3).

One of the most noticeable differences from conventional spin-echo with the more commonly used k-space trajectories is the increased signal from fat on T2-weighted images (3). This results from suppression of J-coupling

TABLE 2: Mean contrast calculations (standard error)

		Node/Muscle	Node/Fat	Lesion/Muscle	Lesion/Fat
Percent contrast	Fast spin-echo	445 (90)	173 (29)	359 (56)	170 (24)
	Conventional spin-echo	314 (50)	31 (15)	276 (35)	16 (8)
	P values*	.031	.003	.031	.005
CNR_a	Fast spin-echo	45 (6)	38 (9)	39 (5)	34 (6)
	Conventional spin-echo	42 (7)	13 (6)	33 (4)	6 (3)
	P values*	.436	.008	.018	.013
CNR_b	Fast spin-echo	19 (3)	12 (2)	13 (1)	11 (2)
	Conventional spin-echo	12 (2)	3 (1)	10 (1)	1 (1)
	P values*	.041	.010	.100	.029

* Contrast comparison for fat-suppression fast spin-echo versus conventional spin-echo, two-tailed.

modulation with fast spin-echo when a sufficiently short interecho spacing is used and may result in up to 20% to 30% enhancement of signal intensity from fat (6). In addition, the multiple closely spaced 180° pulses also may decrease signal losses from diffusion, which also leads to an increase in the signal intensity of fat (6).

Another feature of fast spin-echo that may alter contrast as compared with conventional spin-echo is the enhancement of magnetization transfer effects resulting from the large number of off-resonant 180° radio frequency pulses applied in multisection fast spin-echo imaging (3). In the neck, this effect may result in preferential signal loss from tissues such as muscle.

Several of the differences between fast spin-echo and conventional spin-echo can be used to advantage in evaluation of the neck. The first is the time savings, which can be used to shorten the patient examination time, to increase spatial resolution or excitations, or to acquire additional imaging planes or pulse sequences. A reduction in susceptibility-induced phase dispersion (7) also may provide an advantage in the neck through improved depiction of lesions at the mucosa-air interface. With fat-suppression techniques, fast spin-echo also demonstrates increased contrast between lymph nodes or primary lesions and surrounding fat (Figs 1 and 2) (8).

Several disadvantages are inherent in the fast spin-echo technique when evaluating the neck. Fat surrounds many important structures in the neck, such as lymph nodes and the supraglottic airway. The high signal intensity of fat in fast spin-echo sequences therefore may hinder the MR assessment of these structures when fat-suppression techniques are not used (4, 8). In the present investigation, fat suppression was performed through application of a frequency-selective radio frequency pulse followed by gradient dephasing before section excitation. When working properly, this technique results in excellent, uniform suppression of fat throughout the area of interest (Figs 1 and 2). However, nonuniform fat saturation is not uncommon in the neck and can result from static magnetic field heterogeneities, susceptibility artifact from the changing shape of the neck as one scans from the skull base to the thoracic inlet, or from metallic foreign bodies within the patient. Poor fat saturation can lead to decreased detection of high-signal abnormalities surrounded by the

high-signal fat. Furthermore, field heterogeneity can lead to water saturation by the frequency-selective pulse (Fig 3). This limitation theoretically can be overcome through the use of alternative fat-suppression techniques, such as the three-point Dixon method or inversion-recovery techniques (8, 9). The use of a collar to reduce the susceptibility effects of the shape of the neck on frequency-selective fat suppression also has been described, with encouraging initial results (Cox IH, Dillon WP, Alternative Substances for Avoiding Bulk Susceptibility Artifact in Chemical Fat Saturation MR Imaging of the Head and Neck, Presented at the 31st Annual Meeting of the American Society of Neuroradiology, Vancouver, British Columbia, Canada, May 1993).

Many of these theoretical advantages and disadvantages of fast spin-echo are supported in the results of this investigation. The fast spin-echo parameters in this study do not result in the minimal imaging time, but rather "trade" some of the time savings for increased spatial resolution and increased signal-to-noise ratio. Despite the increase in excitations and matrix size with fast spin-echo compared with conventional spin-echo, the overall imaging time is still reduced by more than a factor of 2. This large reduction likely contributes to the trend for decreased motion artifact with fast spin-echo. A marked improvement in contrast on fast spin-echo with fat suppression is demonstrated in the percent contrast and contrast-to-noise ratio calculations. As expected, the largest improvement on fast spin-echo with fat suppression was noted when comparing the primary lesion or lymph node with fat (Table 2). The observed increase in contrast of the primary lesion or lymph node relative to muscle with fast spin-echo is less intuitive but probably relates to stronger T2 weighting on fast spin-echo resulting from a longer effective echo time (average effective echo time of 92.6 milliseconds for fast spin-echo versus 80 milliseconds for conventional spin-echo), along with a decrease in muscle signal on fast spin-echo from an increase in magnetization transfer. Suppression of fat within muscle and septae also may contribute to the observed decrease in muscle signal intensity.

These effects are evident not only in calculations but on visual inspection of the images (Figs 1 and 2). The greater conspicuity and better margin definition observed with fast spin-

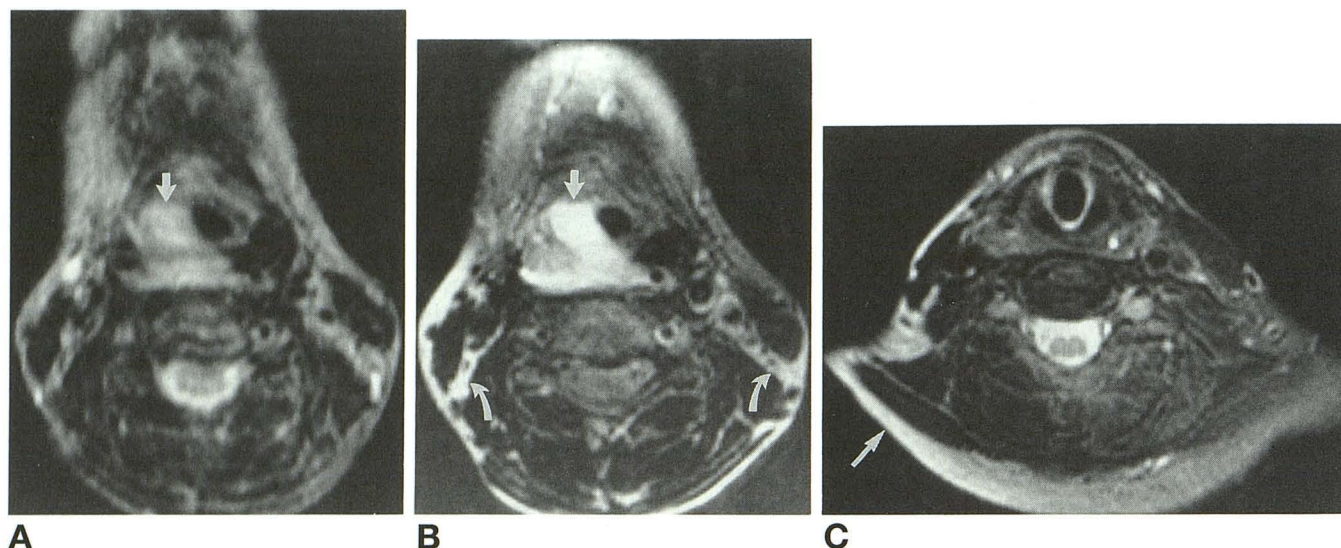


Fig 3. Supraglottic carcinoma, poor fat-suppression homogeneity.

A, Conventional spin-echo (3000/80, 256×128 matrix) and B, fast spin-echo with fat suppression (4000/85, 256×192 matrix). Although the primary lesion margin definition is better on the fast spin-echo examination (*straight arrow*), a failure of fat suppression results in bright fat in the posterior cervical spaces on the fast spin-echo study (*curved arrows*). Undesired water saturation results in loss of signal from cerebrospinal fluid and from small lymph nodes, which appear *black* on the fast spin-echo examination.

C, Lower section from the fast spin-echo examination again demonstrates failure of fat suppression, with bright fat and dark muscle from water saturation on the patient's right (*straight arrow*), compared with satisfactory fat suppression and brighter muscle on the patient's left.

echo in the comparative reader data likely arose from a combination of these improvements in contrast-to-noise ratio along with better spatial resolution and higher signal-to-noise from the increased excitations made possible by the reduced imaging time.

Several subjective contrast differences also can be observed, including a relative increased brightness of cerebrospinal fluid compared with background noted both on visual evaluation and region of interest measurement. The signal intensity of salivary gland tissue varied somewhat from patient to patient. This most likely relates to differences in fat content. In general, the parotid and submandibular glands appear slightly less intense on fast spin-echo with fat suppression compared with conventional spin-echo, but they remain intermediate in signal intensity between the suppressed fat and muscle signal and the typically high-signal lesion or lymph node (Fig 1). Normal lymphoid tissue within the faucial and lingual tonsils also remains bright on fast spin-echo with fat suppression and is similar in signal intensity to lymph nodes and primary squamous cell carcinoma. Fluid collections within necrotic lymph nodes appear somewhat brighter on fast spin-echo with fat suppression than on conventional spin-

echo images. As with cerebrospinal fluid, this appearance likely relates to the increased T2 weighting and theoretical decrease in diffusional losses.

The primary disadvantage of fast spin-echo demonstrated in this study relates to fat suppression, which was considered poor in 17% of the interpretations. Thus, in using fast spin-echo with frequency-selective fat-suppression techniques, careful attention must be paid to any regions of water saturation or insufficient fat suppression (Fig 3). In this investigation, areas of water saturation were usually outside the area of interest. However, when fat-suppression failure occurs in an area of tumor or adenopathy, there is risk of misdiagnosis, and the examination must be repeated with either an alternative fat-suppression technique, further attempts at frequency-selective fat suppression, or a conventional spin-echo examination.

There are several potential sources of error or bias intrinsic to the study design that must be addressed. First, the comparative portion of this investigation was performed without attempt to blind the readers with regard to fast spin-echo versus conventional spin-echo technique, because the differences in tissue contrast are obvious to the experienced reader even when the

imaging parameters are omitted. Second, the use of a 256×192 or higher matrix in 26 of 27 patients with fast spin-echo but in only 9 of 27 conventional spin-echo examinations would tend to bias the results toward the fast spin-echo examination for evaluation of lesion margin definition and lesion and lymph node conspicuity. This bias reflects the actual imaging parameters in clinical use at our institutions, in which a 256×128 matrix with 2 excitations is often used in evaluation of the neck to reduce the long conventional spin-echo imaging times. This potential bias was evaluated through Wilcoxon Signed Rank Test analysis in only those 9 patients with equivalent matrix size and spatial reductions, which also demonstrated a significant preference for fast spin-echo examinations in the conspicuity ratings, albeit with lesser statistical significance from the reduced sample size.

In conclusion, these results suggest that fast spin-echo with fat suppression can replace conventional spin-echo in the routine evaluation of squamous cell carcinoma of the oral cavity, oropharynx, larynx, or hypopharynx, along with associated lymphadenopathy, at a time savings of more than 50%. Fast spin-echo offers greater spatial resolution in a clinically useful imaging time. In addition, fast spin-echo with fat suppression improves tissue contrast and the conspicuity and definition of margins for primary lesions and lymph nodes compared with conventional spin-echo. Despite the absence of flow-compensation techniques, both flow artifact and gross motion artifact seem to be somewhat less with fast spin-echo techniques.

Further investigation remains necessary for optimization of fat suppression, because the major limitation of this technique results from fat-saturation heterogeneity. Thus, careful attention to fat-saturation failure and unwanted water saturation is essential in the clinical setting to avoid these potential causes for diagnostic error.

References

1. Hennig J, Naureth A, Friedburg H. RARE imaging: a fast imaging method for clinical MR. *Magn Reson Med* 1986;3:823-833
2. Norbash AM, Glover GH, Enzmann DR. Intracerebral lesion contrast with spin-echo and fast spin-echo pulse sequences. *Radiology* 1992;185:661-665
3. Constable RT, Anderson AW, Zhong J, Gore JC. Factors influencing contrast in fast spin-echo MR imaging. *Magn Reson Imaging* 1992;10:497-511
4. Jones KM, Mulkern RV, Schwartz RB, Oshio K, Barnes PD, Jolesz FA. Fast spin-echo MR imaging of the brain and spine: current concepts. *AJR Am J Roentgenol* 1992;158:1313-1320
5. Ahn SS, Mantello MT, Jones, KM, et al. Rapid MR imaging of the pediatric brain using the fast spin-echo technique. *AJNR Am J Neuroradiol* 1992;13:1169-1177
6. Henkleman RM, Hardy PA, Bishop JE, Poon CS, Plewes DB. Why is fat bright in RARE and fast spin-echo imaging. *J Magn Reson Imaging* 1992;2:533-540
7. Jones KM, Mulkern RV, Mantello MT, et al. Brain hemorrhage: evaluation with fast spin-echo and conventional dual spin-echo images. *Radiology* 1992;182:53-58
8. Panush D, Fulbright R, Sze G, Smith RC, Constable RT. Inversion-recovery fast spin-echo MR imaging: efficacy in the evaluation of head and neck lesions. *Radiology* 1993;187:421-426
9. Tien RD. Fat-suppression MR imaging in neuroradiology: techniques and clinical application. *AJR Am J Roentgenol* 1992;158:369-379