

# Generic Contrast Agents

Our portfolio is growing to serve you better. Now you have a *choice*.



FRESENIUS  
KABI

[VIEW CATALOG](#)

# AJNR

## Percutaneous Vertebroplasty: A Special Syringe for Cement Injection

Imad Al-Assir, Antonio Perez-Higueras, Jose Florensa, Alberto Muñoz and Emilio Cuesta

*AJNR Am J Neuroradiol* 2000, 21 (1) 159-161

<http://www.ajnr.org/content/21/1/159>

This information is current as  
of May 12, 2025.

# Percutaneous Vertebroplasty: A Special Syringe for Cement Injection

Imad Al-Assir, Antonio Perez-Higueras, Jose Florensa, Alberto Muñoz, and Emilio Cuesta

**Summary:** Percutaneous vertebroplasty is an effective treatment for many focal vertebral lesions. Methyl methacrylate is too viscous to be handled without difficulty in the conventional way because injection time is short. The operator is left with little time and must fumble with multiple syringes. We describe a special screw-system syringe that decreases the effort needed to inject the cement. In addition, it can standardize the injection pressures and control the injected volume because the threaded plunger affords greater control of injection pressure and volume delivered than does the conventional method.

Percutaneous vertebroplasty is a relatively new procedure that is indicated in the treatment of focal vertebral lesions. The purpose of this technique is to bolster the affected vertebral body. In 1987, Galibert et al (1) reported the use of vertebroplasty in the treatment of aggressive hemangiomas, but as the experience increased, there were new indications for this technique (2). Today, vertebroplasty is used in the treatment of lesions that affect the vertebral body, such as aggressive hemangiomas, metastasis, malignant lymphomas, and multiple myelomas (2–4), and to treat vertebral body compression owing to osteoporosis accompanied by severe pain that does not respond to conservative treatment.

Despite the good results of vertebroplasty published in the literature (3, 4), the technique has not yet achieved the expected worldwide use, probably because of the lack of available instrumentation that simplifies the procedure. We describe a special syringe with a screw-plunger mechanism that makes the injection of methyl methacrylate easier and safer.

## Technique

### Patients

During the last 3 years, we performed 80 vertebroplasties in 50 patients with ages ranging from 24 to 84 years (mean age, 69 years). Thirty-three patients suffered severe pain owing to osteoporotic fractures. Twelve patients had vertebral metastasis. Three patients presented with pain and vertebral destruction because of multiple myeloma, and two patients had aggressive vertebral hemangiomas. We performed two cervical, 24 dorsal, and 54 lumbar vertebroplasties. Two or three vertebral bodies were treated at the same session whenever various lesions were observed.

### Special Syringe

A special screw-system syringe (Fig 1) was used to inject the methyl methacrylate cement into the vertebral body. The system includes a conventional syringe to load the special screw syringe, high-pressure plastic tubing, a needle and stylets, a container, and a spoon to prepare the cement. The special syringe is a 10-mL cylinder with a luer-lock end, a lateral port, a handle, and a screw plunger that enables the operator to apply high pressure with precision (Diagnostic Grifols, SA: Barcelona, Spain).

The prototype screw syringe that we use develops 14 atm of pressure, with which we have been able to inject the cement in all affected vertebral bodies. The definitive device that is being manufactured can develop 40 atm of pressure.

### Injection Technique

Informed consent was obtained from all patients. Usually, the vertebroplasty procedure is performed under neuroleptoanalgesia and local analgesia. An anterolateral approach is used for cervical lesions, whereas a transpedicular or a posterolateral approach is used for dorsal or lumbar lesions. The patient is placed in a lateral decubitus position when the lesion is dorsal or lumbar. Under fluoroscopic guidance, the needle is placed in the anterior third of the vertebral body. The methyl methacrylate powder is mixed with tungsten and then with the methyl methacrylate liquid until a homogeneous paste is achieved. The cement is loaded into the special screw-system syringe by a normal 10-mL syringe through the lateral port (Fig 2A–B). The use of this special syringe allows the use of high-pressure plastic tubing and needles of smaller caliber. As the screw plunger advances, the lateral port becomes excluded from the syringe chamber and the cement is pushed to fill the plastic tubing (Fig 3). When the tubing is filled, it is connected to the needle. The plunger is turned, and the cement is injected into the vertebral body. During the injection of the cement, a lateral fluoroscopic projection is performed to observe any leakage.

Control CT is performed 24 hours after the procedure for all patients. The mean time of the vertebroplasty procedure was 45 minutes. The average time for injecting the cement was 2 minutes.

On CT scans obtained the next day, we observed the following radiologic complications. Twelve (16%) epidural leak-

Received February 18, 1999; accepted after revision July 6.

From the Department of Neuroradiology (I.A.-A., A.P.-H., J.F., E.C.), Fundación Jiménez Daz, and the Department of Radiology (A.M.), Section of Neuroradiology, Hospital Universitario, Madrid, Spain.

Address reprint requests to Dr. Imad Al-Assir, Fundación Jiménez Daz, Avenida Reyes Católicos, 2 28040, Madrid, Spain.

The address of **Diagnostic Grifols** is: S.A., Ctra. Nacional 152, km. 21-Pol. Sector Autopista, 08150 Plets de Vallès, Barcelona, Spain.

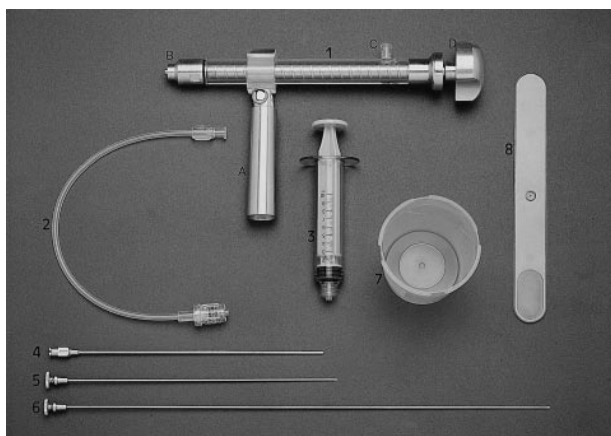


Fig 1. Material used in vertebroplasty. 1, special screw system syringe (A, handle; B, luer-lock end; C, lateral port; D, screw plunger); 2, high-pressure plastic tubing; 3, 10-mL syringe; 4, 14-gauge needle; 5, short stylet; 6, long stylet; 7, container in which to mix cement; 8, spoon.

ages occurred, most during our early experience. With more experience using the special syringe, the incidence of leakage became less frequent. We did not observe clinical complications associated with these leaks. Three (3.75%) interdiscal leakages were observed that were asymptomatic. Two (2.5%) intervertebral foramina leakages, one of which produced transient sciatica that disappeared 1 week later, were observed. Three (3.75%) paravertebral leakages occurred, with no clinical consequence.

### Discussion

Percutaneous vertebroplasty represents an effective treatment in vertebral lesions that cause pain and fractures (2, 3, 5, 6). It provides immediate and long-term pain relief (6). Vertebroplasty may be used alone or in combination with other methods, such as surgery, chemotherapy, and radiotherapy (5).

Although the vertebroplasty was first described in the mid 1980s (2), it has not yet achieved the expected widespread practice, probably because of

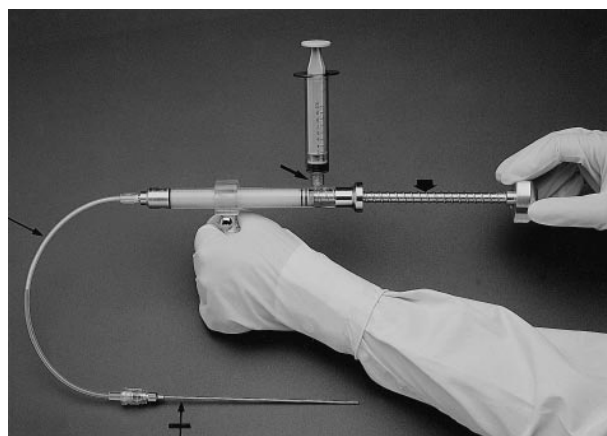


Fig 3. Plastic tubing (*thin arrow*) and needle (*crossed arrow*) are connected to the syringe. As the screw plunger (*thick arrow*) is turned, the cement is advanced into the plastic tubing and then into the needle. The lateral port (*short arrow*) is excluded from the syringe chamber as the plunger advances. One hand holds the syringe by the handle, and the other turns the screw plunger.

the difficulty of injecting the methyl methacrylate into the vertebral body. To overcome this problem, small-volume syringes are used to decrease the required force during injection. Authors report on the use of various 1- to 3-mL syringes to perform the injection into the vertebral body (7, 8). Some propose the use of a special handle to reduce the effort required to inject the cement (2, 3). The procedure must be done rapidly to avoid solidification of the cement (3).

Using the 10-mL new special screw syringe proposed herein, it is not necessary to use various syringes for one vertebral body. This saves valuable time, considering that the methyl metacrylate solidifies rapidly (3).

The screw-plunger system develops a high pressure that enables us to inject the cement without applying human force. This increase of pressure does not increase the risk of cement leakage be-





Fig 2. Special screw system syringe connected to the 10-mL syringe.

A, Before loading, the cement within the conventional syringe that is connected to the lateral port (*thin arrow*) can be seen. Notice the screw system plunger (*thick arrow*).

B, After loading, the cement within the special screw system syringe (*asterisks*), can be seen. The empty conventional syringe is still placed in the lateral port.

cause the screw-plunger system provides a better control of the injection and we can stop the injection as soon as any leakage is observed. Furthermore, the screw-plunger syringe allows connecting high-pressure plastic tubing between the syringe and the needle. This tubing permits handling the syringe without the risk of displacing the needle in the vertebral body (8).

Although we did not measure the difference of irradiation received by the operator by using our system with respect to the technique used in the literature, the use of plastic tubing permits the operator to keep his or her hands away from the fluoroscopy area, thus decreasing radiation exposure.

Because of the viscosity of the cement, most authors report on the use of large-bore needles (10- to 12-gauge needles) to facilitate the injection of the cement (3, 9). The use of our special syringe allows the use of needles of smaller caliber, such as 12- to 14-gauge needles, which produce less injury to the pedicle in cases of transpedicular access and to the vertebral body in cases of posterolateral access as well as paravertebral leakage around the needle.

We observed cement extravasation in 26% of the patients, which we consider high. We noted, however, that most of these extravasations occurred early in our experience. Currently, we perform the injection slowly so that the cement that enters the vertebral body has enough time to solidify. When we feel the resistance increase, we accelerate the injection. If we see any leakage, we stop the injection for 10 to 20 seconds so that the leaked cement can solidify, thereby avoiding further extravasation. We then continue the injection. Our device streamlines the handling of methyl methacrylate and affords greater control of injection pressure and volume. Such convenience allows the operator to pay

more attention to the injection process and helps avoid unnecessary extravasation of cement.

## Conclusion

The new special screw syringe described herein may decrease the risk of cement leakage in vertebroplasty procedures. Additionally, it allows better control of the injection pressure and the volume injected. It therefore makes vertebroplasty easier and safer to perform.

## References

1. Galibert P, Deramond H, Rosat P, Le Gars D. **Note préliminaire sur le traitement des angiomes vertébraux par vertébroplastie acrylique percutanée.** *Neurochirurgie* 1987;33:166-168
2. Depriester C, Deramond H, Toussaint P, Jhaveri H. S., Galibert P. **Percutaneous vertebroplasty: indications, technique and complications.** In: Connors W, ed. *Interventional Neuroradiology Strategies and Practical Techniques*. Philadelphia: Saunders;1999: 246-257
3. Gangi A, Kastler BA, Dietmann JL. **Percutaneous vertebroplasty guided by a combination of CT and fluoroscopy.** *AJNR Am J Neuroradiol* 1994;15:83-86
4. Cotten A, Dewatre F, Cortet B, et al. **Percutaneous vertebroplasty for osteolytic metastasis and myeloma: effects of the percentage of the lesion filling and the leakage of methyl methacrylate at clinical follow-up.** *Radiology* 1996;200:525-530
5. Cotten A, Boutry N, Cortet B, et al. **Percutaneous vertebroplasty: state of the art.** *Radiographics* 1998;18:311-320
6. Weill A, Chiras J, Simon JM, Rose M, Sola-Martinez T, Enkaoua E. **Spinal metastasis: indications and results of percutaneous injection of acrylic surgical cement.** *Radiology* 1996;199:241-247
7. Lapras C, Mottolèse C, Deruty R, Lapras C, Remond J, Duquesnel J. **Injection percutanée de méthyl-méthacrylate dans le traitement de l'ostéoporose et ostéolyse vertébrale grave.** *Ann Chir* 1989;43:371-376
8. Jensen ME, Evans AJ, Mathis JM, Kallmes DF, Cloft HJ, Dion JE. **Percutaneous polymethylmethacrylate vertebroplasty in the treatment of osteoporotic vertebral body compression fractures: technical aspects.** *AJNR Am J Neuroradiol* 1997;18:1897-1904
9. Cotten A, Deperez X, Chabanne B, Duquesnoy B, Chastanet P. **Malignant acetabular osteolysis: percutaneous injection of acrylic bone cement.** *Radiology* 1995;197:307-310