

Generic Contrast Agents

Our portfolio is growing to serve you better. Now you have a *choice*.



[VIEW CATALOG](#)

AJNR

Cervical Diskography: Analysis of Provoked Responses at C2–C3, C3–C4, and C4–C5

Kurt P. Schellhas, Timothy A. Garvey, Blake A. Johnson, Peter J. Rothbart and Steven R. Pollei

AJNR Am J Neuroradiol 2000, 21 (2) 269-275

<http://www.ajnr.org/content/21/2/269>

This information is current as
of May 15, 2025.

Cervical Diskography: Analysis of Provoked Responses at C2–C3, C3–C4, and C4–C5

Kurt P. Schellhas, Timothy A. Garvey, Blake A. Johnson, Peter J. Rothbart, and Steven R. Pollei

BACKGROUND AND PURPOSE: Previous authors have described the locations of provoked responses to cervical diskography from C3–C4 to C6–C7, but we have found no description of the findings at C2–C3. This study was undertaken to analyze the sensations provoked during cervical diskography at C2–C3 and to compare the results with those provoked at C3–C4 and C4–C5.

METHODS: The locations of diskographically provoked responses from 40 consecutive patients who had undergone C2–C3, C3–C4, and C4–C5 diskography were analyzed. Only intensely painful ($\geq 7/10$) and concordant responses were considered. Disk morphology on MR images and diskograms was also compared with the provoked responses.

RESULTS: Eighteen subjects described either unilateral ($n = 10$) or bilateral (usually asymmetric) ($n = 8$) concordant pain at the craniovertebral junction in response to C2–C3 diskography. Nine subjects described either unilateral ($n = 5$) or bilateral ($n = 4$) neck pain during injection. Cephalalgia or head pain was provoked in 19 subjects, seven bilaterally. Four subjects described either unilateral ($n = 3$) or bilateral ($n = 1$) trapezius muscle and/or shoulder pain. Preliminary MR studies were not helpful, as most C2–C3 disks either appeared normal or exhibited nonspecific signs of degeneration. All disks exhibited either fissuring or extradiskal leakage of contrast material at diskography, regardless of the response provoked.

CONCLUSION: Diskography at C2–C3 and C3–C4 frequently produces pain sensations in the head, craniovertebral junction, and neck. There is no correlation between C2–C3 disk morphology and the diskographically provoked response.

The cervical disks (1–6), zygapophyseal joints (1–3, 7–10), and atlanto-occipital and lateral atlantoaxial joints (11) have been implicated in the pathogenesis of headache and neck pain. Cervical diskography has been shown to be a clinically useful test when performed by skilled and experienced practitioners for the investigation of pain that is suspected to be of cervical discogenic origin (6). Prior research (6) has demonstrated that annular tears involving the outer third of the cervical disk annulus are always observed in disks that are intensely painful at diskography, whereas disks without annular tears are not painful when injected. In this same research, it was shown that coincidental, painless annular tears are common at diskography, and painfully deranged cervical disks in patients

suffering head and/or neck pain without neurologic deficit often appear normal on high-resolution MR images. The locations of diskographically provoked head and neck pain have been analyzed and reported at C3–C4 through C6–C7, but not at C2–C3. Since the symptoms associated with diskography at C2–C3 have not been reported, we documented and recorded the responses from 40 consecutive patients with chronic head and neck pain who underwent C2–C3 diskography, along with the injection of subjacent cervical disk levels, which were used as controls for this study. We also compared preliminary high-field MR imaging studies of the cervical spine with the results of diskography in these cases and found poor correlation between MR imaging morphology and diskographically provoked responses at C2–C3, C3–C4, and C4–C5.

The null hypotheses that we tested were as follows: 1) C2–C3 diskography does not produce pain of any kind; 2) C2–C3 diskography does not produce cephalalgia of any kind; 3) C2–C3 diskography does not produce cephalalgia alone, without associated neck pain; 4) C2–C3 diskographic morphology does not correspond to diskographic response; 5) diskographic morphology does not correspond to MR disk morphology; and 6) C2–C3

Received April 8, 1999; accepted after revision September 9.

From the Center for Diagnostic Imaging, St. Louis Park, MN (K.P.S., B.A.J., S.R.P.); the Twin Cities Spine Center, Minneapolis, MN (T.A.G.); and the Rothbart Pain Clinic, North York, Ontario, Canada (P.J.R.).

Address reprint requests to Kurt P. Schellhas, MD, Center for Diagnostic Imaging, 5775 Wayzata Blvd, Suite 190, St. Louis Park, MN 55416.

diskographically provoked pain response does not correspond to MR imaging disk morphology.

Methods

Retrospective (first six cases) and prospective (subsequent 34 subjects) analyses of 40 patients (33 women and seven men, 19–67 years old) with suspected high cervical disk derangement were undertaken. All patients had been referred for diskography by one of 13 physicians subspecializing in either head and neck pain management or spine-related disorders and representing the following subspecialties: orthopedic spine surgery, neurosurgery, neurology, physical medicine/rehabilitation, and anesthesiology. All patients underwent cervical diskography at C2–C3, C3–C4, and C4–C5 in addition to subadjacent levels in most cases to evaluate disabling clinical head and/or neck pain of, at minimum, 12 months' duration (range, 12 months to 18 years), suspected to be of cervical discogenic origin. Thirty-four patients also were studied at the C5–C6 levels diskographically, 16 level had diskography at C6–C7, and two had the C7–T1 disk studied as part of the same multilevel procedure. Thirty-one patients were being examined specifically for head pain as their primary complaint, with or without neck, shoulder, upper back, and/or extremity complaints. Complaints included pain (either isolated or in various locations) involving the cranium, neck, trapezius muscle(s), shoulder(s), upper back, and upper extremity(ies), either unilateral or bilateral.

All patients in the series had undergone preliminary examination of the cervical spine with high-field MR imaging (40 patients) and thin-section CT (10 patients) within 12 months of diskography. Any patient whose symptoms had changed significantly since initial imaging underwent repeat MR imaging before the diskography. All cervical MR studies were performed on a 1.5-T superconducting magnet with a dedicated cervical coil. Sagittal T1-weighted images were obtained with the following parameters: 600/20/1 (TR/TE/excitations), 3-mm-thick sections with a 1.0-mm gap, and 256 × 192 matrix. These were followed by sagittal magnetization-prepared gradient-echo (MPGR) images with 3-mm-thick sections with a 1-mm gap, 20° flip angle, 10/2 (TE/excitations), and a 256 × 192 matrix. Axial MPGR images with 3-mm-thick sections and a 1-mm gap, 20° flip angle, and 10–15/2 (TE/excitations) were then obtained. CT studies were obtained with a high-resolution helical scanner using contiguous 3-mm-thick scans from the midbody of T1 upward through the midbody of C2. Thirty-four patients also had either CT or MR imaging of the head and brain within the same time frame. All MR and CT studies were interpreted by neuroradiologists thoroughly experienced in spine imaging and injection procedures. For this study, each spine MR imaging examination was reviewed with specific regard to the C2–C3 disk (by at least one of the neuroradiologist authors) and categorized as either normal or abnormal. Any decrease in C2–C3 disk hydration seen on MR studies, as well as disk contour change, decrease in height, segmental malalignment, or adjacent endplate infraction seen on either CT or MR studies qualified the disk as abnormal. Patients with prior cervical spine surgery at or above C4–C5 and/or cranial vault surgery were excluded from this study. Two subjects who had undergone previous cervical spine surgery at C5–C6 or below were included in this group.

On the day of diskography, patients completed a questionnaire about their symptoms and filled in the areas where they were experiencing pain on the front and back of human diagrams. All diskographic procedures were subsequently performed by one of three experienced neuroradiologists/cervical diskographers at one of two outpatient imaging centers in suites specifically designed for spinal injection procedures. All procedures were performed without any sedation whatsoever, as this has been and continues to be our custom. Complete details regarding the equipment and diskographic technique

used for C3–C4 through C6–C7 have been described elsewhere (6). Cervical disks are most often studied from caudal to cephalad, although exceptions are made depending on disk disease observed on prior imaging studies. We generally attempted to study the most suspect disks first; however, we have found (6) that imaging studies are inaccurate at predicting diskographic response. One significant change since that publication involves the use of intradiskal antibiotics. All patients in this series had cefazolin mixed with the injected nonionic, water-soluble, low osmolar contrast material (iohexol, 240 mg/mL) in a concentration of 1 g in 10 mL sterile saline/40 mL iohexol, unless the patient was allergic to either cephalosporins or penicillins.

For study of the C2–C3 disk, a 25-gauge 3-inch spinal needle (the same as that used for the lower cervical disks) was advanced toward the disk using an anterolateral right-sided approach from below (Figs 1B, 2C and D, 3B and C, 4B and C, 5A and B) with the patient in a head-extended position, head rotated approximately 30° toward the left, away from the diskographer. The prevertebral soft tissues were palpated and compressed with the left index and third digits, pulling the carotid artery laterally and pushing the pharynx medially, after which the needle was advanced with the right hand through the skin and toward/into the disk. The needle was advanced after fluoroscopic localization and skin marking, but not under direct fluoroscopic vision, to avoid unnecessary radiation exposure to the operator. After initial needle placement from below (caudal to cephalad), the needle position was checked fluoroscopically, after which adjustments were made in order to place the needle tip as near to the center of the C2–C3 disk as possible in each case (Figs 1B, 2C and D, 3B and C, 4B and C, 5A and B). Following successful needle placement, magnified fluoroscopy was centered in either an anteroposterior or lateral projection on the C2–C3 disk, and contrast medium injection was performed under fluoroscopic observation. Each disk was injected to capacity (4–5 atm of pressure, approximately 140–150 mm Hg, based on our previous measurements) or until we either provoked a significant pain response or observed leakage of contrast material, whether through the annulus (Figs 1B, 2C and D, 3B and C, 4B and C, 5A and B), through one or both vertebral body endplates, or into epidural, paraspinal, or intramedullary veins. Morphologically normal cervical disks (C3–C4 through C6–C7) will accept 0.2 to 0.4 mL of saline or contrast. The patients' faces were closely observed by both the proceduralist and assisting technologist during injection for any external manifestation of pain. Any grimaces or facial expressions during injection were recorded. Injected disks were then filmed in both anteroposterior and lateral projections with the needle in place, after which the needle was either removed or, in some especially painful cases, lidocaine, 2% to 4%, was injected in a volume of 0.3 to 1.0 mL prior to needle removal.

After the needle was removed, the patients were asked to describe in detail the experience perceived during the injection. When being questioned about the exact location(s) of pain/pressure perceptions, the patients were, on occasion, touched by the diskographer in various head and neck locations to confirm the precise location(s) being described, especially in situations in which the patient's description was unclear. When verbal communication was difficult, patients were asked to color with a felt-tip marker the precise locations of their perception(s) on the front and back of the human diagrams. Patients were questioned as to the precise location(s) of pain/pressure perception and whether this experience was concordant with (exactly reproducing in location and character) their clinical pain, and they were asked to rate the intensity of this perception at its maximum point on a scale of 0 (no sensation whatsoever) to 10 (extreme, intolerable pain or pressure). Pressure was defined as a sensation of distention, dullness, or heaviness, different from the sharper sensation(s) perceived as "pain." Perceptions that clearly started on one side and then spread across the midline were counted as unilateral and localized to

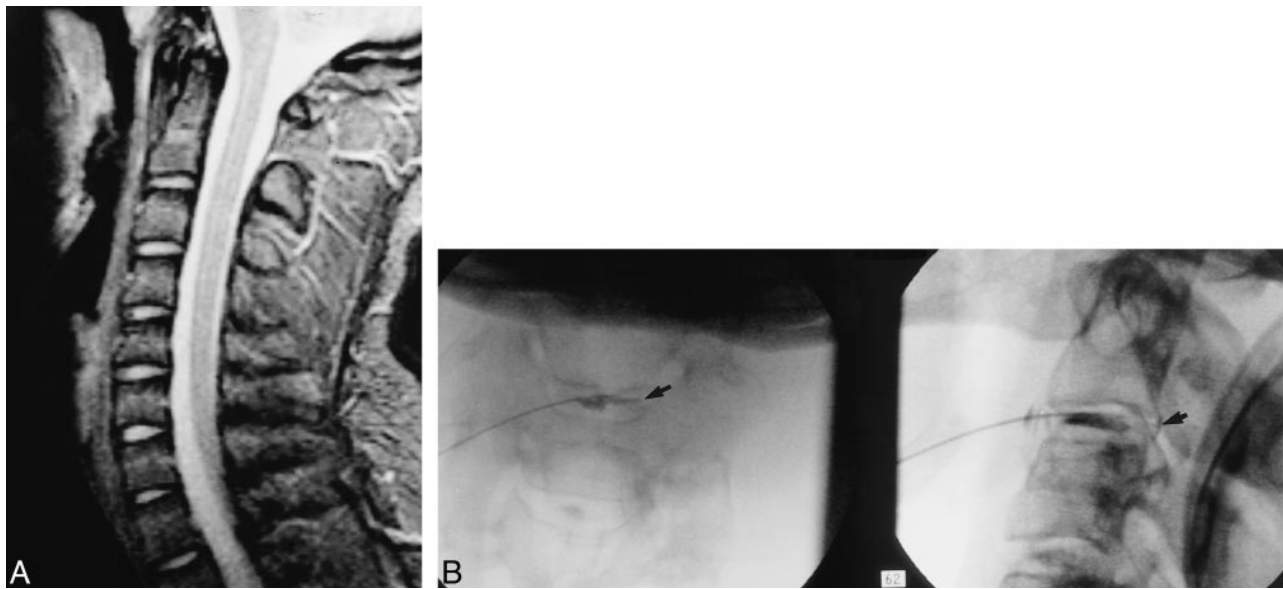


FIG 1. Patient with 5/10 concordant, bilateral, occipital head, CVJ, and upper neck pain.

A, Sagittal MPGR image (3-mm thick, 1-mm gap, 20° flip angle, TE = 10) shows a completely normal-appearing C2–C3 disk.

B, C2–C3 diskogram in anteroposterior (left) and lateral (right) views shows uncovertebral fissure (arrow on left) along with full-thickness posterior tear and contrast leakage (arrow on right).

the place at which the greatest initial perception occurred. All this information was recorded by the assisting technologist on a standard form used for diskography before proceeding to the next level. Once the entire diskographic examination was complete, each patient was given the option of receiving a nonrenewable prescription for a narcotic analgesic (most often hydrocodone) and a muscle relaxant, if needed, for spasms. Most patients requested the prescription, as they often experienced soreness for the first 12 to 36 hours after the procedure, especially if painful disks were provoked. Occasionally, patients experienced an exacerbation of their clinical pain for up to several days after diskography, necessitating the narcotic prescription. We rarely obtained postdiskography CT scans in this series, as we have found such scans noncontributory in most cases (6). All the patients had prediskography imaging, and the diskographies were performed mostly for the provoked responses. The high-quality anteroposterior and lateral diskograms obtained at each level injected provided the needed anatomic information.

Results

MR studies revealed 32 (80%) of 40 C2–C3 disks to be normal in contour, height, and intrinsic signal intensity (Fig 1A). Eight disks (20%) were judged to be abnormal (Figs 2A, 3A, 4A). The most common abnormality noted on MR images was nuclear dehydration (Fig 3A). All 10 of the CT cervical spine studies were judged to be normal at C2–C3. All the brain/head imaging studies were normal with regard to identification of potential sources of pain.

Diskographically provoked responses ranged from 0/10 to 10/10 in intensity and were highly variable with regard to location of pain or pressure (Figs 6 and 7 and Table). Obvious facial expressions and/or other manifestations of pain during C2–C3 injection were observed in 22 (55%) of the patients, all with pain responses of 8/10 or greater.

More subtle (questionable) responses were not recorded. Nine patients described intense ($\geq 7/10$), concordant pain, either unilaterally or bilaterally in the neck; four described pain in either the shoulder(s) or trapezius muscle(s) in association with neck pain; and 18 described pain at the craniovertebral junction (CVJ), with or without neck or head pain. Nineteen described head pain in various locations in association with neck, trapezius, shoulder, or upper back pain. Thirteen described intense, concordant pain at or above the CVJ, without any neck, trapezius, shoulder, or upper back sensation. Four described this pain as being confined to various areas of the cranium without any pain at or below the CVJ. Of the head pain responses, 18 were located in the occiput, nine in the parietal region, 10 in various locations over the temporal bone, and one over the frontal bone, either unilaterally or bilaterally. Two patients described intense, concordant, unilateral orbital, peri- and/or retro-orbital pain in association with occipital, temporal, parietal, and CVJ pain. Eight patients described their head pain as being bilateral, but often asymmetric. The provoked responses at C2–C3 graphically differed from the responses at both C3–C4 and C4–C5 (see Fig 7 and Table). Observed peripheral lesions/fissures in the 40 injected C2–C3 disks were most often posterior and extended into the uncovertebral recesses or even more laterally into the cervical foramina. Leakage of contrast material from painfully deranged disks was generally on the same side as the provoked responses (Figs 1B, 2C and D, 3B and C, 4B and C, 5A and B). All intensely ($\geq 7/10$) painful disks exhibited defects, including fissures extending into or through the outer aspect of the disk, or frank leakage of

FIG 2. Patient with 6.5/10 concordant, but mostly right-sided, occipital and mastoid pain with uncovertebral fissure.

A and B, Sagittal (A) and axial (B) MPGR images (3-mm thick, TE = 1015) show slight forward displacement of C2 on C3 (A). Axial image (B) appears normal. Because of the slight forward displacement of C2 on C3 (A), C2–C3 disk is judged to be abnormal.

C and D, Anteroposterior (C) and lateral (D) diskograms reveal an uncovertebral fissure and contrast leakage (arrows).

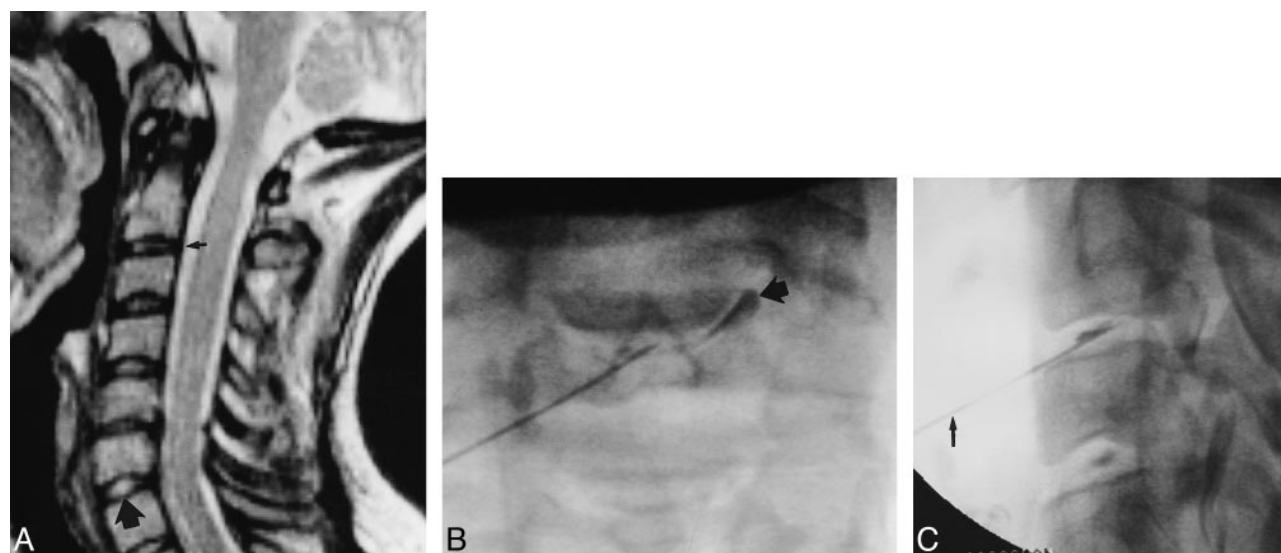
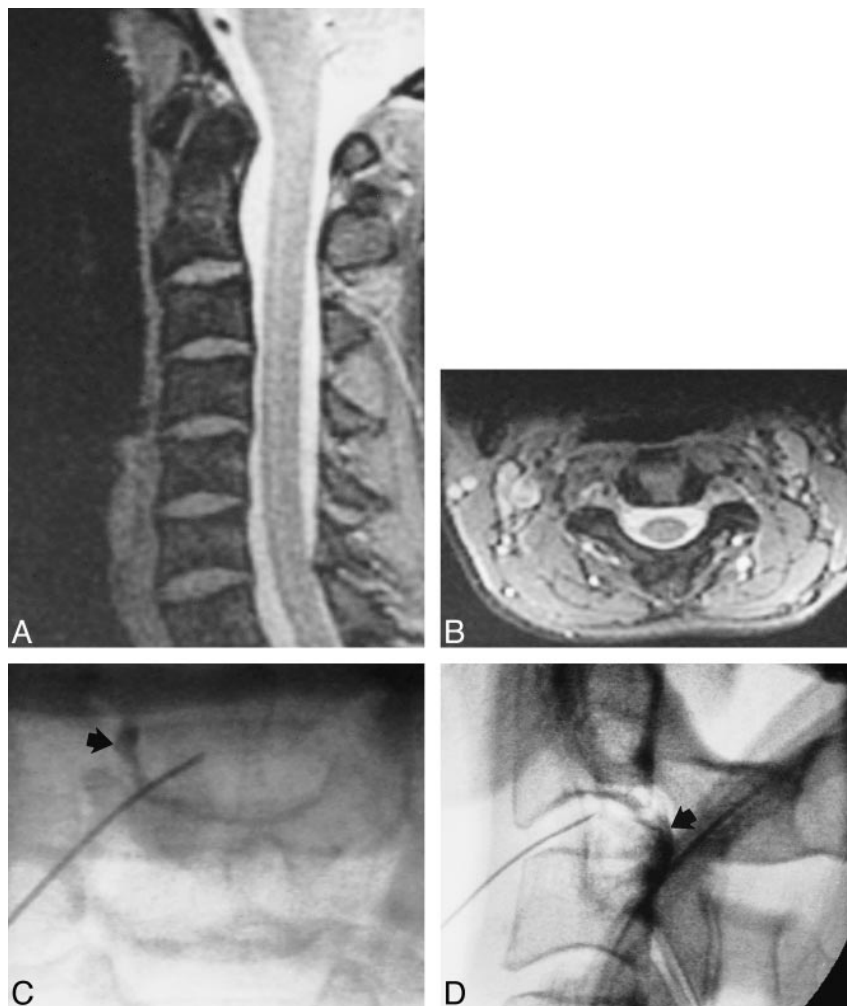


FIG 3. Patient with 9/10 concordant unilateral mastoid and occipital head pain associated with uncovertebral tear.

A, Sagittal, 3-mm-thick MPGR midline image reveals relative dehydration of the C2–C3 disk (small arrow) as compared with the normally hydrated C6–C7 disk (large arrow).

B and C, Anteroposterior (B) and lateral (C) diskograms show an uncovertebral fissure (arrow in B). Note how the 25-gauge needle (arrow in C) enters the disk slightly from below.

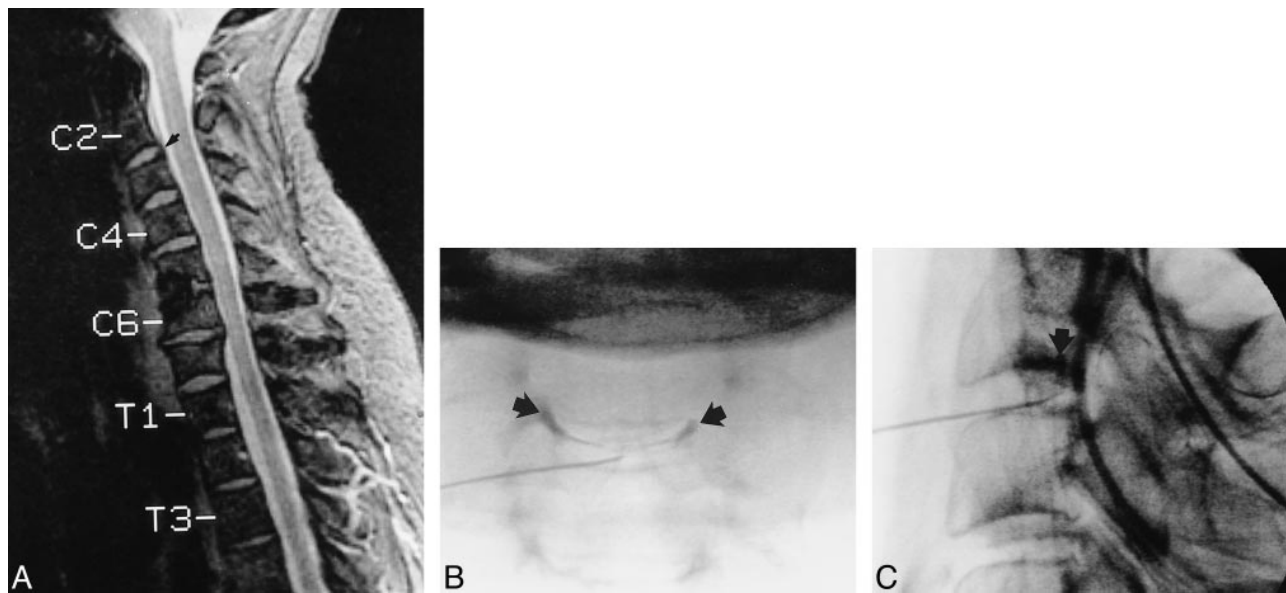


FIG 4. Patient with 9/10 concordant bilateral neck, CVJ, and occipital head pain with slightly abnormal C2–C3 disk contour at MR imaging.

A, Sagittal midline, 3-mm-thick MPGR image shows slight dorsal bulging of the C2–C3 disk annulus (arrow). Note previous interbody fusion at C4–C5.

B and C, Anteroposterior (B) and lateral (C) diskograms reveal bilateral uncovertebral fissures (arrows in B). The fissures are superimposed on lateral view (arrow in C).

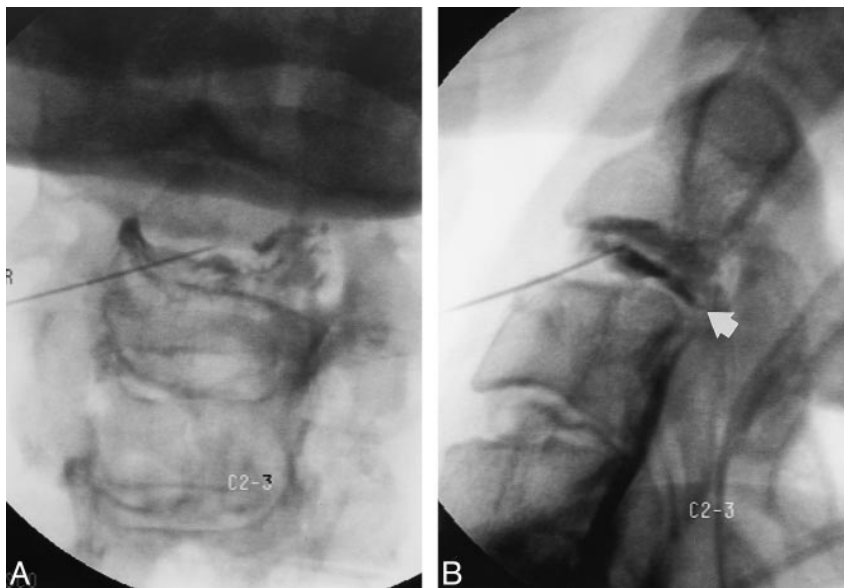


FIG 5. Patient with 8.5/10 concordant, diffuse, bilateral CVJ, occipital, parietal, and temporal head pain associated with bilateral and posterior annular tears of the C2–C3 disk.

A and B, A large, broadly based defect is seen on both projections (arrow in B), extending into C2–C3 foramina (A).

contrast material beyond the disk margins (paraspinous, epidural, intravenous) (Figs 3B, 4B and C, 5A and B). All C2–C3 disks that were painless or that produced low-intensity pain exhibited similar fissures/tears, indicating that such findings are most likely normal for subjects of this age group (Figs 1B, 2C and B).

There were no postdiskographic infections or hematomas in this study. The most significant post-procedural side effect was a temporary exacerbation of the clinical headache and/or neck pain, lasting for up to 4 days after the procedure.

Discussion

MR imaging has been shown by formal study to be insensitive to the detection of painful, nonprotruding peripheral cervical disk lesions at C3–C4 through C6–C7 (6). Pain associated with cervical tears at C3–C4 and below has been shown to be either unilateral or bilateral, generally depending on the location of peripheral disruption (6), whereas cervical facet-related pain has been shown to be unilateral and ipsilateral to the irritated joint(s) (2, 7–9). Our data indicate that central-to-peripheral (annular) defects that extend into or through the

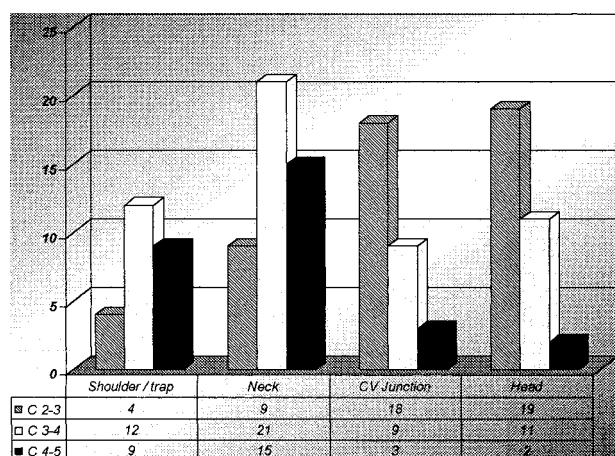


FIG 6. Analysis of diskographically provoked responses at C2–C3, C3–C4, and C4–C5. Forty disks were studied at each level. Only intensely painful ($\geq 7/10$) and concordant disks were counted.

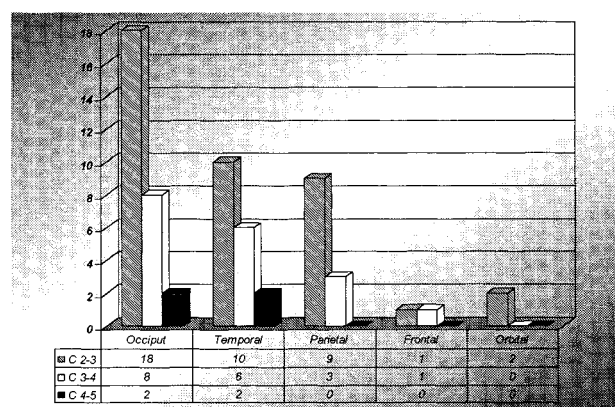


FIG 7. Specific locations of head pain perceptions from intensely painful, concordant disks.

Breakdown of intensely painful, concordant head pain responses comparing C2–C3 alone, C2–C3 and some other disk(s), and disk(s) other than C2–C3

Disk Level	Headache Reproduced	
	Yes	No
C2–C3 and no other level	14	13
C2–C3 and some other level	9	...

outer third of the C2–C3 disk are most common and do not necessarily correspond to clinically significant headache and/or neck pain in symptomatic subjects. Because we do not know what the disk morphology is at C2–C3 in lifelong asymptomatic subjects, a study of such individuals would be of value. Disk annular lesions are common in the lower cervical spine (C3–C4 and below) and increase in frequency with age (12, 13). Painless or coincidental annular tears involving cervical disks (C2–C3 through C6–C7) are also frequently encountered at diskography. Since we did not have a single C2–C3 disk in this series without some degree of uncovertebral fissuring, it is possible that C2–C3 fis-

suring or “uncovertebral recess” opacification is a normal finding in symptomatic adults. With this in mind, it appears that the diskographically provoked responses at C2–C3 were unrelated to disk morphology when fissures were present, both those observed on noninvasive imaging studies and those encountered diskographically.

In our study, the headache complaints ranged from highly localized and unilateral to diffuse bilateral occipital, temporal, parietal, frontal and orbital pain (Fig 7). An important feature of the head pain associated with C2–C3 diskography in our investigation is that it was not necessarily associated with neck pain (Figs 6 and 7). Four patients in our series of 40 had exclusively head pain reproduced at diskography. Most patients, however, had both headache and neck pain of varying degrees and distribution, depending on which cervical disks and/or other structures and cervical segments were involved.

In a previous study (6), we excluded the C2–C3 disk and found that head pain may be associated with lesions involving the cervical disks at C5–C6 through C3–C4, especially C3–C4. In our current and more complete analysis of diskographically provoked responses to C2–C3 injections, we found that either unilateral or bilateral head pain was equally as common as pain involving the CVJ, and more common than neck pain (Fig 6). Head pain was much more frequently associated with C2–C3 than with C3–C4 and lower levels (see Figs 6 and 7 and Table). The bilateral pain (head, neck, CV junction) was often asymmetric and usually on the same side as the peripheral defect and contrast leakage. C2–C3 alone reproduced the clinical head pain in 14 cases, whereas in six patients, C3–C4 was solely associated with intense, concordant head pain. Although significant head pain was associated with C4–C5 diskography in two cases, there were no instances in which head pain was exclusively due to C4–C5 derangement. We observed headache associated with C2–C3 and another disk in nine cases, which was less common than head pain provoked from C2–C3 alone (14 cases). In 13 cases, head pain was not reproduced at diskography (see Table).

Cervical diskography, and especially puncture of the C2–C3 disk, requires considerable technical skill and experience to be performed safely and accurately. The diskographers in this study had each safely performed multiple-level cervical diskographies in more than 50 patients without complication before attempting study of a C2–C3 disk. We directly palpate the spine at all cervical levels, including C2–C3, with our second and third fingers while carefully placing the needle with the opposite hand. If we cannot palpate the spine, we will not attempt disk puncture, especially at C2–C3, where the pharynx can easily lie between the skin and spine, and potentially lead to infection should a needle become contaminated by passing through the pharynx en route to the disk. Patients must be

able to extend their neck and to at least mildly rotate their chin away from the side of needle placement (toward the left and away from the right side in all our cases).

A single, 25-gauge, 3.0- to 3.5-inch spinal needle is used for each disk in all our cervical diskographic procedures. Only one needle is inserted into a disk at any time during the procedure. C2–C3 disks without tears generally accept 0.2 to 0.4 mL of contrast material (or saline), as do lower cervical disks. As soon as we have injected the contrast agent (or saline, if the patient is allergic to contrast material), filmed the disk in at least the anteroposterior and lateral projections, and injected lidocaine (2% to 4%, 0.1 to 0.5 mL, if the injection was especially painful, depending on individual circumstances), we remove the needle and proceed with questioning the patient about the experience during injection. Our technique emphasizes procedural speed. We cleanse the skin with alcohol before each needle placement in an attempt to maintain a sterile field. An intradiskal broad-spectrum, *Staphylococcus aureus*-sensitive antibiotic (cefazolin) is used to further decrease the risk of infection, especially should there ever be an accidental disk contamination during needle placement. We have not had a postdiskographic cervical disk infection to date, and we have now studied over 1300 patients and over 4600 cervical disk levels. We did not begin using routine intradiskal cefazolin for all diskographic procedures (cervical, thoracic, and lumbar) until late 1996. As a precaution against the possible greater risk of disk infection at C2–C3, compared with lower cervical levels, we strongly advocate the use of intradiskal cefazolin unless there is an allergy to antibiotics, either penicillin or cephalosporin.

The information we obtain from cervical diskograms has a major influence on treatment planning. The surgeons who refer the cases to us are loath to remove a cervical disk and perform a fusion with diskographically painful adjacent segment disease. Hence, cervical diskography has become primarily an exclusionary procedure for cervical fusion candidates. Surgery is generally denied in subjects with multilevel, painful disk derangement proved by diskography. Surgery was denied for most of these patients, as multilevel painful disease was found. We performed cervical facet nerve radio frequency (RF) neurotomy (14, 15) in 16 of these patients to date and have had encouraging results in treating their cervicogenic headache and high neck pain. Patients are selected for RF only if they respond with greater than 50% pain relief from cervical facet nerve blocks at C2 and C3. Our best results have been in patients who experienced complete or nearly complete pain relief from preliminary blocks, performed during a separate visit. We are formally investigating cervical facet nerve RF

as a treatment for cervicogenic head pain at this time.

With regard to the null hypotheses we tested: 1) C2–C3 diskography *does* produce pain in many instances; 2) C2–C3 diskography *does* frequently produce cephalalgia; 3) C2–C3 diskography *does*, on occasion, produce cephalalgia alone, without any associated neck pain; 4) C2–C3 diskographic morphology *does not* correspond to diskographic response; 5) C2–C3 diskographic morphology *does not* correspond to MR disk morphology; and 6) C2–C3 diskographically provoked pain *does not* correspond to MR disk morphology.

Conclusion

High-intensity and clinically concordant head, CVJ, and upper neck pain, either individually or in combination, is commonly provoked by C2–C3 and, to a lesser degree, C3–C4 diskography. Fissuring and peripheral defects involving the C2–C3 disk are exceedingly common at diskography in symptomatic patients and do not correspond to provoked response. CT and MR imaging studies of the cervical spine are generally not definitive in assessing head and neck pain without neurologic deficit. Provocative cervical diskography, including C2–C3, if possible, can be used to evaluate head and neck pain of suspected cervical discogenic origin.

References

1. Barnsley L, Lord S, Bogduk N. Clinical review: whiplash injury. *Pain* 1994;58:283–307
2. Bogduk N. Innervation and pain patterns in the cervical spine. *Clin Phys Ther* 1988;17:1–13
3. Bogduk N. The anatomy and pathophysiology of whiplash. *Clin Biomech* 1986;1:92–101
4. Bogduk N, Windsor M, Inglis A. The innervation of the cervical intervertebral discs. *Spine* 1988;13:2–8
5. Cloward RB. Cervical diskography: a contribution to the etiology and mechanism of neck, shoulder and arm pain. *Ann Surg* 1959;150:1052–1064
6. Schellhas KP, Smith MD, Gundry CR, Pollei SR. Cervical discogenic pain: prospective correlation of magnetic resonance imaging and discography in asymptomatic subjects and pain sufferers. *Spine* 1996;21:300–312
7. Bogduk N, Aprill C. On the nature of neck pain, discography, and cervical zygapophysial joint blocks. *Pain* 1993;54:213–217
8. Bogduk N, Marsland A. The cervical zygapophysial joints as a source of neck pain. *Spine* 1988;13:610–617
9. Dwyer A, Aprill C, Bogduk N. Cervical zygapophyseal joint pain patterns, I: a study in normal volunteers. *Spine* 1990;15:453–457
10. Fukui S, Ohseto K, Shiotani M, et al. Referred pain distribution of the cervical zygapophyseal joints and cervical dorsal rami. *Pain* 1996;68:79–83
11. Dreyfuss P, Michaelsen M, Fletcher D. Atlanto-occipital and lateral atlanto-axial joint pain patterns. *Spine* 1994;19:1125–1131
12. Oda J, Tanaka H, Tsuzuki N. Intervertebral disc changes with aging of human cervical vertebra from the neonate to the eighties. *Spine* 1988;13:1205
13. Mercur S, Bogduk N. The ligaments and annulus fibrosus of human adult cervical intervertebral discs. *Spine* 1999;24:619–624
14. Lord SM, Barnsley L, Wallis BJ, et al. Percutaneous radiofrequency neurotomy for chronic cervical zygapophyseal joint pain. *N Engl J Med* 1996;335:1721–1726
15. McDonald GJ, Lord SM, Bogduk N. Long-term follow-up of patients treated with cervical radiofrequency neurotomy for chronic neck pain. *Neurosurgery* 1999; 45:61–68