

Generic Contrast Agents

Our portfolio is growing to serve you better. Now you have a *choice*.



[VIEW CATALOG](#)

AJNR

MR Imaging Correlates of Survival in Patients with High-Grade Gliomas

Whitney B. Pope, James Sayre, Alla Perlina, J. Pablo Villablanca, Paul S. Mischel and Timothy F. Cloughesy

AJNR Am J Neuroradiol 2005, 26 (10) 2466-2474
<http://www.ajnr.org/content/26/10/2466>

This information is current as of May 25, 2025.

MR Imaging Correlates of Survival in Patients with High-Grade Gliomas

Whitney B. Pope, James Sayre, Alla Perlina, J. Pablo Villablanca, Paul S. Mischel, and Timothy F. Cloughesy

BACKGROUND AND PURPOSE: For patients with malignant gliomas, clinical data—including age, perioperative Karnofsky Performance Status (KPS), and tumor resection—and tumor imaging features—including necrosis and edema—have been found to correlate with survival. The purpose of this study was to assess the validity of these results and determine whether other imaging features are useful in predicting survival.

METHODS: We analyzed the relationship between 15 imaging variables obtained from contrast-enhanced MR imaging scans and survival in patients with grade III ($n = 43$) and grade IV ($n = 110$) glioblastoma multiforme (GBM) gliomas. Image analysis was performed by 2 neuroradiologists who were blinded to clinical data. The Kaplan-Meier method was used to estimate survival probabilities. Univariable Cox models were used to assess the impact of imaging features on survival. A recursive partitioning analysis also was performed.

RESULTS: As expected, age and KPS scores had significant prognostic value for both tumor grades. The extent of resection was not a statistically meaningful predictor of survival. For GBM, univariable analysis revealed the following imaging features to be significant, (hazard ratios in parentheses): noncontrast-enhancing tumor (nCET, 0.55), edema (1.62), satellites (1.74), and multifocality (4.34). For grade III tumors, the Cox hazard ratio for necrosis was 4.43 ($P = .014$) and correlated with a poor outcome and survival rates comparable to GBM patients. Lack of nCET, multifocality, and satellite lesions also were correlated with shortened survival.

CONCLUSION: Of 15 tumor imaging features in GBM patients, only nCET, edema, and multifocality/satellites are statistically significant prognostic indicators. The survival advantage of nCET is a novel finding.

Malignant gliomas are heterogeneous tumors in both appearance and gene expression (1–3). Survival times for grade III gliomas are significantly longer than for grade IV astrocytomas (glioblastoma; 4). Even within grades, time of survival is highly variable.

Several imaging properties of GBM have been studied in relationship to survival. Many groups have reported that the extent of necrosis and the amount of edema is negatively correlated with survival (5–7). One group has reported a positive correlation between survival and the presence of large tumor cysts (8).

Clinical data also correlate with survival. The most well-established are age and Karnofsky Performance Status (KPS; 4, 7, 9). Survival is inversely correlated with age. For instance, studies have shown that the survival rate for patients with GBM at 18 months is 50% for those <40 years of age, 20% for those 40–60 years of age, and 10% for those >60 years of age. The survival of patients with GBM is also negatively correlated with KPS. Patients with a KPS <80 have a 1.5 relative risk compared with those with a KPS score of 80 or above (7). Several studies have concluded that more extensive surgical resection prolongs survival (7, 9–11), whereas others have found no significant benefit (4, 12).

Being better able to determine prognosis from routine imaging studies may provide aid in making treatment decisions. For instance, more aggressive and experimental treatment in patients with poor prognosis may be justified. Because most patients with malignant gliomas are diagnosed and followed with MR imaging, the relationship between survival and the appearance of tumor on MR imaging is important. Therefore, we analyzed an extensive number of im-

Received March 4, 2005; accepted after revision April 29.

From the Departments of Radiological Sciences (W.B.P., J.P.V.), Biostatistics (J.S.), Human Genetics (A.P.), Pathology and Laboratory Medicine (P.S.M.), and Neurology (T.F.C.), David Geffen School of Medicine at UCLA Medical Center, Los Angeles, CA.

Address correspondence to Whitney B. Pope, MD, PhD, Department of Radiological Sciences, David Geffen School of Medicine at UCLA Medical Center, 10833 Le Conte Avenue, BL-428/CHS, Los Angeles, CA 90095-1721.

aging features to determine which would be most useful as prognostic indicators. These features were selected to be determined easily from routine scans and therefore useful in everyday clinical practice.

Patients and Methods

Patients with a diagnosis of glioblastoma were selected from consecutive patients seen at the UCLA Neuro-oncology program from May 1999 through March 2004. Patients with a diagnosis of an anaplastic glioma (astrocytoma, oligodendroglioma, or mixed oligoastrocytoma) were selected from consecutive patients from April 1996 through March 2004. Mixed tumor types were used for 2 reasons: to increase the sample size for a more powerful statistical analysis and because the natural history of both anaplastic astrocytomas and anaplastic oligodendrogliomas is to progress to GBM. The diagnosis of grade III glioma was made in most cases on the basis of tissue resected at craniotomy with a minority of the cases (approximately 25%) diagnosed on the basis of biopsy results alone.

Patients were excluded if they did not have a preoperative and postoperative MR imaging with T1 sequences (with and without contrast) and T2 sequences available for review. Treatment was not used to exclude patients. All GBM patients received radiation therapy. Most also were treated with chemotherapy. Most grade III gliomas were treated with radiation therapy. Survival assessment was last performed in June 2004.

Histologic diagnosis was based on the modified World Health Organization classification system. MR imaging scans were read by neuroradiologists (W.B.P., J.P.V.) blinded to patient outcome. Postoperative scans were analyzed to determine the percent of resection. MR imaging sequences were acquired on a 1.5T scanner and included, in most cases, sagittal T1-weighted (TR, 400–550; TE, 14; section thickness, 5 mm), axial T1-weighted (TR, 400; TE, 15; section thickness, 3 mm), T2-weighted fast spin-echo (TR, 4000; TE, 126–130; section thickness, 3 mm), proton attenuation (TR, 4000; TE, 13–15; section thickness, 3 mm), and gadolinium diethylene triamine penta-acetic acid (Omniscan, 10–20 mL; Amersham Health, Princeton, NJ) enhanced axial and coronal T1-weighted images (TR, 400; TE, 15; section thickness, 3 mm), with a field of view of 24 cm and a matrix size of 256×256 . All scans contained at least T1 pre- and postcontrast and T2-weighted images.

Tumor variables determined from the MR imaging scans were characterized according to the criteria outlined in Table 1. The following clinical features were also recorded: age, sex, and perioperative KPS.

Statistical Methods

The end point of the study was patient survival, taken from the date of diagnosis until death or until June 2004. The Kaplan-Meier method was used to estimate survival probabilities. To assess statistical significance of each feature's effect on survival, univariate Cox models were used. Hazard ratios correspond to risk of death, and thus an increased hazard ratio implies a worse prognosis. For all analyses, a *P* value of $<.05$ was accepted as significant. The imaging variables were also assessed by using a stepwise Cox proportional hazard model with bootstrapping, by using Stata 8.0 statistical software (StataCorp LP, College Station, TX). A recursive partitioning analysis by using the classification and regression tree method of Breiman et al (1984) was performed (13). The 10-fold cross-validation was used with minimum-size model within 0.1 SE of the overall minimum cost tree. We confirmed that the log-rank test was significant for each of the splits identified.

Results

A total of 110 patients with histologically confirmed GBM and 41 patients with anaplastic astrocytoma were used for the study.

GBM

At the time of analysis (June 2004), 45/110 (40.9%) of patients were still alive, with a median follow-up of 355 days for patients who died and 423 days for patients still living. The 2- and 5-year probabilities of survival were 24% and 0%. The median survival was 623 days. Patient data are illustrated in Table 2.

A univariate analysis was performed to assess the relationship between imaging features and survival. *P* values $<.05$ were considered significant. Hazard ratios are given in Table 3. Almost all GBMs demonstrated contrast enhancement and necrosis (enhancement, 109/110; necrosis, 105/110), and so these variables were not further analyzed for this tumor grade. It is interesting to note that the single case of nonenhancing GBM had a large oligodendroglioma component and lacked necrosis. This may account for the absence of enhancement. Nonenhancing GBMs have been reported by others as well (14). Some have reported that extent of necrosis is correlated with survival (see Introduction). We did not use this variable, because we wanted to assess only features that were readily determined from routine clinical scans that did not require extensive postprocessing analysis. The following imaging features were found to be statistically significant predictors of longer survival (hazard ratios in parentheses): nCET (0.55), edema (1.62), satellites (1.74), and multifocality (4.3). Definitions are per Table 1. Tumors were scored positive for noncontrast-enhancing tumors (nCETs) if they demonstrated any amount of nonenhancing, solid tissue (Fig 1 for appearance of nCET versus edema). Patients without edema had a median survival of 1098 days versus those with any amount of edema who had a median survival of 442 days ($P < .002$). Median survival was 780 days for GBM patients with nCET compared with 465 days without ($P < .02$). Patients with satellite lesions had a median survival of 341 days compared with 683 days median survival without ($P < .04$). Patients with multifocal lesions had a median survival of 203 days compared with 654 days for those without ($P < .00001$). Cohen's kappa index of inter-rater agreement for these features was (standard error in parentheses): nCET: 0.949 (0.050); edema: 0.926 (0.073); multifocal: 0.875 (0.122); satellites: 0.773 (0.107).

A univariate analysis of the clinical information in addition to imaging features also was performed (Table 3). Age, KPS, percent of resection, and oligodendroglioma component were analyzed. Median survival for patients <50 years of age was 823 days, whereas median survival for patients >50 years of age was 442 days (hazard ratio [HR] 2.29). Median survival for KPS of patients <80 years of age was 384 days compared with median for KPS for patients 80 years of age or older was 654 days (HR 0.98). The presence

TABLE 1: Imaging definitions

Variable	Score	Score Description
Necrosis	0 no, 1 yes	Necrosis is defined as a region within the tumor that does not enhance or shows markedly diminished enhancement, is high on T2W and proton density images, is low on T1W images, and has an irregular border
Enhancement	0 no, 1 yes	Contrast enhancement is defined as having all or portions of the tumor that demonstrate significantly higher signal on the postcontrast T1W images compared to precontrast T1W images
Enhancing rim	0 none, 1 thin, 2 thick, N/A	If most of the enhancing rim is thin, regular, and has homogenous enhancement, the tumor receives a score of 1. If most of the rim demonstrates nodular and/or thick enhancement, the score is 2. If there is only solid enhancement and no rim, the score is 0. The scoring is not applicable if there is no contrast enhancement
Enhancing margin	0 well defined, 1 poorly defined, N/A	If most of the outside margin of the enhancement is well defined, the tumor is scored 1. The scoring is not applicable if there is no contrast enhancement
NEM (grade III)	0 smooth, 1 irregular	If most of the outside nonenhancing margin of the tumor is well defined and smooth (geographic), the tumor is scored 0. If the margin is ill defined, the tumor is scored 1
Solid enhancement	0 none, 1 part, 2 all, N/A	If the enhancing portion of the tumor enhances solidly, without cystic or necrotic components, the tumor is scored 2. If there are both regions of solid enhancement as well as necrosis or central irregular nonenhancement or cyst formation, the tumor is scored 1. If the tumor demonstrates only peripheral or ring enhancement without significant portions, the tumor is scored 0. If there is no enhancement, this variable is not applicable
nCET	0 no, 1 yes	Nonenhancing tumor is defined as regions of T2W hyperintensity (less than the intensity of cerebrospinal fluid, with corresponding T1W hypointensity) that are associated with mass effect and architectural distortion, including blurring of the gray-white interface
Edema	0 none, 1 mild, 2 moderate/severe	If no convincing edema, as demonstrated by regions of very bright T2W signal, then a score of 0 is given. If there is clearly visible, bright T2W signal not associated with mass effect and architectural distortion (see nonenhancing tumor) and not extending more than 1 cm beyond the tumor margin, the score is 1. If there is more extensive, very bright T2W signal intensity, often following white-matter tracts and extending significantly beyond (>1 cm) the margins of the tumor, the edema is scored a 2
Cyst(s)	0 no, 1 yes	Cysts are well defined, rounded, often eccentric regions of very bright T2W signal and low T1W signal essentially matching CSF signal intensity, with very thin, regular, smooth, nonenhancing or regularly enhancing walls, possibly with thin, regular, internal septations
Multifocal	0 no, 1 yes	Multifocal is defined as having at least one region of tumor, either enhancing or nonenhancing, which is not contiguous with the dominant lesion and is outside the region of signal abnormality (edema) surrounding the dominant mass
Satellites	0 no, 1 yes	A satellite lesion is within the region of signal abnormality surrounding the dominant lesion but not contiguous in any part with the major tumor mass
Extent of resection	<20%, 20%–89%, 90%–99%, 100%	The first postoperative scan (contrast-enhanced MR imaging) was assessed for tumor residual. Presence of both enhancing and nonenhancing tumor was determined. Scans were scored 100% resection if no tumor residual was visible. Trace tumor residual <10% of the total corresponded to the 90%–99% category. If the tumor was debulked, but substantial tumor remained, a score of 20%–89% was used. If the tumor was biopsied only, then 0%–19% was used.
TCM	0 no, 1 yes	
ECM	0 no, 1 yes, N/A	
Location	Frontal, parietal, temporal, occipital, corpus callosum, thalamus	
Size	Unidimensional, largest diameter in millimeters	
Side	Left, right	

Note.—NEM indicates nonenhancing margin; nCET, noncontrast-enhancing tumor; TCM, tumor crosses midline; ECM, edema crosses midline.

of a large (but not small) oligodendroglioma component also was a significant prognostic indicator, with mean survival of 703 days for little or no oligodendroglioma component compared with 1193 days for a large oligodendroglioma component (HR 0.58).

Previous studies have used various methods to determine the amount of residual tumor. In the current study, every patient had a postoperative MR imaging that was assessed for both enhancing and nonenhancing tumor. We found that the extent of resection was

not a statistically significant correlate of survival. Median survivals were 663 days for total resection, 513 days for 90%–99% resection, 334 days for 20%–89% resection, and 823 days for <20% resection. The differences were not statistically significant. Even when the data were reorganized into patients with total and subtotal (>90%) resection versus patients with significant tumor residual (<90% resection), or total versus nontotal resection, no survival benefit of more complete resection was found.

TABLE 2: Demographics

Attribute	Grade III Gliomas				Glioblastoma			
	Mean	SD	95% CI		Mean	SD	95% CI	
Age	40.4	14.1	36.4–45.2		54.9	14.3	52.0–57.8	
KPS	86.9	12.8	82.9–90.9		84.2	14.1	81.4–87	
Survival (days)	2010	232	1560–2460		748	60.6	630–867	
Sex		Female, 52.4% Male, 47.6%				Female, 34.5% Male, 65.5%		
Oligodendroglioma	None	Minor	Major		None	Minor	Major	
Component (%)	38.1	28.6	33.3		85.5	7.2	7.3	
Resection (%)	100	90–99	20–89	0–19	100	90–99	20–89	0–19
	16.6	26.2	31.0	26.2	33.7	23.5	26.5	16.3

Note.—KPS indicates Karnofsky performance status.

TABLE 3: Hazard ratios and confidence intervals by attribute

Attribute	Grade III Gliomas			Glioblastomas		
	HR	95% CI	P Value	HR	95% CI	P Value
Clinical						
Age	3.74	1.09–12.9	.036	2.29	1.35–3.86	.002
KPS	0.96	0.93–0.99	.006	0.98	0.96–0.99	.005
Oligodendroglioma component	1.06	0.55–2.07	.854	0.58	0.34–0.99	.047
Resection	1.22	0.67–2.23	.517	1.08	0.85–1.37	.530
Imaging						
Enhancing rim	1.68	0.34–8.37	.519	1.16	0.73–1.84	.522
SE	0.79	0.38–1.61	.508	1.04	0.66–1.63	.863
CE	3.30	0.71–15.3	.127	1.53	0.21–11.1	0.68
ECM	2.45	0.76–7.87	.134	1.33	0.81–2.21	.264
TCM	2.45	0.76–7.87	.134	1.31	0.72–2.36	.374
Location	0.97	0.63–1.52	.914	1.04	0.88–1.23	.639
Multifocal	18.7	3.06–115	.002	4.34	2.11–8.92	.001
Necrosis	4.43	1.35–14.6	.014	1.24	0.30–5.09	.764
nCET	0.05	0.01–0.55	.014	0.55	0.33–0.92	.023
EM	0.32	0.07–1.35	.121	0.64	0.37–1.12	.120
NEM	2.95	0.85–10.3	.089			
Satellites	5.18	1.11–24.1	.036	1.74	1.03–2.93	.038
Side	0.80	0.17–3.79	.782	1.29	0.79–2.07	.300
Size	1.16	0.90–1.50	.235	1.05	0.94–1.17	.393
Cyst	0.03	0.00–20.8	.302	0.92	0.46–1.80	.799
Edema	1.99	0.79–3.99	.158	1.62	1.18–2.22	.003

Note.—HR indicates hazard ratio (of dying); KPS, Karnofsky performance status; SE, solid enhancement; CE, contrast enhancement; ECM, edema crosses midline; TCM, tumor crosses midline; nCET, noncontrast-enhancing tumor; EM, enhancing margin; NEM, nonenhancing margin.

Combining the favorable indicators in a multivariate analysis and comparing them to the groups as a whole showed that patients with nCET but without edema, satellites, and multifocality had median survival of 1098 days (mean, 1106 days; SE, 135) compared with 501 days (mean, 659 days; SE, 57 days) for the remainder. Conversely, patients without nCET but with edema and either satellites or multifocality had median survivals of 384 days (mean, 572 days; SE, 61 days) compared with 823 days (mean, 1047 days; SE, 100 days) for the remainder (Fig 2). The difference in survival between the favorable and unfavorable groups was highly significant ($P < .0001$). The imaging variables were also assessed by using a stepwise Cox proportional hazard model with bootstrapping, which demonstrated that 3 imaging variables are independent predictors of survival: nCET, multifocality, and satellites. The hazard ratios in this analysis

were 0.47 (nCET), 6.2 (multifocality), and 1.7 (satellites), which are within the confidence intervals for the hazard ratios of the univariate analysis. Because edema correlates inversely with nCET (see below), in this analysis edema was not an independent predictor of survival.

Recursive partitioning analysis was performed on the 110 patients with GBM by using all 15 imaging features analyzed (Fig 3). The first branch point was the presence (grades 1 and 2) or absence (grade 0) of edema, with the presence of edema generating a terminal node. The second partitioning was based on the presence or absence of noncontrast enhancing tumor. It is interesting that the presence of satellites and multifocality did not enter into the partitioning analysis, even though they had a significant impact on prognosis. Multifocality was always associated with some amount of edema

FIG 1. MR images of patients with GBM.

A, Axial postcontrast T1-weighted images. There is an enhancing tumor with central, irregular hypoenhancement consistent with necrosis.

B, Axial T2-weighted images of the same patient shown in panel A. High T2-weighted signal intensity surrounds the tumor, with signal intensity approaching that of CSF as seen in the lateral ventricles. The T2-weighted signal intensity change respects the cortical ribbon. The appearance is indicative of vasogenic edema (grade 2, extending more than 1 cm from the tumor, per definitions in Table 1).

C, Axial postcontrast T1-weighted images of another GBM patient. As in the first case there is an enhancing tumor with irregular central hypoenhancement indicating necrosis.

D, Axial T2-weighted images of the same patient shown in panel C. Adjacent to the enhancing portion of the tumor, there is increased T2-weighted signal intensity, which is significantly lower than that of CSF, which extends into the cortex and does not respect the cortical ribbon. The gray-white distinction is obscured. The region corresponds to areas of mildly low T1-weighted signal intensity. This appearance reflects the presence of nonenhancing tumor (nCET). There is also a sliver of higher T2-weighted signal intensity change at the medial margin of the tumor, which indicates a small amount of edema.

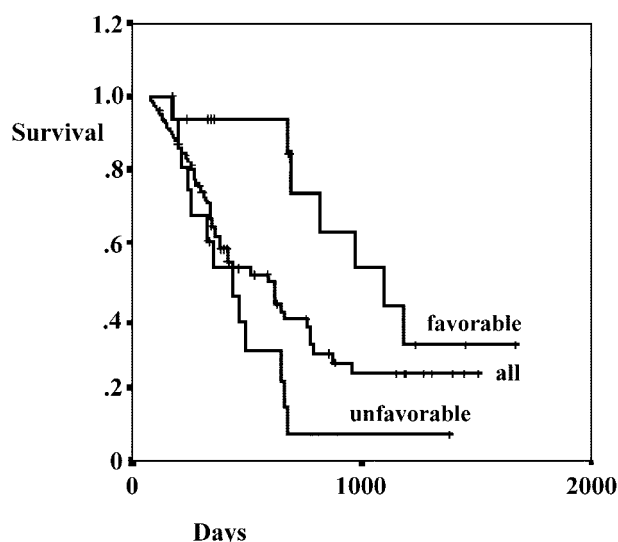
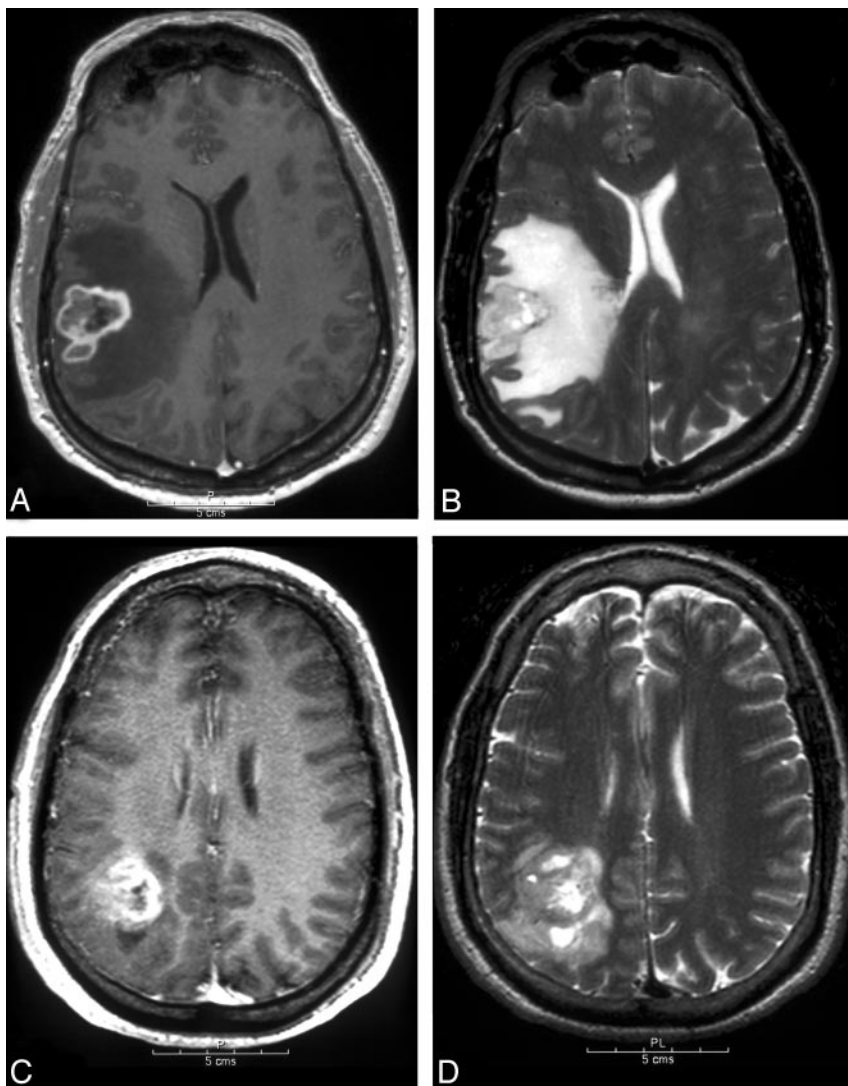


FIG 2. Survival curves for glioblastoma. Favorable ($n = 16$) is tumors with nCET and without edema, satellites, and multifocal disease. Unfavorable ($n = 17$) is edema, and either satellites or multifocal disease, without nCET ($n = 110$ for all GBM patients).

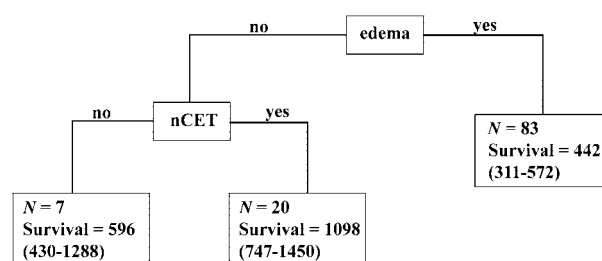


FIG 3. Recursive partitioning analysis. All 15 imaging features as described in the Methods section were entered into the recursive partitioning algorithm. The 95% confidence intervals are shown in parentheses.

in GBM patients, likely accounting for its absence in the recursive analysis.

In the multivariable analysis, we found that edema without nCET is not significant, whereas edema with nCET is significant. A trend in survival based on the amount of edema is seen for patients with nCET, but this was not statistically significant.

Because age was such an important clinical prognostic indicator, we examined the relationship of age

TABLE 4: Correlations for glioblastoma clinical and imaging features

	KPS	Age	Necrosis	nCET	Edema
KPS		-0.290	-0.156	0.100	-0.128
<i>P</i>		.002	.103	.301	.184
Age	-0.290		0.194	-0.374	0.300
<i>P</i>	.002		.042	.001	.001
nCET	0.100	-0.374	-0.076		-0.357
<i>P</i>	.301	<.001	.429		<.001
Edema	-0.128	0.300	0.159	-0.357	
<i>P</i>	.184	.001	.098	<.001	
Multifocality	-0.178	0.149	0.069	0.174	.165
<i>P</i>	.063	.119	.474	.069	0.084
Satellites	-0.064	0.105	0.131	0.025	0.122
<i>P</i>	.510	.275	.174	.792	.204

Note.—KPS indicates Karnofsky performance status; nCET, non-contrast-enhancing tumor. Correlations with *P* values <.05 are set in boldface type.

to the prognostically significant imaging features (Table 4). For younger patients (<50 years of age), 65% had nCET, compared with 30% of patients 50 years of age or older ($P < .001$). For edema, 63% of younger patients compared with 84% of older patients had mild or more edema ($P = .014$). Edema also is correlated with nCET, with a Cramer's *V* dependence measure of 0.36, significant at the $P < .001$ level. For patients with nCET, 33% had edema versus 67% of the patients without nCET.

That the presence of nCET conveyed a significant survival benefit in patients >50 years of age, in contrast to those <50 years of age—though there was a trend for patients <50 years of age ($P = .35$)—is interesting. Therefore, the benefit of nCET appears to be not simply due to a correlation between the presence of nCET with younger age. The presence of nCET positively correlated with a large oligodendroglioma component as 88% of patients with a large oligodendroglioma component had nCET versus 41% of patients overall ($P = .027$). The presence of satellites and multifocality did not appear to be significantly correlated with age ($P = .569$ and $P = .222$, respectively). All GBM patients with multifocal lesions had at least some edema, but the severity of the edema was highly variable.

Anaplastic Glioma

At the time of analysis (June 2004), 30 of 42 (71.4%) patients were still alive, with a median follow-up of 1016 days for patients who were still alive and 441 days for patients who died. The 2- and 5-year probabilities of survival for the patients in this study are 50% and 9.5%, respectively. The median survival was 746 days (Table 2).

In a univariate analysis, the imaging characteristics that were statistically significant predictors of improved survival were no necrosis, multifocality, or satellites, and presence of nCET. Positive trends were seen with irregular contrast-enhancing edge, no edema, cysts, and no extension of tumor or edema

across midline, but these were not statistically significant at the 95% confidence level (Table 3). Anaplastic gliomas had much lower rates of enhancement and imaging evidence of necrosis—56% and 20%, respectively—than GBM. Because enhancement and necrosis are nearly ubiquitous in GBM, and because GBM patients have much worse prognoses than those with anaplastic astrocytomas, we assessed whether enhancement and/or necrosis is a negative prognostic factor in anaplastic glioma. We found that for anaplastic glioma with necrosis ($n = 8$), the median survival was 443 days (mean, 816 days; SE, 197 days), whereas without necrosis ($n = 31$) the median survival was 773 days (mean, 2270 days; SE, 246 days). The Cox hazard ratio for necrosis was 4.43 ($P < .014$; Table 2). Thus, patients with imaging evidence of necrosis had survival comparable to GBM patients. Grade III glioma patients with enhancing tumor had a median survival of 694 days, compared with those with no enhancing tumor, who had a mean survival of 1769 days. The data suggested a shorter survival for patients with enhancing tumors, but the results were not statistically significant.

In a univariate analysis of the clinical data, we found that, as with GBM, there was no survival benefit associated with increased percentage of tumor resected (Table 3). The oligodendroglioma component also was not a statistically significant predictor of survival. As expected, survival was positively correlated with KPS and negatively correlated with age, both at statistically significant levels.

Discussion

Malignant gliomas are heterogeneous appearing tumors with variable survival times (1–3). Most patients with malignant gliomas are diagnosed and followed with MR imaging. Therefore, the relationship between survival and the appearance of tumor on MR imaging is important. We analyzed an extensive number of imaging features to determine which would be most useful as prognostic indicators. These features were selected to be easily determined from routine scans and therefore useful in everyday clinical practice. Being better able to determine prognosis from routine imaging studies may provide aid in making treatment decisions.

In a univariate analysis of 15 imaging features of patients with GBM, we found that only nCET, edema, and multifocality/satellite lesions were statistically significant prognostic indicators. The relationship between increased edema and poorer patient outcomes is well established (5–7). The survival advantage of nCET is a novel finding. For patients with GBM, median survival with nCET was 780 days, compared with 465 days without ($P < .03$). Edema and the presence of nCET were inversely correlated. Younger patients tended to have more nCET and less edema, possibly reflecting underlying differences in tumor biology, which may partly explain why younger patients have longer median survival times than older ones. Although nCETs were more common in

younger patients, the survival benefit was more pronounced for patients >50 years of age. It is interesting that the prognostic value of genetic lesions in GBM has been shown to be age-dependent (15). This raises the possibility that imaging features may also demonstrate an age-related effect.

By combining the favorable versus unfavorable imaging features, we found a great difference in survival curves. Thus, GBM patients with nCET and without edema, satellites, and multifocality had a median survival of 1098 days (mean, 1106 days; $n = 16$) compared with patients without nCET but with edema and either satellites or multifocality ($n = 17$), who had a median survival of 437 days (mean, 481 days; $P < .001$). As a whole, patients with GBM had a median survival of 623 days. These data illustrate the profound prognostic importance that can be derived from combining selected imaging features.

A large oligodendroglioma component has been correlated with improved survival for GBM patients (16). Some GBMs, though lacking an oligodendroglioma component pathologically, still express oligodendroglial genes (1). We found that a large oligodendroglioma component was positively correlated with survival in patients with GBM as well. Thus GBM patients with a large oligodendroglioma component had mean survival of 1193 days (SE, 176 days; $n = 8$), compared with a mean survival of 703 days (SE, 60 days; $n = 102$; $P = .04$) for GBM patients with none or little oligodendroglioma histology. The data analysis also revealed a correlation between oligodendroglioma component and nonenhancing tumor. Thus, part of the survival benefit of nCET may be due to the association with an oligodendroglioma component. In GBM patients with nCET but without an oligodendroglioma component, there was a trend toward increased survival, but this was not statistically significant. A larger study would be required to show that nCET is beneficial in the absence of an oligodendroglioma component.

Because the regions of nCET lack necrosis, they likely correspond to regions of tumor with a lower pathologic grade. The overall pathologic grade of gliomas is based on the most aggressive portion of the lesion. These findings, however, suggest that less-aggressive portions of the tumor also significantly affect outcome. Ongoing genetic analysis may provide additional information on the similarities and differences between the nonenhancing portions of tumors with and without an oligodendroglioma component.

Edema was significant prognostically in both univariate and multivariable analysis, as others have reported (6, 7). There was an association between less edema and the presence of nCET. Patients without edema had a median survival of 1098 days compared with median survival of 442 days for patients with edema. In a recursive partitioning analysis, edema was the first branch point and nCET was the second, which suggests that these are the most important of the imaging features when analyzed together. The presence of edema was statistically significant only in the presence of nCET. Only a few patients ($n = 7$)

without nCET, however, had absolutely no edema, which may explain why edema was not shown to be statistically significant in GBM patients without nCET.

The other variables that were statistically significant in the univariate analysis of GBM were multifocality and satellite lesions. Patients with either satellite lesions or multifocal lesions had significantly worse survival. Although intuitively these findings make sense, there appears to be no prior corroborating literature. Multifocal gliomas are associated with increased rates of p53 germ-line mutations (17). Therefore, these tumors may represent a form of GBM with a different genetic signature. It would be of interest to determine gene expression in multifocal versus nonmultifocal glioblastomas, because these differences may explain the significantly worse prognosis of multifocal disease.

Several groups have reported that the extent of necrosis and amount of edema is inversely correlated with survival (5–7). There also is evidence supporting the association of the pathologic evidence of necrosis with poor outcomes (18). Many of the imaging studies evaluating necrosis found that the extent of necrosis, rather than merely its presence or absence, was correlated with survival. In GBMs, there are gene products linked to necrosis that are correlated with survival (19). We found that nearly all GBMs show evidence of necrosis but did not analyze the extent of necrosis because the postprocessing required to determine the volume of necrotic tumor would not be practical for routine imaging. For grade III gliomas, however, we did find that imaging evidence of necrosis was associated with a worse outcome.

Pathologically, grade III gliomas lack necrosis. Pathologic evidence of necrosis is associated with a worse outcome and, in general, separates grade III and IV tumors (20). Approximately 25% of the anaplastic gliomas we analyzed had imaging evidence of necrosis (ie, peripheral irregular enhancement with central high T2-weighted signal intensity), even though no necrosis was seen histopathologically. A portion of the discrepancy may be explained by sampling error in which portions of the tumor available to the pathologist do not incorporate the area of presumed necrosis. For instance, it has been found that stereotactic biopsy underestimates tumor grade in a significant percentage of patients thought to have anaplastic astrocytoma, when later resected specimens reveal GBM (21). Most of the necrotic grade III tumors (5 of 8) in our study underwent >90% resection, which should reduce sampling error. Another possibility is that necrotic tissue may be suctioned at surgery and not available for histopathology. We found that grade III gliomas that had imaging evidence of necrosis had survival comparable to GBMs, and much worse than grade III gliomas as a whole. Others have reported similar findings in which anaplastic gliomas showing ring enhancement compatible with necrosis are associated with poor survival (22). This raises the possibility that a significant proportion of tumors diagnosed as grade III gliomas, including

tumors that have been mostly resected, are truly GBMs. The survival curves from patients with necrotic tumors diagnosed as grade III gliomas support this conclusion. Thus, the differentiation between grade III gliomas and GBM remains challenging. Cerebral blood volume studies have shown improved sensitivity (although slightly lower specificity) in differentiating low-grade from malignant gliomas; however, no difference in rCBV was found between grade III gliomas and GBMs (14, 23).

In addition to necrosis, we also found that enhancement itself is associated with a worse prognosis. This, however, is probably due to the close correlation between enhancement and necrosis. It is thought that necrosis results in blood-brain barrier breakdown, which leads to both enhancement and edema (24). Patients with grade III gliomas showing only solid enhancement—and therefore lacking imaging evidence of necrosis—had survival equivalent to patients with completely nonenhancing tumor.

Specific genetic deletions in oligodendrogliomas associated with an improved prognosis have been reported to be associated with an irregular noncontrast-enhancing border on MR imaging (25). We did not find this to be the case with grade III astrocytomas and mixed oligoastrocytomas. In fact, an irregular border for grade III tumors tended to be associated with shortened survival, though this did not reach the 95% confidence level, ($P = .089$). It is interesting to note that an irregular contrast-enhancing margin appeared to correlate with improved survival, but, again, statistical significance was not reached, perhaps because of the small number of cases with smooth borders ($n = 4$). Additional patients and longer follow-up times, along with correlation with genetic data, will be required to determine whether the genetic differences underlying enhancing and nonenhancing regions of tumor are significant indicators of survival. It has already been reported that contrast-enhancing regions of tumor appear to demonstrate more heterogeneous proteomic patterns than noncontrast-enhancing regions, at least for GBMs (26). Similar studies for grade III gliomas have not yet been performed.

The survival benefit of tumor resection remains controversial (4, 7, 9, 11–13). In some analyses, the extent of resection was based on the surgeon's impression at the time of surgery and not postoperative scans. Other research used CT scans rather than MR imaging, and others analyzed only contrast-enhancing tumor, rather than both enhancing and nonenhancing tumors. Some studies also suffer from methodologic flaws. For example, in the study by Stark et al (11), approximately 17% of the GBM patients did not receive radiation after surgery because of their poor medical condition. This introduces a confounder, because patients with larger tumors would be more likely to undergo partial resection and would also be in poorer medical condition and, therefore, less likely to receive radiation therapy. The lack of prospective studies is likely a significant factor in this ongoing debate.

In our study, all GBM patients received radiation, and every patient had a postoperative MR imaging, which was assessed for both enhancing and nonenhancing tumors. We did not find that a statistically significant survival benefit was conferred by increased tumor resection. One report with a large number of patients showed improved survival only when >98% of the tumor was resected (7). One of the limitations of our study is that we analyzed only imaging features that are readily apparent from routine MR imaging scans without additional postprocessing to obtain initial and postoperative residual tumor volumes. Thus, we were not able to confirm this finding.

Conclusion

Several imaging features for GBMs and grade III gliomas are meaningful predictors of survival. A favorable combination of imaging features—including nCET, no edema, and no satellite or multifocal lesions—corresponds to a doubling of the median survival compared with an unfavorable combination, underscoring the potential usefulness of these criteria for determining the prognosis of patients in routine clinical practice. Information derived from imaging analysis may be helpful, as more treatments become available, in directing a more individually tailored therapeutic approach.

References

1. Mischel PS, Shai R, Shi T, et al. **Identification of molecular subtypes of glioblastoma by gene expression profiling.** *Oncogene* 2003;22:2361–2373
2. Burger PC, Heinz ER, Shibata T, Kleihues P. **Topographic anatomy and CT correlations in the untreated glioblastoma multiforme.** *J Neurosurg* 1988;68:698–704
3. Rees JH, Smirniotopoulos JG, Jones RV, Wong K. **Glioblastoma multiforme: radiologic-pathologic correlation.** *Radiographics* 1996; 16:1413–1438; quiz 1462–1463
4. Kowalczyk A, Macdonald RL, Amidei C, et al. **Quantitative imaging study of extent of surgical resection and prognosis of malignant astrocytomas.** *Neurosurgery* 1997;41:1028–1036; discussion 1036–1038
5. Pierallini A, Bonamini M, Pantano P, et al. **Radiological assessment of necrosis in glioblastoma: variability and prognostic value.** *Neuroradiology* 1998;40:150–153
6. Hammoud MA, Sawaya R, Shi W, et al. **Prognostic significance of preoperative MRI scans in glioblastoma multiforme.** *J Neurooncol* 1996;27:65–73
7. Lacroix M, Abi-Said D, Fourney DR, et al. **A multivariate analysis of 416 patients with glioblastoma multiforme: prognosis, extent of resection, and survival.** *J Neurosurg* 2001;95:190–198
8. Maldaun MV, Suki D, Lang FF, et al. **Cystic glioblastoma multiforme: survival outcomes in 22 cases.** *J Neurosurg* 2004;100:61–67
9. Laws ER, Parney IF, Huang W, et al. **Survival following surgery and prognostic factors for recently diagnosed malignant glioma: data from the Glioma Outcomes Project.** *J Neurosurg* 2003;99: 467–473
10. Keles GE, Anderson B, Berger MS. **The effect of extent of resection on time to tumor progression and survival in patients with glioblastoma multiforme of the cerebral hemisphere.** *Surg Neurol* 1999;52:371–379
11. Stark AM, Nabavi A, Mehdorn HM, Blomer, U. **Glioblastoma multiforme: report of 267 cases treated at a single institution.** *Surg Neurol* 2005;63:162–169
12. Hess KR. **Extent of resection as a prognostic variable in the treatment of gliomas.** *J Neurooncol* 1999;42:227–231
13. Breiman L, Friedman JH, Olshen RA, Stone CJ. *Classification and regression trees.* Belmont, CA: Wadsworth International Group;1984

14. Knopp EA, Cha S, Johnson G, et al. **Glial neoplasms: dynamic contrast-enhanced T2*-weighted MR imaging.** *Radiology* 1999;211:791-798
15. Batchelor TT, Betensky RA, Esposito JM, et al. **Age-dependent prognostic effects of genetic alterations in glioblastoma.** *Clin Cancer Res* 2004;10:228-233
16. Donahue B, Scott CB, Nelson JS, et al. **Influence of an oligodendroglial component on the survival of patients with anaplastic astrocytomas: a report of Radiation Therapy Oncology Group 83-02.** *Int J Radiant Oncol Biol Phys* 1997;38:911-914
17. Kyritsis AP, Bondy ML, Xiao M, et al. **Germline p53 gene mutations in subsets of glioma patients.** *J Natl Cancer Inst* Mar 2 1994;86:344-349
18. Burger PC, Green SB. **Patient age, histologic features, and length of survival in patients with glioblastoma multiforme.** *Cancer* 1987;59:1617-1625
19. Raza SM, Fuller GN, Rhee CH, et al. **Identification of necrosis-associated genes in glioblastoma by cDNA microarray analysis.** *Clin Cancer Res* 2004;10:212-221
20. Sallinen PK, Sallinen SL, Helen PT, et al. **Grading of diffusely infiltrating astrocytomas by quantitative histopathology, cell proliferation and image cytometric DNA analysis: comparison of 133 tumours in the context of the WHO 1979 and WHO 1993 grading schemes.** *Neuropathol Appl Neurobiol* 2000;26:319-331
21. Jackson RJ, Fuller GN, Abi-Said D, et al. **Limitations of stereotactic biopsy in the initial management of gliomas.** *Neurooncol* 2001;3:193-200
22. Tortosa A, Vinolas N, Villa S, et al. **Prognostic implication of clinical, radiologic, and pathologic features in patients with anaplastic gliomas.** *Cancer* 2003;97:1063-1071
23. Law M, Yang S, Wang H, et al. **Glioma grading: sensitivity, specificity, and predictive values of perfusion MR imaging and proton MR spectroscopic imaging compared with conventional MR imaging.** *AJNR Am J Neuroradiol* 2003;24:1989-1998
24. Pronin IN, Holodny AI, Petraikin AV. **MRI of high-grade glial tumors: correlation between the degree of contrast enhancement and the volume of surrounding edema.** *Neuroradiology* 1997;39:348-350
24. Megyesi JF, Kachur E, Lee DH, et al. **Imaging correlates of molecular signatures in oligodendrogliomas.** *Clin Cancer Res* 2004;10:4303-4306
26. Hobbs SK, Shi G, Homer R, et al. **Magnetic resonance image-guided proteomics of human glioblastoma multiforme.** *J Magn Reson Imaging* 2003;18:530-536