

Generic Contrast Agents

Our portfolio is growing to serve you better. Now you have a *choice*.



[VIEW CATALOG](#)

AJNR

Metastases in Head and Neck Cancer

AJNR Am J Neuroradiol 2005, 26 (10) 2700-2701
<http://www.ajnr.org/content/26/10/2700>

This information is current as
of May 25, 2025.

Book Review

Metastases in Head and Neck Cancer

Edited by Jochen A. Werner and R. Kim Davis. London: Springer; 2005. 233 pages, 106 illustrations, \$149

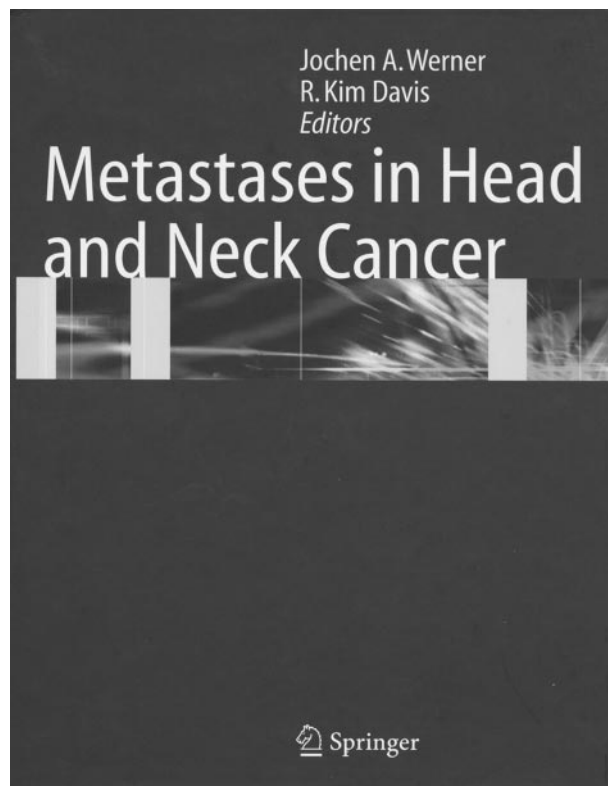
Metastases in Head and Neck Cancer was written by 2 otolaryngologists and is primarily directed toward clinicians. The book has 233 pages, is divided into 11 chapters, and is written in a descriptive and highly personal manner. The authors reference the literature liberally but also freely insert their own personal opinions and experiences to support their recommendations in each chapter.

Chapter 1 discusses the “Basics of Lymphology.” It starts by reviewing the history, embryology, morphology, and distribution of the lymphatics. Although there are some very nice drawings of the lymphatic drainage of the oral cavity, larynx, and pharynx, the reader could have benefitted from more of these drawings reviewing the embryology and the other lymphatic drainage sites discussed. The authors then review the historic changes in the clinical nodal classification in the neck. Although they present the imaging-based classification in chapter 4, it might have been better for continuity to at least mention it here, because this classification has become widely accepted by clinicians and has therefore gained importance for both clinicians and radiologists. This discussion is followed by a brief review of the cervical fascia and a review of the physiology and pathophysiology of the lymph nodes.

Chapter 2 addresses “Lymphogenic Metastatic Spread.” It reviews the various primary tumor sites and their expected metastatic nodal regions of tumor spread. The chapter also presents the overall frequency of metastasis for the various sites and most pathologic tumor types. This information is supplemented by both diagrams and tables.

Chapter 3 discusses the “Pathology of Lymphogenic Metastatic Spread.” There is a discussion of how surgical specimens should be treated and reported by the pathologist. There is also a thorough discussion of the histologic findings; however, the discussion of the currently used immunochemical markers is brief, and the reader could have benefitted from a more thorough discussion and from a table that would review this important pathologic area. There is a thorough discussion of micrometastases and their unclear effect on staging and prognosis as well as a detailed section on extracapsular tumor extension. This chapter finishes with mention of nodal metastases from unknown primaries and primary tumors outside the head and neck. Brief mention is made of some of the nonneoplastic lymph node diseases.

Chapter 4 addresses “Diagnostic Techniques.” There are very thorough discussions of B-mode sonography and color-coded duplex sonography and a brief section on 3D sonography. There is also a sec-



tion on the ultrasound-guided fine-needle aspiration technique. Some sample images for the ultrasound sections are shown. This discussion is followed by a brief section on CT imaging. Some general statements are made, but no imaging examples are presented. Similarly, a brief section on MR imaging again has no imaging examples. With the expression the “European” philosophy, the authors suggest that ultrasound is superior to either CT and/or MR imaging, yet they only briefly mention the problem of deeply situated nodes not being seen well on ultrasound as well as of the failings of ultrasound to accurately map most of the primary tumor sites. Because much of the imaging in patients with head and neck cancer is performed to assess both nodal disease and the primary site, this failing is an important factor in deciding on a primary technique of choice to examine the neck. The authors imply that ultrasound will soon become the preferred imaging technique for nodal disease in the United States, as it is in Europe; however, this remains to be seen. Next is a short discussion about lymphoscintigraphy and dynamic scintigraphy and their present limited use. There is a discussion of the use of positron-emission tomography. The authors omit a discussion of positron emis-

sion tomography/CT studies and mention the use of positron-emission tomography as being better in following patients already treated. The omission of a positron-emission tomography/CT section is unfortunate because this approach is gaining widespread use, despite its high cost. This chapter also does not mention the literature on the growing use of positron-emission tomography/CT in the initial workup of these patients. This chapter ends with a brief discussion of biopsy techniques.

Chapter 5 addresses the "Principles of Surgery." It starts with a brief history of neck dissections, which is followed by an in-depth discussion of all forms of neck dissections, along with reviews of approaches to carotid artery occlusion, the timing of a neck dissection, and the treatment of the geriatric patient. Showing the surgical orientation of the authors, a discussion of incision types and then specific discussions on each type of neck dissection follow. This chapter has very good drawings and a thorough presentation.

Chapter 6 addresses "Radiation Therapy: Principles and Treatment." There is a brief discussion of elective neck irradiation and postoperative radiation. The use of concomitant chemotherapy/radiotherapy is also mentioned. This discussion is followed by a thorough discussion of intensity-modulated radiation therapy, its application to various head and neck tumor sites, and its potential future applications. This chapter also has good drawings and tables to supplement the text.

Chapter 7 addresses "Surgical Treatment Concepts." There is a discussion of the philosophies regarding treating the N0 neck, the contralateral N0 neck with ipsilateral N+ neck, and the verified N+ neck. There are also discussions regarding fixed nodes, adjacent vascular infiltration, surgery following radiation and/or chemotherapy, stomal recurrences, and retropharyngeal node disease. This section is followed by a description of neck dissections for lymphoepithelial carcinomas and salivary gland, skin, and thyroid gland malignancies. The chapter ends with a discussion of sentinel node biopsies. The authors suggest that for the N0 neck, intraoperative assessment does not seem to improve the accuracy of staging and that metastatic nodes are 3 mm or less in diameter, taking note that this may well support the concept of selective neck dissections in otherwise N0 necks.

Chapter 8 is devoted to "Complications," primarily from surgery. These include wound healing impairments, vascular damage, nerve damages, chylus fistulas and chylothorax, increased intracranial pressure, visual loss, lymphedema, and clavicular fractures. The chapter ends with a discussion of radiation complications, including both acute and delayed effects.

Chapter 9 addresses "Cancer of Unknown Primary Sites." There is a discussion of general considerations

(epidemiology, hypothesis for genesis, topography of nodal metastases from an unknown primary tumor, and diagnostic approaches). There is also a discussion of the prognosis of this patient population regarding the sites of nodal disease. The problems of metastatic adenocarcinoma to the neck from an unknown primary and from melanoma of an unknown primary are also discussed. This chapter ends with a discussion of treatment concepts. The initial discussion relates to primary radiation and/or chemotherapy, combined surgery and radiotherapy, and a review of radical-versus-modified-versus-selective neck dissections. There are also discussions of treatment concepts of the N1 neck, the contralateral N0 neck, and metastatic adenocarcinoma and melanoma. Last, the authors address the topic of the importance of discovering the primary tumor site after treatment, and there is also a thorough discussion of branchiogenic carcinoma.

Chapter 10 addresses "Distant Metastases." In a short chapter, the epidemiology of these metastases is discussed and is followed by a brief review of the incidence of distant metastases from most of the major primary head and neck tumor sites.

Chapter 11, the last chapter in the book, briefly deals with "Post-Therapeutic Follow-Up Principles." Follow-up interval; type, extent, and cost of follow-up; and possible strategies are discussed. The authors emphasize that the greatest surveillance should be in the first 2 years after treatment. They again emphasize not only clinical examination but the use of sonography. The authors admit to using CT for screening and following chest disease and using CT and MR imaging for evaluating the abdomen.

Overall, this is a thorough personal review of primarily the surgical approaches and treatment of head and neck cancer. There is also a good discussion regarding the roles of radiation therapy and chemotherapy as well as an approach to patient surveillance. For surgeons or radiation and/or medical oncologists, this book presents an overview of the topics mentioned. If there is a weakness, it is in the role of imaging in the diagnosis and surveillance of these patients. The authors do not give a neutral overview but rather a highly personal opinion on the topic of imaging. Unfortunately, there is no discussion of positron-emission tomography/CT imaging, a growing major influence in imaging patients with head and neck cancer. As such, radiologists interested in obtaining a current overview of the role of ultrasound, CT and MR imaging, and positron-emission tomography/CT imaging in patients with head and neck cancer may be disappointed. If, however, a radiologist wants to get a thorough overview of the surgical, radiation oncologic, and chemotherapeutic treatments of cervical nodal metastases, this book provides this information in a single text.