

Generic Contrast Agents

Our portfolio is growing to serve you better. Now you have a *choice*.



[VIEW CATALOG](#)

AJNR

Percutaneous Laser Disk Decompression: A Review of the Literature

B. Schenk, P.A. Brouwer, W.C. Peul and M.A. van Buchem

AJNR Am J Neuroradiol 2006, 27 (1) 232-235

<http://www.ajnr.org/content/27/1/232>

This information is current as
of May 28, 2025.

B. Schenk
P.A. Brouwer
W.C. Peul

M.A. van Buchem

Percutaneous Laser Disk Decompression: A Review of the Literature

Sciatica, which is usually caused by herniation of an intervertebral disk, is a common problem with an annual incidence of 5 per 1000.^{1,2} In 60%–80% of patients experiencing their first episode of radicular pain, the symptoms recede to a nondisabling level within a period of 6 weeks.² The remaining group of patients qualifies for (surgical) intervention.^{3–5} Because of the considerable morbidity and convalescence period inherent to conventional lumbar disk surgery, there has been an ongoing search for less-invasive methods of treatment.

Percutaneous laser disk decompression (PLDD) is one of the so-called “minimally invasive” treatment modalities for contained lumbar disk herniation. The treatment is performed percutaneously, so morbidity is expected to be lower and convalescence period is postulated to be shorter than for conventional surgery. Because of the minimally invasive nature and the fact that return to work is usually possible within a few days after treatment, PLDD appears to be an interesting alternative to conventional surgery; however, considerable skepticism still greets PLDD. Opponents usually dismiss PLDD as being an experimental treatment with unproven efficacy, whereas those advocating the use of PLDD tend to present it as some kind of miracle treatment. In this review, we try to establish a balanced view on the current position of PLDD in the range of treatment modalities for lumbar disk herniation.

History

The idea of using laser in the treatment of lumbar disk herniations arose in the early 1980s. After a series of in vitro experiments Choy and colleagues performed the first PLDD on a human patient in February 1986.⁶ The US Food and Drug Administration approved PLDD in 1991. By 2002, some 35,000 PLDDs had been performed worldwide.⁷

Treatment Principle of PLDD

The treatment principle of PLDD is based on the concept of the intervertebral disk being a closed hydraulic system. This system consists of the nucleus pulposus, containing a large amount of water, surrounded by the inelastic annulus fibrosus. An increase in water content of the nucleus pulposus leads to a disproportional increase of intradiskal pressure. In vitro experiments have shown that an increase of intradiskal vol-

ume of only 1.0 mL causes the intradiskal pressure to rise by as much as 312 kPa (2340 mmHg).⁶ On the other hand a decrease of intradiskal volume causes a disproportionately large decrease in intradiskal pressure. The radicular pain that characteristically accompanies lumbar disk herniation is the result of nerve root compression by the herniated portion of nucleus pulposus. A reduction of intradiskal pressure causes the herniated disk material to recede toward the center of the disk, thus leading to reduction of nerve root compression and relief of radicular pain. In PLDD, this mechanism is exploited by application of laser energy to evaporate water in the nucleus pulposus. Laser energy is delivered by a laser fiber through a hollow needle placed into the nucleus pulposus. The needle is placed into the intervertebral disk under local anesthesia. Apart from evaporation of water, the increase in temperature also causes protein denaturation and subsequent renaturation. This causes a structural change of the nucleus pulposus, limiting its capability to attract water and therefore leading to a permanent reduction of intradiskal pressure by $\leq 57\%$.⁶

Technique of PLDD

Sixteen clinical trials were included in this review, representing a total of 1579 patients (Table 1). Trials were only included if they provided enough information on techniques used in the procedure (laser type, parameters used, etc) and no additional techniques such as endoscopy were used. Clinical trials were only included when they addressed the outcome of PLDD.

The basic technique of PLDD is the same for all trials. The procedure is conducted under local anesthesia of the skin and underlying muscles. After assessment of the correct disk level by using fluoroscopy, a hollow needle is inserted 10 cm from the midline, pointing toward the center of the disk. When the needle is in place, its correct position is verified by using biplanar fluoroscopy, sometimes in combination with CT imaging. A laser fiber (0.4 mm) is inserted through the needle into the center of the nucleus pulposus (Fig 1). Laser energy is then delivered into the nucleus pulposus to vaporize its content and reduce intradiskal pressure (Fig 2A–D).

Although the techniques used in the different studies are based on the same basic principles, there is a considerable degree of variation in the way PLDD is performed.

Differences can be found in the choice of laser type and laser parameters used (Table 2), and imaging techniques used during the procedure. All but one trial used fluoroscopy as the main imaging method for needle placement. Two studies used additional CT imaging both for assessment of the desired needle tract and for verification of its correct position.^{8,9} One trial

Received July 4, 2005; accepted after revision November 1.

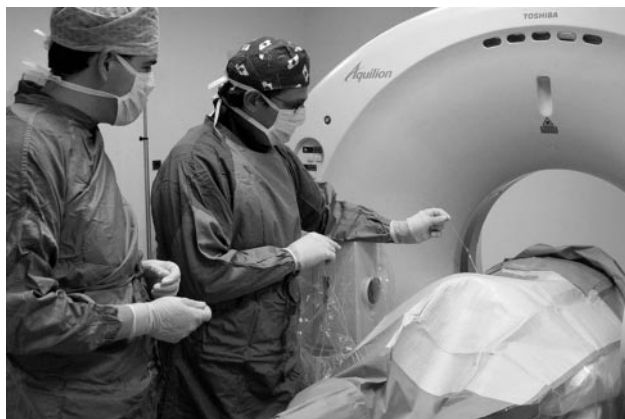From the Departments of Radiology (B.S., P.A.B., M.A.v.B.) and Neurosurgery (W.C.P.), Leiden University Medical Center, Leiden, the Netherlands; and the Department of Neurosurgery, Haaglanden Medical Center, the Hague, the Netherlands.

Address correspondence to B. Schenk, MD, Department of Radiology, C2-S, Leiden University Medical Center, PO Box 9600, 2300 RC Leiden, the Netherlands.

Table 1: Clinical studies included in this review

Reference No.	Number of Patients	Successful Outcome			Complications		Nature of Trial	Follow-up (months)
		<i>n</i>	%	CI (%)	<i>n</i>	%		
8	26	20	77	59–95	0	0	Case series	?
9	169	128	76	70–82	2	1.2	Case series	19 (mean)
10	7	6	86	60–100	1	12.5	Case series	3–4
11	63	44	72	59–85	1	1.8	Case control	20–45
12	350	265	76	72–80	5	0.97	Case series	84 (mean)
13	14	9	64	33–95	0	0	Case series	6
14	82	57	70	58–82	0	0	Case series	12–24
15	46	31	67	50–84	0	0	Case series	2–21
16	50	37	74	60–88	4	8	Case series	24–60
17	99	86	87	80–94	0	0	Case series	24
18	197	147	75	69–81	1	0.51	Case series	Max. 44
19	147	115	78	71–85	1	0.6	Case series	Max. 60
20	35	32	92	83–100	1	2.8	Case series	18
21	164	86	*	*	14	9.6	Case series	At least 12
25	40	34	85	73–97	0	0	Case series	18
27	90	66	73	63–84	0	0	Case series	12–23

*In this trial, each patient was assigned to 1 of 3 groups: 1) those who met all selection criteria for PLDD (leg pain, positive physical examination finding such motor, sensory, or reflex deficits, and/or straight leg raise, contained disk herniation confirmed by diskography); 2) those who did not meet the selection criteria (had a normal physical examination, the presence of stenosis, spondylolisthesis, extruded disk fragment, leakage of diskographic dye from the outer annulus, multiple prior lumbar surgeries; or 3) those who could not be assigned to either of the first 2 groups for reasons such as diskography not being performed or inadequate physical examination data recorded in the chart. In group 1, 29 of 41 patients (70.7%; CI, 57%–85%) had successful outcomes. In group 2, 12 of 42 patients (29%; CI, 12%–42%) had successful outcomes. In group 3, 45 of 81 patients (56%; CI, 45%–66%) had successful outcomes. In group 4, 20 of 45 patients (44%; CI, 30%–59%) had successful outcomes.

**Fig 1.** PLDD in progress

depended solely on MR imaging, both for needle placement and for monitoring the procedure.¹⁰ The actual treatment can be conducted “blind” or by using direct monitoring of the processes that occur intradiskally. In all studies using fluoroscopy as the sole imaging technique, a predetermined amount of laser energy was delivered into the nucleus pulposus. In studies that used additional CT or MR imaging, the amount of laser energy depended on the amount of vaporization as seen on CT or MR images obtained at various points during laser application.^{8–10}

In 2 studies prophylactic antibiotics were administered intravenously during needle placement to reduce the risk of infectious diskitis.^{11,12}

Criteria for Patient Selection

The inclusion and exclusion criteria used within the different studies showed similarities. First, the presence of a radiologically confirmed herniated disk with corresponding radicular symptoms was required in all studies for a patient to qualify for inclusion.^{8–18} Patients with severe neurologic symptoms, such as cauda equina syndrome,^{14,19} severe pare-

ses,^{9,15} or other conditions that require acute surgical intervention were excluded from PLDD.

Because the treatment principle of PLDD is based on the concept of the intervertebral disk being a closed hydraulic system, only contained herniations can be expected to respond to reduction of intradiskal pressure. Therefore, only contained herniations qualify for PLDD.^{9,10,19–24} The presence of disk extrusion or sequestered herniation are considered to be exclusion criteria for PLDD.^{10,11,16,20,21,25} Although tissue heating during laser application remains mostly confined to the water-containing nucleus pulposus, precautions must be taken to prevent heat damage to the endplates of the adjacent vertebrae.²⁶ Furthermore, PLDD requires needle access to the intervertebral disk. For these reasons, patients with a narrowed intervertebral disk space or obstructive vertebral abnormalities are excluded from PLDD.^{9,14,19}

Treatment Outcome: Success Rates and Complications

Success rates in the larger studies varied from 75% (95% confidence interval [CI], 69%–81%)¹⁷ to 87% (95% CI, 80%–94%).²⁰ The definition of “successful outcome” varied strongly between the different studies, depending on the outcome measures used. The duration of follow-up ranged from 3¹⁰ to 84¹² months. Because of insufficient improvement of symptoms or recurrent herniation, 4.4%²⁰ to 25%¹⁷ of patients received additional surgical treatment. In most cases, surgery revealed the presence of free fragments in the spinal canal.

The most frequently described complication of PLDD is (spondylo-) diskitis,^{9,10,12,13,17,18} both aseptic and septic. The reported frequency of diskitis varies from 0%^{11,16,19,21} to 1.2%.⁹ Aseptic diskitis is the result of heat damage to either the disk or the adjacent vertebral endplates.²⁶ To avoid this complication, careful monitoring of patient complaints during the procedure is necessary, with adjustment of laser power, pulse rate, or pulse interval when heat sensations occur. The goal of laser disk decompression is to selectively decrease the amount

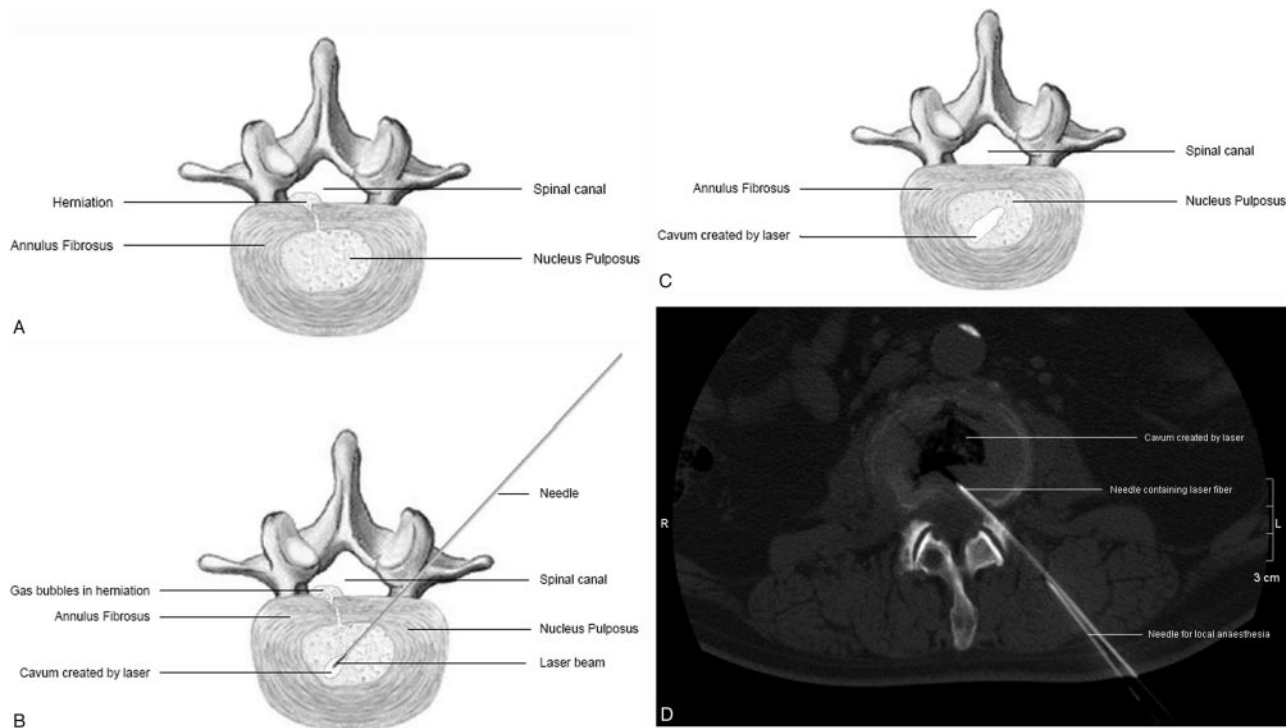


Fig 2. A, Herniated disk before PLDD
 B, Application of laser energy into the nucleus pulposus
 C, Herniated disk after PLDD
 D, CT image after PLDD, showing a gas-containing cavum in the nucleus pulposus.

Table 2: Laser types and parameters

Reference No.	Laser Type	Wavelength (nm)	Power (W)	Pulse Duration (s)	Pulse Interval (s)	Total Energy (J)
8	Diode laser	980	4	0.1–1.0	1.0	1650–2300
9	Nd:YAG	1064	15	0.5–1.0	4.0–10.0	1200–2000
10	Nd:Yag	1064	15	5.0	5.0	1250–4000
11	KTP	532	10	0.2	0.5	1260
12	Nd:YAG	1064	20	1.0	4.0–5.0	1000–1200
13	Nd:YAG	1064	20	1.0	1.0–5.0	1200–1600
14	KTP	532	12	0.2	0.5	1200–1500
15	Nd:YAG	1064	10	1.0	5.0	572–1298
16	CO ₂	10200	16	Continuous	960	16
17	Ho:YAG	2100	13	5.0	5.0	1300
18	Nd:YAG	1320	17–24	1.0	Not specified	1200–1400
19	Ho:YAG	2100	0.8 J at 8 Hz	5.0 s after each 100 J	1200–1600	19
20	Ho:YAG	2100	15	5.0	5.0	1200
21	KTP	532	Not specified	Not specified	Not specified	Not specified
25	KTP	532	10–15	0.5	0.5	Not specified
27	Ho:YAG	2100	Not specified	Not specified		Not specified
	KTP	532				
	Nd:YAG	Not specified				

of nucleus pulposus tissue, while leaving the annulus fibrosus and surrounding tissues unaffected. Therefore, the extent of heat penetration is to be kept as low as possible. The main determinants for heat penetration are water absorption, which varies with laser wavelength, and the duration of application of laser energy. For example, in case of a 980-nm diode laser, the initial power setting is 4 W,⁸ whereas the average power in trials by using a 1024 nm Neodymium-YAG laser is 17 W.^{9,10,12,13,15} In all but one¹⁶ trial laser energy was delivered in pulses, ranging from 0.1⁸ to 5.0^{10,18–20} seconds with intervals of

0.5^{11,14,25} to 10⁹ seconds. Pulsed delivery of laser energy is used to allow dissipation of heat generated by a single pulse before administration of the next pulse, thereby avoiding excessive heating of surrounding tissues. When a patient experiences heat sensations during treatment, the use of longer pulse intervals or lower power settings are effective means for decreasing heat penetration. In this fashion, an excessive build-up of heat can be countered before causing structural damage to the surrounding tissues.

Septic diskitis can occur as a result of inoculation of micro-

organisms during needle placement. To avoid this complication, severe sterility during the intervention is mandatory. The use of additional antibiotic prophylaxis may further reduce the risk of septic diskitis.^{11,12}

A special note must be made on the trial that used a CO₂ laser for PLDD.¹⁶ CO₂ laser beams cannot be administered through a glass fiber. Therefore, in the study involved, a CO₂ laser beam was delivered into the disk by means of a fixed metal cannula. Four cases of thermal nerve root damage occurred due to heating of this cannula, presenting a total complication frequency of 8%.¹⁶ In 3 patients (6%), signs of nerve root damage were transient and resolved over a period of 1–5 months. One patient (2%) suffered persistent pain without further neurologic involvement.¹⁶ The high complication rate for CO₂ lasers can be attributed to the use of these fixed cannulae, so this rate is not representative for PLDD in routine clinical practice.

Discussion

No randomized, controlled trials were available. Almost all trials were case series, with a relatively low strength of evidence. Furthermore, the sample size in most trials was relatively small, resulting in broad 95% CIs that made interpretation of success rates difficult. Generalization of the results into general practice remains difficult, because of the different inclusion and exclusion criteria, laser types, and outcome measures used and the large variation in duration of follow-up. These individual differences impair the mutual comparability of the studies and, more important, limit the possibilities for a valid comparison to studies evaluating the outcome of conventional surgical treatment for lumbar disk herniation.

Despite the fact that PLDD has been around for almost 20 years, scientific proof of its efficacy still remains relatively poor, though the potential medical and economic benefits of PLDD are too high to justify discarding it as experimental or ineffective on the sole basis of insufficient scientific proof. Well-designed research of sufficient scientific strength, comparing PLDD to both conventional surgery and conservative management of lumbar disk herniation, is needed to determine whether PLDD deserves a prominent place in the treatment arsenal for lumbar disk herniation.

References

1. Anderson GBJ. **The epidemiology of spinal disorders.** In: Frymoyer JW, ed. *The adult spine*. New York:Raven Press;1997
2. Van de Velden J, de Bakker DH. **Basisrapport: morbiditeit in de huisartsenpraktijk.** Utrecht: Nivel;1990
3. Dutch Institute for Healthcare Improvement (CBO). **Consensus Het lumbosacraal radiculair syndroom.** Utrecht:CBO;1995
4. Hoffman RM, Wheeler KJ, Deyo RA, et al. **Surgery for herniated lumbar discs: a literature synthesis.** *J Gen Int Med* 1993;8:487–96
5. Spengler DM, et al. **Lumbar discectomy: indications and technique.** In: Frymoyer JW, ed. *The adult spine*. New York:Raven Press;1997
6. Choy DSJ, Michelsen J, Getrajdman D, et al. **Percutaneous laser disc decompression: an update: spring 1992.** *J Clin Laser Med Surg* 1992;10:177–84
7. Choy DSJ. **Percutaneous laser disc decompression: a practical guide.** New York: Springer-Verlag;2003:vii
8. Gevarghez A, Groenemeyer DW, Czerwinski F, et al. **CT-guided percutaneous laser disc decompression with Ceralas D, a diode laser with 980-nm wavelength and 200-microm fiber optics.** *Eur Radiol* 2000;10:1239–41
9. Gangi A, Guth S, Dietemann J-L, et al. **Interventional radiology with laser in bone and joint.** *Radiol Clin North Am* 1998; 36:547–56
10. Steiner P, Zweifel K, Botnar R, et al. **MR guidance of laser disc decompression: preliminary in vivo experience.** *Eur Radiol* 1998; 8:592–97
11. Bossaco SJ, Bossaco DN, Berman AT, et al. **Functional results of percutaneous laser discectomy.** *Am J Orthoped* 1996;25:825–28
12. Choy DSJ. **Percutaneous laser disc decompression PLDD: twelve years' experience with 752 procedures in 518 patients.** *J Clin Laser Med Surg* 1998;16: 325–31
13. Schatz SW, Talla A **Preliminary experience with percutaneous laser disc decompression in the treatment of sciatica.** *Can J Surg* 1995;38:432–36
14. Liebler WA. **Percutaneous laser disc nucleotomy.** *Clin Orthop* 1995;310:58–66
15. Simons P, Lensker E, von Wild K. **Percutaneous nucleus pulposus denaturation in treatment of lumbar disc protrusions: a prospective study of 50 neurosurgical patients.** *Eur Spine J* 1994;3:219–21
16. Nerubay J, Caspi I, Levinkopf M. **Percutaneous carbon dioxide laser nucleolysis with 2- to 5-year follow-up.** *Clin Orthop* 1997;337:45–48
17. Ascher PW. **Laser trends in minimally invasive treatment: atherosclerosis, disk herniations.** *J Clin Laser Med Surg* 1991;9:49–57
18. Siebert W. **Percutaneous laser disk decompression: experience since 1989.** *Orthopade* 1996;25:42–48
19. Agarwal S. **Ho:YAG laser-assisted lumbar disc decompression: a minimally invasive procedure under local anesthesia.** *Neurol India* 2003;51:35–38
20. Casper GD, Hartman VL, Mullins LL. **Results of a clinical trial of the holmium: YAG laser in disc decompression utilizing a side-firing fiber: a two-year follow-up.** *Lasers Surg Med* 1996;19:90–96
21. Ohnmeiss DD, Guyer RD, Hochschuler SH. **Laser disc decompression: the importance of proper patient selection.** *Spine* 1994;19:2054–58
22. Choy, D.S.J. **Percutaneous Disc Decompression; A New Therapeutic Modality.** *Spine Vol 17*, 1992, pp. 949–56
23. Choy DSJ. **Rapid correction of neurologic deficits by percutaneous laser disc decompression.** *J Clin Laser Med Surg* 1996;14:13–15
24. Gangi A, Dietemann JL, Mortazavi R, et al. **CT-guided interventional procedures for pain management in the lumbosacral spine.** *Radiographics* 1998;18: 621–33
25. Davis JK. **Early experience with laser disc decompression: a percutaneous method.** *J Florida Med Assoc* 1992;79:39
26. Turgut M. **Extensive damage to the end-plates as a complication of laser discectomy: an experimental study using an animal model.** *Acta Neurochir Wien* 1997;139:404–10
27. Botsford JA. **Radiological considerations: patient selection for percutaneous laser disc decompression.** *J Clin Laser Med Surg* 1994;12:255–59