

# Generic Contrast Agents

Our portfolio is growing to serve you better. Now you have a *choice*.



[VIEW CATALOG](#)

# AJNR

## **Controversies: Is There a Role for Positron-Emission Tomographic CT in the Initial Staging of Head and Neck Squamous Cell Carcinoma?**

Suresh K. Mukherji and Carol R. Bradford

This information is current as of May 24, 2025.

*AJNR Am J Neuroradiol* 2006, 27 (2) 243-245  
<http://www.ajnr.org/content/27/2/243>

justified on the basis of a long life expectancy and projected additive yearly risks of hemorrhage. The efficacy of clipping was said to be self-evident, whereas a trial designed to show benefits seemed incompatible with the timeframe of a feasible trial.<sup>4</sup> A treatment does not have to be 100% effective to be beneficial however. Endovascular treatment may prove beneficial—or not—within an observation period that is reasonable for a trial. The main goal here is not to compare the efficacy of coiling and clipping, as defined by angiography, but rather to assess whether treatment offers prevention at a reasonable cost in terms of morbidity. Elsewhere we proposed a randomized trial comparing the mortality and morbidity of patients with unruptured aneurysms treated by endovascular coiling or by conservative management.<sup>15-16</sup> We estimate that recruitment of a population of 2000 patients during a 3-year period in 60 centers, followed for 5–10 years, can provide answers to 2 important questions: Is endovascular treatment effective in the prevention of intracranial hemorrhage? Is the clinical outcome improved as compared with deferred treatment? Randomization will also offer more accurate estimates of the natural history and a more realistic portrait of iatrogenia than current observational and single-center experiences.

A randomized trial can reconcile the introduction of a “new” treatment with the necessity to acknowledge uncertainties, assess potential benefits scientifically, and assist individuals, alerted by our technical advances of an ominous condition, in a controlled environment that respects and promotes their autonomy.

## References

1. Weir B. **Unruptured Intracranial Aneurysms: A Review.** *J Neurosurg* 2002;96:3–42
2. Tubiana M. *Histoire de la pensée médicale; les chemins d'Esculape.* Collection Champs 384. Paris: Flammarion;1995
3. Cadore B. L'éthique clinique comme philosophie contextuelle. *Fidès Montreal*; 1997
4. Wiebers DO, Whisnant JP, Huston J, et al. **Unruptured intracranial aneurysms: natural history, clinical outcome, and risks of surgical and endovascular treatment.** *Lancet* 2003;362:103–10
5. Cleophas GC, Cleophas TJ. **Clinical trials in jeopardy.** *Int J Clin Pharmacol Ther* 2003;41:51–55
6. EC/IC Bypass Study Group. **Failure of extracranial-intracranial arterial bypass to reduce the risk of ischemic stroke: results of an international randomized trial: the EC/IC bypass study group.** *N Engl J Med* 1985;313:1191–200
7. Barnett HJM, Taylor DW, Eliasziw M, et al. **The North American Symptomatic Carotid Endarterectomy Trial Collaborators: benefit of carotid endarterectomy in patients with symptomatic moderate or severe stenosis.** *N Engl J Med* 1998;339:1415–25
8. Molyneux A, Kerr R, Stratton I, et al. **International subarachnoid aneurysm trial (ISAT) of neurosurgical clipping versus endovascular coiling in 2143 patients with ruptured intracranial aneurysms: a randomised trial.** *Lancet* 2002;360:1267–74
9. Johnston SC, Wilson CB, Halbach VV, et al. **Endovascular and surgical treatment of unruptured cerebral aneurysms: comparison of risks.** *Ann Neurol* 2000;48:11–19
10. Johnston SC, Dudley RA, Gress DR, et al. **Surgical and endovascular treatment of unruptured cerebral aneurysms at university hospitals.** *Neurology* 1999;52:1799–805
11. Johnston SC, Zhao S, Dudley RA, et al. **Unruptured aneurysm treatment in California: surgery and endovascular therapy.** *J Neurosurg* 2001;94:188A
12. Johnston SC, Zhao S, Dudley RA, et al. **Treatment of unruptured cerebral aneurysms in California.** *Stroke* 2001;32:597–605
13. Raymond J, Guilbert F, Georganos SA, et al. **Long-term angiographic recurrences after selective endovascular treatment of aneurysms with detachable coils.** *Stroke* 2003;34:421–27
14. Bederson JB, Awad IA, Wiebers DO, et al. **Recommendations for the management of patients with unruptured intracranial aneurysms: a statement for healthcare professionals from the Stroke Council of the American Heart Association.** *Stroke* 2000;31:2742–50
15. Raymond J, Chagnon M, Collet JP, et al. **A randomized trial on safety and**

**efficacy of endovascular treatment of unruptured intracranial aneurysms is feasible.** *Intervent Neuroradiol* 2004;10:103–12

16. Roy D, Milot G, Raymond J. **Endovascular treatment of unruptured aneurysms.** *Stroke* 2001;32:1998–2004

Jean Raymond, MD, Francois Guilbert, MD, Alain Weill, MD, and Daniel Roy, MD

## COMMENTARY

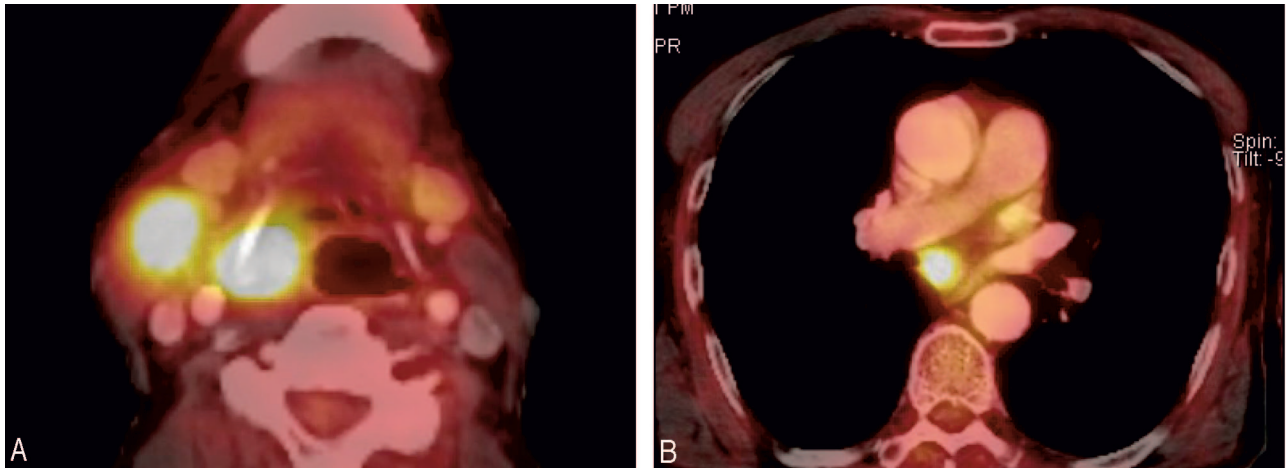
### Controversies: Is There a Role for Positron-Emission Tomographic CT in the Initial Staging of Head and Neck Squamous Cell Carcinoma?

**P**ositron-emission tomographic CT (PET-CT) is gaining greater acceptance in a wide variety of oncologic indications in numerous organ systems (head and neck, central nervous system, breast, gynecologic, pulmonary, lymphoma). The dual-technique capability of PET-CT, which permits direct image fusion and improves the ability to anatomically localize foci of fluorodeoxyglucose (FDG) uptake, is replacing stand-alone PET systems. There are numerous potential clinical applications for PET-CT to evaluate malignancies of the head and neck, specifically squamous cell carcinoma (HNSCCA). Potential clinical applications include pretreatment staging, treatment monitoring and evaluation of the previously treated patients.

The current literature suggests that most primary site HNSCCA with volumes >1 mL will be FDG avid. These correspond to lesions that are moderately sized T1 or greater. Tumors with volumes <1 mL may be detected with FDG, however, the sensitivity decreases with decreasing size. PET also has the ability to detect metastatic cervical lymph nodes, which may be both clinically occult and not detected by CT or MR. In light of these potential benefits, there is debate as to how to use PET-CT for the initial staging of HNSCCA. The current consensus does not support the use of CT-PET for routine staging of all newly diagnosed squamous cell carcinomas. The intent of this manuscript is to propose potential indications for performing PET-CT for initial staging of HNSCCA before treatment.

One potential application is to perform PET-CT in advanced stage HNSCCA to evaluate for occult distant metastases to the lungs or bones. The presence of pulmonary metastases upstages a patient from M0 to M1 and alters treatment intent (Fig 1). The likelihood of pulmonary metastases is low in patients with early-stage disease and the routine imaging work-up for pulmonary metastases is conventional radiography of the chest at most institutions. An argument can be made to perform chest CT in all patients with advanced stage disease; however, if a solitary nodule is identified, it is often unclear whether this is metastasis or a granuloma. PET may help in this evaluation as a FDG-positive nodule will likely require biopsy, whereas an FDG-negative nodule (>8 mm) likely indicates a granuloma, and a biopsy may be avoided.

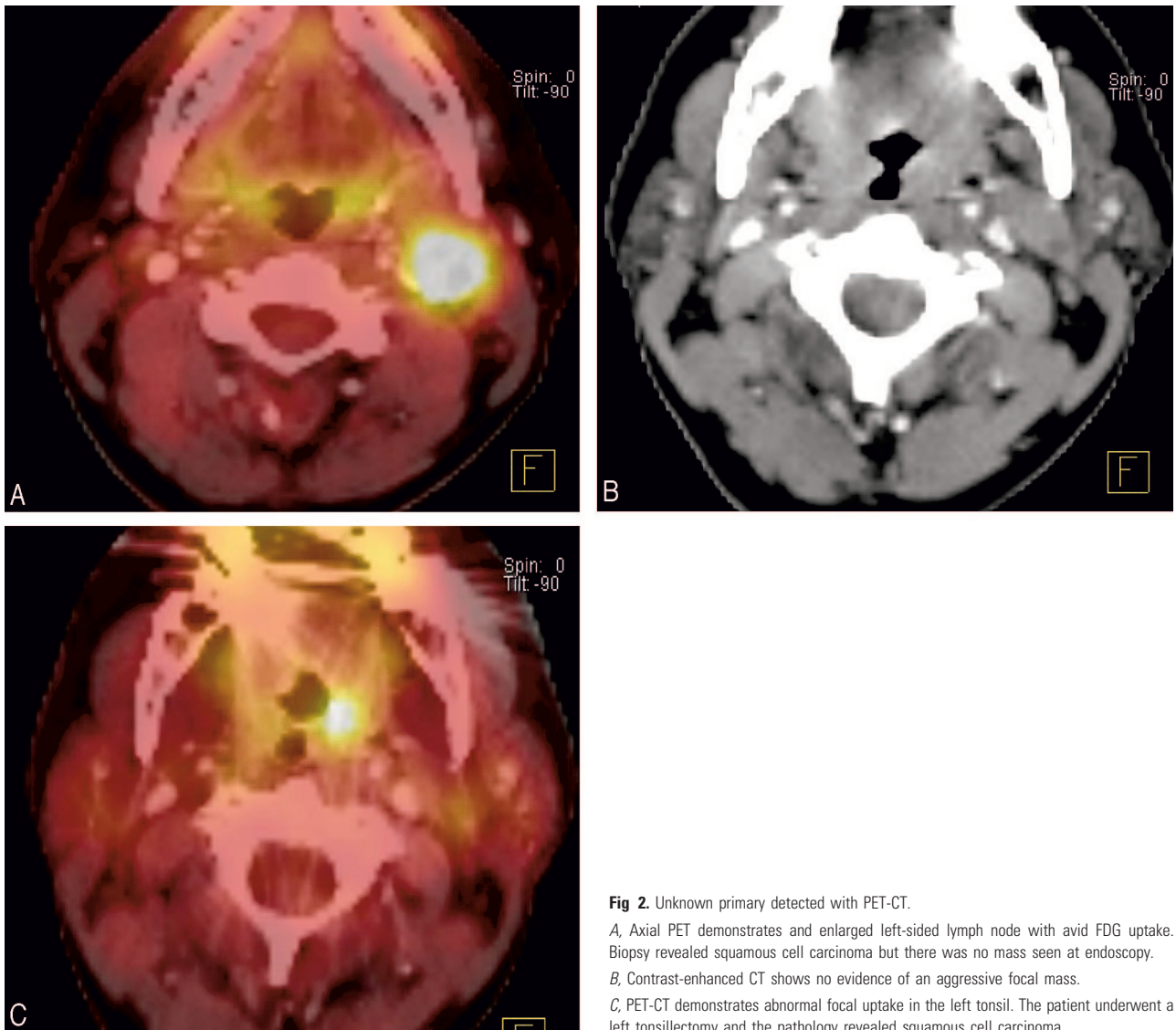
Various studies have been performed to evaluate the diagnostic accuracy of PET-FDG for detecting metastatic cervical lymph nodes. The consensus of the current literature suggests that sensitivity ranges of 70%–90%, whereas the specificity is



**Fig 1.** T3N2 pyriform sinus carcinoma.

*A*, Axial PET-CT demonstrates avid FDG uptake in a right pyriform sinus carcinoma and a metastatic right cervical lymph node.

*B*, PET-CT of the chest shows a mediastinal mass with focal increased uptake. This was not detected on conventional radiography of the chest.



**Fig 2.** Unknown primary detected with PET-CT.

*A*, Axial PET demonstrates and enlarged left-sided lymph node with avid FDG uptake. Biopsy revealed squamous cell carcinoma but there was no mass seen at endoscopy.

*B*, Contrast-enhanced CT shows no evidence of an aggressive focal mass.

*C*, PET-CT demonstrates abnormal focal uptake in the left tonsil. The patient underwent a left tonsillectomy and the pathology revealed squamous cell carcinoma.



slightly higher (80%–95%). The negative predictive value (NPV) is approximately 90%. This is because >40% of metastatic lymph nodes are <7 mm in diameter. As a result, PET-CT has not gained widespread acceptance to be used to exclude the presence of metastases in the clinically N0 neck. In fact, there is currently no imaging study that has a negative predictive value that has been shown to be consistently >95%. It is conceivable that future advances in CT detector technology in PET-CT units will permit diagnostic CT (<2.5 mm and gantry angulation) to be performed. If so, PET-CT may have greater impact on management of the N0 neck as the NPV of this technique will increase if both studies (PET and CT) are of diagnostic quality and both yield normal results.

Numerous investigators have documented the ability of PET-CT to detect unknown primary tumors of the upper aerodigestive tract. The current literature suggests that PET can detect HNSCCA in 30%–50% of patients presenting with an unknown primary tumor (Fig 2). At most institutions, PET-CT is performed after confirming the presence of metastatic HNSCCA and following a negative endoscopy. PET is usually performed before endoscopic biopsies to help improve the yield of the speculative tissue sampling. The diagnostic yield will likely increase with PET-CT because this technique improves accurate anatomic localization of areas of abnormal FDG uptake.

An area of potential utilization of PET-CT currently under investigation is in determining response to nonsurgical treatment modalities, either chemotherapy and/or radiation. Comparison of pretreatment standard uptake values to SUVs 2 weeks into treatment can allow measurement of the speed of response and the sensitivity of the tumor to the treatment technique. Poorly responsive tumors can then be treated to higher effective tumor doses of radiation, for example, or surgery can be performed. Furthermore, initial results suggest that PET-CT can be used to assist in defining primary site and nodal tumor targets for intensity-modulated radiation therapy approaches.

There are numerous professional and financial issues surrounding PET-CT that will require further discussion. Important topics that will need to be addressed include

1. Who should interpret PET-CT? Should these be interpreted by a nuclear medicine physician (PET-CT), the subspecialist who would usually interpret the CT (CT-PET), or some form of joint interpretation?

2. Should intravenous contrast routinely be given for the CT portion of the CT-PET?

3. How should the CT component of the PET be interpreted? Will this only be used as an “anatomic localizer,” or will all PET-CT studies need to be interpreted for unsuspected findings, which would be akin to “screening CT”?

4. How will we bill for PET-CT? The CT technology of earlier versions of CT-PET consisted of 2 or 4 detector rows, which were unable to obtain images to obtain thin sections (<5 mm). Newer versions of PET-CT now integrate state-of-the-art CT 16- and 64-row detector configurations, so it is possible that the PET-CT will provide diagnostic quality CT studies. Will we have one code for a combined PET-CT study; will we bill for a PET study with a modifier for the CT component, or will we independently bill for both the CT and PET components? How will this affect states that have certificate of

need requirements that regulate the number of CT scanners that an institution may have at any one time?

At our institution, we are now routinely administering intravenous contrast for all PET-CT performed of the extracranial head and neck. The studies are jointly interpreted by faculty members of the divisions of neuroradiology and nuclear medicine. It is our belief that PET-CT is a useful adjunct to initial clinical staging of HNSCCA for specific indications and utilization of pretreatment PET-CT will continue to increase with advances in PET-CT technology.

Suresh K. Mukherji and Carol R. Bradford

## References

1. Bruschini P, Giorgetti A, Bruschini L, et al. **Positron emission tomography (PET) in the staging of head neck cancer: comparison between PET and CT.** *Acta Otorhinolaryngol Ital* 2003;23:446–53
2. McQuirt WF, Greven K, Williams D 3rd, Keyes JW Jr, et al. **PET scanning in head and neck oncology: a review.** *Head Neck* 1998;20:208–15
3. Di Martino E, Nowak B, Hassan HA, et al. **Diagnosis and staging of head and neck cancer: a comparison of modern imaging modalities (positron emission tomography, computed tomography, color-coded duplex sonography) with panendoscopic and histopathologic findings.** *Arch Otolaryngol Head Neck Surg* 2000;126:1457–61
4. Benchaou M, Lehmann W, Slosman DO, et al. **The role of FDG-PET in the preoperative assessment of N-staging in head and neck cancer.** *Acta Otolaryngol* 1996;116:332–35
5. Hubner KF, Thie JA, Smith GT, et al. **Clinical utility of FDG-PET in detecting head and neck tumors: a comparison of diagnostic methods and modalities.** *Clin Positron Imaging* 2000;3:7–16
6. Dammann F, Horger M, Mueller-Berg M, et al. **Rational diagnosis of squamous cell carcinoma of the head and neck region: comparative evaluation of CT, MRI, and 18FDG PET.** *AJR Am J Roentgenol* 2005;184:1326–31
7. Halfpenny W, Hain SF, Biassoni L, et al. **FDG-PET: a possible prognostic factor in head and neck cancer.** *Br J Cancer* 2002;86:512–16
8. Haberkorn U, Strauss LG, Dimitrakopoulou A, et al. **Fluorodeoxyglucose imaging of advanced head and neck cancer after chemotherapy.** *J Nucl Med* 1993;34:12–17
9. Mukherji SK, Drane WE, Mancuso AA, et al. **Occult primary tumors of the head and neck: detection with 2-[F-18] fluoro-2-deoxy-D-glucose SPECT.** *Radiology* 1996;199:761–66
10. Bruschini P, Giorgetti A, Bruschini L, et al. **Positron emission tomography (PET) in the staging of head neck cancer: comparison between PET and CT.** *Acta Otorhinolaryngol Ital* 2003;23:446–53
11. Wong WL, Chevetton EB, McGurk M, et al. **A prospective study of PET-FDG imaging for the assessment of head and neck squamous cell carcinoma.** *Clin Otolaryngol Allied Sci* 1997;22:209–14
12. Lowe VJ, Dunphy FR, Varvares M, et al. **Evaluation of chemotherapy response in patients with advanced head and neck cancer using [F-18]fluorodeoxyglucose positron emission tomography.** *Head Neck* 1997;19:666–74
13. Delgado-Bolton RC, Fernandez-Perez C, Gonzalez-Mate A, et al. **Meta-analysis of the performance of 18F-FDG PET in primary tumor detection in unknown primary tumors.** *J Nucl Med* 2003;44:1301–14
14. Sheikholeslam-Zadeh R, Choufani G, Goldman S, et al. **Unknown primary detected by FDG-PET: a review of the present indications of FDG-PET in head and neck cancers.** *Acta Otorhinolaryngol Belg* 2002;56:77–82
15. Paulino AC, Koshy M, Howell R, et al. **Comparison of CT- and FDG-PET-defined gross tumor volume in intensity-modulated radiotherapy for head-and-neck cancer.** *Int J Radiat Oncol Biol Phys* 2005;61:1385–92
16. Schwartz DL, Rajendran J, Yueh B, et al. **FDG-PET prediction of head and neck squamous cell cancer outcomes.** *Arch Otolaryngol Head Neck Surg* 2004;130:1361–67
17. Yao M, Buatti JM, Dornfeld KJ, et al. **Can post-RT FDG PET accurately predict the pathologic status in neck dissection after radiation for locally advanced head and neck cancer? In regard to Rogers, et al.** *Int J Radiat Oncol Biol Phys* 2004;58:694–97; *Int J Radiat Oncol Biol Phys* 2005;61:306–307; author reply 307
18. Koshy M, Paulino AC, Howell R, et al. **F-18 FDG PET-CT fusion in radiotherapy treatment planning for head and neck cancer.** *Head Neck* 2005;27:494–502
19. Nishiyama Y, Yamamoto Y, Yokoe K, et al. **FDG PET as a procedure for detecting simultaneous tumours in head and neck cancer patients.** *Nucl Med Commun* 2005;26:239–44
20. Branstetter BF 4th, Blodgett TM, Zimmer LA, et al. **Head and neck malignancy: is PET/CT more accurate than PET or CT alone?** *Radiology* 2005;235:580–86
21. Gutzeit A, Antoch G, Kuhl H, et al. **Unknown primary tumors: detection with dual-modality PET/CT: initial experience.** *Radiology* 2005;234:227–34