

Generic Contrast Agents

Our portfolio is growing to serve you better. Now you have a *choice*.



[VIEW CATALOG](#)

AJNR

Cervical Vertebral Artery Variations: An Anatomic Study

S.R. Satti, C.A. Cerniglia and R.A. Koenigsberg

AJNR Am J Neuroradiol 2007, 28 (5) 976-980

<http://www.ajnr.org/content/28/5/976>

This information is current as
of May 23, 2025.

CASE REPORT

S.R. Satti
C.A. Cerniglia
R.A. Koenigsberg

Cervical Vertebral Artery Variations: An Anatomic Study

SUMMARY: In this article, we present 5 cases of uncommon anomalous vertebral arteries and discuss the possible embryologic etiologies. These cases include a left vertebral artery as the 2nd branch off the left subclavian, a left vertebral artery with 2 origins, a right vertebral artery arising as the last branch off the aorta, a right vertebral artery arising as the 2nd branch off the right subclavian artery, and right vertebral artery with proximal duplication as the 2nd branch off the right subclavian artery.

Understanding the great vessels of the aortic arch and their variations is important for both the endovascular interventionist and the diagnostic radiologist. This has become more important in the era of carotid artery stents, vertebral artery stents, and new therapeutic options for intercranial interventions.¹

Case Reports

Case 1

A 50-year-old man presented with a history of right-sided numbness. MR imaging of the brain revealed a small acute infarction in the left centrum semiovale. Cerebral angiography showed no significant carotid disease. The left vertebral artery originated as the 2nd branch of the left subclavian artery just distal to the thyrocervical trunk (Figs 1 and 2). The patient was managed conservatively without intervention.

Case 2

A 62-year-old man presented with presyncope. The patient had normal findings on CT of the head. A 4-vessel angiogram was obtained, and the arch arteriography demonstrated a bovine arch or shared left common carotid and innominate origins. Selective catheterization of the right common carotid artery demonstrated a fetal origin of the right posterior cerebral artery. The left common carotid artery was selected, and angiography of the cervical and intracranial components demonstrated no abnormalities. Selective left vertebral angiography demonstrated the left vertebral artery arising as the 3rd branch of the aortic arch with an associated duplication. Selective left vertebral artery injection demonstrated antegrade flow within the proximal left vertebral artery below C7, with retrograde flow into a hypoplastic duplicated limb (Fig 3). This secondary limb angiographically extended from the left subclavian artery to the C7 level, where the 2 limbs coalesced into a single vertebral artery (Fig 4). The right vertebral artery was angiographically normal.

Case 3

A 56-year-old man presented to the emergency department with right-sided weakness. CT confirmed a left cerebellar infarct; however, MR angiography (MRA) was contraindicated secondary to a pacemaker device, and the patient was sent for angiography. A 4-vessel angiography was performed, and an arch arteriogram demonstrated a patent innominate artery, left common carotid artery, and left sub-

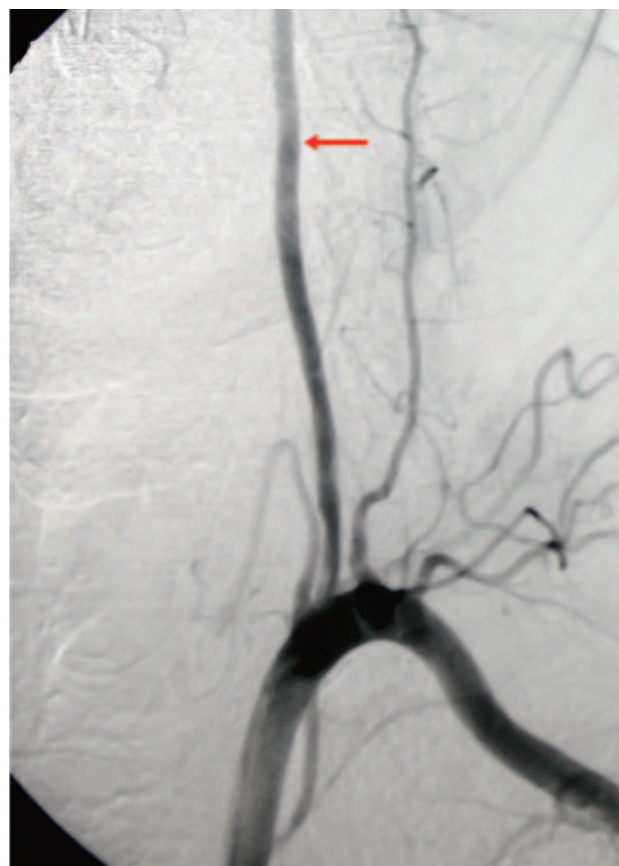


Fig 1. Digital subtraction angiography. There is opacification of the left vertebral artery (LV) as the 2nd branch off the left subclavian artery (LS, arrow). The 1st branch of the left subclavian artery is the thyroid, and the 3rd branch is the cervical artery (CA).

clavian artery. Selective arteriography was performed and demonstrated normal right and left carotid arteries. Intercranial angiography confirmed normal middle and anterior cerebral arteries, but the posterior communicating arteries were not patent. The right vertebral artery was not identified in its normal position. Selective catheterization of the left subclavian artery demonstrated an abrupt cutoff of the left vertebral artery just distal to the origin.

Repeat arch angiography demonstrated a patent but anomalous origin of the right vertebral artery (Fig 5). Cases of anomalous origins of the right vertebral artery as the last branch of the aortic arch, distal to the left subclavian artery, have been described several times in the literature.²

The artery arose as the last branch of the aortic arch and served as the only blood supply to the posterior circulation. (Fig 6). Selective arteriography demonstrated antegrade flow to both posterior communicating arteries via the basilar artery. There was minimal retro-

Received March 3, 2005; accepted after revision August 8, 2006.

From the Department of Diagnostic Radiology (S.R.S., R.A.K.), Hahnemann University Hospital, Drexel University College of Medicine, Philadelphia, Pa; and the Department of Imaging Sciences (C.A.C.), University of Rochester Medical Center, University of Rochester School of Medicine and Dentistry, Rochester, NY.

Please address correspondence to Sudhakar Satti, MD, Department of Diagnostic Radiology, Hahnemann University Hospital, Drexel University, M.S. 206, Philadelphia, PA 19102; e-mail: srsatti@gmail.com

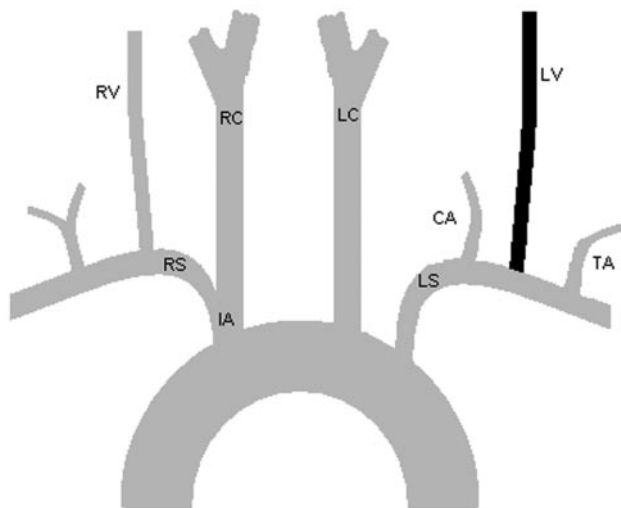


Fig 2. LV as the 2nd branch off the LS between the TA (thyroid artery) and the CA. RV indicates the right vertebral artery; RS, right subclavian artery; IA, innominate artery; RC, right common carotid artery; LC, left common carotid artery; TA, inferior thyroid artery.

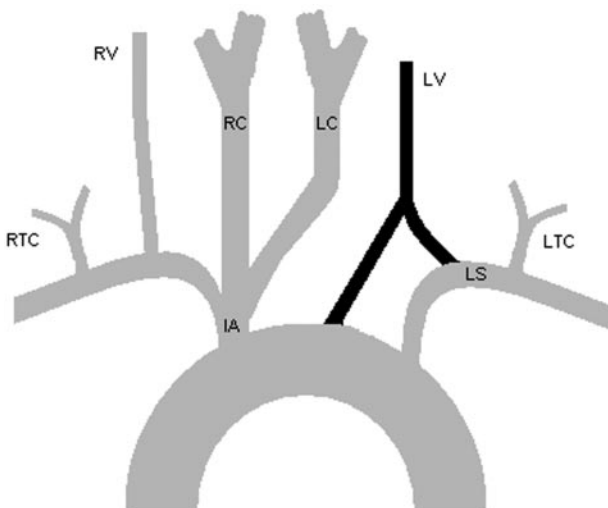


Fig 4. LV has 2 origins. The 1st originates as the 3rd branch of the aortic arch, and the 2nd, as the 1st branch of the LS. There is an incidentally noted bovine arch. RTC indicates right thyrocervical trunk; LTC, left thyrocervical trunk.

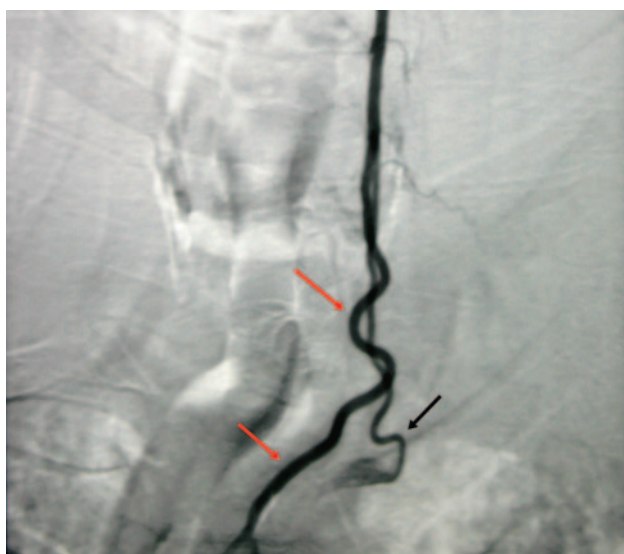


Fig 3. Digital subtraction angiography. There is opacification of the LV as the 3rd branch off the aortic arch (red arrows) with retrograde flow into a hypoplastic duplicated limb (black arrow), which arose as the 2nd branch of the LS.

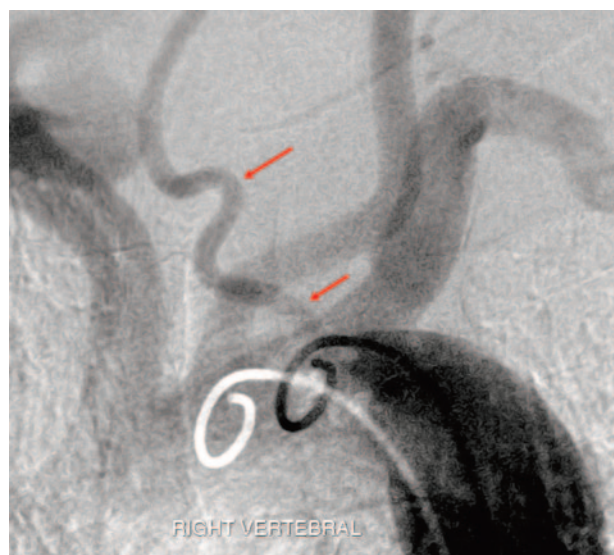


Fig 5. Digital subtraction angiography. Aortogram with the pigtail catheter placed in the proximal descending aorta demonstrates filling of right vertebral artery (red arrows) as the last great vessel off of the arch. The right vertebral artery crosses the midline and extends cranially along the right lateral aspect of the neck.

grade flow through the distal left vertebral artery with opacification of the left posterior inferior cerebellar artery.

Case 4

A 47-year-old woman presented to the emergency department with sudden onset of a severe persistent headache. Emergency department and neurology evaluation lead to a CT of the head, which identified a subarachnoid hemorrhage. The patient was referred to interventional neuroradiology for angiographic evaluation. The arch arteriogram demonstrated a right vertebral artery as the 2nd branch of the right subclavian artery (Figs 7 and 8). The first branch of the subclavian artery was the thyroidea ima.³

Case 5

A 53-year-old woman presented for headache evaluation. Her family history was remarkable for a daughter with a left parietal hemorrhage secondary to a ruptured arteriovenous malformation. MR imaging eval-

uation suggested the presence of a vascular mass at the right skull base. Diagnostic angiography confirmed the presence of a right cavernous carotid aneurysm and an unexpected contralateral cavernous carotid aneurysm. Right vertebral angiography demonstrated duplication of the right vertebral artery from its origin to the C3 level (Fig 9). The diameter of the duplicated portion of the vertebral artery was approximately 50% of the origin. The duplication reconstituted at the C3 level. The left vertebral artery was angiographically normal (Fig 10).

Discussion

A thorough understanding of anomalous vertebral arteries is paramount when performing both diagnostic and interventional angiography. Contrast-enhanced MRA is becoming increasingly common; and with improved resolution, identifying pathology including ostial lesions of the great vessels and vertebral arteries will become more frequent.

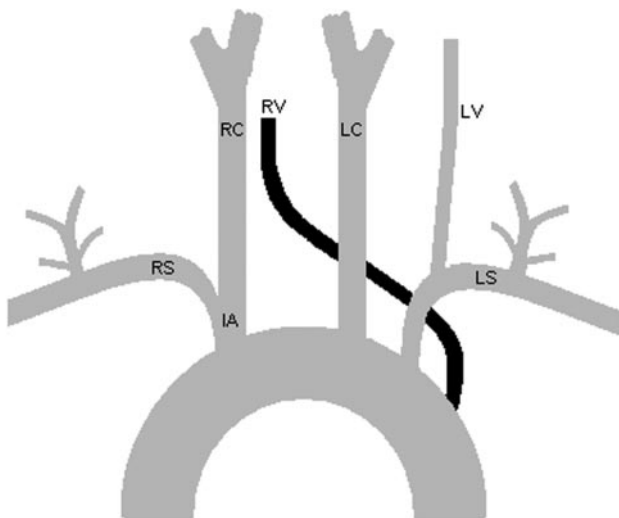


Fig 6. RV arises as the last branch off of the aorta. RS indicates right subclavian artery; RC, right common carotid artery.

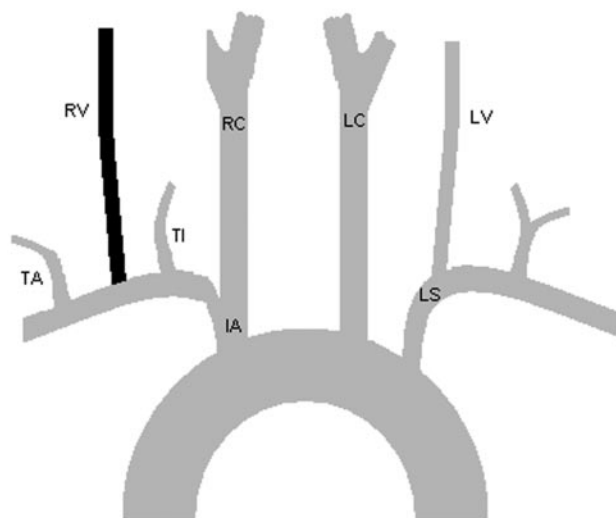


Fig 8. RV is the 2nd branch off the RS between the TI and the TA.

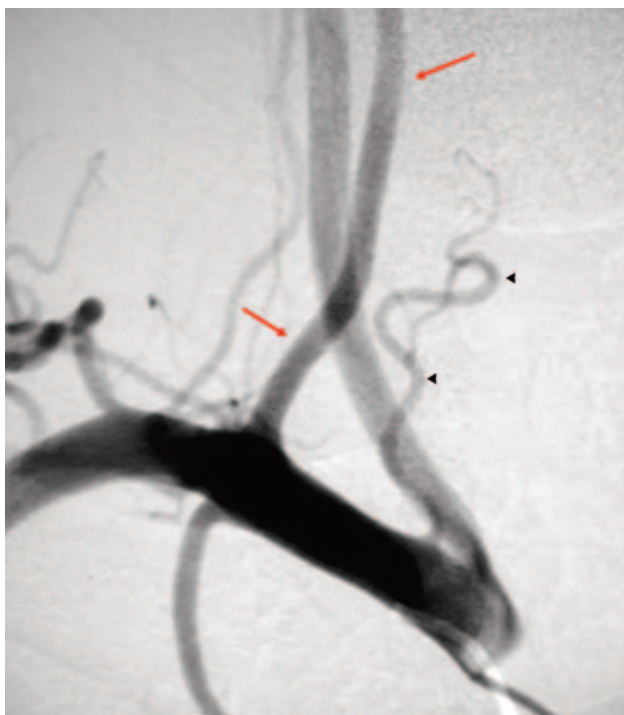


Fig 7. Digital subtraction angiography. There is opacification of the RV (red arrows) as the 2nd branch off the RS. The 1st branch of the RS is the thyroidea ima artery (TI) (black arrowheads), and the 3rd branch is the TA.

Without a thorough understanding of anomalous origins of the great vessels, angiography can be difficult or impossible. If the vertebral arteries are not identified in their normal position, this finding can be misinterpreted as the vessels being congenitally absent. This information is important for vascular or cardiothoracic surgical planning.⁴ Anomalous origins may lead to altered hemodynamics and predispose the patient to intercranial aneurysm formation. Therefore in patients with these anomalies, a thorough search for coexisting aneurysms should be undertaken. Endovascular therapy of intercranial aneurysms can be performed before they present clinically as subarachnoid hemorrhages or by mass effect and, thereby, decrease morbidity and mortality.

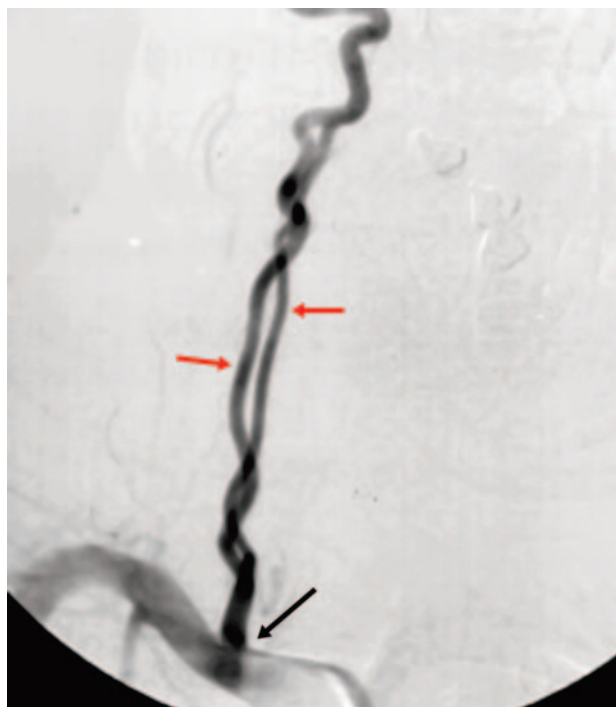


Fig 9. Digital subtraction angiography. There is opacification of a duplicated RV (red arrows). The origin (black arrow) is at the normal position as the 2nd branch of the RS.

To understand anomalies of the great vessels and their branches, one must first understand embryologic development of the aortic arch. The primitive anterior ventral aorta persists bilaterally. The right forms the innominate artery and the right common and right external carotid arteries. The left gives rise to a short portion of the aortic arch, the left common carotid arteries and left external carotid arteries (Figs 11 and 12).

The embryo develops 6 sets of matched aortic arches.⁵ These arches undergo selective apoptosis, and the residual branch vessels constitute the aortic arch and great vessels. During this process, anatomic variants can form. The 1st and 2nd aortic arches (I and II) regress. The paired 3rd arches (III) form the 1st part of the internal carotid arteries bilaterally. The proximal right 4th arch (IV) persists as the right subclavian artery to the origin of the

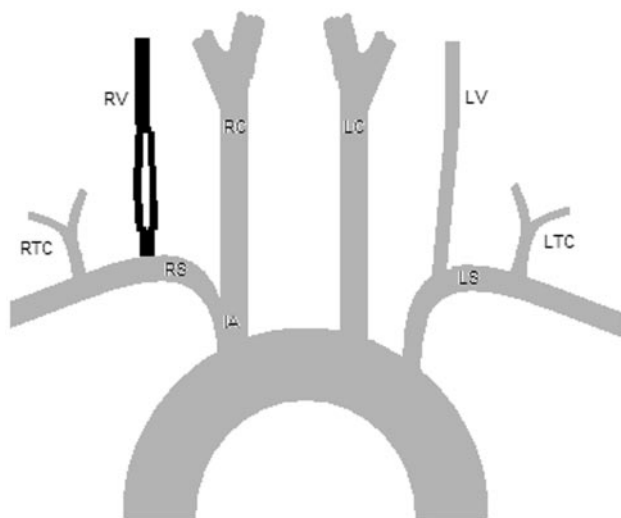


Fig 10. The RV is partially duplicated with a common origin as the 2nd branch off the RS. LTC indicates left thyrocervical trunk.

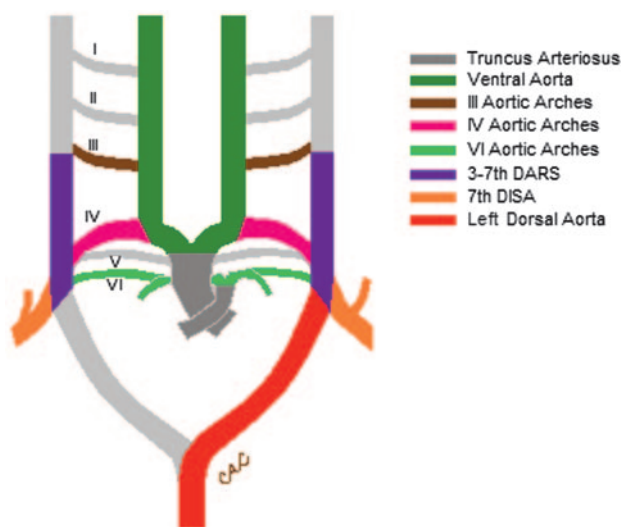


Fig 11. Normal schematic diagram of the primitive ventral and dorsal aorta, 6 aortic arches, dorsal aortic root segments (DARS), and 7th dorsal intersegmental artery (DISA).

internal mammary artery, whereas the distal right 4th arch regresses. The left 4th arch (IV) regresses and forms a small segment of the adult arch between the origin of the left common carotid artery and the left subclavian arteries. The 5th arch (V) either regresses or is incompletely formed. The 6th arch (VI) forms the pulmonary arch, which develops into the right pulmonary artery and ductus arteriosus.¹

Small intersegmental branches of the dorsal aorta extend from the cervical to the sacral region to vascularize the developing somites. In the cervical region, these intersegmental branches form the vertebral artery as the postcostal longitudinal anastomosis between the C1 and C7 intercostal arteries and the cervical intercostals obliteration zone. The vertebral artery typically originates from the distal end of the 7th dorsal intersegmental artery bilaterally. Segmental arteries arise from the primitive dorsal aorta and course between successive segments. The 7th segmental artery forms the lower end of the vertebral artery and, when the forelimb bud appears, sends a branch to it, forming the subclavian artery. The left 7th dorsal intersegmental artery persists to

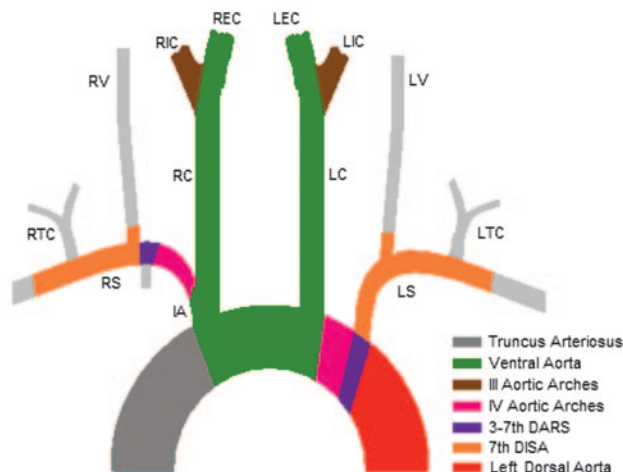


Fig 12. Normal schematic diagram of the aortic arch and the great vessels demonstrates the embryologic origins of the arch and its major branches. RIC indicates right internal carotid artery; REC, right external carotid artery; LIC, left internal carotid; LEC, left external carotid artery.

form the entire proximal left subclavian artery to the level of the internal thoracic artery, whereas on the right, the 7th dorsal intersegmental artery forms the distal one third of the proximal right subclavian artery. The proximal and mid zones of the proximal right subclavian artery are formed by the right 4th aortic arch and the right dorsal aortic root segments 3–7 respectively. Incidentally, the left dorsal aortic root segments 3–7 form a small segment of the aorta at the origin of the left subclavian artery. The right vertebral artery typically arises from the distal aspect of the right 7th dorsal intersegmental artery. Anomalous origins arise from aberrant anastomosis at any time during the embryonic development of the arch. The time and location of this anastomosis will determine the ultimate adult anomalous origin.

Cases 1 and 2 describe the variable origin of the left vertebral artery. The left vertebral artery normally arises as the 1st superior posterior branch of the left subclavian artery. Other anomalous origins of the left vertebral artery that have been described include the left vertebral artery arising directly from the arch (most common), the left vertebral artery arising as the 1st branch of the subclavian artery near its origin at the arch, and the left vertebral artery sharing a common origin with the thyrocervical trunk.⁶ These origins arise from persistence of dorsal intersegmental arteries more cranial than the 7th, which is the typical site of anastomosis. Persistence of the 1st or 2nd dorsal intersegmental artery to the 4th left aortic arch presumably could yield the left vertebral artery from the aortic arch, proximal to the left subclavian origin. This is the most common anomalous origin.

In case 1, the left vertebral artery originates as the 2nd branch off the left subclavian artery. If the interconnection persists from the aortic arch to a left intersegmental artery, this left vertebral artery may have this anomalous configuration. The 2nd case illustrates a patient in whom there is duplication of left vertebral artery origin. One of the left vertebral arteries originated from aortic arch as the 3rd branch, whereas the 2nd arises in the normal position as the 1st branch off the left subclavian artery. A dissociation of additional cervical intersegmental branches from the dorsal aorta is a likely etiology for this congenital anomaly. Following this dissociation, small vascular branches anastomose to form a common vertebral artery distally. There is only a single

case report in the literature that describes a duplicated left vertebral artery with this configuration. In case 2, the limb that arises from the left subclavian artery is hypoplastic.^{7,8}

The 3rd, 4th, and 5th cases describe variable origins of the right vertebral artery. The right vertebral artery normally arises as the 1st superior posterior branch of the right subclavian artery. In the 3rd case, the right vertebral artery originates as the last branch off the aorta. In this instance, the right vertebral artery arises from the aortic arch distal to the origin of the left subclavian artery and passes superiorly and to the right, crossing the midline, posterior to the trachea and esophagus. This variation may be explained by the persistence of the right dorsal aorta and the obliteration of the right 4th arch. If the postcostal longitudinal anastomosis persists with the development of the cervical spine, the origin of the left vertebral artery may arise distal to the left subclavian artery, which has been described numerous times in the literature. Presumably, the 8th or 9th intersegmental artery must persist in this variation.

In the 4th case, the right vertebral artery originates as the 2nd branch off the right subclavian artery between the thyroidea ima and the inferior thyroid arteries. In this configuration, the vertebral artery is normal in position, despite arising as the 2nd branch. The 1st branch, the thyroidea ima, is the variant artery. It supplies the inferior thyroid gland and may also give rise to thymic arteries. This variant has a relative incidence of between 0.4% and 10%. Less than 4% of thyroidea ima vessels arise from the right subclavian artery in this configuration.^{3,9}

When a duplicated vertebral artery is identified, it is important for the endovascular interventionalist and the diagnostic radiologist to consider the possibility of an associated injury.¹⁰ Duplicated vertebral arteries may be more predisposed to dissection. The most common site of dissection is the extradural portion of the vertebral artery.¹¹ Severe cervical spine injuries with rapid deceleration, subluxation, fracture through the transverse foramen, or flexion of the cervical spine are a common mechanism for injury of the vertebral arteries and are most commonly seen in motor vehicle crashes. In the literature, there are numerous references to spontaneous injuries of a single normal vertebral artery; however, the underlying etiology is unknown.^{12,13} A possible mechanism is the inherent risk of having 2 points of attachment in a duplicated vertebral artery.¹⁴ If the vertebral artery exits the transverse foramina at 2 points or arises as the confluence of 1 branch from the subclavian artery and the 2nd from the transverse foramen, then there are more locations for potential injury. An analogous comparison is the common sites of injury to the aorta, which are its points of attachment.

In the 5th case, there is partial duplication of the proximal right vertebral artery. Here, the origin of the vertebral artery likely presented as persistent duplication of the right 7th dorsal intersegmental artery, which anastomosed with the cranial segment of the primitive vertebral artery. Either vertebral artery may enter the foramen in the 2nd through 7th cervical vertebrae. In cases in which the vertebral artery enters 1 of the higher vertebral foramina, the artery may lie directly behind the common carotid artery. The vertebral arteries enter the 6th cervical foramen in most cases.

In a study by Bergman et al⁶ based on 693 laboratory specimens, dual or accessory vertebral arteries were encountered in 5 of 693 specimens, and all were left-sided. Three small accessory vertebral arteries arose as direct branches of the aortic arch, and 2, as a branch of the thyrocervical trunk. In all cases, the larger or main vertebral artery arose from the left subclavian artery.⁶

The vertebral arteries may present in a number of variant positions. The presence of a vertebral variant must be considered in patients in whom the normal position of the vertebral artery cannot be detected. Anecdotal evidence describes clinical symptoms such as dizziness and vertigo in patients with anomalous vertebral artery origins. Anomalous origin effects hemodynamics and may lead to intercerebral malformations. However, there is no conclusive evidence that these variants predispose patients to cerebrovascular accidents.³ Theoretically, altered hemodynamics cause turbulence, which may predispose the patient to aneurysms and, therefore, increase the risk of a cerebrovascular accident.

Conclusion

In this article, we have reviewed 5 aortograms with embryologic variants of the vertebral arteries. The endovascular interventionist and the diagnostic radiologist must be aware of variations of the vertebral arteries to both identify them correctly and to know where to look when the vessels are not seen in their normal position. Extensive knowledge of the exact position of vertebral arteries has become more important, given the range of endovascular and surgical interventions available today and constantly improving imaging techniques.

References

1. Bogousslavsky J, Van Melle G, Regli F. **The Lausanne Stroke Registry: analysis of 1,000 consecutive patients with first stroke.** *Stroke* 1998;19:1083–92
2. Lemke AJ, Benndorf G, Liebig T., et al. **Anomalous origin of the right vertebral artery: review of the literature and case report of right vertebral artery origin distal to the left subclavian artery.** *AJNR Am J Neuroradiol* 1999;20:1318–21
3. Krudy AG, Doppman JL, Brennan MF. **The significance of the thyroidea ima artery in arteriographic localization of parathyroid adenomas.** *Radiology* 1980;136:51–45
4. Giuffrè R, Sherkat S. **The vertebral artery: developmental pathology.** *J Neurosurg Sci* 1999;43:175–89
5. Williams PL. *Gray's Anatomy.* New York: Churchill Livingstone; 1995:312–15
6. Koenigsberg RA, Peereira L, Nair B, et al. **Unusual vertebral artery origins: examples and related pathology.** *Catheter Cardiovasc Interv* 2003;59:244–50
7. Larsen W. *Human Embryology.* New York: Churchill Livingstone; 1997:198–202
8. Goddard AJ, Annesley-Williams D, Guthrie JA, et al. **Duplication of the vertebral artery: report of two cases and review of the literature.** *Neuroradiology* 2001;43:477–80
9. Bergman RA, et al. **Opus II: cardiovascular system vertebral artery variations.** In: Bergman RA, Afifi AF, Miyauchi R, eds. *Illustrated Encyclopedia of Human Anatomic Variation.* Available at: <http://www.anatomyatlases.org/AnatomicVariants/Cardiovascular/Images0001/0095.sht ml>
10. Gaskill SJ, Heinz ER, Kandt R, et al. **Bilateral congenital anomalies of the extracranial vertebral artery: management with balloon therapy.** *Pediatr Neurosurg* 1996;25:147–50
11. Nogueira TE, Chambers AA, Brueggemeyer MT, et al. **Dual origin of the vertebral artery mimicking dissection.** *AJNR Am J Neuroradiol* 1997;18:382–84
12. Jackson RS, Wheeler AH, Darden BV 2nd. **Vertebral artery anomaly with traumatic dissection causing thromboembolic ischemia: a case report.** *Spine* 2000;25:1989–92
13. Kimura K, Yonemitsu M, Hashimoto Y, et al. **Spontaneous dissection associated with proximal vertebral artery anomaly.** *Intern Med* 1997;36:834–36
14. Raupp SF, Jellema K, Sluzewski M, et al. **Sudden unilateral deafness due to a right vertebral artery dissection.** *Neurology* 2004;62:1442