

# Generic Contrast Agents

Our portfolio is growing to serve you better. Now you have a *choice*.



[VIEW CATALOG](#)

# AJNR

## Persistent Falcine Sinus: Is It Really Rare?

C.-W. Ryu

*AJNR Am J Neuroradiol* 2010, 31 (2) 367-369

doi: <https://doi.org/10.3174/ajnr.A1794>

<http://www.ajnr.org/content/31/2/367>

This information is current as  
of May 24, 2025.

C.-W. Ryu

# Persistent Falcine Sinus: Is It Really Rare?

**BACKGROUND AND PURPOSE:** The falcine sinus has been considered as a rare variation of the venous pathway between the dural layers of the falx cerebri. The purpose of this study was to evaluate the incidence of falcine sinus and its anatomic characteristics by using CTA.

**MATERIALS AND METHODS:** A total of 586 consecutive patients were enrolled in this study. A falcine sinus on CTA was defined as a midline venous structure connecting the vein of Galen or the internal sagittal sinus with the superior sagittal sinus. When present, anatomic features of the falcine sinus were evaluated.

**RESULTS:** Falcine sinuses were present in 12 patients (2.1%). Only 1 case was associated with a congenital anomaly, a dysplastic tentorium. Eight patients had absent or rudimentary straight sinuses, and 4 patients had normal straight sinuses.

**CONCLUSIONS:** In contrast to previous reports, falcine sinuses were not rare in the adult population, and most falcine sinuses were not associated with a congenital anomaly or sinus occlusion. Knowledge and recognition of these falcine sinuses are useful and important during the interpretation of brain CTA.

**ABBREVIATIONS:** CTA = CT angiography; DSA = digital subtraction angiography; F/U = follow-up; ICH = intracerebral hematoma; ISS = inferior sagittal sinus; MIP = maximum intensity projection; SAH = subarachnoid hemorrhage; SSS = superior sagittal sinus; VR = volume-rendering.

The falcine sinus is an embryonic vessel that normally closes after birth.<sup>1</sup> Most persistent falcine sinuses presented in previous reports were associated with congenital disorders, such as malformation of the vein of Galen, absence of the corpus callosum, acrocephalosyndactyly, and Chiari II malformation. Falcine sinuses in adults can be associated with acquired occlusion of the straight sinus.<sup>2-4</sup> Falcine sinuses without associated congenital anomalies or sinus occlusion are extremely rare. However, I have experienced several patients with isolated falcine sinus on CTA, which can clearly depict the venous anatomy of the brain,<sup>5</sup> and several studies have evaluated variations of veins by using CTA.<sup>5,6</sup> The purpose of this study was to determine the incidence of falcine sinus and its anatomic characteristics by using CTA.

## Materials and Methods

This study was performed according to the ethical standards of the institutional review board. The study population comprised all 610 consecutive patients who underwent brain CTA at our institution between September 2008 and February 2009. Patients who underwent CTA were the following: 263 from the emergency medical center and inpatient ward, 304 from outpatient medical service, and 43 patients from the health promotion center.

These patients underwent brain CTA for the following reasons:

- 1) screening for cerebrovascular disease; 2) evaluation of bursting headache; 3) subarachnoid hemorrhage or intracerebral hematoma detected on brain CT; and 4) follow-up for known intracranial vascular disease, such as aneurysm, stenosis, or arteriovenous malformation.

If multiple CTAs were performed in a single patient, only the first CTA was included in the analysis.

CTA was performed by using a 16-channel multidetector row CT scanner (Brilliance CT; Philips Medical Systems, Best, the Netherlands) with the following parameters: 120 kV; 345 mA; matrix, 512 × 512; FOV, 250 mm; collimation, 0.75 mm; pitch, 0.563; total scanning time, 12.4 seconds. The scanning range was from approximately C1-C2 up through the vertex of the skull, as a line drawn perpendicular to the anterior skull base. One hundred milliliters of nonionic contrast media (Visipaque 320 [Iodixanol, 320 mg I/mL]; GE Healthcare, Oslo, Norway) was injected into the antecubital vein at a flow rate of 5 mL/s by using an autoinjector, to enhance the intracranial arteries. Acquisition was initiated via triggering at a threshold of 100 HU, with the region of interest set in the internal carotid artery, after the intravenous contrast bolus was initiated. The various projections of 3D volume-rendering and MIP images were reformatted by using a 3D reconstruction software (Rapida Version 2.8 Infinitt Technology, Seoul, South Korea). A sagittal MIP image of the midline of the brain with a slab thickness of 10 mm was included in routine reformatting of the CTA.

The sagittal midline MIP image, VR images, and axial 3-mm multiplanar reconstruction images were retrospectively analyzed by an experienced neuroradiologist. The falcine sinus on CTA was defined as a midline venous structure connecting the vein of Galen or the ISS with the SSS. The continuity and intrafalcine location of the falcine sinus were confirmed on the series of axial images to differentiate the sinus from the cortical veins on the medial surface of the brain.

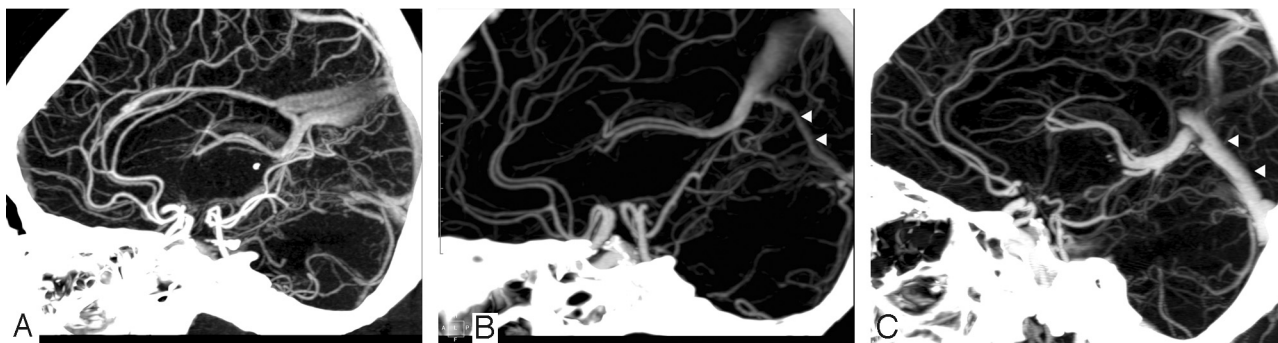
A neuroradiologist retrospectively reviewed CTAs, additional brain images, and clinical information of subjects with a falcine sinus. The anatomic characteristics of falcine sinuses on CTA were reviewed as follows: 1) coincidence of a congenital anomaly of the brain parenchyma or a vascular structure, 2) coincidence of acquired occlusion of another sinus, 3) association with an absent or rudimentary straight sinus, and 4) association with a hypoplastic intervening SSS. When the diameter of the straight sinus on a sagittal MIP was smaller than the diameter of the internal cerebral veins, the straight sinus was de-

Received April 27, 2009; accepted after revision June 20.

From the Department of Radiology, Kyunghee East-West Neo Medical Center, Kyunghee University, College of Medicine, Seoul, Korea.

Please address correspondence to Chang-Woo Ryu, MD, Department of Radiology, East West Neo Medical Center, School of Medicine, Kyunghee University, 149 Sangil-dong, Gangdong-gu, Seoul 137-727, South Korea; e-mail: md.cwryu@gmail.com

DOI 10.3174/ajnr.A1794



**Fig 1.** Three different patterns of straight sinus (arrowheads) with persistent falcine sinus. *A*, First, an absent straight sinus. In addition, the persistent falcine sinus is duplicated. *B*, Second, a rudimentary straight sinus, which is smaller than the internal cerebral veins. *C*, Third, a normal straight sinus.

finer as rudimentary. Additional brain images, such as brain MR imaging and cerebral angiography, were evaluated for associated lesions. Basic demographic data (age, sex) and clinical reasons for undergoing CTA were determined through a review of clinical charts.

## Results

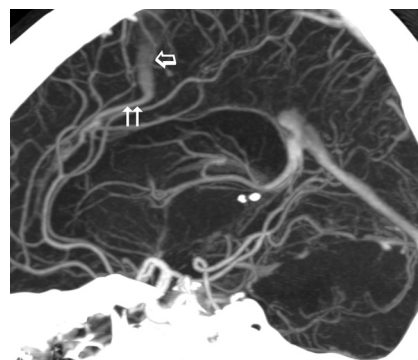
Twenty-four patients were excluded from the study: 13 patients had insufficient venous enhancement due to an early scanning time, 6 patients had insufficient reconstruction images, and 5 patients had severe midline shift of the brain due to hemorrhagic mass effect. Therefore, the CTA images of 586 patients, 275 males and 311 females (mean age with standard deviation [SD],  $52.6 \pm 15.7$  years; median age, 53.0 years; age range, 6–97 years) were ultimately analyzed in this study.

Falcine sinuses were present in 12 patients, resulting in an incidence of 2.1%. There were 5 men and 7 women (mean age with SD,  $50.5 \pm 16.6$  years; median age, 50.5 years; age range, 20–78 years). Falcine sinuses were seen as ribbon- or yardstick-like vascular structures between the vein of Galen and the posterior two-thirds of the SSS. They were spindle-shaped vascular structures in the falx on axial images. One patient (case 9) had an associated congenital anomaly, malposition of the proximal SSS on CTA. Before CTA was performed, she had already undergone a brain MR imaging, which revealed a dysplastic tentorium as well as malposition of the proximal SSS.

The other 11 patients had no associated congenital anomaly or sinus occlusion on brain CT and CTA. In addition, 1 of 11 patients underwent brain MR imaging, which did not reveal any congenital anomaly. Three patients had no straight sinus, 5 patients had rudimentary straight sinuses, and 4 patients had normal straight sinuses (Fig 1). In 1 patient (case 12), the ISS drained through the falcine sinus to the SSS, separate from the deep cerebral veins draining through the straight sinus, without connection between the falcine and straight sinuses (Fig 2). Four patients showed duplication of the falcine sinus (Fig 1A). There was no hypoplasia of the intervening SSS in any of the patients. Two falcine sinuses (cases 2 and 9) were confirmed by cerebral angiography. Demographics and anatomic characteristics of falcine sinuses are summarized in the Table.

## Discussion

Falcine sinuses can be classified into 2 groups, according to pathogenesis: persistent falcine sinuses and recanalized falcine sinuses. A falcine sinus that does not involute but persists



**Fig 2.** A 56-year-old woman underwent CTA for cerebrovascular disease screening. The inferior sagittal sinus (arrows) drains directly into the persistent falcine sinus (arrow), without confluence with the internal cerebral veins.

beyond birth is defined as a persistent falcine sinus. In the 20-mm embryo stage, the primitive falx cerebri contains the sagittal plexus, a meshwork of anastomotic venous channels from which the SSS and straight sinus are thought to develop. A persistent falcine sinus represents a persistent channel of the caudal anastomotic loops of the sagittal plexus.<sup>3</sup> The several duplicated falcine sinuses in this study provided evidence for this hypothesis. The result of autopsy demonstrated that falcine plexus was common in the falx cerebri, and there was significant communication between the ISS and SSS via the falcine venous plexus.<sup>7</sup> Recanalized falcine sinuses probably represent an increase in caliber of 1 of the channels of the normal falcine venous plexus secondary to acquired occlusion of the venous sinus, such that venous drainage is preserved. Because no acquired sinus disease or occlusion was present, probably all the falcine sinuses here are persistent falcine sinuses.

Falcine sinuses are known to be extremely rare in the adult population.<sup>4,8,9</sup> Most reported falcine sinuses in the adult population have been correlated with congenital anomalies or sinus obstruction caused by thrombosis or meningioma. However, in this study, falcine sinuses were not rare on CTAs, and all of the patients with falcine sinuses were adults. Most of these cases were not associated with congenital anomalies or acquired sinus occlusion. Although this study was relatively limited with respect to the number of patients enrolled, the CTA incidence of persistent falcine sinus was 2.1%, which was higher than the prevalence of persistent trigeminal artery, the most common variant of persistent carotid-basilar arterial anastomosis in a large angiographic series (0.1%–0.6%).<sup>10</sup>

Demographics and anatomic characteristics of falcine sinuses									
Case No.	Age (yr)	Sex	Straight Sinus	Congenital Anomaly	Sinus Occlusion	SSS	Other Brain Imaging	Cause of CTA	Remark
1	37	M	Absent	No	No	Normal	MR imaging, DSA	Screening	Duplication
2	40	M	Absent	No	No	Normal		SAH	
3	78	F	Absent	No	No	Normal	MR imaging, DSA	F/U aneurysm	Duplication
4	39	M	Rudimentary	No	No	Normal		Headache	
5	49	F	Rudimentary	No	No	Normal		Screening	Duplication
6	54	F	Rudimentary	No	No	Normal		ICH	
7	61	F	Rudimentary	No	No	Normal		Screening	
8	77	M	Rudimentary	No	No	Normal		ICH	
9	20	F	Normal	Dysplastic tentorium, malposition of SSS	No	Normal		Abnormality on brain MR imaging	
10	43	F	Normal	No	No	Normal		Screening	Duplication
11	52	M	Normal	No	No	Normal		Headache	
12	56	F	Normal	No	No	Normal		Screening	Direct drainage of ISS

These discrepancies between the results of the present study and previous knowledge may be explained as follows: First, to my knowledge, there has been no reliable study looking at the incidence of falcine sinuses in the general population, though previous studies have noted that the persistent falcine sinuses are rare. The total number of the population has not been clearly stated in many previous studies. Second, the way in which the study population was selected may have contributed to the discrepancy in the incidence of associated disease. Most of falcine sinuses were detected on MR imaging and MR venography in previous reports. Because MR venography is a special MR imaging for visualization of venous structures, it is not routinely, but selectively, performed in patients with suspected venous disease. Because sedation is necessary to perform brain MR imaging in pediatric patients, the clinical indications for pediatric brain MR imaging are limited to suspected congenital anomaly, neurologic impairment, epilepsy, suspected brain tumor, etc. Third, the falcine sinus may be overlooked on conventional MR imaging. The falcine sinus can be seen only on a midline sagittal MR image. Therefore, it may be unrecognized by inexperienced radiologists during the interpretation of brain MR imaging. Non-contrast-enhanced MR venography, which has been widely used to show cerebral veins, may have a limitation in revealing a persistent falcine sinus.<sup>11</sup>

In this study, 9 of 12 patients (75%) had both falcine and straight sinuses, and 4 patients had preserved normal caliber of the straight sinuses. I suggest that the falcine sinus may provide important collateral channels in the straight sinus or the caudal segment of the SSS, when the straight sinus is sacrificed in a surgical procedure.<sup>12,13</sup> On the other hand, the falcine sinus may be at risk for major bleeding after iatrogenic falcine injury. Therefore, the presence of the falcine sinus should not be missed on CTA. Despite the findings of this study, clinicians should be aware that falcine sinuses can be associated with congenital anomalies or acquired occlusion of the straight sinus.

This study was limited in that the population was not evenly distributed, because most CTAs were performed in adults. Therefore, children with falcine sinus, who are more commonly reported than adults, were excluded from the study. Another limitation of this study was that the number of

brain MR images available in patients with falcine sinus was low. Therefore, small congenital lesions might be overlooked in patients who underwent brain CTA only.

## Conclusions

In this study, the frequency of persistent falcine sinus was 2.1%—a relatively high incidence—and most falcine sinuses were isolated. Knowledge and recognition of these variations are useful and important during the interpretation of cerebral CTA.

## Acknowledgments

I thank Geon-Ho Jahng, PhD, for discussions and comments on the article.

## References

1. Sener RN. Association of persistent falcine sinus with different clinicoradiologic conditions: MR imaging and MR angiography. *Comput Med Imaging Graph* 2000;24:343–48
2. Manoj KS, Krishnamoorthy T, Thomas B, et al. An incidental persistent falcine sinus with dominant straight sinus and hypoplastic distal superior sagittal sinus. *Pediatr Radiol* 2006;36:65–67
3. Kesava PP. Recanalization of the falcine sinus after venous sinus thrombosis. *AJNR Am J Neuroradiol* 1996;17:1646–48
4. Varma DR, Reddy BC, Rao RV. Recanalization and obliteration of falcine sinus in cerebral venous sinus thrombosis. *Neurology* 2008;70:79–80
5. Kaminogo M, Hayashi H, Ishimaru H, et al. Depicting cerebral veins by three-dimensional CT angiography before surgical clipping of aneurysms. *AJNR Am J Neuroradiol* 2002;23:85–91
6. Suzuki Y, Matsumoto K. Variations of the superficial middle cerebral vein: classification using three-dimensional CT angiography. *AJNR Am J Neuroradiol* 2000;21:932–38
7. Tubbs RS, Loukas M, Louis RG Jr, et al. Anatomy of the falcine venous plexus. *J Neurosurg* 2007;107:155–57
8. Strub WM, Leach JL, Tomsick TA. Persistent falcine sinus in an adult: demonstration by MR venography. *AJNR Am J Neuroradiol* 2005;26:750–51
9. Kashimura H, Arai H, Ogasawara K, et al. Persistent falcine sinus associated with obstruction of the superior sagittal sinus caused by meningioma: case report. *Neurol Med Chir (Tokyo)* 2007;47:83–84
10. Uchino A, Sawada A, Takase Y, et al. MR angiography of anomalous branches of the internal carotid artery. *AJR Am J Roentgenol* 2003;181:1409–14
11. Rollins N, Ison C, Reyes T, et al. Cerebral MR venography in children: comparison of 2D time-of-flight and gadolinium-enhanced 3D gradient-echo techniques. *Radiology* 2005;235:1011–17
12. Ito M, Sonokawa T, Mishina H, et al. Reversible dural arteriovenous malformation-induced venous ischemia as a cause of dementia: treatment by surgical occlusion of draining dural sinus—case report. *Neurosurgery* 1995;37:1187–91, discussion 1191–92
13. Kanno T, Sugishita N, Kasama A. Surgical ablation of veins and sinuses: safety and risk. In: Hakuba A, ed. *Surgery of the Intracranial Venous System*. Tokyo, Japan: Springer-Verlag; 1996:116–20