



## Discover Generics

Cost-Effective CT & MRI Contrast Agents



WATCH VIDEO

# AJNR

This information is current as of June 1, 2025.

### **Restoration of Spinal Alignment and Disk Mechanics following Polyetheretherketone Wafer Kyphoplasty with StaXx FX**

S.M. Renner, P.P. Tsitsopoulos, A.T. Dimitriadis, L.I. Voronov, R.M. Havey, G. Carandang, B. McIntosh, C. Carson, D. Ty, J.G. Ringelstein and A.G. Patwardhan

*AJNR Am J Neuroradiol* 2011, 32 (7) 1295-1300

doi: <https://doi.org/10.3174/ajnr.A2484>

<http://www.ajnr.org/content/32/7/1295>

ORIGINAL  
RESEARCH

S.M. Renner  
P.P. Tsitsopoulos  
A.T. Dimitriadis  
L.I. Voronov  
R.M. Havey  
G. Carandang  
B. McIntosh  
C. Carson  
D. Ty  
J.G. Ringelstein  
A.G. Patwardhan



# Restoration of Spinal Alignment and Disk Mechanics following Polyetheretherketone Wafer Kyphoplasty with StaXx FX

**BACKGROUND AND PURPOSE:** EPFs sustained during VCFs degrade the disk's ability to develop IDP under load. This inability to develop pressure in combination with residual kyphotic deformity increases the risk for adjacent vertebral fractures. We tested the hypothesis that StaXx FX reduces kyphosis and endplate deformity following vertebral compression fracture, restoring disk mechanics.

**MATERIALS AND METHODS:** Eight thoracolumbar, 5-vertebrae segments were tested. A void was selectively created in the middle vertebra. The specimens were compressed until EPF and to a grade I-II VCF. PEEK wafer kyphoplasty was then performed. The specimens were then tested in flexion-extension ( $\pm 6$  Nm) under 400-N preload intact, after EPF, VCF, and kyphoplasty. Endplate deformity, kyphosis, and IDP adjacent to the fractured body were measured.

**RESULTS:** Vertebral body height at the point of maximal endplate deformity decreased after EPF and VCF and was partially corrected after StaXx FX, remaining less than intact ( $P = .047$ ). Anterior vertebral height decreased after VCF ( $P = .002$ ) and was partially restored with StaXx FX, remaining less than intact ( $P = .015$ ). Vertebral kyphosis increased after VCF ( $P < .001$ ) and reduced after StaXx FX, remaining greater than intact ( $P = .03$ ). EPF reduced IDP in the affected disk in compression-flexion loading ( $P < .001$ ), which was restored after StaXx FX ( $P = 1.0$ ). IDP in the unaffected disk did not change during testing ( $P > .3$ ).

**CONCLUSIONS:** StaXx FX reduced endplate deformity and kyphosis, and significantly increased anterior height following VCF. Although height and kyphosis were not fully corrected, the disk's ability to pressurize under load was restored.

**ABBREVIATIONS:** EPF = endplate fracture; IDP = intradiskal pressure; PEEK = polyetheretherketone; VCF = vertebral compression fracture

Vertebroplasty and balloon kyphoplasty are widely applied techniques for the management of compression fractures.<sup>1-3</sup> In addition to pain relief, they both aim at increasing the strength and stiffness of the affected vertebra, thereby preventing further deterioration of segmental spine biomechanics.<sup>4</sup> In particular, kyphoplasty by using an inflatable balloon tamp attempts to restore the height of the fractured vertebral body and to correct the local kyphosis.<sup>5</sup>

In patients with osteoporotic VCFs, the risk for subsequent fractures has been reported to be 5-fold after a single vertebral fracture and up to 12-fold in the presence of 2 or more fractures.<sup>6-8</sup> Individuals with VCFs also tend to develop significant kyphotic deformity. This modifies the loads within the kyphotic segment by shifting the center of gravity forward, ultimately increasing the compressive loads and the risk for adjacent vertebral fractures.<sup>9-11</sup>

Under normal conditions, the nucleus develops pressure when the spine is loaded. This pressure allows the nucleus to share load with the annulus, producing a uniform load on the vertebral body. If no nucleus pressure is created, there will be no load-sharing within the disk and the annulus alone will bear the load, leading to an increased load on the anterior cortex. Changes in the properties of the intervertebral disk have been shown to alter the pattern of load distribution between the disk and the vertebral centrum.<sup>12,13</sup> The coexistence of an osteoporotic compression fracture with endplate depression also alters the mechanical properties of the intervertebral disk, thereby modifying the load distribution within the adjacent spine areas.<sup>14</sup> Depression of the fractured vertebral endplate has been shown to decrease intervertebral disk pressure and increase adjacent level strain in compression-flexion loading, therefore predisposing adjacent vertebrae to fracture.<sup>14</sup> Based on this finding, it has been suggested that in addition to restoring spinal sagittal alignment, the ability to fully reduce the entire fractured endplate is equally important to restore load transmission across the fractured level and decrease the likelihood of adjacent vertebral fractures.<sup>14</sup>

Recently, StaXx FX has been introduced as an alternative to traditional balloon kyphoplasty. The StaXx FX system (Spine Wave, Shelton, Connecticut) uses a percutaneous, parapedicular (posterolateral vertebral body) approach developed as an alternative to traditional vertebroplasty and kyphoplasty. By using PEEK wafers, it provides controlled and vertically directed fracture reduction and vertebral augmentation in 1-mm increments with a permanent implant. Other theoretic

Received September 16, 2010; accepted November 21.

From the Department of Veterans Affairs (S.M.R., P.P.T., L.I.V., R.M.H., G.C., B.M., A.G.P.), Edward Hines Jr. VA Hospital, Hines, Illinois; Loyola University Medical Center (P.P.T., A.T.D., L.I.V., R.M.H., A.G.P.), Maywood, Illinois; Spine Wave, Inc. (C.C.), Shelton, Connecticut; and Nuclear Medicine Service (J.G.R.), Edward Hines Jr. VA Hospital, Hines, Illinois


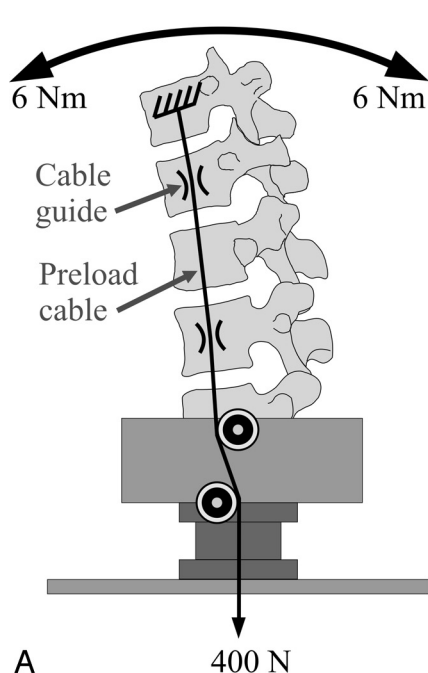
Institutional research support was provided by the Department of Veterans Affairs, Washington, D.C., and Spine Wave, Inc., Shelton, Connecticut

Please address correspondence to Avinash G. Patwardhan, PhD, Department of Orthopaedic Surgery and Rehabilitation, Loyola University Medical Center, 2160 S. First Ave, Maywood, IL 60153; e-mail: apatwar@lumc.edu



Indicates open access to non-subscribers at [www.ajnr.org](http://www.ajnr.org)

DOI 10.3174/ajnr.A2484



**Fig 1.** Testing setup shown in schematic (A) and photo (B).

cal advantages over the currently applied techniques of vertebroplasty and balloon kyphoplasty include retained intraoperative fracture reduction and a reduced amount of cement infusion, and thus a lower likelihood of cement extravasation.

The current study tested the hypothesis that PEEK wafer kyphoplasty reduces vertebral kyphosis and endplate deformity following VCF, thereby restoring the disk's ability to develop pressure under load.

## Materials and Methods

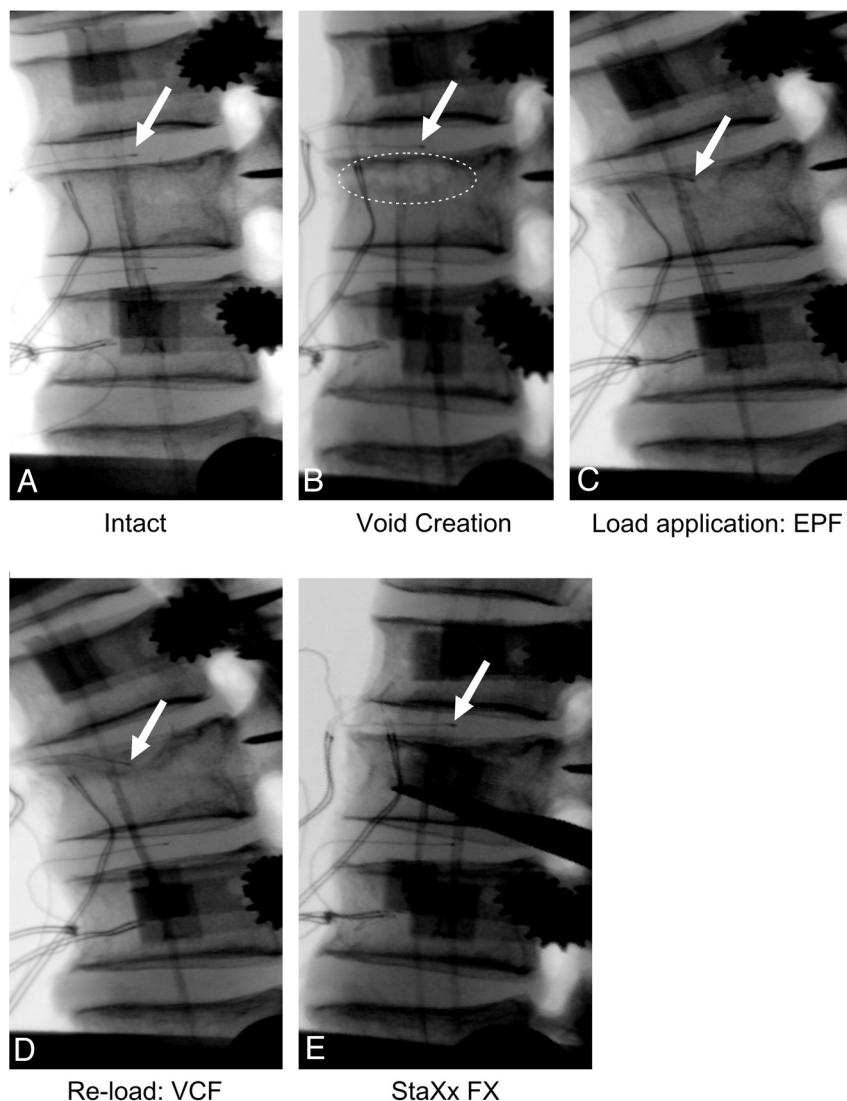
### Specimens and Experimental Setup

Eight fresh-frozen human thoracic-lumbar specimens (age range,  $67.8 \pm 5.7$  years; 4 male, 4 female), each consisting of 5 vertebrae (T10-L2, T12-L4, and L1-L5), were used. All specimens were radiographically screened to exclude pre-existing osteoporotic fractures within the tested levels, severe disk space collapse, bridging osteophytes, and vertebral neoplastic disease. Bone mineral attenuation of the index and adjacent levels was determined by using dual energy x-ray absorptiometry (Lunar Prodigy/DPX Series; GE Healthcare, Waukesha, Wisconsin). The specimens were thawed at room temperature (20°C) 24 hours before testing. The paravertebral muscles were dissected, while keeping the disks, ligaments, and posterior bony structures intact. The most cephalad and caudal vertebrae of each specimen were anchored in cups by using bone cement and pins.

The specimen was fixed to the testing apparatus at the caudal end and was free to move at the cephalad end. A moment was applied by controlling the flow of water into bags attached to loading arms fixed to the cephalad vertebra. A 6-axis load cell (model MC3A-6-1000; AMTI, Newton, Massachusetts) was placed under the specimen to measure the applied loads and moments. The apparatus allowed for continuous cycling of the specimen between specified maximal moment end points in flexion and extension. The load-displacement data were collected until 2 reproducible load-displacement loops were obtained. This required a maximum of 3 loading cycles. The collected data from the last cycle were used for analysis.

The motion of the cephalad vertebra relative to the caudal vertebra was measured by using an optoelectronic motion measurement system (model 3020, Optotrak; Northern Digital, Waterloo, Ontario, Canada). In addition, biaxial angle sensors (model 902-45; Applied Geomechanics, Santa Cruz, California) were mounted on the cephalad and caudal vertebrae to allow real-time feedback for the optimization of the preload path. The spines were instrumented with pressure transducers (model 060S-1000; Precision Measurement, Ann Arbor, Michigan) in the nucleus pulposus of the disks above and below the target vertebra. The pressure transducers were calibrated before the testing of each specimen by using a pressure chamber. Load and pressure data were collected throughout the loading cycle at a rate of 5 Hz, resulting in approximately 200 data points from 0 to 6 Nm.

Compressive preload was applied to the specimens according to the follower load concept<sup>15</sup> where the compressive preload is applied along a path that follows the curve of the spine. By applying a compressive load along the follower load path, the segmental bending moments and shear forces due to the preload application are minimized, allowing a multisegment thoracolumbar spine to support physiologic compressive preloads without constraining the sagittal plane motion.<sup>16</sup> The preload was applied by using bilateral loading cables attached to the cup holding the cephalad vertebra. The cables passed freely through guides anchored to the vertebrae adjacent to the target vertebra (Fig 1). To avoid creation of stress risers, the cable guide mounting technique did not violate the cortices of the vertebral bodies adjacent to the target vertebra. No cable guides were mounted to the target vertebra. The loading cables were connected to loading actuators under the specimen. The cable guide mounts allowed anteroposterior adjustments of the follower load path. The alignment of the preload path was optimized by adjusting the cable guide locations to minimize changes in the sagittal alignment of the specimen when a compressive load of up to 400 N was applied. The cables were coated with radiopaque barium solution to be visible on x-ray images. A radiopaque ball (19.05 mm in diameter) was used as a calibration marker for the x-ray images.



**Fig 2.** Testing sequence shown on specimen 6. Intact specimen with pressure transducers inserted in the disks above and below the middle vertebra (A). Dashed circle shows the location of the void created to selectively fracture the upper endplate of the middle vertebra (B). Arrow indicates location of pressure transducer in cephalad disk: Note the location of the transducer within the vertebral body space after EPF and VCF (C and D) and restoration of the intact transducer location after StaXx FX (E).

### Experimental Protocol

Each specimen was tested under flexion-extension moments ( $\pm 6$  Nm) with a 400-N compressive preload intact, after EPF, after VCF, and after kyphoplasty with PEEK wafers. Pressure was recorded in the disks above and below the middle (target) vertebra (Fig 2A).

### Experimental Creation of Endplate and VCF

A previously described technique was used to selectively fracture only the upper endplate of the middle vertebra.<sup>14</sup> Through a small opening on the anterior wall, a void was created selectively under the upper endplate and was extended to one-third of the vertebral body trabecular content; thereby creating a “stress-riser” under the target endplate (Fig 2B). The specimen was flexed to 5 Nm and compressed by using the loading cables until a fracture of the upper endplate (loss of continuity or development of endplate concavity) without significant anterior height loss was evident on fluoroscopy (Fig 2C). After creation of the EPF, the specimen was loaded in flexion-extension ( $\pm 6$  Nm) with a compressive preload of 400 N. Following the moment loading, the specimen was again flexed to 5 Nm and compressed until an anterior height loss of 20%–30% was seen radiographically (Fig

2D). After creation of the vertebral compression fracture, the specimen was again loaded in flexion-extension ( $\pm 6$  Nm) with a compressive preload of 400 N.

### Reduction of the Vertebral Kyphotic Deformity Using PEEK Wafer Kyphoplasty

After vertebral fracture, the specimen remained under a physiologic compressive preload of 150 N, representing the compressive preload on the lumbar spine in the prone position.<sup>17</sup> PEEK wafer kyphoplasty was performed by using the StaXx FX device following the manufacturer’s instructions. In this procedure, PEEK wafers with a thickness of 1 mm, width of 8 mm, and a length of either 20, 25, or 30 mm were inserted through a parapedicular approach (posterolateral vertebral body). The wafers were progressively inserted in a manner that each newly introduced wafer pushed the previously implanted wafers superiorly until the desired fracture reduction was achieved (Fig 2E). The wafers were inserted and positioned such that maximal reduction of the endplate deformation without overcorrection was observed radiographically by using sagittal, frontal, and 2 oblique views. Bone cement was then injected around the wafer stack to stabilize the PEEK



wafers and fractured vertebra. The cement was allowed to harden for 1 hour with the specimen at room temperature and under a 150-N compressive load. The specimen was then retested in flexion-extension with a compressive preload of 400 N.

### Data Analysis

CT scans (section increment, 0.6 mm; Sensation Cardiac 64, Siemens, Malvern, Pennsylvania) were taken of each specimen intact and following implant insertion to evaluate the placement of the PEEK wafers within the index vertebra. Endplate deformity, anterior vertebral height, vertebral kyphosis, and segmental kyphosis measurements were performed at the index level by using computer software (Image-Pro Plus, version 4.1.0; MediaCybernetics, Bethesda, Maryland) on digital fluoroscopy images taken with the specimen in neutral posture under 400-N compressive preload by 2 independent observers. The first observer (P.P.T.) is a neurosurgeon and fellowship-trained spine surgeon. The second observer (S.M.R.) is a PhD biomedical engineer with 11 years of experience in spine biomechanics. Pearson coefficients were calculated to determine interobserver reliability. The endplate deformity was measured as the vertebral height at the point of maximal endplate depression. To ensure that the height measurement was taken at the same location for each testing condition, the location of the maximal endplate deformation was first determined in the EPF condition as the point of the lowest EPF concavity. The distance from that location to the posterior rim along the inferior endplate was then measured and used to determine the location for the vertebral height measurements in all other testing conditions. Disk pressure was normalized so that values in neutral position under 400-N preload were taken to 0 to compensate for thermal drifting of sensors throughout testing. As a result, the change in pressure from neutral to full flexion for each testing condition was used for analysis. The data were analyzed by using repeated measures analysis of variance with Bonferroni correction for 4 comparisons with the level of significance set at  $P = 0.05$ . The SPSS statistical package, version 15.0 was used (SPSS, Chicago, Illinois).

## Results

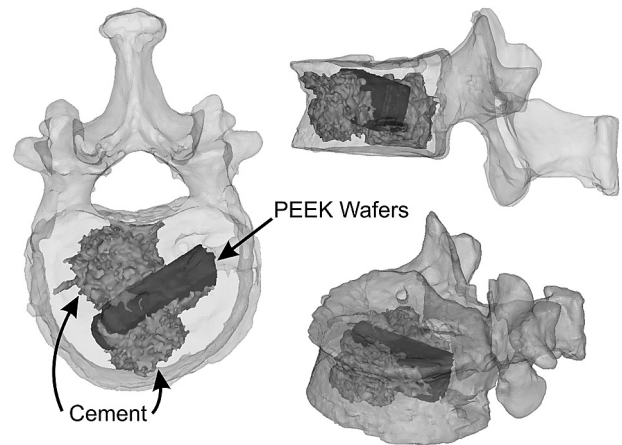
### Baseline Data

The average bone mineral attenuation of the index vertebra was  $0.80 \pm 0.14$  g/cm<sup>2</sup>. No significant difference was seen in the bone densities at the index level and both adjacent levels ( $P > .10$ ). An average of  $15 \pm 1.0$  wafers (range, 13–16) and  $4.0 \pm 0.8$  mL of cement were inserted during the kyphoplasty procedure to achieve the maximal endplate deformity reduction possible. In all specimens, the cement was injected evenly between the anterior and posterior aspects of the wafer stacks. No extravasation of bone cement was noted. Three-dimensional CT scan reconstructions showed appropriate placement of the PEEK wafers below the endplate deformity in all specimens (Fig 3).

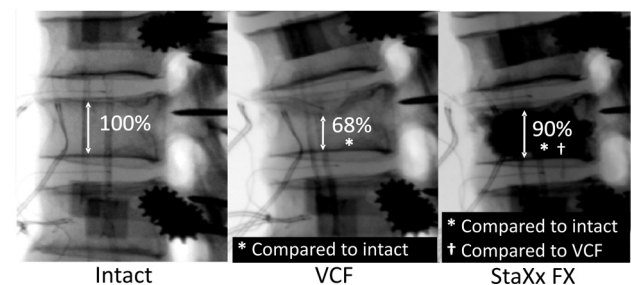
Interobserver reliability among the 2 independent observers was strong for all measurements; thus, all values presented are an average of both independent measurements ( $\kappa = 0.90, 0.96, 0.90$ , and  $0.94$  for anterior height, endplate deformity, vertebral kyphosis, and segmental kyphosis, respectively).

### Endplate Deformity

Endplate deformity significantly increased after EPF and VCF. Vertebral heights at the point of maximal endplate deformity



**Fig 3.** 3D CT scan reconstructions of specimen 6 showing placement of the PEEK wafers and cement below the endplate deformity.



**Fig 4.** Vertebral body height at the location of maximal endplate deformity as a percentage of intact height as shown on specimen 6.

were  $71.3 \pm 6.5\%$  and  $66.6 \pm 7.4\%$  of intact controls after EPF and VCF, respectively ( $P < .001$ ). After PEEK wafer kyphoplasty, though the deformity was remarkably reduced ( $P < .001$ ), it remained greater than intact, with a vertebral height at the point of maximal endplate deformity of  $88.7 \pm 8.3\%$  of intact controls ( $P = .022$ ) (Fig 4).

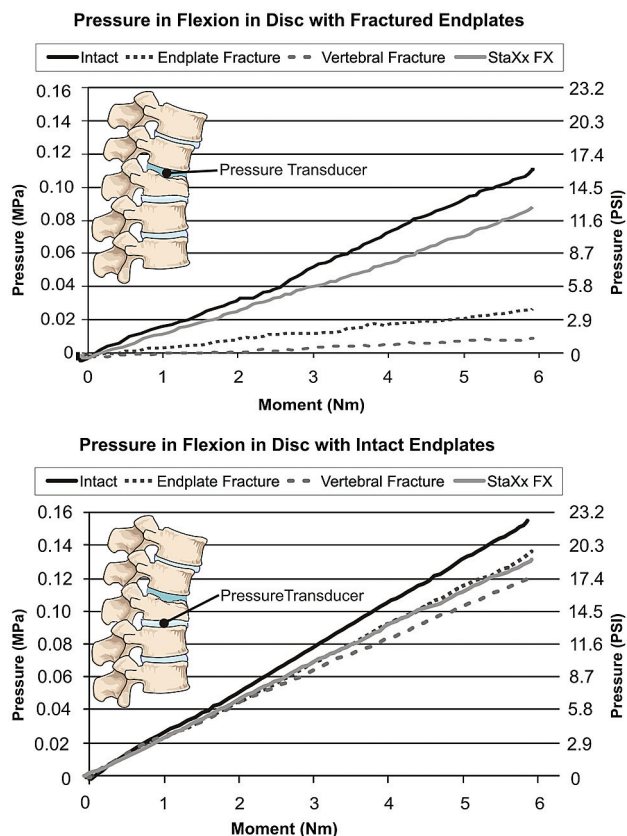
### Anterior Height

Anterior vertebral body height at the index level was unchanged with endplate deformity ( $91.9 \pm 9.3\%$  of intact,  $P = .095$ ) but was significantly decreased with VCF ( $80.8 \pm 9.3\%$  of intact,  $P = .002$ ). After PEEK wafer kyphoplasty, though the anterior height was significantly increased compared with the height with VCF ( $P = .015$ ), it remained less than intact ( $86.3 \pm 9.0\%$  of intact,  $P = .019$ ).

### Kyphosis

Vertebral kyphosis did not change after EPF ( $P = .24$ ); however, it increased by  $7.8 \pm 3.2^\circ$  after vertebral compression fracture ( $P = .003$ ). After PEEK wafer kyphoplasty, vertebral kyphosis was reduced by  $3.5 \pm 1.8^\circ$  ( $P < .001$ ), while remaining greater than intact ( $P = .02$ ).

After EPF, segmental kyphosis increased by  $7.4 \pm 4.6^\circ$  ( $P = .01$ ) compared with intact and was increased by  $9.96 \pm 3.5^\circ$  from intact controls following VCF ( $P < .001$ ). StaXx FX decreased segmental kyphosis by  $2.2 \pm 1.0^\circ$  ( $P < .001$ ), but segmental kyphosis remained greater than intact ( $P = .003$ ).



**Fig 5.** Representative intradiscal pressure under flexion-compression loading (specimen 6) in the cephalad disk with damaged endplates (*top*) and in the caudal disk with undamaged endplates (*bottom*).

### IDP in Flexion

Flexion IDP in the cephalad disk with the damaged endplate significantly reduced after both EPF and VCF compared with intact ( $27.5 \pm 18.6\%$  and  $36.3 \pm 8.8\%$  of intact values, respectively;  $P < .001$ ). It was restored after StaXx FX to  $81.4 \pm 39.7\%$  of intact values ( $P = 1.00$ ). Flexion disk pressure was not significantly affected in the caudal disk where endplates remained undisturbed during the experiment ( $P > .27$ ) (Fig 5).

### Discussion

The efficacy of kyphoplasty by using the StaXx FX system in correcting endplate deformity and restoring intervertebral disk mechanics following compression fractures in osteoporotic vertebrae was tested by using a previously validated technique. EPF caused a significant reduction in the vertebral body height at the point of maximal endplate deformity compared with intact, and it significantly reduced the ability of the intervertebral disk to develop IDP under flexion-compression loading compared with the intact disk. Anterior vertebral body height at the index level was significantly reduced only after vertebral compression fracture. Kyphosis induced by vertebral body fracture, though improved after augmentation, remained greater than intact. StaXx FX increased endplate height to 90% of intact, increased anterior height to 86% of intact, significantly decreased kyphotic deformity and restored disk pressure to 81% of prefracture values. No changes in the pressure profiles were seen in the disk where the end-

plates had not been damaged, which is consistent with the observations of Tzermiadianos et al.<sup>14</sup>

The major concern associated with compression fractures is deformity progression and the increased risk of adjacent fractures. Although new adjacent fractures do occur with or without the use of vertebroplasty or kyphoplasty, there is still no adequate documentation on the risk of adjacent fracture after vertebral augmentation.<sup>18,19</sup> This is probably dependent more upon load transmission to the surrounding structures and maintenance of spine alignment rather than upon changes in the vertebral bone stiffness.<sup>14</sup>

In an osteoporotic vertebral body, kyphosis increases peak stresses up to 2.5-fold. If kyphotic spinal alignment alters load sharing and disturbs the balance between vertebral segments leading to an increased likelihood of new fractures, any effort to correct the kyphosis to prevent subsequent vertebral fractures is justified.<sup>4,11,18</sup> Gaitanis et al<sup>11</sup> showed that cement augmentation with hyperextension almost totally restored anterior and middle vertebral column height; however, posterior height was not corrected adequately. The results from the current study closely match those of Gaitanis et al<sup>11</sup> in terms of restoration of anterior height, whereas StaXx FX was able to nearly equally reduce both the vertebral and segmental kyphosis.

It has been demonstrated that sustained disk compression in the lumbar spine reduces the volume and pressure in the nucleus pulposus, while increasing compressive forces in the periphery of the annulus.<sup>20</sup> Sustained bending and compression also narrow disk space height, creating slack in the collagen fibers in the annulus, making them unable to resist tensile forces related to bending.<sup>20</sup> It has also been shown that load distribution between the cortical and cancellous bone within a vertebral body are largely dependent upon the intervertebral disk properties.<sup>12,13</sup> Data from in vitro studies indicate that endplate injury increases the space available for the nucleus, which cannot increase pressure during flexion, thus decreasing IDP at adjacent segments.<sup>14,21,22</sup> The result of decreased nuclear pressure is increased stress on the annulus and apophyseal ring.<sup>18,23</sup>

Tzermiadianos et al<sup>14</sup> tested the hypothesis that the inability of the disk to generate adequate IDP after vertebral fractures in human cadaveric specimens will increase loading of adjacent vertebra predisposing them to fracture even in the absence of a kyphotic deformity. In this study, after cement augmentation, disk pressure increased during flexion by  $15 \pm 11\%$  in the specimens with intact endplates, whereas it was decreased by  $19 \pm 26.7\%$  in the disks with the fractured endplates. It was suggested that load concentration on the anterior part of adjacent vertebrae can be associated with an increased risk of fracture and that in addition to the correction of the spinal alignment, reduction of the fractured endplate is a major factor for restoring normal load sharing, thus decreasing the likelihood of adjacent vertebral fractures.<sup>14</sup>

In the current study, the endplate deformity and kyphosis induced after a compression fracture were reduced substantially with StaXx FX, and the pressure within the disk with damaged endplates was fully restored to intact levels. This suggests that StaXx FX can address both factors thought to be associated with adjacent fractures: spinal alignment and altered disk mechanics.

The present findings should be interpreted under the spectrum of the study limitations. Biomechanical testing cannot fully replicate physiologic loads. In particular, the complex musculature at the thoraco-lumbar level renders a direct reproduction of muscle load nearly impossible in a cadaveric spine. Although pressure was recorded in both flexion and extension, the pressure data were only presented for flexion loading due to difficulties in interpreting the data in extension. In most cases, a decrease in pressure was seen as the spine moved into extension following fracture and PEEK wafer kyphoplasty. This may be due to several reasons. First, the repeated and high magnitude compressive loading required to create the fractures (~1500–2000 N) led to height loss to the posterior aspect of the disk, which was evident radiographically. This disk height loss led to abutment of the posterior endplates, a large amount of compression of the posterior annulus during extension, or both, and may then have created a hinging effect on the motion segment. Second, the timing of facet joint engagement as the motion segment moves in extension will be affected by a decrease in disk height, with facet engagement occurring sooner with smaller disk height. Endplate abutment and motion segment hinging may have then led to decreased disk pressure under extension loading. As a result, extension pressure data have not been presented due to difficulty in interpreting the data in a way that is meaningful in the context of VCFs that are more likely to occur under flexion loading. Furthermore, all testing steps (endplate and vertebral body fracture, PEEK wafer kyphoplasty) were carried out acutely. Therefore, the long-term course of fracture and augmentation at both the index and adjacent segments remains unknown.

To our knowledge, there are no published laboratory or clinical studies on the use of StaXx FX for the treatment of VCFs. An ongoing clinical study suggests that PEEK wafer kyphoplasty, in addition to cement infusion, seems to be a safe and effective procedure that relieves pain and delivers less cement volume compared with conventional techniques.<sup>24</sup> However, the long-term effects and consequences have yet to be determined.

## Conclusions

The current study showed that in an acute treatment scenario, StaXx FX can effectively reduce the kyphotic and endplate deformity associated with VCFs and allow the intervertebral disk to develop pressure under load, thereby restoring normal disk mechanics and load sharing. Therefore, kyphoplasty by using the StaXx FX system may be a mechanically viable treatment method for osteoporotic vertebral compression fractures, which addresses the 2 main risk factors related to adjacent fractures: kyphotic deformity and altered disk biomechanics. Because there is a paucity of clinical data, further in vivo studies are needed to test the efficacy of PEEK wafer kyphoplasty in eliminating pain, restoring spinal alignment, and possibly reducing the risk of adjacent vertebral fractures in the long term.

Disclosures: S.M.R., Research Support (including provision of equipment or materials): Spine Wave, Inc. Details: Research Grant; B.M., Research Support (including provision of equipment or materials): Loyola Musculoskeletal, Biomechanics Laboratory, Details: Performed spinal implant testing; C.C., Ownership Interest: Stock options, Other financial relationships: Direct employment, Details: Director R&D, salary, and bonus; D.T., Consultant: employed by Spine Wave, Inc., Ownership Interest: Stock option, Other Financial Relationships: Direct employment; A.G.P., Research Support (including provision of equipment or materials): Department of Veterans Affairs, Washington D.C., and Spine Wave, Inc.

## References

1. Eck JC, Nachtigall D, Humphreys SC, et al. **Comparison of vertebroplasty and balloon kyphoplasty for treatment of vertebral compression fractures: a meta-analysis of the literature.** *Spine J* 2008;8:488–97
2. Hadjipavlou AG, Tzermiadianos MN, Katonis PG, et al. **Percutaneous vertebroplasty and balloon kyphoplasty for the treatment of osteoporotic vertebral compression fractures and osteolytic tumours.** *J Bone Joint Surg Br* 2005;87:1595–604
3. Taylor RS, Fritzell P, Taylor RJ. **Balloon kyphoplasty in the management of vertebral compression fractures: an updated systematic review and meta-analysis.** *Eur Spine J* 2007;16:1085–100
4. Patwardhan AG, Tzermiadianos MN. **Biomechanics of vertebral body augmentation.** *Adv Osteoporot Fract Manag* 2005;4:34–39
5. Mueller CW, Berlemann U. **Kyphoplasty: chances and limits.** *Neurol India* 2005;53:451–57
6. Lindsay R, Silverman SL, Cooper C, et al. **Risk of new vertebral fracture in the year following a fracture.** *JAMA* 2001;285:320–23
7. Melton LJ, 3rd, Atkinson EJ, Cooper C, et al. **Vertebral fractures predict subsequent fractures.** *Osteoporos Int* 1999;10:214–21
8. Ross PD, Genant HK, Davis JW, et al. **Predicting vertebral fracture incidence from prevalent fractures and bone density among non-black, osteoporotic women.** *Osteoporos Int* 1993;3:120–26
9. Black DM, Arden NK, Palermo L, et al. **Prevalent vertebral deformities predict hip fractures and new vertebral deformities but not wrist fractures. Study of Osteoporotic Fractures Research Group.** *J Bone Miner Res* 1999;14:821–28
10. Pongchaiyakul C, Nguyen ND, Jones G, et al. **Asymptomatic vertebral deformity as a major risk factor for subsequent fractures and mortality: a long-term prospective study.** *J Bone Miner Res* 2005;20:1349–55
11. Gaitanis IN, Carandang G, Phillips FM, et al. **Restoring geometric and loading alignment of the thoracic spine with a vertebral compression fracture: effects of balloon (bone tamp) inflation and spinal extension.** *Spine J* 2005;5:45–54
12. Kurowski P, Kubo A. **The relationship of degeneration of the intervertebral disc to mechanical loading conditions on lumbar vertebrae.** *Spine* 1986; 11:726–31
13. Liu L, Pei F, Song Y, et al. **The influence of the intervertebral disc on stress distribution of the thoracolumbar vertebrae under destructive load.** *Chin J Traumatol* 2002;5:279–83
14. Tzermiadianos MN, Renner SM, Phillips FM, et al. **Altered disc pressure profile after an osteoporotic vertebral fracture is a risk factor for adjacent vertebral body fracture.** *Eur Spine J* 2008;17:1522–30
15. Patwardhan AG, Havey RM, Meade KP, et al. **A follower load increases the load-carrying capacity of the lumbar spine in compression.** *Spine* 1999; 24:1003–09
16. Stanley SK, Ghanayem AJ, Voronov LI, et al. **Flexion-extension response of the thoracolumbar spine under compressive follower preload.** *Spine* 2004; 29:E510–14
17. Shindle MK, Gardner MJ, Koob J, et al. **Vertebral height restoration in osteoporotic compression fractures: kyphoplasty balloon tamp is superior to postural correction alone.** *Osteoporos Int* 2006;17:1815–19
18. Hadley C, Awan OA, Zoarski GH. **Biomechanics of vertebral bone augmentation.** *Neuroimaging Clin N Am* 2010;20:159–67
19. Buchbinder R, Osborne RH, Ebeling PR, et al. **A randomized trial of vertebroplasty for painful osteoporotic vertebral fractures.** *N Engl J Med* 2009; 361:557–68
20. Dolan P, Adams MA. **Recent advances in lumbar spinal mechanics and their significance for modelling.** *Clin Biomech* 2001;16(suppl 1):S8–S16
21. Adams MA, McNally DS, Wagstaff J, et al. **Abnormal stress concentrations in lumbar intervertebral discs following damage to the vertebral bodies: a cause of disc failure?** *Eur Spine J* 1993;1:214–21
22. Adams MA, McNally DS, Dolan P. **'Stress' distributions inside intervertebral discs. The effects of age and degeneration.** *J Bone Joint Surg Br* 1996;78:965–72
23. Gaitanis IN, Hadjipavlou AG, Katonis PG, et al. **Balloon kyphoplasty for the treatment of pathological vertebral compressive fractures.** *Eur Spine J* 2005;14:250–60
24. Olan W. **Structural kyphoplasty: a novel approach that is safe and effective for vertebral fracture repair with early results suggesting a lower subsequent fracture rate.** *J Neurointerv Surg* 2009;1:77