

Generic Contrast Agents

Our portfolio is growing to serve you better. Now you have a choice.



[VIEW CATALOG](#)

AJNR

IgG4-Related Inflammatory Pseudotumor of the Trigeminal Nerve: Another Component of IgG4-Related Sclerosing Disease?

M. Katsura, A. Morita, H. Horiuchi, K. Ohtomo and T. Machida

This information is current as of May 25, 2025.

AJNR Am J Neuroradiol 2011, 32 (8) E150-E152

doi: <https://doi.org/10.3174/ajnr.A2256>

<http://www.ajnr.org/content/32/8/E150>

CASE REPORT

M. Katsura
A. Morita
H. Horiuchi
K. Ohtomo
T. Machida



IgG4-Related Inflammatory Pseudotumor of the Trigeminal Nerve: Another Component of IgG4-Related Sclerosing Disease?

SUMMARY: IgG4-related IPTs have been reported in various sites and may form part of the spectrum of systemic IgG4-related sclerosing disease. Some pseudotumors are clinically and radiologically indistinguishable from malignant tumors. We present the first case of an IgG4-related IPT of the trigeminal nerve diagnosed histopathologically without involvement of any of the common sites. The trigeminal nerve pseudotumor may represent a component of IgG4-related sclerosing disease.

ABBREVIATIONS: ALK = anaplastic lymphoma kinase; DWI = diffusion-weighted imaging; HPF = high-power field; IgG = immunoglobulin G; IgG4 = immunoglobulin G4; IMT = Inflammatory myofibroblastic tumor; IPT = inflammatory pseudotumor

IPT is a rarely occurring non-neoplastic lesion that can mimic a neoplasm. Histologically, the lesions are characterized by inflammatory cell infiltration and variable fibrotic responses. IPT has been described in the literature by many different names, a fact that suggests the complexity and variable histologic characteristics and behavior of this entity.

In recent years, the relationship between some populations of IPT and IgG4 has been suggested. IgG4-related IPTs may form part of the spectrum of systemic IgG4-related sclerosing disease, with autoimmune pancreatitis being the predominant clinical presentation.¹ However, IgG4-related sclerosing diseases without pancreatic involvement have also been reported.²

In this article, we report a rare case of pathologically proved IgG4-related IPT that involved the unilateral trigeminal nerve.

Case Report

A 59-year-old woman with a medical history of palmoplantar pustulosis and diabetes presented with left-sided facial numbness, which she had experienced for 4 years. She denied tinnitus, difficulty in hearing, or dysphagia. Physical examination revealed paresthesia in areas supplied by the left trigeminal nerve. Findings of the remainder of her neurologic examination were unremarkable. She had no surgical history in the head or neck region.

MR imaging revealed a homogeneously enhancing soft-tissue mass involving the skull base along the second and third divisions of the left trigeminal nerve (Fig 1A). T2-weighted imaging demonstrated a hypointense mass in the left Meckel cave, extending to the left pterygopalatine fossa via the left foramen rotundum and further to the infraorbital canal. The mass also extended to the left masticator space (Fig 1B) via the left foramen ovale. CT in a bone algorithm showed expansion of the left

infraorbital canal (Fig 1C), the left foramen rotundum, and the left foramen ovale. There were no signs of bone destruction.

Laboratory work-up results were all within normal limits. Tumor markers were also negative. Chest, abdominal, and pelvic CT findings were unremarkable.

The mass in the left retromaxillary area was surgically biopsied. Histologic evaluation showed nerve fibers (Fig 2A, *arrowhead*) surrounded by an attenuated inflammatory infiltrate (Fig 2B) comprising predominantly B and T lymphocytes with moderate fibrosis. Immunohistochemistry indicated abundant IgG4+ plasma cell infiltration (128/HPF) in and around the aggregates of lymphocytes (Fig 2C) and high ratios of IgG4+/IgG+ plasma cells (71%). There was no evidence of atypia or neoplasia. Immunostaining for ALK was negative. The final diagnosis was IgG4-related IPT.

The patient did not seek further treatment. MR imaging studies at 6- and 12-month follow-up showed no significant changes.

Discussion

The etiology of IPT is still unclear but is thought to be infectious or autoimmune in nature. IPT is histologically characterized by a proliferation of spindle cells such as fibroblasts and myofibroblasts, admixed with inflammatory components consisting of lymphocytes, plasma cells, eosinophils, and histiocytes. However, the cell population can vary from one tumor to another or even from one microscopic field to another within the individual tumor.

Historically, IPT has been designated under various synonyms, such as plasma cell granuloma, xanthogranuloma, histiocytoma, and IMT. IMT is now considered as a “distinctive neoplastic proliferation” composed predominantly of myofibroblasts.³ Recent studies have revealed ALK gene rearrangements in IMT, suggesting a neoplastic cause, though, not all IMTs are positive for ALK by immunohistochemistry. Our case showed predominant lymphocyte proliferation with reactive fibrosis. Myofibroblastic spindle cells did not show cytologic atypia, and immunostaining for ALK was negative.

Recently, some populations of IPTs of the liver⁴ and lung⁵ have been reported to show pathologic characteristics similar to those of IgG4-related sclerosing disease as they involved lymphoplasmacytic infiltration and high IgG4+ plasma cell infiltrates. IgG4-related IPTs are occasionally complicated

Received June 2, 2010; accepted June 20.

From the Departments of Radiology (M.K., T.M.), Neurosurgery (A.M.), and Pathology (H.H.), NTT Medical Center Tokyo, Tokyo, Japan; and Department of Radiology (M.K., K.O.), Graduate School of Medicine, University of Tokyo, Tokyo, Japan.

Paper previously presented in part at: Annual Meeting of the Japanese Society of Neuroradiology, February 12, 2010; Tokyo; Japan.

Please address correspondence to Masaki Katsura, MD, Department of Radiology, Graduate School of Medicine, University of Tokyo, 7-3-1 Hongo, Bunkyo-ku, Tokyo 113-0033, Japan; e-mail: mkatsura-ty@umin.ac.jp



Indicates open access to non-subscribers at www.ajnr.org

<http://dx.doi.org/10.3174/ajnr.A2256>

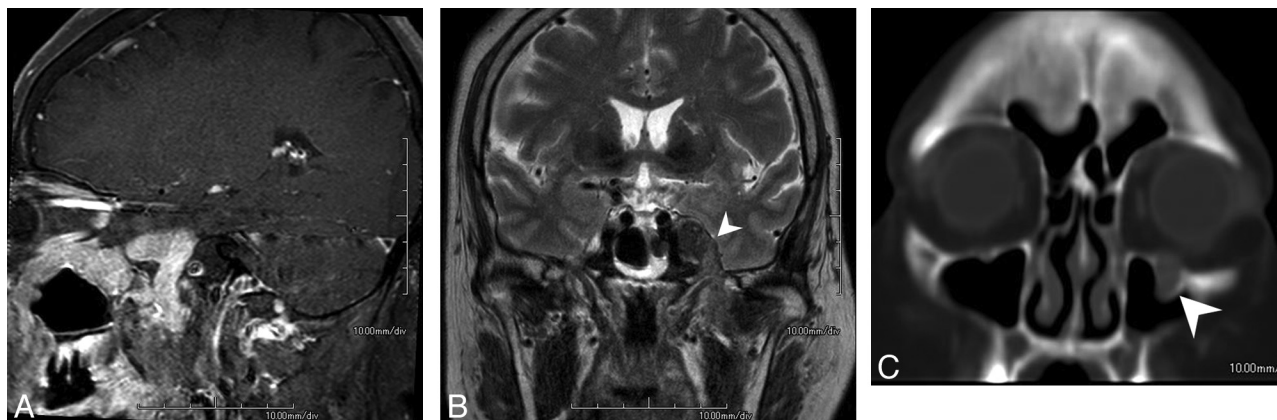

Fig 1. A, MR image reveals a homogeneously enhancing soft-tissue mass involving the skull base along the second and third divisions of the left trigeminal nerve. B, T2-weighted image demonstrates a hypointense mass (arrowhead) extending to the left masticator space via the left foramen ovale. C, CT scan in a bone algorithm shows enlargement of the left infraorbital canal (arrowhead).

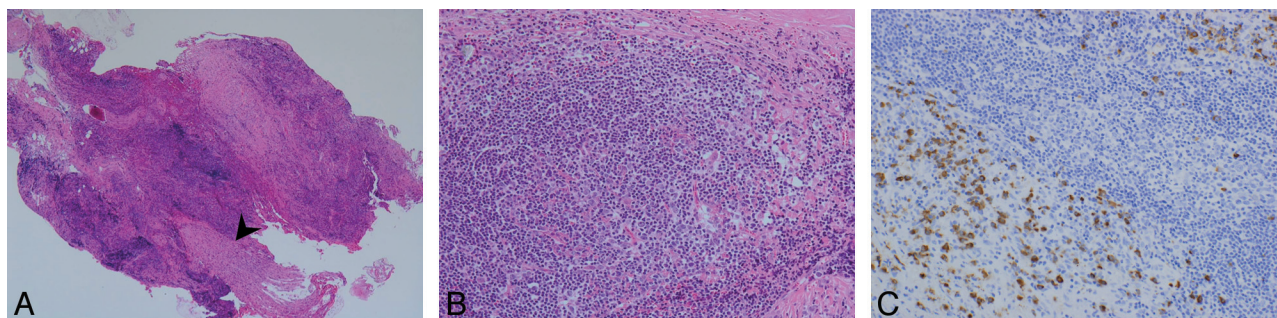


Fig 2. A and B, Pathologic specimen in low power (A, magnification $\times 40$) and high power (B, magnification $\times 200$). Note nerve fibers (A, arrowhead) surrounded by an attenuated inflammatory infiltrate (B) with moderate fibrosis. C, (magnification $\times 200$). Immunohistochemistry indicates abundant IgG4-positive plasma cell infiltration (128/HPF) in and around the aggregates of lymphocytes and high ratios of IgG4+/IgG+ plasma cells ($>71\%$).

with IgG4-related pancreatitis and sialadenitis, suggesting that these types of IPTs may form part of the spectrum of systemic IgG4-related sclerosing disease.

There is currently no consensus on the number of IgG4+ plasma cells required for the diagnosis of IgG4-related IPT; however, several reports recommend that the ratio of IgG4+/IgG+ cells is also important for the diagnosis.^{4,5} According to the literature, IgG4+ cells >60 – 100 /HPF and the ratio of IgG4+/IgG+ cells $>40\%$ – 50% seem to be highly suggestive of IgG4-related disease. Yamamoto et al⁶ recently reported that both of these values are significantly lower in IMTs than in IgG4-related lesions. In our case, the number of IgG4+ plasma cells per HPF was 128, and the ratio of IgG4+/IgG+ cells was 71%.

In the head and neck region, IgG4-related IPTs of the salivary glands, lacrimal glands, and pituitary glands are well known; however, nasal/paranasal,⁷ dura mater,⁸ and parapharyngeal space⁹ lesions have also been reported. Our report describes a case of IgG4-related IPT of the trigeminal nerve without involvement of any of the preferential organs. Seol et al¹⁰ described another case of skull base IPT, which showed perineural spread along the trigeminal nerve, very similar to our case. However, no attempt was made to investigate the possible linkage with IgG4-related systemic disease or to characterize the plasma cell immunophenotype.

Imaging findings of IPT, including IgG4-related IPT, frequently reveal a homogeneously enhancing soft-tissue mass. On T2-weighted images, the mass is usually iso- to hypo-

intense relative to brain. This can possibly be explained by the combination of fibrosis and attenuated cellularity of IPTs, which may also explain why IPTs tend to appear hyperintense on DWI. Attempts to differentiate IPTs from cancer¹¹ and lymphoma¹² on DWI have been made. However, the various degrees of cellularity, fibrosis, and perfusion in IPTs account for differences in diffusion restriction and often make the diagnosis difficult. IPTs with bone involvement and internal carotid artery encasement have also been reported in the past,^{13,14} including pathologically proved IgG4-related IPTs.⁷ In addition to these imaging features, our patient also had extensive perineural spread along the trigeminal nerve, highly suggestive of a neoplastic process.

IgG4-related IPT generally has a benign clinical course. These lesions usually respond to corticosteroids; however, relapse rates range from 30% to 40%.¹⁵ For unresponsive IPTs, surgical resection may be considered. Our patient did not seek further treatment. Her symptoms and follow-up MR images have not shown significant changes. However, a recent report suggests that there is a frequency of lymphomatous transformation in 10% of cases,¹⁶ adding yet another reason for close long-term surveillance.

References

- Hamano H, Kawa S, Horiuchi A, et al. High serum IgG4 concentrations in patients with sclerosing pancreatitis. *N Engl J Med* 2001;344:732–38
- Tanabe T, Tsumura K, Yasuo M, et al. IgG4-associated multifocal systemic fibrosis complicating sclerosing sialadenitis, hypophysitis, and retroperito-

- neal fibrosis, but lacking pancreatic involvement. *Intern Med* 2006;45:1243–47. Epub 2006 Dec 1
3. Paulus W, Scheithauer BW, Perry A. **Mesenchymal, non-meningothelial tumours.** In: Louis DN, ed. *WHO Classification of Tumours of the Central Nervous System*. 4th ed. Lyon, France: IARC Press; 2007:174–75
 4. Zen Y, Fujii T, Sato Y, et al. **Pathological classification of hepatic inflammatory pseudotumor with respect to IgG4-related disease.** *Mod Pathol* 2007;20: 884–94
 5. Zen Y, Kitagawa S, Minato H, et al. **IgG4-positive plasma cells in inflammatory pseudotumor (plasma cell granuloma) of the lung.** *Hum Pathol* 2005;36: 710–17
 6. Yamamoto H, Yamaguchi H, Aishima S, et al. **Inflammatory myofibroblastic tumor versus IgG4-related sclerosing disease and inflammatory pseudotumor.** *Am J Surg Pathol* 2009;33:1330–40
 7. Ishida M, Hotta M, Kushima R, et al. **Multiple IgG4-related sclerosing lesions in the maxillary sinus, parotid gland and nasal septum.** *Pathol Int* 2009;59: 670–75
 8. Lui PCW, Fan YS, Wong SS, et al. **Inflammatory pseudotumors of the central nervous system.** *Hum Pathol* 2009;40:1611–17
 9. Maruya S, Miura K, Tada Y, et al. **Inflammatory pseudotumor of the parapharyngeal space: a case report.** *Auris Nasus Larynx* 2010;37:397–400. Epub 2009 Oct 25
 10. Seol JB, Loevner LA, O'Malley BW Jr, et al. **Inflammatory pseudotumor of the trigeminal nerve: a neoplastic mimic you do not want to miss.** *AJNR Am J Neuroradiol* 2009;30:1941–43
 11. Kamisawa T, Takuma K, Anjiki H, et al. **Differentiation of autoimmune pancreatitis from pancreatic cancer by diffusion-weighted MRI.** *Am J Gastroenterol* 2010;105:1870–75
 12. Kapur R, Sepahdari AR, Mafee MF, et al. **MR imaging of orbital inflammatory syndrome, orbital cellulitis, and orbital lymphoid lesions: the role of diffusion-weighted imaging.** *AJNR Am J Neuroradiol* 2009;30:64–70
 13. DeVuysere S, Hermans R, Sciort R, et al. **Extraorbital inflammatory pseudotumor of the head and neck: CT and MR findings in three patients.** *AJNR Am J Neuroradiol* 1999;20:1133–39
 14. Som PM, Brandwein MS, Maldjian C, et al. **Inflammatory pseudotumor of the maxillary sinus: CT and MR findings in six cases.** *AJR Am J Roentgenol* 1994;163:689–92
 15. Hirano K, Tada M, Isayama H, et al. **Long-term prognosis of autoimmune pancreatitis with and without corticosteroid treatment.** *Gut* 2007;56:1719–24
 16. Cheuk W, Yuen HKL, Chan JK. **Complication of IgG4-related chronic sclerosing dacryoadenitis by lymphoma.** *Arch Ophthalmol* 2008;126:1170