

Generic Contrast Agents

Our portfolio is growing to serve you better. Now you have a *choice*.



[VIEW CATALOG](#)

AJNR

Manual Hippocampal Volumetry Is a Better Detector of Hippocampal Sclerosis than Current Automated Hippocampal Volumetric Methods

H.R. Pardoe and G.D. Jackson

This information is current as of May 13, 2025.

AJNR Am J Neuroradiol 2013, 34 (10) E114-E115

doi: <https://doi.org/10.3174/ajnr.A3750>

<http://www.ajnr.org/content/34/10/E114>

Manual Hippocampal Volumetry Is a Better Detector of Hippocampal Sclerosis than Current Automated Hippocampal Volumetric Methods

We read with interest “3T MRI Quantification of Hippocampal Volume and Signal in Mesial Temporal Lobe Epilepsy Improves Detection of Hippocampal Sclerosis,”¹ in which Coan et al presented convincing evidence that quantitative assessment of hippocampal volume and T2 improves detection of hippocampal sclerosis vs visual inspection. Although we agree with the principal findings of the study, we disagree with the statement “whether manual or automatic analysis [of hippocampal volume] has higher sensitivity and specificity is still debatable” (text in square brackets added for clarity). We assert that current methods of automated hippocampal segmentation have poorer sensitivity and specificity than manual hippocampal segmentation for the detection of hippocampal sclerosis. To provide evidence supporting this assertion, we measured left hippocampal volumes in 22 patients with epilepsy with left-lateralized hippocampal sclerosis and 22 age-matched healthy control participants 1) manually and 2) automatically (using FreeSurfer version 5.0; <http://surfer.nmr.mgh.harvard.edu>), and compared the sensitivity and specificity of the 2 techniques. A subset of the MR imaging scans used for this analysis were used in a prior study.²

The sensitivity and specificity are both dependent on the hippocampal volume threshold used to classify participants. The commonly used method of measuring the area under the receiver operating characteristic (ROC) curve was used to assess which method (manual or automated) is a superior detector of hippocampal sclerosis. The ROC curves for manual and automated hippocampal segmentation are provided in the Figure. The area under the ROC curve for manual hippocampal segmentation is higher than automated hippocampal segmentation, indicating that manual segmentation is a superior method for the discrimination of hippocampal sclerosis (Table). Sensitivity and specificity are greater for manual segmentation than automated when each other's measure is set at 0.95. In our opinion, the superiority of manual segmentation vs current automated methods, particularly in pathologic conditions such as hippocampal sclerosis, is widely accepted by the image-processing community and is not particularly controversial.

The most important caveat to attach to this analysis is that the discriminative ability of automated, manual, and visual-based

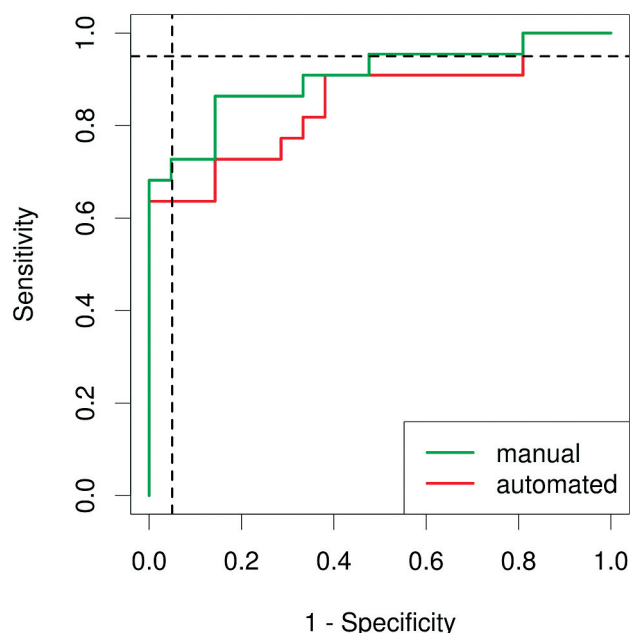


FIGURE. ROC curves for manual segmentation (green line) and automated segmentation (red line) in hippocampal sclerosis. The area under the ROC curve is higher for manual segmentation, indicating that it is a superior method to classify hippocampal sclerosis. The vertical dashed line indicates a specificity of 0.95 and shows that the sensitivity is higher for manual segmentation; in a likewise fashion, the horizontal dashed line indicates a sensitivity of 0.95 and shows that the specificity is higher for manual segmentation.

Manual and automated hippocampal volume as a classifier of hippocampal sclerosis

Hippocampal Volume	AUC	Sensitivity (Specificity, 0.95)	Specificity (Sensitivity, 0.95)
Manual	0.9	0.72	0.52
Automated	0.85	0.63	0.19

Note.—The higher AUC for manual assessment indicates that the method has superior sensitivity and specificity over a range of volume thresholds. Example sensitivities and specificities are provided. AUC indicates area under the ROC curve.

methods is likely to improve as MR imaging acquisitions improve. Nevertheless, we believe that manual hippocampal segmentation would likely improve the ability of quantitative methods to detect hippocampal sclerosis above the 28% improvement presented by Coan et al.¹

In summary, we have presented evidence that manual hippocampal segmentation has higher sensitivity and specificity and is a better detector of hippocampal sclerosis than current automated hippocampal segmentation methods.

REFERENCES

1. Coan, AC, Kubota B, Bergo FP, et al. 3T MRI quantification of hippocampal volume and signal in mesial temporal lobe epilepsy im-

- proves detection of hippocampal sclerosis. *AJNR Am J Neuroradiol* 2013 Jul 18. [Epub ahead of print]
2. Pardoe HR, Pell GS, Abbott DF, et al. Hippocampal volume assessment in temporal lobe epilepsy: How good is automated segmentation? *Epilepsia* 2009;50:2586–92

H.R. Pardoe

New York University School of Medicine
New York, New York

G.D. Jackson

The Florey Institute of Neuroscience and Mental Health
Heidelberg, Victoria, Australia