

Generic Contrast Agents

Our portfolio is growing to serve you better. Now you have a *choice*.



[VIEW CATALOG](#)

AJNR

What Does the Boxed Warning Tell Us? Safe Practice of Using Ferumoxytol as an MRI Contrast Agent

C.G. Varallyay, G.B. Toth, R. Fu, J.P. Netto, J. Firkins, P. Ambady and E.A. Neuwelt

This information is current as of May 17, 2025.

AJNR Am J Neuroradiol 2017, 38 (7) 1297-1302

doi: <https://doi.org/10.3174/ajnr.A5188>

<http://www.ajnr.org/content/38/7/1297>

What Does the Boxed Warning Tell Us? Safe Practice of Using Ferumoxytol as an MRI Contrast Agent

C.G. Varallyay, G.B. Toth, R. Fu, J.P. Netto, J. Firkins, P. Ambady, and E.A. Neuwelt



ABSTRACT

BACKGROUND AND PURPOSE: Despite the label change and the FDA's boxed warning added to the Feraheme (ferumoxytol) label in March 2015, radiologists have shown increasing interest in using ferumoxytol as an MR imaging contrast agent as a supplement or alternative to gadolinium. The goals of this study were to provide information regarding ferumoxytol safety as an imaging agent in a single center and to assess how the Feraheme label change may affect this potential, currently off-label indication.

MATERIALS AND METHODS: This retrospective study evaluated the overall frequency of ferumoxytol-related adverse events when used for CNS MR imaging. Patients with various CNS pathologies were enrolled in institutional review board–approved imaging studies. Ferumoxytol was administered as multiple rapid bolus injections. The risk of adverse events was correlated with demographic data/medical history.

RESULTS: The safety of 671 ferumoxytol-enhanced MR studies in 331 patients was analyzed. No anaphylactic, life-threatening, or fatal (grade 4 or 5) adverse events were recorded. The overall proportion of ferumoxytol-related grade 1–3 adverse events was 10.6% (8.6% occurring within 48 hours), including hypertension (2.38%), nausea (1.64%), diarrhea (1.04%), and headache (1.04%). History of 1 or 2 allergies was associated with an increased risk of adverse events (14.61% versus 7.51% [no history]; $P = .007$).

CONCLUSIONS: The frequency of mild ferumoxytol-related adverse events was comparable with literature results, and no serious adverse event was recorded. Although the recommendations in the boxed warning should be followed, serious adverse events appear to be rare, and with proper precautions, ferumoxytol may be a valuable MR imaging agent.

ABBREVIATIONS: AE = adverse event; CTCAE = Common Terminology Criteria for Adverse Events; HSR = hypersensitivity reaction

Ferumoxytol, marketed as Feraheme (AMAG Pharmaceuticals, Waltham, Massachusetts), is an ultra-small iron oxide nanoparticle approved to treat iron deficiency anemia in adults with chronic kidney disease.¹ Because of its superparamagnetic prop-

erties, ferumoxytol can be used as an MR imaging contrast agent.² Despite the label change and the FDA's boxed warning about possible serious hypersensitivity reactions (HSR) added to the Feraheme label in March 2015, radiologists have shown increasing interest in using ferumoxytol as an MR imaging contrast agent because the long plasma half-life and the lack of early leakage allow imaging of the intravascular space early after injection.^{3–7} Delayed MR imaging (24 hours after ferumoxytol administration) shows blood-brain barrier defects similar to gadolinium agents, which makes it a potential alternative if gadolinium-based contrast agents are contraindicated.^{8,9} Delayed ferumoxytol imaging can also take advantage of intracellular uptake of the nanoparticles to image inflammation¹⁰ or assess the lymph nodes for tumor staging.^{11–14}

There are limited safety data of ferumoxytol as an MR imaging contrast agent in the literature. A recent study analyzing 65 cases of children and young adults from institutional review board–approved imaging studies concluded that ferumoxytol was well tolerated as an MR imaging agent.¹⁵ Another publication re-

Received December 22, 2016; accepted after revision February 17, 2017.

From the Departments of Radiology (C.G.V., J.P.N.), Neurology (C.G.V., G.B.T., J.P.N., J.F., P.A., E.A.N.), Medical Informatics and Clinical Epidemiology (R.F.), and Neurosurgery (E.A.N.) and School of Public Health (R.F.), Oregon Health & Science University, Portland, Oregon; and Portland Veterans Affairs Medical Center (E.A.N.), Portland, Oregon.

This work was supported by National Institutes of Health grants NS053468, CA199111, and CA137488-1S51, in part with Federal funds from the National Cancer Institute, National Institutes of Health, under Contract No. HHSN261200800001E, and by the Walter S. and Lucienne Driskill Foundation (all to E.A.N.).

Paper previously presented at: Annual Meeting of the Radiological Society of North America, November 29–December 4, 2015; Chicago, Illinois.

Please address correspondence to Edward A. Neuwelt, MD, Oregon Health & Science University, 3181 SW Sam Jackson Park Rd, L603, Portland, OR 97239; e-mail: neuwelte@ohsu.edu

Indicates open access to non-subscribers at www.ajnr.org

Indicates article with supplemental on-line tables.

<http://dx.doi.org/10.3174/ajnr.A5188>

ported a single anaphylactoid reaction in 2000 off-label uses of ferumoxytol for MR imaging,¹⁶ whereas a recently published single-center investigation with 217 patients showed no serious adverse events (AEs) with the diagnostic use of ferumoxytol.¹⁷ Our institution has more than 10 years of experience using ferumoxytol as an MR imaging contrast agent in the CNS in patients with or without compromised renal function and, as of December 31, 2015, had completed 671 MR imaging studies with ferumoxytol in 8 institutional review board–approved imaging protocols in which AEs were closely monitored. These are the largest single-institution safety data of ferumoxytol used in imaging research protocols. Detailed demographic information was collected, and patients were followed-up for 6 weeks after ferumoxytol administration. The goals of this study were to provide information regarding the safety of ferumoxytol as an MR imaging contrast agent and to assess how the ferumoxytol label change may affect this potential, currently off-label indication.

MATERIALS AND METHODS

Ferumoxytol Administration

This retrospective, single-center study analyzed the safety data of 671 ferumoxytol injections in 331 patients between June 2004 and December 2015. The average age of the patients was 51.08 years (SD, ± 16.82 years), and the female-male ratio was 1:1.33. All patients signed informed consent and were enrolled in 1 of the 8 institutional review board–approved ferumoxytol imaging protocols (On-line Table 1).

In all cases, ferumoxytol was given during MR imaging by using 1 or multiple IV bolus injections (1:1 or 1:2 diluted ferumoxytol, 3 mL/s flow rate, with 20-mL saline flush at the same flow rate). In most studies, the first 1 mg/kg (or 75 mg) was used for dynamic perfusion imaging, with the remaining dose administered in 1 or 2 subsequent bolus injections. The full 4–7 mg/kg or 510 mg was never given as a single injection. Subsequent to the label changes and boxed warning, infusion parameters were modified in all protocols, as Fig 1 indicates. Patients were evaluated for AEs after each ferumoxytol injection. Blood pressure, pulse, and oxygen saturation were recorded before and after each injection. Patients were observed for at least 30 minutes after the completion of ferumoxytol administration. A research nurse or physician was always present during ferumoxytol administration, the postcontrast MR imaging acquisition, and the following observation period.

Recording Adverse Events

Data on AEs were recorded according to Common Terminology Criteria for Adverse Events v3.0 or v4.0 (CTCAE),^{18,19} including the description of the toxicity event, toxicity category, toxicity grade, time of occurrence after ferumoxytol injection, and toxicity attribute. Attribute describes the likelihood that the AE was caused by ferumoxytol based on clinical judgment and has 5 categories: 1, unrelated; 2, unlikely; 3, possible; 4, probably; and 5, definite. We only included AEs that occurred within 6 weeks (42 days) of each ferumoxytol injection. Patients were contacted by phone by a research nurse or completed a clinic visit 6 weeks after administration of ferumoxytol to assess for any AEs. Patient characteristics such as age, race, sex, existence of allergies, steroid use, pathology, and administered ferumoxytol dose were also re-

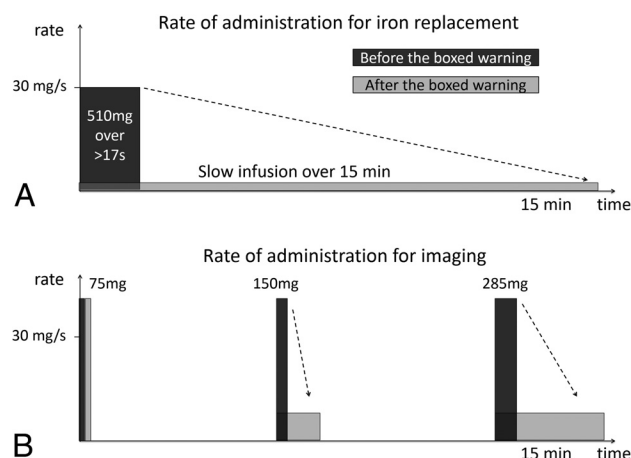


FIG 1. Rate of ferumoxytol administration; for iron replacement (A), the prior label allowed bolus injection of 510 mg of ferumoxytol not faster than 17 seconds (equivalent to 30 mg/s Fe). The current label recommends slow infusion of diluted ferumoxytol over 15 minutes. For imaging, which is still an off-label indication, we used to administer ferumoxytol in 2 or 3 rapid bolus injections. Panel B shows ferumoxytol administration of protocol #1562, in which a full vial of 510 mg was given. As a response to the boxed warning, only the initial 75 mg is injected as before (3 mL/s of 1:1 diluted ferumoxytol, equivalent to 45 mg/s Fe), and dynamic perfusion data are acquired. The other ongoing protocols have been adjusted accordingly; only the first 1 mg/kg being injected as a bolus.

corded. On-line Table 2 shows the potential AEs with ferumoxytol classified to CTCAE and FDA categories. Note that CTCAE grade 3 (severe) AEs may or may not be serious based on FDA classification.^{18–20} Serious AEs are associated with specific outcomes (eg, life-threatening or hospitalization). In contrast, a “severe nosebleed” may not qualify as being categorized as serious.

Statistical Methods

Descriptive statistics were used to summarize patient demographics and clinical characteristics. AEs with an attribute of 3, 4, or 5 were characterized, including at least 1 AE in an infusion, early AE (occurring within 48 hours of ferumoxytol administration), and AE by event type by using proportions. Association between at least 1 AE in an infusion and patient characteristics was assessed by using a logistic generalized estimating equation model while taking into account the correlation of multiple infusions within a patient. The statistical package SAS 9.4 (SAS Institute, Cary, North Carolina) was used.

RESULTS

Among the 671 ferumoxytol infusions, grade 1, 2, or 3 AEs occurred in 71 infusions (10.6%) recorded within 6 weeks. Most AEs occurred within 48 hours after ferumoxytol infusion (in 58 cases [8.6% of the infusions]). There were no life-threatening or fatal (grade 4 or 5) AEs. The most frequent mild and moderate AEs were hypertension (2.38%), nausea (1.64%), diarrhea (1.04%), and headache (1.04%) (Fig 2). Only 2 grade 3 AEs were recorded (0.30%). One patient had a rapid rash on his trunk, both upper extremities, and thighs after the imaging. He received IV dexamethasone, and after several hours of observation, all symptoms disappeared with no further treatment needed. Another patient, who developed red sclera with burning/tingling sensation after an otherwise uneventful ferumoxytol MR imaging, returned for a

second study visit 6 months later. Immediately after the initial 1 mg/kg ferumoxytol administration, he reported severe nausea and moderate degree of shortness of breath along with lower back pain. The patient was removed from the scanner, and no further ferumoxytol was given. He was treated with albuterol and diphenhydramine, and the symptoms completely subsided after 2 hours.

In the logistic generalized estimating equation model, patients with 1 or 2 pre-existing allergies were more likely to have at least 1 AE after ferumoxytol infusion compared with patients without any pre-existing allergy (14.6% versus 7.5%; $P = .007$). No other patient characteristics showed significant association with the occurrence of AE (Table 1).

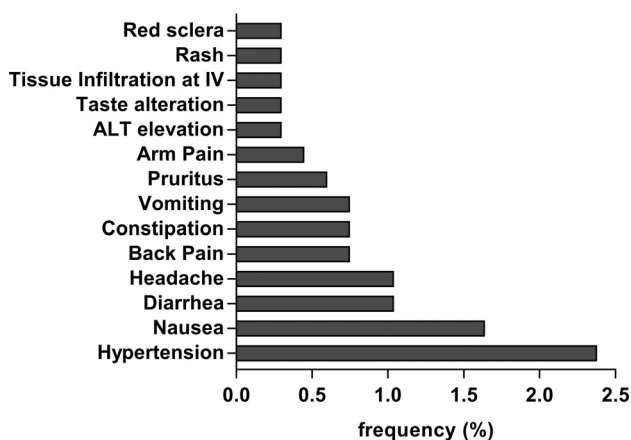


FIG 2. Frequency of AEs potentially related to ferumoxytol. Events that occurred in at least 2 cases are displayed. Note that multiple AEs (symptoms, abnormal lab values) may be associated with a single injection according to the CTCAE recording guidelines.

Table 1: Patient characteristics

Characteristics	Infusions, No.	Infusions With At Least 1 Event	% of Infusions With At Least 1 Event	Odds Ratio	P Value ^a
Age					
<70 yrs	634	67	10.6	Reference	.91
>70 yrs	37	4	10.8	1.06 (0.37, 3.02)	
Race					
White	645	68	10.5	Reference	.87
Non-white	26	3	11.5	1.10 (0.35, 3.50)	
Gender					
Female	272	33	12.1	Reference	.38
Male	399	38	9.5	0.79 (0.47, 1.33)	
Number of existing allergies					
0	333	25	7.5	Reference	.026 ^b
1 or 2	268	39	14.6	2.13 (1.23, 3.70)	.007 ^c
>2 allergies	70	7	10	1.35 (0.58, 3.17)	.49
Ferumoxytol dose					
≤2 mg/kg	121	8	6.6	Reference	.40 ^b
2–4 mg/kg	303	34	11.2	1.77 (0.69, 4.54)	.23
>4 mg/kg	247	29	11.7	1.86 (0.75, 4.58)	.18
Steroid use					
None	461	44	9.5	Reference	.13
On decadron	183	25	13.7	1.56 (0.92, 2.67)	
Pathology					
Non-tumor	54	5	9.3	Reference	.71
Tumor	617	66	10.7	1.20 (0.47, 3.04)	

^a P values are obtained from the logistic generalized estimating equation model.

^b Overall P value for the number of existing allergies or ferumoxytol dose.

^c Statistically significant.

DISCUSSION

Contrast materials are frequently used in imaging and provide valuable information, often changing the course of treatment. Contrast agents are known to be generally safe, with minimal risk of HSR.²¹ Our results showed that overall ferumoxytol-related AE occurred in 10.6% of infusions, most of them occurring within 48 hours (8.6%), in concordance with 10%–14.6% of AE published in the literature based on 3 randomized trials for iron replacement.^{22–24} Based on our data, the frequency of AE with Feraheme is equivalent to ionic iodinated contrast media, approximately 15 times higher than gadolinium MR contrast agents, and 4 times higher than non-ionic iodinated contrast agents,^{25,26} which is summarized in Table 2. Severe reactions, based on literature data, occur 6–7 times more often with ferumoxytol compared with gadolinium or currently used nonionic iodinated agents.

At our institution, we have not recorded any serious AEs with ferumoxytol. However, we acknowledge that our sample size may not be adequate to record this rare event. It is worth mentioning that our patient population may differ from populations reported in prior studies because most of our patients had brain tumors; it has been shown that patients with tumor can be anergic^{27–29} and are often on corticosteroids, which may cause immunosuppression and, in theory, help prevent HSR.³⁰ Our results, however, did

Table 2: Frequency of adverse events using various contrast media from the literature and our data

Contrast Media	Adverse Events	Severe Adverse Events
Gadolinium ²⁵	0.8%	0.03%
Iodinated (ionic) ²⁶	12.66%	0.22%
Iodinated (nonionic) ²⁶	3.13%	0.04%
Ferumoxytol (Feraheme label)	3.7%	0.2%
Ferumoxytol (our data)	10.6%	0%

not show any risk reduction in patients with long-term corticosteroid use, nor in those with tumor pathology. The benefit of premedication before IV iron products remains controversial in the literature and is generally not advised.³¹

Although the 2 grade 3 reactions were possibly HSR-related, most of the AEs recorded in this study are likely unrelated to HSR. Hypertension, recorded most frequently after ferumoxytol injection, may be anxiety-related, which normalized without intervention by the time the patient left the MR imaging suite. No ferumoxytol-related blood pressure drop has been detected. Our study found a significant association between 1 or 2 existing allergies and the frequency of mild AEs. The exact mechanism of iron HSR is still unclear. Bioactive, labile iron, which is present in all IV iron products, may be an important causative factor. Complement activation-related pseudoallergy, triggered by iron nanoparticles, is probably a more frequent mechanism in acute reactions to current IV formulations than is an immunologic IgE-mediated response.³²

The boxed warning of Feraheme is intended to mitigate the risk and potential morbidity of HSR, thus enhancing patient safety. Recommendations are to observe patients up to 30 minutes after injection and monitor heart rate and blood pressure at baseline and after (each) ferumoxytol administration, which was re-emphasized in this warning and which we strictly adhere to in our imaging protocols. Rapid bolus injection (previously up to 30 mg/s) was eliminated from the package insert, and infusion of the diluted ferumoxytol over 15 minutes became the recommendation. Although there are currently no data using ferumoxytol to support that slow infusion is indeed safer than bolus injection, slow infusion is recommended with other iron products³² and it also allows observation of the patient during ferumoxytol administration and termination of the infusion if HSR occurs.

For MR imaging, to best comply with FDA recommendations, rapid bolus should be avoided. Our imaging protocols have eliminated rapid injection, and only the first 1 mg/kg is given as a bolus to gain clinically valuable dynamic imaging data. The lack of contrast agent leakage has been demonstrated as a benefit compared with low molecular weight agents, though the latter ones may be corrected with mathematical algorithms.³³ For most imaging applications, such as high-resolution steady-state blood volume mapping, steady-state angiography, and visualization of delayed ferumoxytol enhancement/inflammation, no bolus injection is necessary; therefore, high flow rate injection may be completely avoided.

The new prescribing information as of March 2015 provides additional information regarding the potential for more severe HSR in elderly patients with multiple or serious comorbidities and increased risk of HSR to Feraheme in patients with a history of multiple drug allergies. This information may be useful when considering risk and benefit.

A detailed analysis and guideline have been published by an international group to minimize the risk and severity of IV iron supplement-related AEs. There is emphasis on observation, prompt recognition of symptoms, and severity-related interventions by well-trained medical and nursing staff.³² On-line Table 3 summarizes our recommendations in managing hypersensitivity related to IV iron, when used as an MR contrast agent.

Contrast agent safety is a relevant clinical issue. HSR is just one of the contrast agent-related AEs; in gadolinium-based agents, the incidence of nephrogenic systemic fibrosis has been minimized since the guidelines and boxed warning. Given the emerging safety record of macrocyclic contrast agents in patients with renal failure, remaining contraindications are rare and limited essentially to a history of rare severe allergic reaction to gadolinium-based agents. Gadolinium deposition in the nervous system is a recent finding, which occurs even in patients with normal renal function, and its clinical impact is still unknown.³⁴ Although no serious AE with ferumoxytol was observed in 671 administrations at our institution, it is important to understand the potential risks and be prepared in case a severe reaction occurs. Having trained staff and appropriate medications available would be considered good medical practice in any facility using any imaging contrast agent.

The limitations of ferumoxytol imaging include potential iron overload in patients with iron metabolism disorders. The maximum administered dose (510 mg) is equivalent with 2 units of blood, which is unlikely to cause acute or chronic toxicity in patients with normal iron metabolism.¹⁵ Ferumoxytol is taken up by the liver, spleen, and bone marrow, which may cause signal change on the MR imaging for months. In the CNS, contrast enhancement may be detectable a few days after administration. Adding another contrast agent (ie, if used in addition to gadolinium-based contrast agents) may increase the costs, in addition to MR imaging time, if additional imaging is used. Our research protocols included up to 3 consecutive days of scanning, and MR imaging times were long: between 60–90 minutes on days when contrast agent was given and 30–45 minutes to image late ferumoxytol enhancement. In clinical practice, however, more focused imaging is applied to answer the clinical question. High-resolution blood volume maps may be obtained with only an additional 5 minute scan time.⁵ Steady-state angiography requires only a few minutes of scan time, whereas late enhancement/imaging inflammation/lymph node imaging requires a separate MR imaging scanning session, which is likely the length of a noncontrast MR imaging study. Multiphase contrast administration was used to test the optimal doses for various applications, but in clinical use, a single infusion of the most appropriate dose is sufficient. Applications, such as visualizing the micro- and macrovasculature and visualizing inflammation, hold promise, but future trials have to prove their impact on improving clinical diagnosis and clinical management.

Limitations of this study include the variable patient characteristics and ferumoxytol doses. Although our sample size of 671 was the highest reported in a single center, this number is still too low to evaluate the frequency of rare, but serious HSR.

CONCLUSIONS

The safety of 671 well-documented cases of using ferumoxytol as an MR imaging agent was reported in this study. The overall occurrence of AEs is in agreement with prior ferumoxytol safety studies, and no serious AE was observed. Although the AE is more frequent compared with gadolinium, and there may be increased costs, emerging new MR imaging applications may justify the use of ferumoxytol as an MR imaging contrast agent. The recommen-

dations in the boxed warning should be followed to further improve the safety of imaging with ferumoxytol.

Disclosures: Rongwei Fu—UNRELATED: Grants/Grants Pending: Oregon Health & Science University*. Jenny Firkins—RELATED: Grants/Grants Pending: Driskill Foundation grant and R01*; UNRELATED: Employment: Driskill Foundation grant and R01. Edward Neuwelt—RELATED: Grants/Grants Pending: National Institutes of Health, Driskill Foundation, Comments: This work was supported in part by National Institutes of Health grants NS053468, CA199111, and CA137488–1S1, in part with Federal funds from the National Cancer Institute, National Institutes of Health, under Contract No. HHSN261200800001E, and by the Walter S. and Lucienne Driskill Foundation, all to E.A.N.; UNRELATED: Grants/Grants Pending: AMAG Pharmaceuticals, Comments: Dr. Neuwelt's studies involving ferumoxytol were entirely funded by National Institutes of Health research grants and the Driskill Foundation, with the ferumoxytol ultra-small superparamagnetic iron oxide nanoparticles donated by AMAG Pharmaceuticals. Oregon Health & Science University has received a small sponsored research agreement from AMAG Pharmaceuticals to partially fund clinical trials of MRI with ferumoxytol. None of the authors has financial interest in this agent or in its developer AMAG Pharmaceuticals.* Money paid to the institution.

REFERENCES

- Lu M, Cohen MH, Rieves D, et al. **FDA report: ferumoxytol for intravenous iron therapy in adult patients with chronic kidney disease.** *Am J Hematol* 2010;85:315–19 CrossRef Medline
- Bashir MR, Bhatti L, Marin D, et al. **Emerging applications for ferumoxytol as a contrast agent in MRI.** *J Magn Reson Imaging* 2015;41:884–98 CrossRef Medline
- Hope MD, Hope TA, Zhu C, et al. **Vascular imaging with ferumoxytol as a contrast agent.** *AJR Am J Roentgenol* 2015;205:W366–73 CrossRef Medline
- Nayak AB, Luhan A, Hanudel M, et al. **High-resolution, whole-body vascular imaging with ferumoxytol as an alternative to gadolinium agents in a pediatric chronic kidney disease cohort.** *Pediatr Nephrol* 2015;30:515–21 CrossRef Medline
- Varallyay CG, Nesbit E, Fu R, et al. **High-resolution steady-state cerebral blood volume maps in patients with central nervous system neoplasms using ferumoxytol, a superparamagnetic iron oxide nanoparticle.** *J Cereb Blood Flow Metab* 2013;33:780–86 CrossRef Medline
- Christen T, Ni W, Qiu D, et al. **High-resolution cerebral blood volume imaging in humans using the blood pool contrast agent ferumoxytol.** *Magn Reson Med* 2013;70:705–10 CrossRef Medline
- Finn JP, Nguyen KL, Han F, et al. **Cardiovascular MRI with ferumoxytol.** *Clin Radiol* 2016;71:796–806 CrossRef Medline
- Neuwelt EA, Hamilton BE, Varallyay CG, et al. **Ultrasmall superparamagnetic iron oxides (USPIOs): a future alternative magnetic resonance (MR) contrast agent for patients at risk for nephrogenic systemic fibrosis (NSF)?** *Kidney Int* 2009;75:465–74 CrossRef Medline
- Neuwelt EA, Varallyay CG, Manninger S, et al. **The potential of ferumoxytol nanoparticle magnetic resonance imaging, perfusion, and angiography in central nervous system malignancy: a pilot study.** *Neurosurgery* 2007;60:601–11; discussion 611–12 CrossRef Medline
- Storey P, Arbini AA. **Bone marrow uptake of ferumoxytol: a preliminary study in healthy human subjects.** *J Magn Reson Imaging* 2014;39:1401–10 CrossRef Medline
- Guthrie PJ, Thomas JV, Peker D, et al. **Perivesical unicentric Castleman disease initially suspected to be metastatic prostate cancer.** *Urol Ann* 2016;8:245–48 CrossRef Medline
- Liu L, Tseng L, Ye Q, et al. **A new method for preparing mesenchymal stem cells and labeling with ferumoxytol for cell tracking by MRI.** *Sci Rep* 2016;6:26271 CrossRef Medline
- Pouw JJ, Grootendorst MR, Bezooijen R, et al. **Pre-operative sentinel lymph node localization in breast cancer with superparamagnetic iron oxide MRI: the SentiMAG Multicentre Trial imaging subprotocol.** *Br J Radiol* 2015;88:20150634 CrossRef Medline
- Wang YX. **Current status of superparamagnetic iron oxide contrast agents for liver magnetic resonance imaging.** *World J Gastroenterol* 2015;21:13400–02 CrossRef Medline
- Muehe AM, Feng D, von Eyben R, et al. **Safety report of ferumoxytol for magnetic resonance imaging in children and young adults.** *Invest Radiol* 2016;51:221–27 CrossRef Medline
- Vasanawala SS, Nguyen KL, Hope MD, et al. **Safety and technique of ferumoxytol administration for MRI.** *Magn Reson Med* 2016;75:2107–11 CrossRef Medline
- Nguyen KL, Yoshida T, Han F, et al. **MRI with ferumoxytol: a single center experience of safety across the age spectrum.** *J Magn Reson Imaging* 2017;45:804–12 CrossRef Medline
- Common Terminology Criteria for Adverse Events v3.0 (CTCAE).** Published August 9, 2006. https://ctep.cancer.gov/protocolDevelopment/electronic_applications/docs/ctcae3.pdf. Accessed April 3, 2017
- Common Terminology Criteria for Adverse Events (CTCAE) Version 4.0.** Published 2010. https://ctep.cancer.gov/protocolDevelopment/electronic_applications/ctc.htm. Accessed April 3, 2017
- What is a serious adverse event? U.S. Food and Drug Administration. <https://www.fda.gov/safety/medwatch/howtoreport/ucm053087.htm>. Accessed May 4, 2017
- Brockow K, Sánchez-Borges M. **Hypersensitivity to contrast media and dyes.** *Immunol Allergy Clin North Am* 2014;34:547–64, viii CrossRef Medline
- Vadhan-Raj S, Strauss W, Ford D, et al. **Efficacy and safety of IV ferumoxytol for adults with iron deficiency anemia previously unresponsive to or unable to tolerate oral iron.** *Am J Hematol* 2014;89:7–12 CrossRef Medline
- MacDougall IC, Strauss WE, McLaughlin J, et al. **A randomized comparison of ferumoxytol and iron sucrose for treating iron deficiency anemia in patients with CKD.** *Clin J Am Soc Nephrol* 2014;9:705–12 CrossRef Medline
- Hetzel D, Strauss W, Bernard K, et al. **A phase III, randomized, open-label trial of ferumoxytol compared with iron sucrose for the treatment of iron deficiency anemia in patients with a history of unsatisfactory oral iron therapy.** *Am J Hematol* 2014;89:646–50 CrossRef Medline
- Bleicher AG, Kanal E. **Assessment of adverse reaction rates to a newly approved MRI contrast agent: review of 23,553 administrations of gadobenate dimeglumine.** *AJR Am J Roentgenol* 2008;191:W307–11 CrossRef Medline
- Katayama H, Yamaguchi K, Kozuka T, et al. **Adverse reactions to ionic and nonionic contrast media. A report from the Japanese Committee on the Safety of Contrast Media.** *Radiology* 1990;175:621–28 CrossRef Medline
- Evans C, Dalgleish AG, Kumar D. **Review article: immune suppression and colorectal cancer.** *Aliment Pharmacol Ther* 2006;24:1163–77 CrossRef Medline
- Kawakami Y, Yaguchi T, Sumimoto H, et al. **Cancer-induced immunosuppressive cascades and their reversal by molecular-targeted therapy.** *Ann N Y Acad Sci* 2013;1284:80–86 CrossRef Medline
- Pumhirun P, Wasuwat P. **Anergy testing in patients with head and neck cancer.** *Asian Pac J Allergy Immunol* 2003;21:189–92 Medline
- Braaten K, Holcombe RF, Kim SS. **Premedication with IV steroids effectively prevented anaphylactic reactions following ferumoxytol given as IV push in hematology and oncology patients.** *Am J Hematol* 2015;90:E207 CrossRef Medline
- Bircher AJ, Auerbach M. **Hypersensitivity from intravenous iron products.** *Immunol Allergy Clin North Am* 2014;34:707–23, x-xi CrossRef Medline
- Rampton D, Folkersen J, Fishbane S, et al. **Hypersensitivity reactions to intravenous iron: guidance for risk minimization and management.** *Haematologica* 2014;99:1671–76 CrossRef Medline
- Gahramanov S, Muldoon LL, Varallyay CG, et al. **Pseudoprogression of glioblastoma after chemo- and radiation therapy: diagnosis by using dynamic susceptibility-weighted contrast-enhanced perfusion MR imaging with ferumoxytol versus gadoteridol and correlation with survival.** *Radiology* 2013;266:842–52 CrossRef Medline
- Kanda T, Ishii K, Kawaguchi H, et al. **High signal intensity in the dentate nucleus and globus pallidus on unenhanced T1-weighted MR images: relationship with increasing cumulative dose of a gad-**

- olinium-based contrast material. *Radiology* 2014;270:834–41 CrossRef Medline
35. Gahramanov S, Raslan AM, Muldoon LL, et al. **Potential for differentiation of pseudoprogression from true tumor progression with dynamic susceptibility-weighted contrast-enhanced magnetic resonance imaging using ferumoxytol vs. gadoteridol: a pilot study.** *Int J Radiat Incol Biol Phys* 2011;79:514–23 CrossRef Medline
 36. Hamilton BE, Nesbit GM, Dosa E, et al. **Comparative analysis of ferumoxytol and gadoteridol enhancement using T1- and T2-weighted MRI in neuroimaging.** *AJR Am J Roentgenol* 2011;197:981–88 CrossRef Medline
 37. Nasser M, Gahramanov S, Netto JP, et al. **Evaluation of pseudo-progression in patients with glioblastoma multiforme using dynamic magnetic resonance imaging with ferumoxytol calls RANO criteria into question.** *Neuro Oncol* 2014;16:1146–54 CrossRef Medline
 38. Dósa E, Tuladhar S, Muldoon LL, et al. **MRI using ferumoxytol improves the visualization of central nervous system vascular malformations.** *Stroke* 2011;42:1581–88 CrossRef Medline
 39. Dósa E, Guillaume DJ, Haluska M, et al. **Magnetic resonance imaging of intracranial tumors: intra-patient comparison of gadoteridol and ferumoxytol.** *Neuro Oncol* 2011;13:251–60 CrossRef Medline
 40. Farrell BT, Hamilton BE, Dósa E, et al. **Using iron oxide nanoparticles to diagnose CNS inflammatory diseases and PCNSL.** *Neurology* 2013;81:256–63 CrossRef Medline
 41. Hamilton BE, Woltjer RL, Prola-Netto J, et al. **Ferumoxytol-enhanced MRI differentiation of meningioma from dural metastases: a pilot study with immunohistochemical observations.** *J Neurooncol* 2016;129:301–09 CrossRef Medline
 42. Thompson EM, Guillaume DJ, Dósa E, et al. **Dual contrast perfusion MRI in a single imaging session for assessment of pediatric brain tumors.** *J Neurooncol* 2012;109:105–14 CrossRef Medline
 43. UpToDate: Evidence-Based Clinical Decision Support System. Waltham, Massachusetts: Wolters Kluwer; 1992 [updated in 2016]. <https://www.uptodate.com>. Accessed April 3, 2017
 44. ACR Committee on Drugs and Contrast Media. *ACR Manual on Contrast Media*. Version 10.2. Published June 2016. https://www.acr.org/~media/ACR/Documents/PDF/QualitySafety/Resources/Contrast-Manual/2016_Contrast_Media.pdf. Accessed April 3, 2017