

Generic Contrast Agents

Our portfolio is growing to serve you better. Now you have a *choice*.



[VIEW CATALOG](#)

AJNR

This information is current as of May 20, 2025.

Two-Center Experience in the Endovascular Treatment of Intracranial Aneurysms Using the Woven EndoBridge 17 Device Including Midterm Follow-Up Results: A Retrospective Analysis

C. Maurer, I. König, A. Berlis, W. Weber and S. Fischer

AJNR Am J Neuroradiol 2019, 40 (9) 1517-1522

doi: <https://doi.org/10.3174/ajnr.A6177>

<http://www.ajnr.org/content/40/9/1517>

Two-Center Experience in the Endovascular Treatment of Intracranial Aneurysms Using the Woven EndoBridge 17 Device Including Midterm Follow-Up Results: A Retrospective Analysis

 C. Maurer,  I. König,  A. Berlis,  W. Weber, and  S. Fischer



ABSTRACT

BACKGROUND AND PURPOSE: The Woven EndoBridge device proved its effectiveness in the treatment of ruptured and unruptured intracranial aneurysms as a stand-alone device. Before 2016, Woven EndoBridge deployment required at least a 0.021-inch microcatheter. In 2016, a smaller device, the Woven EndoBridge 17 with finer size increments that used a 0.017-inch microcatheter, was introduced. We retrospectively analyzed our initial and follow-up results with the Woven EndoBridge 17 in ruptured and unruptured aneurysms.

MATERIALS AND METHODS: One hundred twenty-seven intracranial aneurysms in 117 patients were scheduled for treatment with the Woven EndoBridge 17 between June 2017 and February 2019. Twenty-nine aneurysms were ruptured.

RESULTS: Treatment was performed as intended in 124 of 127 cases (97.6%). Additional devices such as stents or coils were used in 12 cases (9.7%). Five thromboembolic complications and 1 hemorrhagic complication were encountered, resulting in clinical deterioration in 2 patients. The overall morbidity and mortality in the entire series have been 1.7% and 0.0% to date, respectively. The follow-up results at 3 and 12 months revealed complete occlusion in 76.1% (70/92) and 78.0% (32/41).

CONCLUSIONS: The Woven EndoBridge 17 device is safe in the treatment of small broad-based aneurysms without the general need for additional devices. The low complication rate and the promising follow-up results underline the value of this technique in a growing range of endovascular treatment options for intracranial aneurysms.

ABBREVIATIONS: AcomA = anterior communicating artery; GCP = good clinical practice

The concept of intra-aneurysmal flow disruption consists of a hemodynamically active implant placed inside the aneurysm sac, which, in combination with an attenuated coverage of the neck area, acts as a scaffold for final neointimal growth, resulting in an intra-aneurysmal thrombosis. Experience with the Woven EndoBridge device (WEB; Sequent Medical, Aliso Viejo, California) as the most established flow disruptor is growing, and its safety and effectiveness in the treatment of ruptured and unruptured aneurysms have been documented in numerous publications including clinical trials.^{1–7} A potential drawback in

treatment with the WEB device consisted of comparatively large microcatheters needed for deployment. In the initial phase, a 0.033- or a 0.027-inch microcatheter was necessary for every WEB device, while in 2015, a modification of the device resulted in the possibility of implanting WEB devices via a 0.021-inch microcatheter. The WEB 17 system, which became available in December 2016, is supposed to facilitate the treatment of small broad-based aneurysms. The possibility of using a 0.017-inch microcatheter might enable the operator to catheterize more distally located lesions and to treat more complex and smaller aneurysms with a potentially lower risk of vessel injury compared with larger catheters. The addition of the WEB 17 system to the pre-existing range of WEB devices, therefore, expands the possibilities and indications for endovascular treatment by intra-aneurysmal flow diversion.

This study is a retrospective evaluation of the immediate and follow-up results of 2 neurovascular centers using the WEB 17 device in the treatment of ruptured and unruptured intracranial aneurysms.

Received April 28, 2019; accepted after revision July 5.

From the Knappschafts Krankenhaus Bochum-Langendreer (I.K., W.W., S.F.), Universitätsklinik, Institut für Diagnostische und Interventionelle Radiologie, Neuroradiologie, Nuklearmedizin, Bochum, Germany; and Klinikum Augsburg (C.M., A.B.), Klinik für Diagnostische Radiologie und Neuroradiologie, Augsburg, Germany.

Please address correspondence to Sebastian Fischer, MD, Knappschafts Krankenhaus Bochum-Langendreer, Universitätsklinik, Institut für Diagnostische und Interventionelle Radiologie, Neuroradiologie, Nuklearmedizin, In der Schornau 23-25, 44892 Bochum, Germany; e-mail: sebif101@googlemail.com

<http://dx.doi.org/10.3174/ajnr.A6177>

MATERIALS AND METHODS

WEB Device

The WEB device is an intra-aneurysmal self-expanding electrothermically detachable implant available in 2 versions, a Single-Layer Sphere (SLS) and a more oblong Single-Layer (SL) configuration. It consists of a braided mesh of platinum-coated nitinol wires that converge at the bottom and the top of the device. A detailed summary of the design and development of the WEB device including its evolutionary steps is given in the literature.^{6,8,9}

The size of the microcatheter needed for delivery of the device depends on the width of the WEB used. While the SL version comes in well-defined width and length sizes, the length of each SLS device is 1.6 mm less than its width. While devices from 4 to 7 mm in width are compatible with a 0.021-inch microcatheter, larger ones need a 0.027-inch (8–9 mm) or a 0.033-inch (10–11 mm) microcatheter. The WEB 17 system is compatible with a 0.017-inch microcatheter and comes in sizes from 3 to 7 mm with 0.5-mm increments between the 3- and 5-mm devices. Devices with sizes from 6 to 7 mm are compatible with both a 0.017- or a 0.021-inch delivery catheter in the SL and SLS configurations. Even though the total number of wires that build the device is less in the WEB 17 compared with the WEB 21 version, the metal coverage at the bottom, as an elementary factor for intra-aneurysmal thrombosis and neointimal growth, is not less (approximately 60% in both versions).^{6,8} The VIA Microcatheter (Sequent Medical) is exclusively designed for the delivery of the WEB device and is therefore available in the mentioned sizes from 0.033 to 0.017 inch. The aneurysms analyzed in the present study were exclusively treated with the WEB 17 system using a VIA 17 microcatheter.

Decision-Making for Treatment with WEB

All cases were discussed in a weekly interdisciplinary conference including neurosurgical, neurologic, and neurointerventional expertise, and the decision for an endovascular treatment was reached by consensus following an “endovascular first” concept at both institutions. The final endovascular treatment strategy was determined by the neurointerventionalist. Clinical and morphologic factors were considered, whereas absolute exclusion criteria for an endovascular approach with the WEB 17 device were a neck width larger than the fundus width referring to an aspect ratio of <1 , an incorporation of a branch into the aneurysmal sac, and an aneurysm size below or above the suitable range for the WEB 17 device given by the manufacturer's sizing guide (<2.0 to >6.5 mm). Informed consent was obtained at least 24 hours before the procedure. Decision-making in cases of acutely ruptured aneurysms was reached outside the scheduled conference with the responsible neurosurgeon. The treatment results of acute cases were retrospectively analyzed in the following neurovascular conference. Patients in a poor clinical condition following an acute SAH were treated without prior informed consent on the basis of an emergency indication.

Endovascular Procedure: Device Selection

The basic procedural setup with the WEB 17 did not differ from the general institutional standards for any endovascular

aneurysm treatment in both participating centers. The analyzed procedures were performed by 4 neurointerventionalists, each with comprehensive experience in the endovascular treatment of intracranial aneurysms. Procedures were exclusively performed with the patient under general anesthesia on a biplane angiographic system, including the option of rotational angiography (Artis Q; Siemens, Erlangen, Germany). In unruptured aneurysms, a bolus of 5000 IU of heparin was administered, and patients were placed on dual-antiplatelet therapy before the procedure if mandatory to preserve the parent artery with a stent. After termination as intended, patients were kept on 100 mg of acetylsalicylic acid daily for 4–6 weeks. In cases of acutely ruptured aneurysms, the procedure was performed with 5000 IU of heparin without antiplatelet therapy.

Once the target artery was catheterized with an 8F or 6F guiding catheter or a combination of both, the aneurysm was visualized in an appropriate working position free from superimpositions of surrounding arteries. The selection of a WEB device suitable for the aneurysm resulted from calibrated measurements of its height and width in 2 orthogonal projections. The mean value of both determined the selection of the device based on the basic principle of an oversizing of the WEB in width with a compensatory undersizing of its height as described elsewhere.^{6,8} This principle became known as the “+1/–1 rule” before the introduction of the WEB 17 system, indicating an oversizing and undersizing of 1 mm for the appropriate WEB device. The horizontal compression of the device results in a longitudinal extension of 1 mm.¹⁰ The fixed value of 1 mm became improper for very small aneurysms, especially with regard to 0.5-mm increments for WEB 17, meaning that the required extent of oversizing is less in smaller aneurysms. This resulted in a sizing calculator based on an algorithm created by the manufacturer. The size selection of WEB 17 in this study was based on this sizing calculator.

The selected WEB 17 device was then advanced toward the aneurysm with a VIA 17 microcatheter placed in the proximal fundus. The complete unfolding of the device resulted from a gentle withdrawal of the microcatheter in combination with an advancement of the device. Both the microcatheter and the device were finally pushed forward to obtain a stable position inside the aneurysm with a proper apposition to the aneurysmal wall. The device was left undetached for approximately 10 minutes. In cases of malposition or an inadequate size (indicated by contrast filling between the device and the aneurysm wall or an extension toward the parent artery), the device was withdrawn and a larger or smaller device was implanted. In cases of a mild extension of the WEB device inside the parent artery with an anticipated flow disturbance, a self-expanding stent was applied to stabilize the device and to protect the parent artery. This decision was based on the individual interventionalist's estimation during an observational period of 10 minutes before the final detachment of the device.

Data Analysis and Follow-Up Schedule

Angiographic and clinical data were collected in retrospect and entered in a previously adapted data base. The initial and follow-

up angiographic results were graded on a 5-point scale as suggested by Caroff et al² (no residual flow in the aneurysm/WEB, 1; opacification of the proximal recess of WEB, 2; neck remnant, 3; residual flow inside the WEB, 4; aneurysm remnant, 5).

In the final descriptive analysis, grades 1–2 were summarized as complete occlusion, grades 3 and 4 indicated a neck remnant or flow inside the WEB, and grade 5 represented an aneurysm remnant.

The angiographic follow-up schedule at the 2 centers does not differ from that of interventionally treated aneurysms in general, with examinations planned after 3 and 12 months. The clinical condition of each patient was determined according to the mRS on admission, at discharge, and at each follow-up visit by the responsible neurosurgeon or neurointerventionalist. Patients with a clinical deterioration were analyzed separately with regard to the underlying cause.

Statistical Analysis

The statistical analysis of all variables was performed independently using Excel (Microsoft, Redmond, Washington). Continuous variables were given as the median and range. Independent variables were described as percentages.

Ethics Statement

We declare that all human and animal studies have been approved by the ethics committee of Ruhr Universität, Bochum, Germany. The study was performed in accordance with the ethical standards established in the 1964 Declaration of Helsinki and its later amendments. A separate informed consent from each patient before inclusion in this study was not required due to the retrospective design of the study.

RESULTS

Patients

A total of 117 patients (median age, 53 years; range, 25–81 years) with 127 intracranial aneurysms planned for treatment with the WEB 17 were included at the 2 participating centers during the sample period (June 2017 to February 2019). Of those, 29 aneurysms were acutely ruptured (SAH within 7 days before hospital admission) and the remaining 98 were unruptured.

Aneurysms Treated with WEB 17

One hundred thirteen (88.9%) aneurysms included were located in the anterior circulation, and the remaining 14 (11.1%) were posterior circulation aneurysms. Table 1 summarizes the aneurysm locations in detail.

While 29 aneurysms were acutely ruptured, 91 were found incidentally, 6 were remnants or previously coiled or clipped aneurysms, and 1 was a flow-related aneurysm in a patient with a large arteriovenous malformation. The median width of all aneurysms was 4.0 mm (range, 2.0–6.0 mm) with a median height of 4.0 mm (range, 2.0–7.0 mm) and a median neck size of 3.0 mm (range, 2.0–6.0 mm).

Primary Results

Treatment with the WEB 17 was successful in all except 3 procedures. One was an incidental finding of an aneurysm of the

Table 1: Location of the 127 intracranial aneurysms treated with WEB 17

Location	No.	Ratio (%)
Anterior circulation (<i>n</i> = 113) (88.9%)		
ACA AcomA	33	26.0%
ACA A2	11	8.6%
MCA bif	52	41.0%
MCA M1	2	1.6%
ICA PcomA	10	7.8%
ICA bif	5	4.0%
Posterior circulation (<i>n</i> = 14) (11.1%)		
BA tip	7	5.4%
PCA	1	0.8%
PICA	3	2.4%
Superior cerebellar artery	3	2.4%
		100.0%

Note:—ACA indicates anterior cerebral artery; ACA A2, anterior cerebral artery A2 segment; bif, bifurcation; PcomA, posterior communicating segment; BA tip, basilar artery tip; PCA, posterior cerebral artery.

middle cerebral artery bifurcation in a patient with a previously ruptured aneurysm of the basilar artery treated previously by coiling. The small aneurysm was difficult to catheterize with the VIA 17 microcatheter due to an unfavorable angle, and once a WEB 17 device of 3 mm in width and 2 mm height was deployed, the inferior branch of the middle cerebral artery showed a narrowing. A repositioning of the WEB device ideally with a temporary invagination of the proximal marker to optimize the configuration of the device inside the aneurysm might have been necessary to preserve the parent artery but appeared impossible given the angular anatomy of the parent artery. Therefore, the operator decided to recapture the device. The aneurysm was finally treated by stent-assisted coiling without problems. In the other failed case of an internal carotid artery aneurysm with a tight angulation to the parent artery, the WEB Device (WEB 17-SLS, 4 mm) dislocated into the middle cerebral artery directly after detachment, which was probably related to a combination of improper sizing and an interaction of the microcatheter with the detached device. The device was withdrawn from the middle cerebral artery using an Alligator retrieval device (Medtronic, Dublin, Ireland) without problems, and the aneurysm was finally treated by balloon-assisted coiling. The third case was a residual filling of a large ruptured, previously coiled aneurysm of the anterior communicating artery. Several attempts to place the smallest WEB 17 (SL3-2) failed due to the broad-based morphology, so the aneurysm remnant was finally treated with coils assisted by a remodeling balloon.

Therefore 124 successfully treated aneurysms were analyzed in the study. In 10 cases, the primary selected WEB 17 device was recaptured and a device of a different size was successfully implanted; and in 2 other cases, the final detachment of the WEB was after 2 other devices had to be withdrawn. Criteria to recapture the WEB were an incomplete filling of the aneurysm by the device or an extension of the mesh into the parent artery.

Additional devices such as self-expanding stents or coils were used in 12 (9.7%) cases; this addition was part of the intended treatment strategy in 7 (5.6%) cases (4 cases with stents [LVIS, MicroVention, Tustin, California; and Neuroform Atlas, Stryker

Table 2: Immediate and follow-up results of the aneurysms treated with WEB 17 according to the 5-point scale of Caroff et al^{2,a}

Grade No.	Immediate	Ratio (%)	3-Month Follow-Up	Ratio (%)	12-Month Follow-Up	Ratio (%)
1	124	100.0%	92	74.2%	41	33.1%
2	23	18.6%	62	67.4%	29	70.8%
3	2	1.6%	8	8.7%	3	7.3%
4	2	1.6%	11	12.0%	6	14.6%
5	86	69.4%	8	8.7%	1	2.4%
	11	8.8%	3	3.2%	2	4.9%

^a Grade 1: no residual flow in aneurysm/WEB 17; grade 2: opacification of the proximal recess of WEB 17; grade 3: neck remnant; grade 4: residual flow inside the WEB 17; grade 5: aneurysm remnant. Grades 1–2 are summarized as complete occlusion, grades 3 and 4 indicate a neck remnant or flow inside the WEB, and grade 5 represents an aneurysm remnant.

Neurovascular, Kalamazoo, Michigan] to stabilize the device inside the aneurysm and to preserve the parent artery; 3 cases combined with coiling). In the remaining 5 (4.0%) cases, a self-expanding stent was used as a bailout strategy to protect the parent artery. The decision for the additional implantation of a stent was made by the interventionalist as described above.

Angiographic Results

As with extra-aneurysmal flow diverters, an unchanged or at least reduced aneurysm perfusion directly after placement of the WEB device is the typical finding because the process of complete intra-aneurysmal thrombosis and neointimal growth may need up to several months. Nevertheless, some aneurysms occlude promptly after placement of an extra- or intra-aneurysm flow diverter.^{4,11} We found an initial rate of complete aneurysm occlusion in 25 (20.2%) of our 124 cases. This rate changed to 76.1% and 78.0% during the follow-up period of 3 and 12 months (median, 3.6 and 12.3 months; range, 0.2–12.4 and 4.40–24.2 months). Table 2 summarizes the initial and follow-up results according to the 5-point scale of Caroff et al.²

We observed 2 cases of clustering of the WEB device during the follow-up period. One of those was a carotid artery aneurysm (ICA posterior communicating artery), and the other was an anterior communicating artery (AcomA) aneurysm that was retreated by stent-assisted coiling. Two other aneurysms were retreated during the follow-up period due to a remaining perfusion of the neck not covered by the device. The decision for retreatment was made following a discussion in the neurovascular board.

Peri- and Postprocedural Complications

We observed thrombus formation within the parent artery after placement of the WEB 17 in 5 cases. Of those, 3 were successfully treated by an intravenous bolus of 500 mg of acetylsalicylic acid ($n=2$) or a weight-adapted bolus of eptifibatide. There was a spontaneous regression of the thrombus in 1 case. All those were cases of unruptured aneurysms. The last case was a ruptured, irregularly shaped aneurysm of the middle cerebral artery that was treated by a combination of coils and a 4 × 2 mm WEB 17 device placed at the base of the aneurysm. The device dislocated during the detachment process resulting in an occlusion of the inferior branch of the middle cerebral artery followed by a clinically relevant ischemia in the dependent vascular territory. The operator decided against an attempt to reopen the occluded branch with antithrombotic drugs because the patient was scheduled for

the acute evacuation of the intracerebral hematoma caused by the ruptured aneurysm directly after the endovascular intervention.

Another patient with a ruptured MCA bifurcation aneurysm was treated with a 5 × 3 mm WEB 17 device without problems but showed an increasing subarachnoid hemorrhage on the post-interventional CT scans. Although no contrast extravasation was observed peri-interventionally, this case was classified as an intra-procedural or early postinterventional subarachnoid hemorrhage. The patient developed a mild permanent deficit with an ongoing disorder of concentration and a reduction of mental capacity without any focal neurologic deficit (mRS 1), probably related to the described circumstance.

The 2 patients described experienced a clinically relevant deterioration, probably related to the procedure, resulting in a morbidity rate of 1.7% (2/117) and a mortality rate of 0.0%.

DISCUSSION

Our results underline the technical and clinical efficacy of the WEB 17 system in the treatment of ruptured and unruptured intracranial aneurysms, with an acceptable safety profile and convincing complete and adequate occlusion rates of 77.1% and 89.2% after 3 months.

The concept of intra-aneurysmal flow diversion with the WEB device proved its effectiveness in several good clinical practice (GCP) studies and single-center series before the introduction of the WEB 17 system. These GCP studies revealed a midterm adequate occlusion rate of 79.1% and a mortality rate of 1.2%.¹² The recently published 1-year results of the WEB Intracascular Therapy (WEB-IT) study with 148 patients treated with the WEB device showed complete and adequate occlusion rates of 58.8% and 84.6%, respectively, with a safety profile comparable with that of the previous GCP studies.¹³ The introduction of the WEB 17 system expanded the indications toward smaller and more distally located aneurysms. The results of the GCP studies (including larger aneurysms partly treated with the older Double-Layer system [WEB-DL]) are therefore not transferrable to the group of aneurysms exclusively treated with the WEB 17 without restriction because smaller aneurysms are generally known for a lower risk of recurrence or reperfusion compared with larger ones.¹⁴ Nevertheless, the occlusion and complication rates found in our series are similar to those of previously published series with the primary versions of the WEB device.^{4,6,10,12,13}

To date, there are only limited series of aneurysms exclusively treated with the WEB 17. Van Rooij et al⁸ analyzed their 46

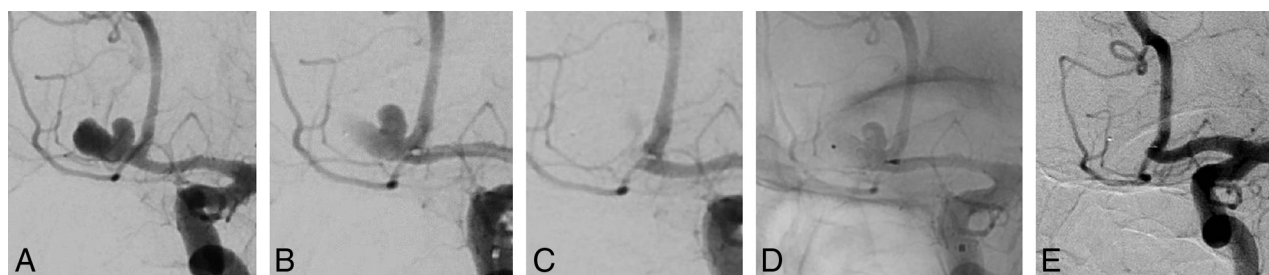


FIGURE. The complete occlusion of an unruptured bilobulated aneurysm of the AcomA in a patient with a history of SAH from another aneurysm. Injection of the left ICA with visualization in left-anterior-oblique view (A), deployment of a 6-mm WEB-SLS in the lower lobule of the aneurysm covering the orifice of the upper lobule (B), progressive thrombosis in both the lower and upper lobules of the aneurysm (C), visualization of the WEB 17 in the lower lobule of the aneurysm (fluoroscopy) (D), and 9-month follow-up angiography with stable and complete occlusion of the aneurysm (E).

aneurysms treated with the WEB 17 system. Of those, 25 were ruptured. They found 2 thromboembolic complications related to the procedure but not the device, and the patients remained without permanent clinical impairment. The complete and adequate occlusion rates at 3 months of 72% and 95% are comparable with the occlusion rates found in our series. Most interesting, there was only 1 case of an aneurysm remnant not sealed by the WEB device directly after placement. We did not analyze the number of cases with remnants or daughter aneurysms not sealed by the device, but in our experience, a complete filling of the entire aneurysm sac is not obligatory as long as the neck area is completely covered by the attenuated bottom of the WEB device, which facilitates a subsequent thrombosis of the entire aneurysm (see the illustrative case in the Figure). This characteristic is helpful, especially in the treatment of acutely ruptured aneurysms because potentially more vulnerable blebs of the aneurysm sac do not need to be catheterized separately.

In another study of 28 unruptured aneurysms treated with the WEB 17, 1 delayed thromboembolic complication was encountered. The complete occlusion rate was 91.7% during the short- and midterm follow-up periods.¹⁵

Besides these convincing angiographic and clinical results, the technical alterations of the WEB 17 allow the treatment of not only smaller aneurysms. With the possibility of introducing the WEB through a 0.017-inch microcatheter, catheterization of more distally located aneurysms with a tight angulation to the parent artery becomes easier compared with the larger VIA microcatheters. There were 8.6% distally located aneurysms of the anterior cerebral artery in our series. The WEB 17 consists of 72–108 wires compared with 144 wires in the previous versions. However, the amount of metal coverage at the bottom of the device, the hemodynamically active section, does not differ among all available sizes of the WEB. The metal coverage of approximately 60% for the WEB 17 is a consequence of a different braiding design compared with the previous versions. The lower amount of material makes it easier to deploy the device in tortuous anatomies with a more stable position of the microcatheter compared with the previous versions. The formability of the WEB 17 seems to be more pronounced, facilitating configuration within the aneurysm sac and allowing a recapture with less traction if necessary. Nevertheless, a triaxial access to the aneurysm increases the

stability during the implantation of the device, especially in tortuous anatomies.

Pierot et al¹⁶ presented a series of aneurysms in “atypical” locations treated with the WEB device, with impressive angiographic and clinical results. “Atypical” in this context means a location or morphology other than a bifurcation as the typical indication for the WEB device. With the WEB 17 being a softer device compared with previous versions, treatment of these atypical (sidewall) locations becomes straightforward. Our series with several aneurysms in atypical locations (A2, ICA posterior communicating artery, PICA) underlines this expansion of indications for WEB 17.

Asnafi et al,⁴ in a systemic review of 15 studies on the WEB device (all performed without the WEB 17), found a 12.0% rate of additional devices used in combination with the WEB. This is in line with the 9.7% in our series, in which additional devices were applied as a bailout strategy in 4.0%. Most interesting, in the series of van Rooij et al⁸ with the WEB 17, all aneurysms were treated without additional devices. This might be the consequence of the high rate of acutely ruptured aneurysms in their series (54%), in which the use of stents with their need for a dual-antiplatelet therapy is unfavorable. This refers to our treatment regimen with the WEB. In cases of unruptured aneurysms, patients were placed on dual-antiplatelet therapy before the procedure with a monotherapy of 100 mg of acetylsalicylic acid prescribed for 4–6 weeks. This concept not only allows a switch to stent-assisted coiling in cases of failure with the WEB but also allows a stent to stabilize the WEB or to preserve the parent artery in cases of doubt.

The design of WEB 17 with a lower number of wires might promote a compaction during the follow-up period with potentially lower occlusion rates compared with the previous version of the device. This relation, based on the WEB 17 being a softer device, remains hypothetical, and we think that with an exact sizing, the rate of compaction will not be different from that with the previous device.

The retreatment rate in our series was 2.4%, which is relevantly lower than the rates of 12.3% and 21.1% reported in other series with the WEB device.^{17,18} One reason can be found in the increasing experience with the WEB device (learning curve), resulting in a more appropriate initial size selection with a lower retreatment rate as described in the literature.^{18,19} Another reason

might be found in the smaller aneurysm size in this series and the comparatively short follow-up period. A comparative analysis of all aneurysms treated with WEB 21 and WEB 17 with longer follow-up data that is currently being conducted at our institution will help to identify the factors influencing a stable long-term occlusion.

Our study has several limitations that are mainly related to the retrospective design. The angiographic results were not analyzed independently. Because the WEB 17 system is a comparatively new device (available in Europe since December 2016), only midterm follow-up results are reported in our series, which impedes a direct comparison with other treatment options for broad-based bifurcation aneurysms. The mismatch of unruptured and ruptured aneurysms makes a statistically exploitable comparison unfeasible.

CONCLUSIONS

The WEB 17 device is safe in the treatment of broad-based aneurysms without the general need for additional devices or dual antiplatelet therapy. The system enlarges the indications toward smaller, otherwise difficult-to-treat, aneurysms. The low complication rate and the promising follow-up results underline the value of this technique in the growing range of endovascular treatment options for intracranial aneurysms. Comparative clinical trials with longer follow-up data will allow a direct comparison with conventional endovascular techniques.

Disclosures: Christoph Maurer—UNRELATED: Grants/Grants Pending: MicroVention and Stryker, Comments: educational grant by MicroVention and Stryker. Ansgar Berlis—RELATED: Consulting Fee or Honorarium: proctoring for MicroVention and Sequent Medical*; UNRELATED: Consultancy: proctoring for Stryker and Medtronic; Payment for Lectures Including Service on Speakers Bureaus: Penumbra*; Other: Clinical Event Committee for phenox. Werner Weber—UNRELATED: Consultancy: Penumbra, MicroVention, Stryker, phenox, Comments: proctoring, lecture, and chair. Sebastian Fischer—UNRELATED: Consultancy: Stryker, phenox, MicroVention, Kaneka Corporation, Comments: speaker honorarium; Payment for Lectures Including Service on Speakers Bureaus: MicroVention, Comments: speaker honorarium. *Money paid to the institution.

REFERENCES

- Pierot L, Spelle L, Molyneux A. Clinical and anatomical follow-up in patients with aneurysms treated with the WEB device: 1-year follow-up report in the cumulated population of 2 prospective, multicenter series (WEBCAST and French Observatory). *Neurosurgery* 2016;78:133–41 [CrossRef Medline](#)
- Caroff J, Mihalea C, Klich C, et al. Single-layer WEBs: intrasaccular flow disrupters for aneurysm treatment—feasibility results from a European study. *AJNR Am J Neuroradiol* 2015;36:1942–46 [CrossRef Medline](#)
- Pierot L, Costalat V, Moret J, et al. Safety and efficacy of aneurysm treatment with WEB: results of the WEBCAST study. *J Neurosurg* 2016;214:1250–56 [CrossRef](#)
- Asnafi S, Rouchaud A, Pierot L, et al. Efficacy and safety of the Woven EndoBridge (WEB) device for the treatment of intracranial aneurysms: a systematic review and meta-analysis. *AJNR Am J Neuroradiol* 2016;37:2287–92 [CrossRef Medline](#)
- Fiorella D, Molineux A, Coon A, et al. Demographic, procedural and 30-day safety results from the WEB intra-saccular therapy study (WEB-IT). *J NeuroInterv Surg* 2017;0:1191–96 [CrossRef Medline](#)
- Popielski J, Berlis A, Weber W, et al. Two-center experience in the endovascular treatment of ruptured and unruptured intracranial aneurysms using the WEB device: a retrospective analysis. *AJNR Am J Neuroradiol* 2018;39:111–17 [CrossRef Medline](#)
- Tau N, Sadeh-Gonik U, Aulagner G, et al. The Woven EndoBridge (WEB) for endovascular therapy of intracranial aneurysms: update of a systematic review with meta-analysis. *Clin Neurol Neurosurg* 2018;166:110–15 [CrossRef Medline](#)
- van Rooij SB, Peluso JP, Sluzewski M, et al. The new low-profile WEB 17 system for treatment of intracranial aneurysms: first clinical experience. *AJNR Am J Neuroradiol* 2018;39:859–63 [CrossRef Medline](#)
- Jiang B, Paff M, Colby GP, et al. Cerebral aneurysm treatment: modern endovascular techniques. *Stroke Vasc Neurol* 2016;1:93–100 [CrossRef Medline](#)
- Lescher S, Du Mesnil de Rochemont R, Berkefeld J. Woven Endobridge (WEB) device for endovascular treatment of complex unruptured aneurysms: a single center experience. *Neuroradiology* 2016;58:383–90 [CrossRef Medline](#)
- Fischer S, Vajda Z, Aguilar Perez M, et al. Pipeline embolization device (PED) for neurovascular reconstruction: initial experience in the treatment of 101 intracranial aneurysms and dissections. *Neuroradiology* 2012;54:369–82 [CrossRef Medline](#)
- Pierot L, Moret J, Barreau X, et al. Safety and efficacy of aneurysm treatment with WEB in the cumulative population of three prospective, multicenter series. *J Neurointerv Surg* 2018;10:553–56 [CrossRef Medline](#)
- Arthur AS, Molyneux A, Coon AL, et al; WEB-IT Study investigators. The safety and effectiveness of the Woven EndoBridge (WEB) system for the treatment of wide-necked bifurcation aneurysms: final 12-month results of the pivotal WEB Intrasaccular Therapy (WEB-IT) study. *J Neurointerv Surg* 2019 Apr 16. [Epub ahead of print] [CrossRef Medline](#)
- Feng X, Wang L, Guo E, et al. Progressive occlusion and recanalization after endovascular treatment for 287 unruptured small aneurysms (<5 mm): a single-center 6-year experience. *World Neurosurg* 2017;103:576–83 [CrossRef Medline](#)
- Mihalea C, Caroff J, Pagiola I, et al. Safety and efficacy of the fifth generation Woven EndoBridge device: technical note. *J Neurointerv Surg* 2019;0:1–5 [CrossRef](#)
- Pierot L, Biondi A, Narata AP, et al. Should indications for WEB aneurysm treatment be enlarged? Report of a series of 20 patients with aneurysms in “atypical” locations for WEB treatment. *J Neuroradiol* 2017;44:203–09 [CrossRef Medline](#)
- Kabbasch C, Goertz L, Siebert E, et al. Treatment strategies for recurrent and residual aneurysms after Woven Endobridge implantation. *J Neurointerv Surg* 2019;11:390–95 [CrossRef Medline](#)
- Hagen F, Maurer C, Berlis A. Endovascular treatment of unruptured MCA bifurcation aneurysms regardless of aneurysm morphology: short- and long-term follow-up. *AJNR Am J Neuroradiol* 2019;40:503–09 [CrossRef Medline](#)
- Behme D, Berlis A, Weber W, et al. Woven EndoBridge intrasaccular flow disruptor for the treatment of ruptured and unruptured wide-neck cerebral aneurysms: report of 55 cases. *AJNR Am J Neuroradiol* 2015;36:1501–06 [CrossRef Medline](#)