

Generic Contrast Agents

Our portfolio is growing to serve you better. Now you have a *choice*.



[VIEW CATALOG](#)

AJNR

Initial Experiences with the Trenza Embolization Device for the Treatment of Wide-Neck Intracranial Aneurysms: A 12-Patient Case Series

Rahul Raj and Jussi Numminen

This information is current as of May 21, 2025.

AJNR Am J Neuroradiol 2024, 45 (4) 418-423

doi: <https://doi.org/10.3174/ajnr.A8153>

<http://www.ajnr.org/content/45/4/418>

Initial Experiences with the Trenza Embolization Device for the Treatment of Wide-Neck Intracranial Aneurysms: A 12-Patient Case Series

Rahul Raj and Jussi Numminen



ABSTRACT

SUMMARY: The Trenza embolization device is a frame coil implant with flow-disruption properties and is a new alternative to treat challenging mid-to-large-sized broad-neck bifurcation or sidewall aneurysms. We conducted an observational single-center retrospective study of 12 consecutive patients treated for 10 unruptured and 2 ruptured 6- to 12-mm broad-neck bifurcation or sidewall aneurysms with the Trenza device during 2022–2023. The median patient age was 64 years (interquartile range, 59–70 years), 58% were women, the median largest aneurysm diameter was 9.6 mm (interquartile range, 7.5–11.9 mm), the median dome-to-neck ratio was 1.8 (interquartile range, 1.6–1.9), the most common aneurysm locations were the anterior communicating artery (33%) and basilar artery tip (33%). After a median follow-up of 6.5 months, adequate aneurysm occlusion was achieved in 83%. There were 3 major ischemic complications (25%), leading to 2 permanent neurologic deficits (17%) and 1 transient neurologic deficit (8%). There was 1 fatal rupture of a treated aneurysm 1.6 months after the index treatment. Two patients were retreated (17%). Ischemic complications occurred in patients after a too-dense coil packing at the base of the aneurysm. No technical issues related to the device were encountered. In summary, an adequate aneurysm occlusion rate was achieved using the Trenza-assisted coiling technique for otherwise challenging mid-to-large-sized broad-neck aneurysms. Ischemic complications seemed to occur following overdense coiling at the base of the aneurysm.

ABBREVIATIONS: ASA = acetylsalicylic acid; DAPT = double antiplatelet treatment; IQR = interquartile range

Endovascular coiling or balloon-assisted coiling of broad-neck mid-sized intracranial aneurysms without the use of additional stents is associated with an up to 20%–30% probability of incomplete occlusion^{1–5} but with a rather low risk of thromboembolic complications.⁶ Stent-assisted coiling improves the occlusion rate but is associated with an increased risk of thromboembolic events, especially when treating ruptured intracranial aneurysms or when using complex stent configurations.^{7–10} Thus, to keep the occlusion rate of stent-assisted coiling but to minimize the risk of stent-associated thromboembolic events, especially in ruptured aneurysms, endosaccular flow-disruption devices such as the Woven EndoBridge device (WEB; Sequent Medical), the Artisse intrasaccular device (Medtronic), and the Contour device (Cerus Endovascular) have been introduced.^{11–16} Yet, these intrasaccular

devices have geometric and size restrictions, which limit their use in certain aneurysms.¹⁷

Recently, the Trenza coil implant (Stryker) was introduced as an alternative to treat 6- to 12-mm broad-neck bifurcation or sidewall aneurysms. The Trenza device is an intrasaccular braided ribbon-like frame coil implant, with flow-disruption properties, which aims to create a stable basket in the aneurysm that is then filled with standard coils. It is hypothesized that due to the endosaccular nature, the flow-disruption properties of the Trenza device together with a normal coiling procedure would lead to higher occlusion rates but a lower risk of thromboembolic complications compared with simple coiling alone or stent-assisted coiling.

Here we summarize our initial experience treating 12 patients with the Trenza device with the aim of transparently reporting radiologic and neurologic complications as well as clinical and 6-month angiographic results.

MATERIALS AND METHODS

We conducted a single-center retrospective analysis of all consecutive patients with intracranial aneurysms treated with the Trenza embolization device at Helsinki University Hospital between May 2022 and January 2023. The Trenza device is CE approved and was available for routine clinical use in Finland

Received November 9, 2023; accepted after revision December 20.

From the Departments of Neurosurgery (R.R.) and Radiology (J.N.), Helsinki University Hospital and University of Helsinki, Helsinki, Finland.

This study was supported by the state funding for university-level health research in Finland (TYH2023330, Helsinki University Hospital).

Please address correspondence to Rahul Raj, MD, PhD, Bridge Hospital, 3rd floor, Room STA3.082, Haartmaninkatu 4, PO Box 320, 00029 HUS, Helsinki, Finland; e-mail: rahul.raj@hus.fi; @rahulbrraj

Indicates article with online supplemental data.

<http://dx.doi.org/10.3174/ajnr.A8153>

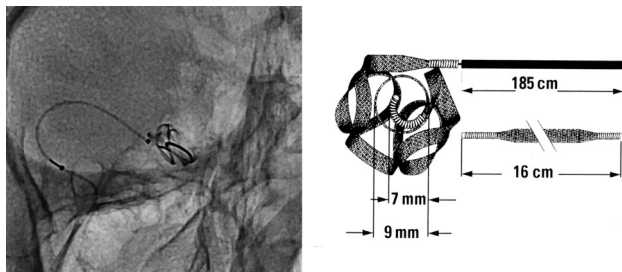


FIG 1. Native image showing the Trenza embolization device (left) and an illustration of a 9-mm Trenza device.

during the study. All consecutive patients were treated before the start of the Trenza Embolization Device for Intracranial Aneurysm Treatment study (TREAT, clinicaltrials.gov identifier: NCT04380350; recruitment started in Helsinki in December 2022). We included patients with ruptured and unruptured aneurysms. The decision to treat the aneurysm was made by a multidisciplinary neurovascular team. The decision to treat the aneurysm with the Trenza embolization device was made by the operating interventionalist. Aneurysms considered for treatment with the Trenza device had to be 6- to 12-mm bifurcation or sidewall aneurysms with a wide neck (defined as neck of ≥ 4 mm or dome-to-neck ratio of < 2). Aneurysms fulfilling the criteria were carefully reviewed before deciding to use the Trenza device. Aneurysms that were considered to have a high risk of treatment-related complications using other techniques (eg, stent-assisted coiling or flow diversion) and suitable for the Trenza device were selected. Although the aspect ratio of the aneurysm does not per se affect the usability of the Trenza, given that the other measurement features are fulfilled, we did not choose aneurysms with a marked discrepancy in aneurysm dimensions.

The institutional review board approved the study (research approval HUS/313/2022). Due to the retrospective design of the study, national legislation does not warrant informed consent because the Trenza device was used as part of routine care. The study was reported with the Strengthening the Reporting of Observational Studies in Epidemiology (STROBE) guidelines.

Trenza Device

The Trenza embolization device is a specially designed coil implant that creates a stable ω -shaped basket to be filled with coils until the aneurysm is occluded. The coil implant is designed to have flow-disruption properties to enhance aneurysm thrombosis. The Trenza device is available in 6- to 12-mm sizes, with 1-mm intervals. Each size has a fixed length (eg, 6×11 mm, 7×13 mm, 8×15 mm, and so forth). One or several Trenza devices can be used to create a stable basket after which the recommendation is to fill the basket with Target XL (Stryker Neurovascular) coils until the aneurysm is occluded. The device is attached to a flexible delivery wire, and detachment of the device is electrothermal, similar to several other neurovascular implant-delivery systems (Fig 1). The device is sized as the mean diameter of the aneurysm in 3 planes, irrespective of the neck size, with no plane being smaller than 5 mm without accounting for secondary lobules.

The indications to use the Trenza embolization device are broad-based saccular bifurcation or sidewall aneurysms (defined

as having a dome-to-neck ratio of < 2 or a neck ratio of ≥ 4.0 mm) between 6 and 12 mm in size.

Treatment Setup

For treatment, we used a coaxial system (femoral or radial access, 8F-long sheath, distal-access catheter) with the Excelsior 1018 microcatheter (Stryker). All patients were heparinized during the treatment, and heparinization levels were followed using active clotting time measurements. Generally, we aimed for an active clotting time value of approximately 2 times the baseline level.

In general, our pretreatment antiplatelet regimen consisted of double antiplatelet treatment (DAPT), consisting of acetylsalicylic acid (ASA), 100 mg once a day, and prasugrel, 10 mg once a day, or clopidogrel, 75 mg once a day, starting 7 days before the intervention. Our posttreatment antiplatelet regimen was ASA, 100 mg once a day for 3 months, either with or without prasugrel (favoring ASA + prasugrel with increased experience with the Trenza device). We tested the preintervention antiplatelet medication response using the VerifyNow method (Werfen).

Definition of Radiologic Complications, Neurologic Complications, Clinical Outcome, and Radiologic Outcome

We defined radiologic complications as hemorrhagic or ischemic. Hemorrhagic and ischemic complications had to be symptomatic and verified by CT or MR imaging within 6 months of the treatment and located in the vascular territory of the treated aneurysm. All patients underwent postoperative head CT on the first postoperative day. Further CT or MR imaging scans were obtained at the discretion of the treating clinicians. Patients with ruptured aneurysms were imaged at the discretion of the treating clinicians. We further noted whether the patient was retreated or scheduled for retreatment during the study period.

We defined symptomatic neurologic complication as a new neurologic deficit with supportive imaging findings related to the treated aneurysm occurring within 6 months of the treatment. If the neurologic symptom resolved within 6 months, we classified it as being transient.

We assessed clinical outcomes using the mRS (range, 0 [no symptoms] to 6 [death]) 6 months after the index treatment at the time of the control DSA.

We performed a routine DSA follow-up at approximately 6 months for all patients. We assessed aneurysm occlusion rates using the modified Raymond-Roy classification.¹⁸

Statistical Analysis

Given the small sample size, we used only descriptive statistics. Categorical data were presented as number (percentage); parametric data, as mean (SD); and nonparametric data, as median (interquartile range [IQR]). STATA (StataCorp) was used for the statistical analyses.

RESULTS

Baseline Characteristics

Of 32 eligible aneurysms, a total of 12 aneurysms in 12 patients were treated from May 2022 to January 2023 with the Trenza embolization device (Fig 2). The median age was 64 years, 58%

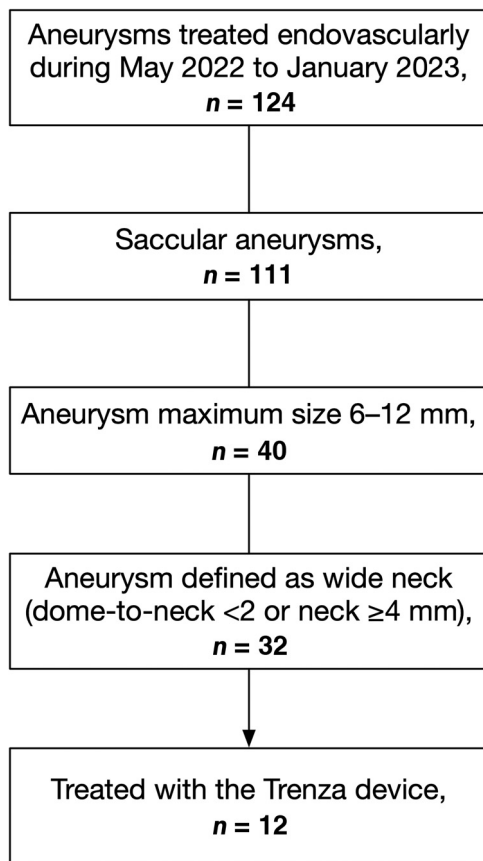


FIG 2. Flow chart describing the patient population.

were women, 42% were never smokers, 58% had a history of hypertension, and 17% (2 patients) had acutely ruptured aneurysms (Table 1).

Nine patients were DAPT-premedicated, and 1 patient was prasugrel-only pretreated due to ASA allergy. Two patients were acutely ruptured cases and did not receive any pretreatment antithrombotic medication. The posttreatment antiplatelet regime was DAPT (ASA + prasugrel) in 4 patients, ASA only in 6 patients, ASA + apixaban in 1 patient (due to concomitant atrial fibrillation), and prasugrel only in 1 patient (due to ASA allergy).

Anterior communicating artery and basilar artery aneurysms were the most frequent (33% for both). The median largest aneurysm diameter was 9.6 mm, median neck length was 5.4 mm, and the median dome-to-neck ratio was 1.8 (Table 1).

Treatment Characteristics

The median intervention time was (from puncture to closure) 121 minutes (IQR, 100–170 minutes). In 1 procedure, an additional stent (NeuroForm Atlas; Stryker) was used to protect the lumen of the parent artery (case 8 in the Online Supplemental Data); in 1 case, a Comaneci device (Rapid Medical) was used as support during the embolization (case 2 in the Online Supplemental Data); in 1 case, a balloon was used during the implantation of the Trezza device (case 11 in the Online Supplemental Data); and in 1 case an unruptured right-sided multilobular anterior cerebral artery, 1 segment

Table 1: Patient and aneurysm characteristics

Variable	Patients (n = 12)
Patient characteristics	
Age (median) (IQR) (yr)	64 (59–70)
Female sex	7 (58%)
Smoking	
Never	5 (42%)
Ex-smoker, stopped >6 months ago	5 (42%)
Active smoker or stopped <6 months ago	2 (16%)
Hypertension	7 (58%)
Diabetes	2 (17%)
Aneurysm characteristics	
Acutely ruptured	2 (17%)
Location	
AcomA	4 (33%)
Basilar artery tip	4 (33%)
ICA communicating segment	3 (25%)
MCA	1 (9%)
Height (median) (IQR) (mm)	8.2 (6.3–8.9)
Dome (median) (IQR) (mm)	9.6 (7.4–11.9)
Neck (median) (IQR) (mm)	5.4 (3.7–7.2)
Largest diameter (median) (IQR) (mm)	9.6 (7.5–11.9)
Aspect ratio (median) (IQR)	0.83 (0.78–1.09)
Dome-to-neck ratio (median) (IQR)	1.8 (1.6–1.9)

Note:— AcomA indicates anterior communicating artery.

(A1), aneurysm was coiled in the same session (case 5 in the Online Supplemental Data).

One Trezza device was used in 5 cases (42%), and 2 Trezza devices were used in 7 cases (58%). There were no technical failures related to the Trezza device.

All pre-embolization DSA images and follow-up DSA images are shown in the Online Supplemental Data.

Radiologic and Neurologic Complications

Two patients (17%) had an immediate treatment-related symptomatic ischemic complication, and 1 patient's aneurysm bled 1.6 months after the index treatment, which lead to death. Both patients with symptomatic ischemic complications were pretreated with DAPT. The clinical consequences of the ischemic complications were 2 (17%) permanent neurologic deficits (Table 2). There were no delayed ischemic complications.

Clinical Outcome

The median follow-up time was 6.5 months (IQR, 6.2–6.8 months). Of the patients treated for an unruptured aneurysm, 7 of 10 (70%) had an unchanged mRS of 0. One patient died from a posttreatment bleed from the treated aneurysm, and 2 patients' mRS scores worsened to 2.

Both patients treated for a ruptured aneurysm (initial SAH severity, World Federation of Neurosurgical Societies I and IV, respectively) had good clinical outcomes (mRS 0 and 1, respectively).

Radiologic Outcome and Retreatments

Eight patients (67%) had a complete occlusion, and 10 patients (83%) had an adequate occlusion of the treated aneurysm after a median of 6.5 months (IQR, 6.2–6.8 months). Two patients had an inadequately obliterated aneurysm, with contrast opacification between the Trezza and coils and the aneurysmal wall. One caused a rupture 1.6 months from the index treatment, and the

Table 2: Aneurysm occlusion rate and outcomes^a

Characteristic	Patients (n = 12)
Aneurysm occlusion ^b	
Complete obliteration	8 (67%)
Residual neck	2 (16.5%)
Residual aneurysm with contrast filling within the coils	0
Residual aneurysm with contrast filling between the coils and the aneurysm wall	2 (16.5%)
Complications	
Ischemic complications	2 (17%)
Hemorrhagic complications	1 (8%)
Symptomatic neurologic complications	
Permanent	2 (17%)
Transient	0 (0%)
Death	1 (7.5%)
Permanent symptomatic neurologic deficit or death	3 (25%)

^a All variables presented as No. (%).

^b Median time to imaging follow-up 6.5 months (IQR, 6.2–6.8 months).

patient died after an acute re-intervention (case 9 in the Online Supplemental Data). The other re-treated patient was re-treated 7 months after the index treatment (case 10 in the Online Supplemental Data). Thus, 2 of 12 patients were re-treated (17%).

DISCUSSION

In this case series, we evaluated 12 patients with broad-based mid-to-large-sized aneurysms (median diameter of nearly 10 mm, median dome-to-neck ratio of 1.8) who underwent endovascular treatment using the Trezza coil implant device complemented by additional coiling. The six-month follow-up demonstrated an occlusion rate of 83%. This rate is particularly notable given the challenging nature of the aneurysms treated, characterized by their size and broad necks—factors traditionally associated with lower occlusion rates and higher procedural risks.²

The use of the Trezza device was also associated with a reduction in the need for stent deployment, with 11 of the 12 patients avoiding stents altogether. This outcome not only simplifies the treatment but may also lead to a lower risk of ischemic complications, which are more prevalent in patients with larger aneurysms and wider necks.^{6,19,20} Furthermore, given the challenging nature of the treated aneurysms, an assisting support device during the coiling was only needed in 2 cases. The avoidance of support devices and stents may contribute to a lower incidence of ischemic complications, especially in ruptured aneurysms, though this result remains to be elucidated in comparative studies. Thus, the ability of the Trezza device to achieve high rates of occlusion in challenging aneurysms without the adjunctive use of stents is noteworthy.

Despite the high occlusion rate, there was a 17% incidence of ischemic complications within this cohort. This figure, while not negligible, must be interpreted with caution due to the small sample size and the complex anatomy of the aneurysms treated. Specifically, there were 2 ischemic complications in 2 patients with basilar tip aneurysms measuring 12 and 14 mm, where the coiling at the base was excessively dense, leading to compromised flow in the posterior cerebral arteries (as shown in cases 8 and 10 of the Online Supplemental Data). Thus, our preliminary data

suggest that for large bifurcation aneurysms with broad necks, a strategy of less dense coiling at the base may be advantageous, preserving the patency of the bifurcation. This approach is facilitated by the flow-disruption capabilities of the Trezza device, which appears to promote effective aneurysm occlusion even with less dense packing at the neck. The efficacy of the Trezza device in flow disruption and subsequent aneurysm occlusion is particularly evident in cases 2, 3, and 11 (Online Supplemental Data), in which, despite the aneurysms being loosely coiled at their bases, complete occlusion was achieved at follow-up.

In this cohort, 92% of patients had favorable functional outcomes after 6 months. One patient had a fatal rupture of the treated unruptured ICA aneurysm (maximum diameter, 12 mm) 1.6 months after treatment (case 9 in the Online Supplemental Data). Considering the aneurysm size, the short time span from treatment to rupture, and the point of extravasation being seen from the densely coiled part of the aneurysm, this complication is likely related to the instability of the large aneurysm instead of being related to the device itself.

Technically, the use of the Trezza device is similar to that of a normal coiling procedure with some exceptions. The Excelsior 1018 microcatheter (0.019 inch) must be used, which is somewhat larger and stiffer than other coiling microcatheters but smaller than some microcatheters used for other devices. The Trezza device is stiffer than normal framing coils and may cause recoil kickback of the microcatheter, highlighting the need for good proximal catheter support. Furthermore, if the Trezza basket does not cover the aneurysm optimally, it may be challenging to coil the space between the Trezza and the aneurysm wall (for example, case 5 in the Online Supplemental Data). However, complete or dense coiling of the aneurysm might not always be necessary to achieve complete aneurysm occlusion (case 11 in the Online Supplemental Data).

There have been several intrasaccular devices designed to treat wide-neck aneurysms. These include, for example, the Medina device (Medtronic), the Luna aneurysm embolization device (Medtronic), the WEB device, and the Contour device. Of these various intrasaccular devices, the Trezza and the Medina share similar engineering principles in that both are coil-like implants with flow-disrupting properties. Reports on the Medina device have shown adequate occlusion rates of 71%–83% (83% in our study), retreatment rates of 8%–38% (17% in our study), and complication rates of 8%–23% (17% in our study).^{21–23} Studies on the Medina device have included smaller aneurysms with wider necks; thus, the results are not directly comparable. Of the intrasaccular devices, the WEB is the most established, with long-term adequate occlusion rates of approximately 90%,²⁴ long-term retreatment rates of 12%,²⁵ and an ischemic complication rate of 7.5%.²⁶ Data regarding the Luna and Contour devices are scarcer, but reports have shown adequate occlusion and ischemic complication rates of 85% and 2.5%–12.5%, respectively, for the Contour^{15,27} and 78% and 5%, respectively, for the Luna.²⁸ Nevertheless, comparative long-term outcome studies of the various intrasaccular devices are needed of the optimal device for specific patients and aneurysms.

In conclusion, the Trezza coil implant device has potential as a valuable tool in the endovascular armamentarium for the

treatment of broad-neck aneurysms measuring 6–12 mm. Nevertheless, the findings from this series should be interpreted as preliminary. Larger, controlled studies are warranted to corroborate these results and to refine the coiling strategies that optimize clinical outcomes. Furthermore, comparative studies with other endovascular techniques are essential to delineate the role of the Trenza device in the broader context of aneurysm management.

Limitations

This is a case series of only 12 patients, so there are some inherent limitations. First, the small sample size limits the generalizability of the results, and further larger studies are needed to really assess the effectiveness and safety of the Trenza device. Second, because the device is new, there are no data regarding the optimal antiplatelet treatment strategy. Because the treated aneurysms were broad-neck and the need for stents is challenging to exclude before treatment, we pretreated most patients with DAPT and continued with DAPT or single antiplatelet therapy after the intervention for 3 months. The use of DAPT is somewhat contradictory because one of the main advantages of intrasaccular over parent artery stent placement is the avoidance of DAPT. Pretreatment with DAPT was used as a safety measure in case of bailout stent placement, something needed in only 1 of the 12 cases. DAPT was continued for 3 months due to the relatively high metal coverage of a wide neck, again, used as a safety measure that may not be necessary. For example, only posttreatment aspirin was used in the 2 ruptured cases, with neither patient exhibiting any signs of device-related ischemic complications. Third, because we had no clinical experience in using the device (except ex vivo simulations), the duration of the interventions was longer than normal (median, 2 hours). It is likely that with increased experience, intervention times will go down, possibly reducing the risk of ischemic complications. Furthermore, with increased experience, a better understanding of how to place the Trenza device to achieve complete occlusion is likely, possibly increasing the occlusion rate and decreasing the risk of ischemic complications. The learning curve is expected to be low due to the similarities to a normal, simple coiling procedure. Fourth, we report results after a median of 6 months. More long-term data are needed to establish the safety and effectiveness of the Trenza device.

CONCLUSIONS

An adequate aneurysm occlusion rate was achieved using the Trenza-assisted coiling technique for otherwise challenging mid-to-large-sized broad-neck aneurysms. Ischemic complications seemed to occur following overly dense coiling at the base of the aneurysm.

Disclosure forms provided by the authors are available with the full text and PDF of this article at www.ajnr.org.

REFERENCES

- Raymond J, Klink R, Chagnon M, et al. **Hydrogel versus bare platinum coils in patients with large or recurrent aneurysms prone to recurrence after endovascular treatment: a randomized controlled trial.** *AJNR Am J Neuroradiol* 2017;38:432–41 [CrossRef Medline](#)
- Pierot L, Barbe C, Thierry A, et al. **Patient and aneurysm factors associated with aneurysm recanalization after coiling.** *J Neurointerv Surg* 2022;14:1096–101 [CrossRef Medline](#)
- Raymond J, Guilbert F, Weill A, et al. **Long-term angiographic recurrences after selective endovascular treatment of aneurysms with detachable coils.** *Stroke* 2003;34:1398–403 [CrossRef Medline](#)
- Pierot L, Cognard C, Anxionnat R, et al; CLARITY Investigators. **Endovascular treatment of ruptured intracranial aneurysms: factors affecting midterm quality anatomic results—analysis in a prospective, multicenter series of patients (CLARITY).** *AJNR Am J Neuroradiol* 2012;33:1475–80 [CrossRef Medline](#)
- Ferns SP, Sprengers ME, van Rooij WJ, et al. **Coiling of intracranial aneurysms: a systematic review on initial occlusion and reopening and retreatment rates.** *Stroke* 2009;40:e523–29 [CrossRef Medline](#)
- Pierot L, Barbe C, Nguyen HA, et al. **Intraoperative complications of endovascular treatment of intracranial aneurysms with coiling or balloon-assisted coiling in a prospective multicenter cohort of 1088 participants: Analysis of Recanalization after Endovascular Treatment of Intracranial Aneurysm (ARETA) study.** *Radiology* 2020;296:E130–33 [CrossRef Medline](#)
- Piotin M, Blanc R, Spelle L, et al. **Stent-assisted coiling of intracranial aneurysms: clinical and angiographic results in 216 consecutive aneurysms.** *Stroke* 2010;41:110–15 [CrossRef Medline](#)
- Bsat S, Bsat A, Tamim H, et al. **Safety of stent-assisted coiling for the treatment of wide-necked ruptured aneurysm: a systematic literature review and meta-analysis of prevalence.** *Interv Neuroradiol* 2020;26:547–56 [CrossRef Medline](#)
- Hong Y, Wang YJ, Deng Z, et al. **Stent-assisted coiling versus coiling in treatment of intracranial aneurysm: a systematic review and meta-analysis.** *PLoS One* 2014;9:e82311 [CrossRef Medline](#)
- Bartolini B, Blanc R, Pistocchi S, et al. **“Y” and “X” stent-assisted coiling of complex and wide-neck intracranial bifurcation aneurysms.** *AJNR Am J Neuroradiol* 2014;35:2153–58 [CrossRef Medline](#)
- Kabbasch C, Goertz L, Siebert E, et al. **WEB embolization versus stent-assisted coiling: comparison of complication rates and angiographic outcomes.** *J Neurointerv Surg* 2019;11:812–16 [CrossRef Medline](#)
- Naamani KE, Chen CJ, Abbas R, et al. **Woven EndoBridge versus stent-assisted coil embolization of cerebral bifurcation aneurysms.** *J Neurosurg* 2022;137:1786–93 [CrossRef Medline](#)
- Arthur AS, Molyneux A, Coon AL, et al; WEB-IT Study investigators. **The safety and effectiveness of the Woven EndoBridge (WEB) system for the treatment of wide-necked bifurcation aneurysms: final 12-month results of the pivotal WEB Intrasaccular Therapy (WEB-IT) Study.** *J Neurointerv Surg* 2019;11:924–30 [CrossRef Medline](#)
- Pierot L, Moret J, Barreau X, et al. **Safety and efficacy of aneurysm treatment with WEB in the cumulative population of three prospective, multicenter series.** *J Neurointerv Surg* 2018;10:553–59 [CrossRef Medline](#)
- Liebig T, Killer-Oberpfalzer M, Gal G, et al. **The safety and effectiveness of the Contour Neurovascular System (Contour) for the treatment of bifurcation aneurysms: the CERUS Study.** *Neurosurgery* 2022;90:270–77 [CrossRef Medline](#)
- Piotin M, Fahed R, Redjem H, et al. **The ARTISSE intrasaccular device for intracranial aneurysm treatment: short-term, mid-term and long-term clinical and angiographic results.** *J Neurointerv Surg* 2022;14:957–61 [CrossRef Medline](#)
- Goyal N, Hoit D, DiNitto J, et al. **How to WEB: a practical review of methodology for the use of the Woven EndoBridge.** *J Neurointerv Surg* 2020;12:512–20 [CrossRef Medline](#)
- Mascitelli JR, Moyle H, Oermann EK, et al. **An update to the Raymond-Roy occlusion classification of intracranial aneurysms treated with coil embolization.** *J Neurointerv Surg* 2015;7:496–502 [CrossRef Medline](#)
- Pierot L, Spelle L, Vitry F, ATENA Investigators. **Immediate clinical outcome of patients harboring unruptured intracranial aneurysms treated by endovascular approach: results of the ATENA study.** *Stroke* 2008;39:2497–504 [CrossRef Medline](#)

20. Pierot L, Cognard C, Anxionnat R, et al; CLARITY Investigators. **Ruptured intracranial aneurysms: factors affecting the rate and outcome of endovascular treatment complications in a series of 782 patients (CLARITY study).** *Radiology* 2010;256:916–23 [CrossRef](#) [Medline](#)
21. Bhogal P, Brouwer PA, Yeo L, et al. **The Medina Embolic Device: Karolinska experience.** *Interv Neuroradiol* 2018;24:4–13 [CrossRef](#) [Medline](#)
22. Sourour NA, Vande Perre S, Maria FD, et al. **Medina® embolization device for the treatment of intracranial aneurysms: safety and angiographic effectiveness at 6 months.** *Neurosurgery* 2018;82:155–62 [CrossRef](#) [Medline](#)
23. Haffaf I, Clarençon F, Shotar E, et al. **Medina embolization device for the treatment of intracranial aneurysms: 18 months' angiographic results.** *J Neurointerv Surg* 2019;11:516–22 [CrossRef](#) [Medline](#)
24. Hassankhani A, Ghozy S, Amoukhteh M, et al. **Long-term outcomes of the Woven EndoBridge device for treatment of intracranial aneurysms: a systematic review and meta-analysis.** *Interv Neuroradiol* 2023 Jun 26. [Epub ahead of print] [CrossRef](#) [Medline](#)
25. Pierot L, Szikora I, Barreau X, et al. **Aneurysm treatment with the Woven EndoBridge (WEB) device in the combined population of two prospective, multicenter series: 5-year follow-up.** *J Neurointerv Surg* 2023;15:552–57 [CrossRef](#) [Medline](#)
26. Dmytriw AA, Diestro JD, Dibas M, et al. **International study of intracranial aneurysm treatment using Woven EndoBridge: results of the WorldWideWEB Consortium.** *Stroke* 2022;53:e47–49 [CrossRef](#) [Medline](#)
27. Hecker C, Broussalis E, Pfaff JA, et al. **Comparison of the Contour Neurovascular System and Woven EndoBridge device for treatment of wide-necked cerebral aneurysms at a bifurcation or side-wall.** *J Neurosurg* 2023;139:563–72 [CrossRef](#) [Medline](#)
28. Pötin M, Biondi A, Sourour N, et al. **The LUNA aneurysm embolization system for intracranial aneurysm treatment: short-term, mid-term and long-term clinical and angiographic results.** *J Neurointerv Surg* 2018;10:e34 [CrossRef](#) [Medline](#)